This is a digital copy of a book that was preserved for generations on library shelves before it was carefully scanned by Google as part of a project to make the world's books discoverable online.

It has survived long enough for the copyright to expire and the book to enter the public domain. A public domain book is one that was never subject to copyright or whose legal copyright term has expired. Whether a book is in the public domain may vary country to country. Public domain books are our gateways to the past, representing a wealth of history, culture and knowledge that's often difficult to discover.

Marks, notations and other marginalia present in the original volume will appear in this file - a reminder of this book's long journey from the publisher to a library and finally to you.

Usage guidelines

Google is proud to partner with libraries to digitize public domain materials and make them widely accessible. Public domain books belong to the public and we are merely their custodians. Nevertheless, this work is expensive, so in order to keep providing this resource, we have taken steps to prevent abuse by commercial parties, including placing technical restrictions on automated querying.

We also ask that you:

+ *Make non-commercial use of the files* We designed Google Book Search for use by individuals, and we request that you use these files for personal, non-commercial purposes.
+ *Refrain from automated querying* Do not send automated queries of any sort to Google's system: If you are conducting research on machine translation, optical character recognition or other areas where access to a large amount of text is helpful, please contact us. We encourage the use of public domain materials for these purposes and may be able to help.
+ *Maintain attribution* The Google "watermark" you see on each file is essential for informing people about this project and helping them find additional materials through Google Book Search. Please do not remove it.
+ *Keep it legal* Whatever your use, remember that you are responsible for ensuring that what you are doing is legal. Do not assume that just because we believe a book is in the public domain for users in the United States, that the work is also in the public domain for users in other countries. Whether a book is still in copyright varies from country to country, and we can't offer guidance on whether any specific use of any specific book is allowed. Please do not assume that a book's appearance in Google Book Search means it can be used in any manner anywhere in the world. Copyright infringement liability can be quite severe.

About Google Book Search

Google's mission is to organize the world's information and to make it universally accessible and useful. Google Book Search helps readers discover the world's books while helping authors and publishers reach new audiences. You can search through the full text of this book on the web at `http://books.google.com/`

No.

BOSTON
MEDICAL LIBRARY
ASSOCIATION,
19 BOYLSTON PLACE.

TRANSACTIONS

OF THE

AMERICAN

OPHTHALMOLOGICAL SOCIETY.

VOL. V.

1888-1890.

HARTFORD:
PUBLISHED BY THE SOCIETY.
1890.

CATALOGUED,
M. J.
3. 4. 1891

INDEX TO VOLUME V.

INDEX OF AUTHORS.

PAGE.

Bull, C. S. A contribution to the surgical treatment of membranous opacities in the vitreous, ... 34
An analysis of 90 cases of simple glaucoma, ... 243
Contributions to the subject of tumors of the orbit and neighboring cavities, ... 368
Case of double choked disc due to intracranial tumor — with autopsy, ... 378
Simple extraction of cataract without iridectomy, ... 572
The extraction of lenses dislocated into the vitreous humor, . . 598
Buller, F. Case of pulsating exophthalmos probably due to rupture of the carotid artery in the cavernous sinus, ... 22
Burnett, S. M. An analysis of the refraction of 576 healthy human corneæ, 48
Models for demonstrating refraction by crossed cylinders, . . 112
Callan, P. A. Treatment of ulcers of the cornea, ... 133
Capron, F. P. Case of glioma, ... 106
Carmalt, W. H. Contributions to ocular tumors, ... 545
Coggin, D. Some vagaries of accommodation, ... 429
Dennett, W. S. A new method of numbering prisms, ... 422
Derby, H. Eight Cases of rudimentary zonular double cataract, . . 722
Derby, R. H. Case of monocular neuro retinitis, ... 166
Emerson, J. B. Case of progressive hyperopic astigmatism, . . . 60
Green, J. On certain stereoscopic illusions evoked by prismatic and cylindrical spectacle glasses, ... 449
An elementary discussion of some cases of centrical refraction through tipped spectacle lenses, ... 690
Notes on twenty-one cases of cataract, ... 724
Gruening, E. Iridectomy in glaucoma, ... 287
Use of the curette in inveterate pannus, ... 304
Harlan, G. C. Hysterical blindness of ten years' duration in a healthy male subject, ... 327
Extensive vascular growth in the vitreous, ... 426
Periscopic cylindrical and sphero-cylindrical glasses, ... 433
Transient amblyopia with bi-temporal hemianopsia in a case of malarial cachexia, ... 640
New operation for symblepharon, ... 651
Transient pulsation of retinal arteries induced by use of homatropine, 653
A new ophthalmoscope, ... 730

PAGE.

Holt, E. The inefficiency of hydrobromate of homatropine in controlling accommodation, ... 413
Howe, L. Legislation for the prevention of blindness, ... 540
Jackson, Edward. A new form of cataract knife, ... 62
Bruise of eyeball, ... 68
Symmetrical aberration of the eye, ... 141
Report on designation of prisms, ... 150
The decentering of lenses for accurate prismatic effects, . . . 417
The absolute static refraction of the eye, ... 435
Progressive hyperopic astigmatism, ... 676
Kipp, C. J. Case of double vascular exophthalmos, ... 26
Further observations on malarial keratitis, ... 331
Knapp, H. Caries and necrosis of the walls of the orbit, ... 319
Koller, C. Blepharo-spasm, ... 161
Kollock, C. W. Two cases of glaucoma, ... 634
Lippincott, J. A. Irrigation of the anterior chamber, ... 341
New tests for binocular vision, ... 560
Milliken, B. L. Case of foreign body in the eye twenty years, . . 565
Complete paralysis of the lateral movements of both eyes, etc., . 644
Mittendorf, W. F. Symptomatic myopia, ... 70
Acute cocaine conjunctivitis, ... 155
Embolism of upper branch of retinal artery with normal vision, . 669
Moore, W. O. Hysterical blindness in the male, ... 80
Norris, W. F. Two cases of brain tumor, with interesting eye symptoms, 470
Foreign bodies in the orbit, ... 569
Noyes, H. D. Enucelation during panophthalmitis suppurativa, . . 314
The therapeutic effect of prisms in ophthalmic practice, . . 483
Oliver, C. A. Tests for color blindness, ... 86
Case of embolism of central retinal artery, ... 93
An analysis of some of the ocular symptoms observed in so-called general paresis, ... 355
Case of intra-cranial neoplasm with localizing eye symptoms, . 479
An analysis of the ocular symptoms found in the third stage of general paralysis of the insane, ... 646
Pomeroy, O. D. Three extractions of luxated lenses by means of the Agnew bident, ... 168
Pooley, T. R. Removal of large exostosis of orbit with preservation of the eye, ... 611
Operation for ectropion of the lower lid by sliding flap method, . 622
Randall, B. A. Cases of outgrowth on the optic disc, ... 116
Anomalies of the veins upon the optic disc, ... 117
Simple tests of the ocular muscles, ... 362
Can hypermetropia be healthfully outgrown, ... 657
Cyst of iris following penetrating wound, ... 718
Richey, S. O. A contribution to the management of initial myopia acquisita, ... 306
Rider, C. E. The winking test, ... 551

PAGE.
Risley, S. D. A new rotary prism, ... 412
Cyst of iris following penetrating wound, ... 718
St. John, S. B. Case of hemianopsia with peculiar cerebral symptoms, . 359
Standish, Myles. Partial tenotomies in cases of neurasthenia, etc., . 388
Sutphen, T. Y. Puncture of retina for detachment, ... 100
Case of sarcoma, ... 457
Tansley, J. O. New eye instruments, ... 63
Theobald, S. Case of double congenital iridiremia, ... 99
Unusually long eye-lash, ... 120
Is astigmatism a factor in the causation of glaucoma, ... 126
The employment of oleate of veratria to facilitate the determination of errors of refraction, ... 442
Report of a case of recurrent irido-choroido-retinitis, ... 629
Wadsworth, O. F. Two cases of extraction of steel from vitreous, . 349
Spastic torticollis cured by tenotomy, ... 381
Mydriasis of one eye with intact accommodation from homatropine, 408
Case of metastatic carcinoma of choroid, ... 654
Thrombosis of arteria centralis retinae, ... 672
Webster, D. Case of extraction of calcareous lens, ... 117
Some tenotomies for correction of heterophoria, ... 176
Williams, H. W. Multiple cysts of iris in both eyes, ... 326
Wilson, F. M. Specimen of filaria oculi humani, ... 727

INDEX OF SUBJECTS.

Accommodation, some vagaries of. Coggin, ... 429
Amblyopia (transient) with bi-temporal hemianopsia in case of malarial cachexia. Harlan, ... 640
An analysis of some of the ocular symptoms observed in so-called general paresis. Oliver, ... 355
An analysis of the ocular symptoms found in the third stage of general paralysis of the insane. Oliver, ... 646
Anomalies of veins upon the optic disc. Randall, ... 177
Astigmatism a factor in the causation of glaucoma. Theobald, . . 126
Binocular vision, new tests for. Lippincott, ... 560
Blepharo-spasm. Koller, ... 161
Brain-tumor, two cases of, with interesting eye symptoms. Norris, . . 470
Bruise of eyeball. Jackson, ... 68
Caries and necrosis of walls of orbit. Knapp, ... 319
Cataract, eight cases of rudimentary zonular double. H. Derby, . . 722
simple extraction of. Bull, ... 572
notes on twenty-one cases. Green, ... 724
knife, a new form of. Jackson, ... 62

PAGE.
Centrical refraction through tipped spectacle lenses. Green, . . . 690
Cocaine conjunctivitis, acute. Mittendorf, ... 155
Color blindness, tests for. Oliver, ... 86
Corneæ, analysis of the refraction of 576 healthy human. Burnett, . 48
Cysts (multiple) of iris in both eyes. Williams, ... 326
Cyst of iris following penetrating wound. Randall and Risley, . . 718
Decentering of lenses for accurate prismatic effects. Jackson, . . 417
Designation of prisms, report on. Jackson, ... 150
Double choked disc due to intra-cranial tumor. Bull, ... 378
Ectropion of the lower lid, operation for by sliding flap method. Pooley, 622
Embolism of upper branch of retinal artery with normal vision. Mittendorf, ... 669
Embolism central retinal artery, case of. Oliver, ... 93
Enucleation during panophthalmitis suppurativa. Noyes, . . . 314
Exophthalmos, case of pulsating. Buller, ... 22
Case of double vascular. Kipp, ... 26
Exostosis of orbit, removal of with preservation of eye. Pooley, . . 611
Extraction of steel from vitreous, two cases. Wadsworth, . . . 349
Eye-lash, an unusually long. Theobald, ... 120
Filaria oculi humani, specimens of. Wilson, ... 727
Foreign body in the eye 20 years. Milliken, ... 565
Foreign bodies in the orbit. Norris, ... 569
Glaucoma, two cases of. Kollock, ... 634
iridectomy in. Gruening, ... 287
simplex, analysis of 90 cases. Bull, ... 243
Glioma, case of. Capron, ... 106
Hemianopsia, case of, with peculiar cerebral symptoms. St. John, . 359
Hydrobromate of homatropine, the inefficiency of in controlling accommodation. Holt, ... 413
Hypermetropia, can it be healthfully outgrown. Randall, . . . 657
Hysterical blindness, ten years duration in healthy male. Harlan, . 327
in the male. Moore, ... 80
Intra-cranial neoplasm with localizing eye symptoms. Oliver, . . 479
Iridiremia, case of double congenital. Theobald, ... 99
Irrigation of anterior chamber. Lippincott, ... 341
Lens, extraction of calcareous. Webster, ... 117
Lenses dislocated into vitreous, extraction of. Bull, ... 598
Luxated lenses, three extractions of by means of the Agnew bident. Pomeroy, ... 168
Malarial keratitis. Kipp, ... 331
Membranous opacities in vitreous, surgical treatment of. Bull, . . 34
Metastatic carcinoma of choroid. Wadsworth, ... 654
Mydriasis of one eye, with intact accommodation from homatropine. Wadsworth, ... 408
Myopia acquisita, contribution to the management of. Richey, . . 306
Neuro retinitis, case of monocular. R. H. Derby, ... 166
New eye instruments. Tansley, ... 63

PAGE.
Ocular muscles, simple tests of. Randall, ... 362
Ocular tumors, contributions to. Carmalt, ... 545
Oleate of veratria, the employment of to facilitate the determination of errors of refraction. Theobald, ... 442
Ophthalmoscope, a new. Harlan, ... 730
Outgrowth on the optic disc, cases of. Randall, ... 116
Pannus, use of the curette in. Gruening, ... 304
Paralysis of lateral movements of both eyes, etc. Milliken, ... 644
Partial tenotomies in cases of neurasthenia. Standish, ... 388
Periscopic cylindrical and sphero-cylindrical glasses. Harlan, . . . 433
Prevention of blindness, legislation for. Howe, ... 540
Prisms in ophthalmic practice, the therapeutic effect of. Noyes, . . . 483
new method of numbering. Dennett, ... 442
Prism, a new rotary. Risley, ... 412
Progressive hyperopic astigmatism. Emerson, ... 60
Jackson, ... 676
Pulsation (transient) of retinal arteries induced by homatropine. Harlan, 653
Puncture of retina for detachment. Sutphen, ... 100
Recurrent irido-choroiditis, case of. Theobald, ... 629
Refraction, models for demonstrating. Burnett, ... 112
Sarcoma, case of. Sutphen, ... 457
Spastic torticollis cured by tenotomy. Wadsworth, ... 381
Static refraction of the eye. Jackson, ... 435
Stereoscopic illusions evoked by prismatic and cylindrical glasses. Green, 449
Symblepharon, new operation for. Harlan, ... 651
Symmetrical aberration of the eye. Jackson, ... 141
Symptomatic myopia. Mittendorf, ... 70
Tenotomies for correction of heterophoria. Webster, ... 176
Thrombosis of arteria centralis retinae. Wadsworth, ... 672
Tumors of orbit and neighboring cavities. Bull, ... 368
Ulcers of cornea, treatment of. Callan, ... 133
Vascular growth in vitreous. Harlan, ... 426
Winking test. Rider, ... 551



C. R. Ashman

TRANSACTIONS

OF THE

AMERICAN

OPHTHALMOLOGICAL SOCIETY.

Twenty-Fourth Annual Meeting.

BOSTON MEDICAL
MAR 5 1889
LIBRARY ASS'N.

NEW LONDON, CONN., 1888.

HARTFORD:
PUBLISHED BY THE SOCIETY.
1888.

OCT 20 1889

PRESS OF
THE CASE, LOCKWOOD & BRAINARD CO.,
HARTFORD, CONN.

BOSTON MEDICAL
MAR 4 1891
LIBRARY ASS'N.

CONTENTS.

PAGE.

Members of the Society, ... 5
Minutes of Twenty-fourth Annual Meeting, ... 9
Memorial notice of Dr. C. R. Agnew, ... 14
Memorial notice of Dr. E. G. Loring, ... 16
Memorial notice of Dr. Joseph Aub, ... 21
Case of Pulsating Exophthalmos, probably due to rupture of the carotid artery in the cavernous sinus, F. Buller, M.D., Montreal, ... 22
Case of Double Vascular Exophthalmos, with recovery under intermittent compression of the carotid artery and iodide of potassium, C. J. Kipp, M.D., Newark, ... 26
A Contribution to the Surgical Treatment of Membranous Opacities in the Vitreous, C. S. Bull, M.D., New York, . . 34
An Analysis of the Refraction of 576 Healthy Human Corneæ, examined with the ophthalmometer of Javal & Schiötz, Swan M. Burnett, M.D., Washington, ... 48
A case of Progressive Hyperopic Astigmatism, J. B. Emerson, M.D., New York, ... 60
A New Form of Cataract Knife, Edw. Jackson, M.D., Phila., . 62
New Eye Instruments, J. Oscroft Tansley, New York, . . . 63
Bruise of Eye-ball, etc., Edw. Jackson, M.D., Phila., . . . 68
Symptomatic Myopia, W. F. Mittendorf, M.D., New York, . . 70
Hysterical Blindness in the Male (three cases), W. O. Moore, M.D., New York, ... 80
Tests for Color-blindness, C. A. Oliver, M.D., Phila., . . . 86
Case of Embolism of Central Retinal Artery, C. A. Oliver, M.D., Phila., ... 93
Case of Double Congenital Iridiremia, S. Theobald, M.D., Baltimore, ... 99
Puncture of Retina for Detachment (three operations), T. Y. Sutphen, M.D., Newark, ... 100
Case of Glioma, with remarks, F. P. Capron, M.D., Providence, . 106
Models for Demonstrating Refraction by Crossed Cylinders, shown by Swan M. Burnett, M.D., Washington, . . 112
Cases of Outgrowth on the Optic Disc, B. A. Randall, M.D., Phila., 116

PAGE.

Anomalies of the Veins upon the Optic Disc, B. A. Randall, M.D., Phila., ... 117
Case of Extraction of Calcareous Lens, David Webster, M.D., New York, ... 117
Unusually Long Eye lash, S. Theobald, M.D., Baltimore, . . 120
Minutes of special meeting, Washington, Sept. 19th, . . . 125
Is Astigmatism a Factor in the Causation of Glaucoma, S. Theobald, M.D., Baltimore, ... 126
Treatment of Ulcers of the Cornea, P. A. Callan, M.D., New York, 133
Symmetrical Aberration of the Eye, Edw. Jackson, M.D., Phila., . 141
Report on the Designation of Prisms by Degree of Refractive Power, by committee, Edw. Jackson, Chairman, . . . 150
Acute Cocaine Conjunctivitis, W. F. Mittendorf, M.D., New York, 155
Blepharo-spasm, Carl Koller, M.D., New York, ... 161
Case of Monocular Neuro-Retinitis, R. H. Derby, M.D., New York, 166
Three Extractions of Luxated Lenses by means of the Agnew Bident, O. D. Pomeroy, M.D., New York, ... 168
Some Tenotomies for the Correction of Heterophoria, David Webster, M.D., New York, ... 176

MEMBERS

OF THE

AMERICAN OPHTHALMOLOGICAL SOCIETY,

1888-9.

ACTIVE MEMBERS.

Dr. F. W. Abbott,	Buffalo, N. Y.
Dr. A. Alt,	St. Louis, Mo.
Dr. J. A. Andrews,	New York, N. Y.
Dr. S. C. Ayres,	Cincinnati, O.
Dr. William T. Bacon,	Hartford, Conn.
Dr. Edwin W. Bartlett,	Milwaukee, Wis.
Dr. H. W. Bradford,	Boston, Mass.
Dr. Charles S. Bull,	New York, N. Y.
Dr. F. Buller,	Montreal, Canada.
Dr. Swan M. Burnett,	Washington, D. C.
Dr. Peter A. Callan,	New York, N. Y.
Dr. F. P. Capron,	Providence, R. I.
Dr. W. H. Carmalt,	New Haven, Conn.
Dr. D. C. Cocks,	New York, N. Y.
Dr. David Coggin,	Salem, Mass.
Dr. H. Culbertson,	Zanesville, Ohio.
Dr. George R. Cutter,	Brooklyn, N. Y.
Dr. David De Beck,	Cincinnati, O.
Dr. W. S. Dennett,	New York, N. Y.
Dr. Hasket Derby,	Boston, Mass.
Dr. Richard H. Derby,	New York, N. Y.
Dr. Lewis S. Dixon,	Boston, Mass.
Dr. Stephen Dodge,	Halifax, Nova Scotia.
Dr. Abram Du Bois,	New York, N. Y.

Dr. J. B. Emerson,	New York, N. Y.
Dr. L. Webster Fox,	Philadelphia, Pa.
Dr. B. E. Fryer,	Kansas City, Mo.
Dr. John Green,	St. Louis, Mo.
Dr. Emil Gruening,	New York, N. Y.
Dr. A. D. Hall,	Philadelphia, Pa.
Dr. H. F. Hansell,	Philadelphia, Pa.
Dr. George C. Harlan,	Philadelphia, Pa.
Dr. Gustavus Hay,	Boston, Mass.
Dr. Albert G. Heyl,	Philadelphia, Pa.
Dr. Edward L. Holmes,	Chicago, Ill.
Dr. E. E. Holt,	Portland, Me.
Dr. Lucien Howe,	Buffalo, N. Y.
Dr. Edward Jackson,	Philadelphia, Pa.
Dr. B. Joy Jeffries,	Boston, Mass.
Dr. Samuel J. Jones,	Chicago, Ill.
Dr. Charles J. Kipp,	Newark, N. J.
Dr. H. Knapp,	New York, N. Y.
Dr. Charles W. Kollock,	Charleston, S. C.
Dr. J. A. Lippincott,	Pittsburg, Pa.
Dr. F. B. Loring,	Washington, D. C.
Dr. C. J. Lundy,	Detroit, Mich.
Dr. W. V. Marmion,	Washington, D. C.
Dr. Arthur Mathewson,	Brooklyn, N. Y.
Dr. S. F. McFarland,	Binghamton, N. Y.
Dr. Chas. H. McIlwaine,	Trenton, N. J.
Dr. R. J. McKay,	Wilmington, Del.
Dr. C. S. Merrill,	Albany, N. Y.
Dr. B. L. Milliken,	Cleveland, Ohio.
Dr. H. G. Miller,	Providence, R. I.
Dr. J. Lancelot Minor,	Memphis, Tenn.
Dr. W. F. Mittendorf,	New York, N. Y.
Dr. William O. Moore,	New York, N. Y.
Dr. Russell Murdoch,	Baltimore, Md.
Dr. William F. Norris,	Philadelphia, Pa.
Dr. Henry D. Noyes,	New York, N. Y.
Dr. J. F. Noyes,	Detroit, Mich.
Dr. Charles A. Oliver,	Philadelphia, Pa.
Dr. Henry S. Oppenheimer,	New York, N. Y.
Dr. O. D. Pomeroy,	New York, N. Y.
Dr. Thomas R. Pooley,	New York, N. Y.

Dr. M. H. Post,	St. Louis, Mo.
Dr. J. S. Prout,	Brooklyn, N. Y.
Dr. B. Alexander Randall,	Philadelphia, Pa.
Dr. William Rankin,	Newark, N. J.
Dr. Stephen O. Richey,	Washington, D. C.
Dr. Charles E. Rider,	Rochester, N. Y.
Dr. Samuel D. Risley,	Philadelphia, Pa.
Dr. Edmund C. Rivers,	Denver City, Col.
Dr. D. B. St. John Roosa,	New York, N. Y.
Dr. John D. Rushmore,	Brooklyn, N. Y.
Dr. Robert Sattler,	Cincinnati, O.
Dr. H. S. Schell,	Los Angeles, Cal.
Dr. W. W. Seely,	Cincinnati, O.
Dr. Henry L. Shaw,	Boston, Mass.
Dr. J. A. Spaulding,	Portland, Me.
Dr. Francis P. Sprague,	Boston, Mass.
Dr. Myles Standish,	Boston, Mass.
Dr. George T. Stevens,	New York, N. Y.
Dr. Samuel B. St. John,	Hartford, Conn.
Dr. George Strawbridge,	Philadelphia, Pa.
Dr. T. Y. Sutphen,	Newark, N. J.
Dr. J. Oscroft Tansley,	New York, N. Y.
Dr. Lewis H. Taylor,	Wilkesbarre, Pa.
Dr. Samuel Theobald,	Baltimore, Md.
Dr. William Thomson,	Philadelphia, Pa.
Dr. John Van Duyn,	Syracuse, N. Y.
Dr. J. J. B. Vermyne,	New Bedford, Mass.
Dr. O. F. Wadsworth,	Boston, Mass.
Dr. Leroy Pope Walker,	New York, N. Y.
Dr. David Webster,	New York, N. Y.
Dr. Robert Willard,	Boston, Mass.
Dr. Charles H. Williams,	Chicago, Ill.
Dr. Henry W. Williams,	Boston, Mass.
Dr. F. M. Wilson,	Bridgeport, Conn.
Dr. J. P. Worrell,	Terre Haute, Ind.
Total,	100.

HONORARY MEMBER.

Dr. C. Schweigger,	Berlin, Prussia.
Whole Number,	101.

MINUTES OF THE PROCEEDINGS.

TWENTY-FOURTH ANNUAL MEETING.

PEQUOT HOUSE,
NEW LONDON, July 17, 1888.

The Twenty-fourth Annual Meeting of the Society was called to order by the President, Dr. WILLIAM F. NORRIS, at 10 A. M. The President made fitting allusion to the deaths of Drs. Agnew and Loring, appointed Dr. Myles Standish, Secretary, *pro tem*, and announced the following committees:

Committee on Bulletin — Drs. SWAN M. BURNETT and F. BULLER.

Committee on Membership — Drs. JOHN GREEN, ARTHUR MATHEWSON, SAMUEL THEOBALD, W. H. CARMALT, and C. S. BULL.

Auditing Committee — Dr. C. J. KIPP.

The Treasurer's Report was read and referred to the Auditing Committee, and subsequently accepted and ordered to be placed on file.

Voted,— That the assessment for 1888–1889 be $10.

The Society went into Executive Session, and several nominations for membership were received.

Regular session resumed.

Drs. Carl Koller of New York and Frank Nodine of Cleveland, and all members of the Otological Society present in New London were invited to attend the meetings of the Society at this session.

Dr. H. D. Noyes read a memorial of the late Dr. C. R. Agnew, which was referred to the Publishing Committee.

On motion of Dr. Carmalt, it was voted that the Chair appoint a committee to make the proper minutes on the record of the death of Dr. E. G. Loring.

The Chair appointed Drs. Carmalt and Bull.

Dr. Green moved and it was voted that Dr. Kipp be asked to draw up a proper minute in regard to the death of Dr. Joseph Aub.

Dr. Green moved that the Publishing Committee be authorized to insert the portrait of Dr. Agnew in the next published transactions of the Society.

Dr. Dennett moved that the same authority in regard to the publication of a portrait be authorized in the case of Dr. Loring.

Both motions prevailed unanimously.

The Committee on Bulletin reported, and the following papers were read:

1. "A contribution to the treatment of Membranous Opacities in the Vitreous," by Dr. C. S. Bull. Discussed by Drs. Strawbridge, Dennett, and Theobald.

2. "A case of Pulsating Exophthalmos," by Dr. F. Buller.

3. "A case of Pulsating Exophthalmos," by Dr. C. J. Kipp. These cases were discussed by Drs. Tansley, Carmalt, Risley, and Randall.

4. "Refraction of the Cornea," by Dr. S. M. Burnett. Discussed by Drs. Koller, Noyes, Theobald, and Randall.

5. "Progressive Hypermetropic Astigmatism," by Dr. J. B. Emerson.

6. "A new Cataract Knife," by Dr. E. Jackson.

7. "Lachrymal Syringe and other New Instruments," by Dr. J. O. Tansley. Discussed by Drs. Theobald, Risley, Mittendorf, and Noyes.

8. "Bruise of the Eyeball," by Dr. Edward Jackson.

9. "Sympathetic Myopia," by Dr. W. F. Mittendorf. Discussed by Drs. Tansley, Koller, Butler, Risley, and Green.

Adjourned at 2 P. M. to meet at 8 P. M.

Meeting called to order at 8 P. M.

Executive Session.

Dr. Kipp reported that the Treasurer's report had been audited and found correct.

Dr. Green reported for the Committee on Admissions, that the following gentlemen were recommended for election to the Society: Dr. CHAS. W. KOLLOCK; Dr. F. M. WILSON; Dr. LEWIS H. TAYLOR; Dr. J. C. LUNDY; Dr. B. J. MILLIKEN.

Upon ballot, all of the above-named gentlemen were elected members of the Society.

Dr. Green read the following from the Executive Committee:

Recommended.—That a special meeting of this Society be held at the Arlington Hotel, Washington, D. C., on September 19, 1888. Said meeting to be for the consideration of scientific subjects only, to the exclusion of all matters of business, which if brought before said special meeting shall be laid over until the next regular meeting in July, 1889.

The Society adopted the recommendation of the committee.

The Committee on Membership made the following nominations:

For President—Dr. W. F. NORRIS.
For Vice-President—Dr. HASKET DERBY.
For Corresponding Secretary—Dr. J. S. PROUT.
For Recording Secretary—Dr. S. B. ST. JOHN.
For Publishing Committee—Drs. D. B. ST. JOHN ROOSA, W. S. DENNETT, and the Secretary (*ex officio*).

The above officers were unanimously elected.

The Committee recommended as the place of the next Annual Meeting, The Pequot House, New London, Conn., and it was so voted.

The Bulletin was then resumed.

10. "Hysterical Blindness in the Male," by Dr. William O. Moore. Discussed by Drs. Randall, Noyes, Webster, Risley, and Jackson.

11. "A Test for Color-blindness," by Dr. Chas. A. Oliver.

12. "Embolism of Central Retinal Artery," by Dr. Chas. A. Oliver. Discussed by Drs. Mittendorf, Burnett, and Noyes.

Adjourned to 9 A. M. 19th July.

Meeting called to order at 9.30 A. M.

The records of the previous day were read and accepted, and the Chair appointed the following committee on discipline: Drs. Green, Bull, Mathewson, Carmalt, and Theobald.

The name of Dr. Carl Koller was proposed for membership by Drs. Carmalt and Norris.

The Bulletin was then resumed:

13. "A Case of Double Congenital Iridiremia," by Dr. S. Theobald. Discussed by Dr. Randall.

14. "Puncture of the Retina for Detachment," by Dr. T. Y. Sutphen. Discussed by Drs. Webster, Jackson, Holt, and J. F. Noyes.

15. "Exhibition of Photograph of a Case of Glioma," by Dr. F. P. Capron. Discussed by Drs. J. F. Noyes, Sutphen, Randall, St. John, Webster, Norris, and Jackson.

16. "Exhibition of Models showing the Refraction of Cylinders," by Dr. Swan M. Burnett. Discussed by Drs. Koller, Jackson, and Randall.

17. "A Case of Anomalous Outgrowth on the Optic Disk together with Drawings of anomalies of the Retinal Vessels," by Dr. B. A. Randall.

18. "Extraction of a Partially Absorbed Calcareous Lens," by Dr. David Webster.

19. * "The Designation of Prisms by their Refracting Power," by Dr. Edward Jackson. Discussed by Dr. Koller.

On motion of Dr. Mittendorf, it was voted that a committee be appointed to consider the subject of the designation of prisms, and to report at the Washington meeting, and Drs.

* Not published as a separate paper, as the substance is embodied in the committee report further on.

Edward Jackson, H. D. Noyes, and Swan M. Burnett were appointed as the committee.

20. "Card Specimen," by Dr. Samuel Theobald.

Adjourned.

Present at the Twenty-fourth Annual Meeting:

Dr. Chas. S. Bull,
Dr. F. Buller,
Dr. Swan M. Burnett,
Dr. Peter A. Callan,
Dr. F. P. Capron,
Dr. W. H. Carmalt,
Dr. David Coggin,
Dr. George R. Cutter,
Dr. W. S. Dennett,
Dr. J. B. Emerson,
Dr. L. Webster Fox,
Dr. John Green,
Dr. E. E. Holt,
Dr. Edward Jackson,
Dr. Chas. J. Kipp,
Dr. Arthur Mathewson,
Dr. C. S. Merrill,
Dr. H. G. Miller,
Dr. W. F. Mittendorf,
Dr. Wm. O. Moore,
Dr. William F. Norris,
Dr. Henry D. Noyes,
Dr. J. F. Noyes,
Dr. Chas. A. Oliver,
Dr. J. S. Prout,
Dr. B. Alexander Randall,
Dr. Samuel D. Risley,
Dr. Myles Standish,
Dr. Samuel B. St. John,
Dr. George Strawbridge,
Dr. T. Y. Sutphen,
Dr. J. Oscroft Tansley,
Dr. Samuel Theobald,
Dr. J. J. B. Vermyne,
Dr. David Webster.

Present by invitation:

Dr. Carl Koller,
Dr. Frank Nodine.

MYLES STANDISH,
Secretary, *pro tem.*

DR. CORNELIUS REA AGNEW.

In Memoriam.

By HENRY D. NOYES, M. D.,
NEW YORK.

The death of Dr. Cornelius Rea Agnew, of New York, has removed from the American Ophthalmological Society one of its founders and most important members.

He was president from 1873 to 1878. He habitually attended its meetings, was active in shaping its policy, and contributing to its scientific proceedings.

The beginning of his professional career was at the period when modern ophthalmology was entering upon its brilliant development and he threw himself into it with characteristic energy. He quickly made his high abilities felt and gained wide reputation. He displayed special adaptation to the practice of his art, in operative work and sagacious treatment. His manner induced confidence and his devotion deserved it; while the fertility of his resources, the promptness and zeal of his service commanded a full measure of success even under difficult conditions. The same admirable qualities which made his early reputation, have sustained his high position through a period of over thirty years. He has long been recognized both in Europe and in this country as one of the foremost in clinical ophthalmology.

The papers which he has contributed in the transactions of this society and elsewhere have been characterized by originality and a practical quality. He busied himself with questions which touch the exigencies of disease more than with the theories and processes of disease. His skill, his tact, his courtesy, his retentive memory, his readiness to seize the salient features of a case, easily account for the high esteem with which he was regarded, and the wide demand for his services.

His was a strong character, and he was a leader among men.

Exerting a powerful influence in every sphere where he moved, he was not ambitious for himself, but labored for the things which are true and right and beneficent. His activities ranged over an extraordinary breadth of interests. On the professional side, he was active in the management of medical societies of his own city, of the state, and of the country. He took deep interest in the management of charitable institutions, especially the comfort and hygiene of their inmates. He took part in the formation and for many years was a manager of the Insane Asylum at Poughkeepsie; he was appointed by President Arthur on the commission to care for the Indians; he was most widely known for his devotion to the work of the Sanitary Commission during the civil war; he founded one Eye and Ear hospital in Brooklyn, and another in New York. The extent of his labors in such directions cannot be enumerated.

He was professor of Ophthalmology and Otology in the College of Physicians and Surgeons of New York, and threw himself earnestly into the effort to improve the quality of medical education. He was at his death president of its alumni association. As a trustee of Columbia College, and especially in connection with the establishment of its School of Mines, he showed the breadth of his views in general education. In religious and charitable work he was constantly active, yet he never was intolerant of the views and feelings of others nor did he make his own offensively conspicuous.

In civil affairs he took an influential part, not as a partisan, yet with strong convictions and persistent effort. We cannot here do more than indicate imperfectly the scope and value of the beneficent and enlightened labors of our deceased colleague in his professional work in science, in society, in the State, and in religion. His eulogy has been written, and we simply record our testimony to his noble character, to his untiring and unselfish activities, to his great and merited success, and to the beneficent and fragrant memories which he has left behind him. We express our deep regret at his loss; we point to his life and work as a glorious achievement.

EDWARD GREELY LORING, JR.,

The second son of Judge E. G., and Harriet Booth Loring; was born in Boston in 1837. He began his medical studies in Florence, Italy, in 1859, continued them there and at Pisa for three years, giving especial attention to anatomy under Professor Duranti, the representative of the Italian government to the International Medical Congress held in Washington in 1887. In 1862 he returned to Boston, entered the Harvard Medical school, and was graduated therefrom in 1864. The brilliant labors of Von Graefe, Donders, Helmholtz and others in the field of scientific ophthalmology were just then being announced, and bearing fruit, and Dr. Loring determined to study in the same line. He took a service as externe to the ophthalmic clinic at the Boston City Hospital, and also followed the service of the Massachusetts Charitable Eye and Ear Infirmary. In 1865 he went to Baltimore, Md., to practice. The following year he came to New York, entering into a partnership with Dr. C. R. Agnew. He was appointed surgeon to the Brooklyn Eye and Ear Hospital, and on its foundation, to the Manhattan Eye and Ear Hospital. He afterwards became surgeon to the New York Eye and Ear Infirmary, and served it until his death. He was also ophthalmic surgeon to St. Luke's hospital, and besides being a member of this society since 1865, he was a member of the New York State Medical Society, of the New York Academy of Medicine, of the New York County Medical Society, of the New York Ophthalmolgical Society, of the Roman Medical Society, and of the American Neurological Association. He was twice married; his first wife was a daughter of the art connoisseur, James Jackson Jarvis, his second was Mrs. Swift of New York city, who survives him. He had no children.

His death, which occurred on the 23d of April, 1888, was very sudden; he was walking across a street, was seen by a policeman to stagger, catch at a lamp-post and fall, by the time the first one reached him he was already dead. The only lesion detected at the autopsy was an atheroma of the coronary arteries.

EDWARD G. LORING, M.D.

From the above statement of the positions of public professional trust and honor and of his society memberships it is evident that Dr. Loring was a man of industrious professional habits and your committee has regarded it as desirable that this society in which so much of his work was done should have a record of his professional labors beyond that contained within its own limits. We have therefore collected the titles of all the articles which Dr. Loring published so far as we could get traces of them. It is an honorable record of an active professional life, crowned at the close by the "Text Book on Ophthalmoscopy," the revision of the last volume of which he was engaged upon to the day of his death.

While your committee do not regard it as necessary to indulge in eulogium on one with whose worth all are so well acquainted, they know they are but expressing the feelings of each member of the society in referring to the deep regret with which they contemplate the loss of one so earnest in the advancement of the science to which we are all attached. We believe we do not exaggerate when we say that by his writings on ophthalmological subjects and by his perfection of the ophthalmoscope he has done more than any other one man to place American ophthalmology abreast with that of the world, and while perhaps not strikingly original in opening new avenues for investigation, his mind was thoroughly independent and critical in the best sense of the term. Scrupulously upright and honest himself, his scorn of all forms of sham, whether of professional pretence or otherwise, was profound and it may be his denunciation was sometimes aggressive, but never carried beyond the bounds of social courtesy; withal he was charitable, and unless the thing was flagrant or intentional he would pass it by. Woe, however, betide the venturesome one who openly advocated unjust claims or made pretensions not justified by an honest consideration of the facts.

He was loyal and lovable in his friendships, and to those who had the pleasure of an intimate acquaintance his personality had a charm that will not be forgotten.

WM. H. CARMALT, M.D.,
CHAS. STEDMAN BULL, M.D., } *Committee.*

CONTRIBUTIONS OF DR. EDWARD G. LORING, JR., TO OPHTHALMIC LITERATURE.

1. The Causes of Exudation in Inflammation.— Boylston Prize Essay, 1864.

2. Report of Operations in the Department of Ophthalmic Surgery at the Boston City Hospital. — Boston Med. and Surg. Journal, Dec. 1, 1864, and Jan. 26, 1865.

3. The Comparative Merits of the Nitrate of Silver and the Sulphate of Copper in certain forms of Conjunctivitis. — Boston Med. and Surg. Jour., July 27, 1865.

4. Tests for the Insufficiency of the Recti Interni. — Boston Med. and Surg. Jour., Dec. 31, 1867. Trans. Amer. Ophthalmological Soc., 1868.

5. Relative Accommodation. — Trans. of Amer. Ophthalmological Society, 1868. Amer. Jour. Med. Science, Jan., 1869.

6. Relative Accommodation in Strabismus and Insufficiency of the Recti Muscles.— Trans. of Amer. Ophthal. Soc., 1869.

7. A Modification of the Ophthalmoscope. — Trans. of Am. Ophthalmol. Soc., 1869.

8. Remarks on Strabismus. — Boston Med. and Surg. Jour., Dec. 9, 1869.

9. The Light Streak seen in the Center of the Retinal Vessels. — Trans. of Amer. Ophthal. Soc., 1870; ditto 1873, and New York Med. Jour., XIX, 30.

10. The use of Concave Glasses in Asthenopia. — New York Med. Journal, IV, 347, and V, 89.

11. The Determination of the Optical Condition of the Eye by means of the Ophthalmoscope, with a new modification of the instrument for that purpose. — Amer. Jour. Med. Science, April, 1870.

12 and 13. The Halo around the Macula Lutea. — Trans. of Amer. Ophthal. Soc., 1871 ; ditto, Report of Fifth International Ophthalmological Congress, New York, 1876.

14. Remarks on Cataract. — Trans. of Amer. Ophthal. Soc., 1871 ; Boston Med. and Surg. Jour., Oct. 12, 1871, Dec. 31, 1871, Jan. 25, 1872.

15. Divergent Strabismus. — Amer. Jour. Med. Science, April, 1871.

16. The Modern Operation for Strabismus. — New York Med. Record, April 12, 1872.

17. A new Modification of the Ophthalmoscope. — Trans. Amer. Ophthal. Society, 1874; Amer. Jour. Med. Science, Jan. 1874.

18. Syphilitic Gumma on the Ciliary Body, (in conjunction with Dr. H. C. Eno.)—Trans. Amer. Ophthal. Society, 1874.

19. The History of the Ophthalmoscope as an Optometer. — New York Med. Record, March 2, 1874.

20. Remarks on Embolism. — Amer. Jour. Med. Science, April, 1874.

21. The Retinal Circulation and the Mechanical Causes of Choked Disk. — New York Med. Record, Jan. 16, 1875.

22. Etiology of Choked Disk in Brain Disease. — Amer. Jour. Med. Science, October, 1875.

23. — Some remarks on the circulation of the retina and its relation to that of the brain. — Amer. Psychological Jour., Nov., 1875.

24. Are progressive Myopia and Conus due to hereditary predisposition, or can they be induced by defect of refraction acting through the influence of the ciliary muscle. — Trans. International Med. Cong., Phila., 1876.

25. The Metric System as applied to the Ophthalmoscope. — Report of the Fifth Inter. Ophthal. Cong., New York, 1876, and Boston Med. and Surg. Jour., Sept. 7, 1876.

26. Determination of the Refraction of the Eye by means of the Ophthalmoscope. — (Advanced sheets of text-book on Ophthalmoscopy). New York: William Wood & Co., 1876.

27. Remarks on the Ciliary Muscle. — Report of the Fifth Inter. Ophthal. Cong., New York, 1876.

28. A new Modification of the Ophthalmoscopic Mirror. — New York Med. Record, Jan. 6, 1877.

29. The Care of the Eyes. — New York Med. Record, April 7, 1877.

30. Historical Note on Modern Ophthalmoscopes. — New York Med. Record, June 9, 1877.

31. A reply to Dr. Knapp on Ophthalmoscope making. — New York Med. Record, June 23, 1877.

32. Is the human eye changing its form under the influence of modern education. — New York Med. Record, Nov. 17, 1877.

33. The influence of vitiated air and the direction of light upon eyes. — Public Health, London, 1877, VI, 359-362.

34. The effect of the optical condition of the eye on the development of character. — Trans. of Med. Soc. of the State of New York, 1879.

35. A reply to Dr. Hunt's criticisms. — New York Med. Jour., March, 1879.

36. Consequences of Defective Vision. — Harper's Magazine, 1879, p. 456.

37. The Keratometer, a new instrument for measuring the curvature of the cornea.—Trans. of Amer. Ophthal. Society, 1880.

38. An improved operation for a new pupil after cataract operations. — Trans. of Amer. Ophthal. Soc., 1880, and New York Med. Record, Nov., 1880.

39. A case of death from croupous inflammation of the middle ear, with Acute Septomeningitis of the Convexity. — Amer. Jour. of Otology, April, 1881.

40. Conjunctivites from impure dust of the streets. — New York Med. Record, April 9, 1881.

41 and 42. Premature Delivery for the Prevention of Blindness. — Trans. of Amer. Ophthal. Soc., 1882, and New York Med. Jour., Jan. 20, 1883.

43. A Case of Osteotoma of the Conjunctiva. — Trans. Amer. Ophthal. Soc., 1882, and New York Med. Jour., Jan. 6, 1883.

44. An improved means of oblique illumination. — Trans. Amer. Ophthal. Soc., 1882, and New York Med. Record, Nov. 25, 1882.

45. A new nervous connection between Intracranial disease and choked disc. — New York Med. Jour., June, 1882.

46. Hypermetropia in the Public Schools. — Medical News, Jan. 28, 1882.

47. Dioptric, Dioptre, Dioptrie, or Dioptry. — New York Med. Jour., July 24, 1886, and Sept. 25, 1886.

48. Anomalous circulation in the eye.—(An undated pamphlet with colored plate) New York.

49. A Text-Book of Ophthalmoscopy. Vol. I. New York, 1886. Vol II. (In the press)

DR. JOSEPH AUB.

Dr. Joseph Aub died of chronic heart disease at Cincinnati, Ohio, in May, 1888, at the early age of forty-three. Although in bad health for several years previous to his death, he continued in active practice till February of this year, when he went South, hoping that a milder climate would have a beneficial effect on his disease. But finding his hope not realized he returned to his home to die. Dr. Aub was born and educated in Cincinnati, and graduated from the Medical College of Ohio in 1866. After that he went abroad and continued his studies in Berlin, Vienna, and London. On his return to this country he became resident surgeon to the New York Ophthalmic and Aural Institute, and continued in this position for three years. While here he published a paper entitled "Do the eyes perform any rotation on the optic axis in lateral inclination of the head," and another under the title "Contributions to the clinical history of injuries to the eyeball and its surroundings." In 1870 he was elected a member of this society. Returning to the city of his birth in 1872, he soon acquired a large and lucrative practice. He was appointed Professor of Ophthalmology to the Cincinnati Medical College, and held this position for five years. He was a member of the medical staff of the Cincinnati Hospital from 1872 to the time of his death. During this period he published the following papers: Ectropion, treated by transplantation of flaps without pedicle; a Case of Cyst of the ciliary body; Two Cases of Orbital Tumors. At the meeting of this society in 1884, he read a paper on the removal of foreign bodies from the vitreous by aid of the electro-magnet.

Industrious, devoted to study, and possessed of more than ordinary skill, Dr. Aub soon rose to a prominent position among the ophthalmologists of the country and at the time of his death had secured a place in the front rank of his profession. He was of a modest and amiable disposition, earnest in his friendship, and beloved by all who knew him well. His early death will be deeply deplored by the medical profession and by his many friends in all parts of the country.

A CASE OF PULSATING EXOPHTHALMOS, PROBABLY DUE TO RUPTURE OF THE CAROTID ARTERY IN THE CAVERNOUS SINUS.

BY F. BULLER, M.D.,

MONTREAL.

PULSATING EXOPHTHALMOS occurring spontaneously, or as a result of traumatism, is met with so seldom that every new case of this kind may still claim a place in the records of Ophthalmic Surgery; at the same time the pathology of this affection is now so well understood, in the light of cases already recorded, that little or nothing new in this direction remains for present observation. In the matter of treatment, however, there is no rule so firmly established but that much must be left to the judgment and discretion of the surgeon. *Injury to the carotid artery, in the cavernous sinus,* is no doubt much more common than the records of surgery seem to show. The case I am about to describe is the fourth I have myself seen, two of which have certainly not found their way into ophthalmic literature. The first occurred in a man forty-five years of age, who was thrown from his horse, striking his head violently on the frozen ground; a few weeks later pulsating exophthalmos gradually made its appearance and steadily augmented for several months. At this time there was enormous proptosis, and a large, soft, pulsating swelling over the inner end of the right eyebrow. Here, too, a harsh bruit could be heard with the stethoscope, and the patient was much troubled with a pulsating noise in the head. Ligature of the carotid was finally performed, but I believe the patient died a few weeks later from repeated and severe attacks of epistaxis. The second case has been placed on record by Walter Rivington. [Med. Chirurg. Transact., Vol. LVIII, page 183.]

The third was that of a young man who, in a boiler explosion, was struck over the left brow by a large fragment of iron, receiving a depressed fracture of the frontal bone. About four weeks later he came to me on account of defective vision of the left eye. I found the vision of this eye very much impaired and a pronounced atrophy of the optic nerve. He was under observation about ten days, during which time he had two slight attacks of epistaxis. A day or two later, just as he was leaving home to visit the hospital, he was suddenly seized with a violent epistaxis and bled to death in a few minutes. The post mortem showed a depressed fracture of the frontal bone, a fissure extending from this across the orbital roof, the optic foramen, and the body of the sphenoid directly beneath the cavernous sinus. Here an ulceration of the bone had taken place, and a direct communication was established between the vault of the left nostril and the left internal carotid, which had either been perforated by a spicule of bone at the time of the injury, or had subsequently become involved in the ulcerative process affecting the bone beneath it. In this case the aperture in the artery did not communicate with the cavernous sinus, hence there was no arterio-venous aneurism.

The fourth case, being the subject proper of this communication, came under my observation on the 24th of last May. About the middle of last February, W. G., aged twenty-eight, a robust and perfectly healthy young man, fell from a railway bridge, a distance of twenty feet, striking the right side of head and face on a piece of square timber. Was said to have been unconscious for about twenty-four hours. Both upper and lower jaw on the right side were supposed to have been fractured, but there are no signs of this lesion now discoverable. The right side of head and face was greatly swollen for several days, the right eye being closed for five days after the injury. During this time he suffered a good deal of pain in the injured parts. When the swelling subsided so that he could see again with both eyes there was diplopia, one object appearing higher than the other, and less distinct. As soon as he recovered consciousness he also became aware of a loud beating sound in the right ear, which has continued unabated ever since.

After a few days there was no more pain, but the eye remained moderately swollen and the diplopia was constantly present, the higher, false image, moving perceptibly up and down with each heart-beat.

During the succeeding eight or ten weeks there was no perceptible change in his condition, and he was able to follow his employment. About two weeks ago he again became troubled with pain, which was chiefly referred to the orbit and brow. With this there was a marked increase in the prominence of the eye and the swelling of the eyelids. Four days ago the pain became intense, so that he was unable to sleep at night. It was indeed the severity of the pain that finally induced him to give up his work and seek relief.

When I first saw him the appearance of the eye was strongly suggestive of orbital cellulitis. The lids had a tense, dusky, and swollen aspect, the eyeball was strongly protruded and stationary, while the swollen and œdematous ocular conjunctiva, extending far in advance of the palpebral fissure, was covered with a watery and mucous secretion. The conjunctiva generally was in a state of well-marked venous hyperæmia. The refractive media were unimpaired, and, when the upper lid was slightly raised, there was no difficulty in making a satisfactory ophthalmoscopic examination; this showed a somewhat œdematous condition of the retina, this structure being somewhat cloudy, with enlargement and tortuosity of its venous system. The optic nerve was not swollen, though its margins were slightly indistinct. In other respects the fundus oculi was perfectly normal. Visiôn was reduced to $\frac{20}{100}$. The pupil slightly dilated and fairly active, the visual field unimpaired. Displacement of the eye amounted to about $\frac{5}{10}''$ in an outward and $\frac{6}{10}''$ in a forward direction.

At the inner extremity of the eyebrow there was an ill-defined swelling, soft and elastic to the touch, and imparting a distinct thrill to the examining finger; just at this point, too, the stethoscope disclosed a harsh, rasping bruit, synchronous with the action of the heart. This sound was distinctly audible for a considerable distance upwards, and also outwards, as far as the zygoma. Pressure over the common carotid greatly

diminished its intensity. The eyeball could be pressed nearly into its proper place, but, in so doing, communicated to the fingers a strong pulsation. A pulsating movement of the eye was also readily seen in profile view.

Pressure over the carotid artery caused almost complete cessation of the pulsation, with softening and reduction of the swelling in the orbit. Under these circumstances there could be no reasonable doubt we had to do with an arterio-venous aneurism.

Dr. Shepherd, and several other members of the hospital staff, kindly examined the case with me, and it was decided to ligate the common carotid artery without unnecessary delay, the reasons for this decision being as follows. Pressure over the artery caused reduction of the protrusion of the eye, softening of the orbital swelling, and almost complete abolition of the pulsation without distress or inconvenience to the patient, who was moreover a healthy, vigorous man, and likely to bear the operation well. The recent increase in the swelling, attended as it was with severe pain and rapid deterioration of vision, threatened irreparable damage to the sight unless some speedy means of relief could be obtained. The man himself was exceedingly avérse to any form of treatment that did not promise an immediate cure. On the following day, May 25th, Dr. Shepherd ligated the common carotid in the upper part of its course with the usual antiseptic precautions. Two ligatures were placed around the artery and the vessel severed between them. The edges of the wound were brought together over a decalcified bone drainage-tube and an antiseptic dressing applied. The immediate effect of the operation on the orbital tumor was the same as had been temporarily obtained by digital compression; softening of the swelling, partial reposition of the eye, great diminution in the pulsation, and total cessation of the bruit.

Recovery from the anæsthetic was perfectly normal, without the slightest sign of impairment in the cerebral or nervous functions.

May 26th. Proptosis greatly diminished, the conjunctival œdema has nearly disappeared, vision greatly improved, and the

voluntary movements of the eyeball are tolerably free. There is no diplopia. Patient feels perfectly comfortable.

May 27th. Uninterrupted improvement.

May 28th. Feels quite well and "can see nicely" with the affected eye, $V = \frac{20}{40}$. States that since the operation there has been no noise in the ear. Proptosis now only slight in degree.

June 4th. Dressings removed from the neck to-day, the wound found to be completely healed, and the bone drainage-tube entirely absorbed. Can see as well as ever, $V = \frac{20}{20}$; movements of the eye appear to be entirely normal, the globe however is still somewhat displaced forwards.

June 12th. Patient thinks himself cured and declines to remain longer in hospital. Beyond a slight fullness of the orbit there is no indication of the recent orbital affection.

A CASE OF DOUBLE VASCULAR EXOPHTHALMOS. RECOVERY UNDER INTERMITTENT COMPRESSION OF THE RIGHT CAROTID ARTERY AND THE INTERNAL USE OF THE IODIDE OF POTASSIUM. COCAINE CONJUNCTIVITIS.

BY CHARLES J. KIPP, M.D.,
NEWARK, N. J.

Mrs. M., a stout but feeble lady, 76 years of age, consulted me for the first time on the 4th of August, 1886, for protrusion of the eyeballs, impairment of sight, and a very loud noise in her right ear and the right half of the head. I learned from her that she had always been in good health, and had good sight up to a year ago. About three months before her visit to me she fell down several steps and struck her head against the ground. She was stunned by the fall but did not become unconscious. No hemorrhage from nose, mouth, or ear followed the fall. As to the exact date of the beginning of the noise she is in doubt, but thinks that it was present some days before the fall; since then, it has, however, been much louder. The members of her house-

hold attribute it to the fall. Up to two weeks ago she heard the noise in both ears; now she hears it only in the right half of her head. The noise prevents her from sleeping and has made her very nervous. The protrusion of the eyes was first noticed after the fall.

On examination I found both eyes much protruded forwards and slightly downwards; the right perhaps a little more than the left. I estimated the protrusion of the right eye at 5 mm., that of the left at 4 mm. The upper lids were enlarged but not red. The mobility of both eyeballs was considerably impaired in all directions. The impairment was greatest in the right eye and most marked outwards. The external rectus muscle of this eye was paralyzed. At the upper and inner angle of the orbit there was a marked fullness but no tumor could be felt. There was no visible pulsation of the eyeballs and none was felt on pressing the eyeballs back into the socket with the hand. On placing my ear against her right temple I heard a loud blowing noise with every pulsation of the carotid, and a fainter continuous sound could also be heard at times. Further examination revealed that its bruit could be heard all over the anterior half of the head. I could also hear it below the right ear. On compressing the right carotid artery the bruit ceased entirely at once, but the protrusion of the eye remained unchanged. Compression of the left carotid artery considerably lessened the bruit but did not stop it. There was a very marked pulsation over the junction of the sternum with the right clavicle; no tremor could be felt, however. The heart seemed healthy.

The condition of the eyes was as follows: The ocular conjunctiva was quite œdematous and its veins were very broad and tortuous. The cornea was clear; the anterior chamber of normal dimensions; iris normal; pupil active. Lens contains numerous opaque stripes in both anterior and posterior cortical layer. The vitreous body contained many large floating opacities The optic disk was of a greyish color and flat. It was surrounded by a very broad white ring (atrophy of choroid). Retinal vessels of about normal size. Retina transparent everywhere. No other choroidal changes. Both eyes were in about the same condition. Right eye: Hm. 1.5 D; S $\frac{5}{18}$. Left eye: Hm. 1 D; S $\frac{5}{24}$.

As digital compression of the carotid artery produced no unpleasant head symptoms, I taught the patient and a member of the family how to control the right carotid and directed pressure to be made at short intervals for as long a period as she could bear it. At the same time I prescribed iodide of potassium in 5-grain doses, three times daily. For the hyperæmia of the conjunctiva I gave her a collyrium composed of boric acid and cocaine.

For a few weeks the compression of the right carotid was kept up by the patient for several hours daily, but after that time she applied it only when the noise in her head was unusually annoying, as the pressure gave her considerable pain. The iodide of potassium was increased to thirty grains daily.

Nine weeks after her first visit to me the exophthalmos was as great and the bruit as marked as then. The lids covered the eyes with difficulty. No pulsation of the eyeballs or of the swelling at the upper inner angle of the orbits has been felt at any time. The right eye was about in the condition first noted except that the opacity of the lens was greater. The left eye had, however, undergone a remarkable change. The conjunctiva was as before mentioned; the cornea was clear; *the anterior chamber was very shallow, the iris being almost in contact with the cornea.* The deeper part of the eye had not changed. T + 1 (?). Very careful and frequently repeated examination of the cornea failed to discover anything abnormal in this membrane. The collyrium of boric acid and cocaine had been used quite frequently of late. The irregular compression of the carotid was continued and the iodide of potassium was given as before mentioned.

Nine days later the anterior chamber of the left eye was again of normal depth. Tn. The ocular conjunctiva of this eye was much less swollen and the greatly enlarged and tortuous veins which traversed this membrane some weeks before had largely disappeared. The right eye showed no marked change, though its anterior chamber seemed more shallow than that of the left eye. The protrusion of the eyeballs and the bruit continued as last mentioned.

November 15th (three months and eleven days after first visit)

the patient joyfully informed me that the dreadful noise in her head and right ear had ceased two days previously, and auscultation failed to discover it in any part of the head and side of neck. Not a trace of the noise could be heard on the most searching examination. The left eye has now returned to its normal position, its mobility is unimpaired. The upper lid is still larger than it should be. The œdema and congestion of the ocular conjunctiva have almost entirely disappeared. Otherwise the eye is as before. The right eye is as much protruded as formerly, indeed it seems even more bulged than it was when I last saw the patient. The upper lid is enlarged and red. The ocular conjunctiva is very œdematous and intensely congested. A wreath of enlarged veins around the cornea is especially conspicuous. The anterior chamber is very shallow. No change in other parts. Tn. The globe does not pulsate, and no pulsation can be felt when eye is pressed into orbit, nor is there any swelling at the upper inner angle of orbit. The compression of the carotid was discontinued, but the iodide of potassium is to be continued.

December 29th. There has been no return of the bruit. The left eye is in normal position. Lids normal size. The eye is no longer injected. All enlarged vessels in conjunctiva have disappeared. The right eye has now almost returned to its normal position. It is still a little more prominent than the left eye, but not enough to be noted by casual observers. The swelling which formerly occupied the upper inner angle of orbits has entirely disappeared on left side. In its place is now occasionally felt a varicose vessel on the right side. The upper lid is no longer red and is of nearly normal dimensions. The ocular conjunctiva is no longer swollen and the enlarged vessels have disappeared, except a large one which protrudes from outer canthus nearly to margin of cornea and then dividing into two branches nearly encircles the cornea. The anterior chamber is of normal depth. The lens is much more opaque than formerly.

June 6, 1888. There has been no return of the bruit. The right eye is still slightly more prominent than the left which is in normal position. The mobility of both eyes is unimpaired in every direction. In the right eye, the large conjunctival

vessel above mentioned is still present, otherwise the ocular conjunctiva is normal. This eye is now blind from cataract. Perception and projection good. The left eye is normal in appearance. The lens is also cataractous. The patient comes to-day to get relief from itching and burning of lids. The lids are a little puffy. The ocular conjunctiva is slightly œdematous and of a dirty yellowish cast, and the limbus conjunctivæ is enlarged. On everting the lids the palpebral conjunctiva is found succulent and swollen and on its surface is studded with innumerable semi-transparent follicles. The condition is almost the same as that seen occasionally after the long continued use of atropine, except that the color of the conjunctiva is a yellowish red. The follicles are found on every part of the palpebral conjunctiva, but are most abundant, and of largest size on the retrotarsal folds. Having seen the same condition follow the long continued use of cocaine, I inquired as to what had been applied to the eyes, and learned that a solution of cocaine which I gave her many months before, had been continued in both eyes several times daily ever since. No other remedy had been used. I prescribed a collyium of zinc and stopped the use of the cocaine. Yesterday the follicles had greatly diminished in number and the swelling of the conjunctiva had almost disappeared.

REMARKS. In this case the symptoms were probably due to a spontaneous rupture of the right carotid artery in the cavernous sinus. This supposition offers to me at least the most satisfactory explanation of the bilateral exophthalmos and the aneurysmal bruit. The absence of pulsation of the eyeballs and of the swellings between the globes and the upper inner orbital wall, and the nearly normal size of the retinal veins were features also in several of the cases collected by Sattler in his exhaustive treatise on pulsating exophthalmos (Graefe und Saemisch Handbuch der gesammten Augenheilkunde. Band V.) That the intermittent compression of the carotid artery and the taking of small doses of the iodide of potassium contributed to the recovery, I have, of course, no means of proving, but who can prove that these measures were of no service? In view of the very small number of recoveries from this disease without ligation of the carotid artery (see Sattler, op. cit. page 922), I think I need

not apologize for occupying your time with the recital of a single case.

DISCUSSION.

DR. J. O. TANSLEY, New York. — Eight years ago I had a similar case. The patient was injured by being thrown from a carriage, striking the head over the left eye against a rock. When she regained consciousness, it was found that she could not see with that eye. I saw her six or seven months after the injury. The eye protruded considerably and there was a serous and pulsating tumor hanging down from the lower portion of the orbit, everting the lower lid and reaching as low as the ala of the nose. There was no motion of the eye except a trifle upward, inwards, and downward. There was no perception of light. She had consulted several parties who had recommended ligation of the carotid. I thought that this was unnecessary. I put her on large doses of the iodide and bromide of potassium and in about six weeks the pulsating tumor entirely disappeared, as also did the aneurismal bruit which had been present in the left temple.

DR. W. H. CARMALT, New Haven. — I think that Dr. Buller is to be congratulated on the result of his case. The same operation has frequently been performed with nothing like as satisfactory results.

I would ask why he made the diagnosis of arterio-venous aneurism rather than that of simple aneurism? Looking at the result and the notes of the case it seems to me that traumatic aneurism, pure and simple, would account for the symptoms.

DR. F. BULLER. — I would ask Dr. Carmalt, aneurism of what artery would explain this case? My reasons for not diagnosing aneurism of the ophthalmic artery were that arterio-venous aneurism following rupture of the carotid artery into the cavernous sinus is well known, while aneurism of the ophthalmic artery is clinically unknown. A case has been recorded where such an aneurism was found after death, but clinically I believe that it is unknown. There was in my case a history of injury closely preceding the development of the tumor. There was continuous trouble in the orbit which soon assumed an aneurismal character. There was great venous hyperæmia of the visible structures. There was a bruit and this was most pronounced in that position where examination of cases of arterio-venous aneurism of the orbit, verified by post-mortem examinations, show that it is most likely to occur, that is, over the inner extremity of the brow, where the veins are most largely developed. In that situation I felt a fluctuating tumor which could not be anything but venous in character.

For these reasons, I think that this was an arterio-venous aneurism and not a simple arterial aneurism.

DR. W. H. CARMALT. — I am well aware that aneurism of the ophthalmic artery is rare, but I was not aware that only one had been reported. I must say, however, that I do not see that the reasons advanced for this particular case disprove the possibility that it might have been a simple aneurism. The symptoms, while rendering the presumption of arterio-venous aneurism more likely than that of simple aneurism, are not sufficient to satisfy my mind that the case was not one of the latter condition. The results of the operation were much more favorable than we should expect in arterio-venous aneurism. I think that the true nature of this case can only be determined by autopsy, which I hope Dr. Buller will not have an opportunity of making for some time.

I recall a case of pulsating exophthalmos for which Mr. Bowman tied the common carotid artery. The patient died and at the autopsy nothing was found to account for the tumor or the pulsation (Roy. Ophth. Hosp. Rep., Vol. II, p. 6), and I think there are other cases reported where the autopsies did not reveal the expected arterio-venous aneurism, or indeed other satisfactory explanation of the pulsation. (Am. Jour. of Med. Science, 1876, Apr., p. 341.)

DR. F. BULLER. — I think that if Dr. Carmalt will study the literature of this subject, he will find that ligature of the common carotid for pulsating exophthalmos is not so unfavorable in its results as he seems to imagine. About fifty per cent., if I remember rightly, have terminated favorably as regards life and the restoration of vision.

DR. SAMUEL D. RISLEY, Philadelphia. — I would recall the attention of the Society to a case reported by Dr. George C. Harlan some years ago, in which a pulsating exophthalmos was cured by pressure on the carotid made by the patient. I have also reported a case of pulsating exophthalmos, the right eye being pressed forward, downward, and outward, the patient having been struck with a book over the right supraorbital ridge. The exophthalmos appeared some months after the injury, and at the time that I saw the patient, it was increasing. The pulsation had not been recognized either by the patient or by the physician. Placing my fingers on the ball, I felt a positive pulsation, and on auscultation an aneurismal bruit and thrill were plainly recognized over the temporal region. I placed my fingers over the carotid artery, pressing it back against the spinal column and continued the pressure until the patient became dizzy. While the pressure was applied the pulsation and the bruit ceased. During the consultation this pressure was

repeated at least three times. She was not conscious of any impairment of vision although she saw double. At a subsequent consultation vision was found to be $\frac{20}{XXX}$. Two weeks later, I again saw her, in consultation with Dr. Agnew of Philadelphia, and the president of this Society. There was at this time no pulsation and no bruit. Exploration of the orbit revealed a small tumor deep in the upper and inner part of the orbit, as near as could be determined of the size of a filbert. The opinion expressed was that in all probability it had been an aneurism of the orbit, and if so, the eye would gradually be replaced. The pressure which I had made had resulted in commencing clotting which had continued until the cure was effected. Some months later, I accidentally met her father, who stated that the eye had gone back into its place. He however ascribed the cure to the fact that he had taken her to some woman who had treated her with herbs. I call attention to this case as encouraging us to endeavor to treat these cases by repeated applications of pressure to the carotid artery. I do not know whether or not Dr. Buller tried pressure in his case. The experience of Dr. Harlan, Dr. Kipp, and myself encourages us to try to free the patients from these aneurisms of the orbit by pressure before resorting to so serious an operation as ligature of the carotid artery.

DR. B. ALEX. RANDALL, Philadelphia. — A few months ago, I met the patient to whom Dr. Risley has referred. There was still slight exophthalmos with downward deviation of the eye. The appearance of the eye indicated that there might be amaurosis, but there was no opportunity for an examination.

DR. F. BULLER, Montreal. — Pressure was of course thought of in my case. I should not have advised immediate resort to this operation if the patient had not almost declined to put himself under any form of treatment that was liable to be protracted. He insisted upon having the most rapid cure possible, for, as he said, his family depended on him, and he wanted to get home as soon as possible. This, together with the fact that he was a young and healthy man and suffered no inconvenience in having the carotid compressed, led me to at once resort to operation. My only regret is that he did not remain longer in the hospital, for there is always a possibility of the recurrence of the condition, if I am correct in supposing that there was a communication between the artery and the sinus.

NOTE. — Since then I have successfully extracted the cataract of this eye. The operation was done under cocaine, on October 5, 1888. As the tension of the eye seemed slightly increased, I made an iridectomy. Only slight bleeding followed this step. The wound healed without pain or injection, or swelling of ocular conjunctiva. The cocaine did not cause a relapse of the conjunctivitis. The patient returned home on October 19. The sight of this eye at that time was $\frac{5}{24}$. Since then it has improved to $\frac{5}{18}$.

A CONTRIBUTION TO THE SURGICAL TREATMENT OF MEMBRANOUS OPACITIES IN THE VITREOUS.

BY CHARLES STEDMAN BULL, M.D.,

NEW YORK.

PATHOLOGY teaches us that membranous and cord-like opacities in the vitreous humor are not usually freely movable or floating, owing to the continuity of the original septa, which is more or less completely preserved, and to the consistency of the intercellular substance of the vitreous humor contained within these septa. When, however, the processes of retrogressive metamorphosis and degeneration set in, and the intercellular substance becomes fluid, then these membranous opacities may become freely movable, unless they have formed adhesions to the retina, choroid, or optic nerve, and even then they may often be seen to wave and flutter with every motion of the eyeball. These membranes, no matter how delicate and cobweb-like they may be, resist all internal medication or local applications, even though persisted in for a long time, and such are the vitreous opacities which seem suitable for operation. *Von Græfe* was the first to suggest the possible advantage of surgical interference in such cases, and he gives in detail the history of a case of a young woman, aged nineteen, in whose left eye a moderately thick membrane extended all across the posterior part of the vitreous. Vision in this eye was reduced to counting fingers at eighteen inches, and the patient could read some words of Jaeger No. 20 with spherical $+\frac{1}{6}$. *Von Græfe* rotated the eyeball strongly inwards, and then plunged a keratonyxis needle through the sclera, between the external and inferior recti, just in front of the equatorial region, parallel to the plane of the iris and behind the lens, and divided the membrane in several places from before backwards. In a few days the patient could read Jaeger 8 with sph. $+\frac{1}{6}$, and, 3 weeks later, she could read Jaeger 3 with the naked eye. The ophthalmoscope

showed a retraction of the membrane from the center towards the periphery, and a subsequent absorption of its remains. Ten months after the operation not the slightest trace of opacity could be discovered in the vitreous, eccentric vision was perfectly normal, and central vision was almost normal. (See Archiv für Ophthalmologie, IX, 2, page 102, 1863.) In the experience of the writer, this operation has proved positively useful in some cases. There are some opacities of the vitreous, such as are seen after hemorrhages or inflammatory processes in the choroid, which are capable of undergoing retrogressive metamorphosis, and disappear wholly or in part. But we often meet with membranous opacities which resist all treatment, and not only materially affect the vision, but become still more dangerous through their traction on the retina at their points of adhesion. If we succeed in dividing such membranes, we not only gain a direct optical effect and improve the vision, but may also start up an absorptive process which may produce further contraction, and also by reducing the tension in the membrane, lessen the danger to the retina. If the cornea and lens be transparent, the position of these membranes may be located with tolerable accuracy. When in a choroidal process the infiltration encroaches on the region of the papilla, the opacity in the vitreous is almost certain to occur in its posterior part, in the form of threads, or patches, or membranes, which are often directly connected with the optic papilla by adhesions to the sheath of the central vessels. On the other hand, the farther forward the choroidal infiltration occurs, and the nearer to the ciliary processes, the more anterior are the opacities in the vitreous likely to be. Other things being equal, the posterior opacities are more easily reached by the needle or knife in the proposed operation, the less the danger of injuring the lens, and the more favorable are the results likely to be. (See Bergmeister, Archiv für Ophthalmologie, XX, 2, page 95, 1874.)

The writer has done this operation in seventeen cases of chronic membranous opacities in the vitreous, and presents the histories of these cases with the results obtained to the Society for its consideration. In some of the cases the ordinary discission or keratonyxis needle was employed; in others, a broader needle

with a double cutting edge; while in still others, where the membrane appeared to be tough and thick, a very slender cataract knife was the instrument selected. Cocaine was employed in all cases. Wherever the peculiarities of the case admitted, the point selected for the puncture was just in front of the equator of the eyeball, and just below the lower border of the external rectus muscle. In a few cases the puncture was made on the nasal side of the eyeball, just below the lower margin of the internal rectus muscle. The operation is a very brief one, and, where possible, was preceded and followed by a rapid ophthalmoscopic examination. There seems to be no danger of any loss of vitreous through the minute puncture made in the sclera, and almost as little probability of any annoying or disturbing hemorrhage. Care should be taken to make the puncture always posterior to the ciliary processes, and to avoid any undue pressure on the eyeball by the forceps, which are used in rotating the eye inwards or outwards, as the case may be. Little or no reaction follows, save in exceptional cases, and a protective bandage is needed for but two or three days.

I. Selah M., aged forty-five, first seen Oct. 12, 1885. Has always been myopic, but has never worn glasses. About eighteen months before the left eye had become inflamed without any apparent cause, though he has been rheumatic for years. The attack was accompanied by some pain and marked loss of vision, and the inflammatory symptoms did not subside until nearly four months had elapsed. Since then there has been no relapse, and vision has somewhat improved, but is still extremely defective. *Present condition:* *R. E.* $\frac{20}{100}$, with cyl.—D 2.50, axis 90° = $\frac{20}{30}$ + media clear—fundus normal, except a small conus on temporal side of disc. *L. E.* $\frac{3}{200}$, unimproved. Cornea clear, iris normal in color and reaction, lens transparent, except for some faint striæ at periphery. Under a dilated pupil there is seen a broad, thin membranous opacity, running from the nasal margin of the optic disc downward, forwards, and outwards to the lens. Both ends fixed, and the membrane becoming broader as it neared the lens. The rest of the vitreous was apparently clear, but the course of the membrane covered both the disk and the region of the macula. There were traces

of an old choroiditis, marked by patches of atrophy, some of them surrounded by a zone of pigment. A four per cent. solution of cocaine was instilled several times, and the eyeball was strongly adducted by means of a pair of forceps grasping the conjunctiva over the insertion of the internal rectus muscle. A keratonyxis needle was then plunged through the sclera just in front of the equator and below the external rectus muscle, and the membrane lacerated freely in several directions. The needle was then withdrawn, and an ophthalmoscopic examination was at once made, the pupil being under the influence of atropia. This showed that the membrane had been completely divided in two places and incompletely in one place. Atropia was instilled and the eye at once bandaged. The bandage was removed on the third day, and there being no sign of reaction, vision was tested on the fifth day and found to have risen to $\frac{10}{200}$ without a glass, and with sph.—D 2 ⌒ cyl—D 1 ax 90°, to $\frac{20}{70}$. The patient was then permitted to go out, and on the eighth day left for her home. Three months later, V = $\frac{20}{50}$+ with the above glasses, and an ophthalmoscopic examination showed that the divided ends of the membrane had retracted, leaving the optic disc and region of the macula exposed to view.

II. Miss Emma W., aged twenty-six, first seen Oct. 19, 1885. Ten months before the patient had been attacked by a serious inflammation in both eyes, only slightly painful in character, but attended by marked loss of vision. There was no external evidence of any ocular inflammation. The disease subsided in about two months, and the vision slightly improved in R. E., but there has been no change in the latter for at least six months. The patient gives a distinct syphilitic history. *Present condition. R. E.* V = $\frac{1}{100}$, cornea and aqueous humor clear, iris normal in color and reaction, lens transparent. A mass of filaments and membranes running like a mesh work across the vitreous, the fundus appearing indistinctly through the meshes. *L. E.* V = $\frac{20}{30}$—unimproved. Media clear, except for some small floating opacities in the vitreous. Iris normal. Small patches of old choroidal inflammation, mainly in equatorial region. This was considered an unfavorable case, but the operation was done on the right eye in the same posi-

tion as the first case, but with a broad needle with a double cutting edge. The ophthalmoscope showed that the membranous mesh-work had been incompletely divided in two places. Atropia and a bandage. Latter removed on third day; no reaction. V = $\frac{4}{100}$. Ophthalmoscope showed that the cut on the temporal side had gaped considerably. The vision was tested at the end of two weeks and found to have risen to $\frac{15}{200}$, beyond which it did not improve. Patient seen at the end of two months and the same condition existed.

III. Mrs. Mary R., aged thirty-five, first seen Oct. 26, 1885. Patient has been myopic since childhood, and four years ago had serious trouble with both eyes, particularly the left eye, accompanied by partial loss of vision and great intolerance of light, brought on probably by long-continued abuse of her eyes in doing fine embroidery. Since the attack subsided she has been careful in the use of her eyes, and there has been considerable improvement in the vision of the *right* eye, but the *left* eye has remained very defective in vision. No history of syphilis or rheumatism. There is no external evidence of disease in either eye, except a tendency to divergence of the *left eye*. *Present condition.* *R. E.* V = $\frac{10}{100}$: with sph.— D 6 = $\frac{20}{50}$. Some floating opacities in vitreous — general choroidal atrophy, most marked on temporal side of disc and downwards in infero-temporal quadrant. *L. E.* V = $\frac{6}{70}$: with sph. — D 6 = $\frac{20}{200}$. Numerous floating opacities in vitreous, and one band of thin membrane running from near the nasal margin of disc forwards and outwards to the ciliary region. Patches of choroidal atrophy all over fundus. Here the two-edged cutting needle was introduced on the nasal side of left eyeball in a corresponding position and the membranous band thoroughly divided as the ophthalmoscopic examination showed. There was no reaction and on fifth day V = $\frac{20}{70}$ with sph.— D 6. Two weeks later vision was the same, and remained unchanged for four months, since which time the patient has not been seen.

IV. Miss Emma F., aged twenty-two, first seen Nov. 30, 1885. Patient has always been myopic and has worn glasses for several years. Nine years before she had received a violent blow on the *left eye*, with immediate loss of vision, which was

followed by severe inflammation, swelling of the lids, and great pain in eye and head. As the inflammatory symptoms subsided, the vision began to be restored, but there has been no change for a number of years. *Present condition.* *R. E.* $V = \frac{20}{200}$: with sph. — D 2.50 $= \frac{20}{30}+$. The fundus presents the usual appearances of a myopic eye. *L. E.* $V = \frac{5}{100}$ unimproved. Pupil dilated and immovable. Lens slightly opaque at periphery. Floating opacities in the vitreous of varying size and shape, and a large, thick, vascularized membrane attached anteriorly to the outer ciliary region and posteriorly to the retina on the nasal side of the disc, and entirely concealing the latter and the region of the macula from observation. Here the membrane was so dense that the slender cataract knife was employed, being introduced on the temporal side of the left eye through the sclera, and the membrane divided in the vertical direction. It was felt to give under the knife, and the ophthalmoscope showed a small hemorrhage, probably from the divided vessels of the membrane, lying on the membrane and floating in the vitreous. Some reaction followed this operation, but on the tenth day the eye was quiet, and $V = \frac{10}{100}$. The ophthalmoscope showed a retraction of the nasal end of the membrane, while both ends moved freely as the eye moved. There was no further improvement in the vision, though the case was watched for nearly a year.

V. Mrs. M. N., aged sixty-three, first seen Nov. 30, 1885. Patient has been excessively myopic from childhood, but has never worn glasses. Has had repeated attacks of some form of deep inflammation in the eyes, accompanied by deterioration of vision, from which she recovered each time with a steady loss of vision. *Present condition.* *R. E.* $V = \frac{3}{200}$ unimproved. Iris sluggish in its movements. Periphery of lens cloudy. Several broad, fine membranes stretching across the vitreous apparently from side to side, floating with the movements of the eye, but fixed at either end, and permitting a very indistinct view of the fundus through their cobweb-like substance, where are signs of most extensive choroidal atrophy. Myopia of about D 16 with the ophthalmoscope. *L. E.* $V = \frac{3}{200}$, and the vitreous and fundus are in about the same condi-

tion as the right eye. As both eyes were about alike, the operation was done on temporal side of right eye with the discission needle, and the membrane extensively lacerated as the ophthalmoscope showed. No reaction. On the fifth day V=$\frac{3}{200}$, but with sph.—D 14 it rose to $\frac{10}{200}$, and continued slowly to improve until at the end of the second month it was $\frac{20}{200}$, the membrane having retracted on both sides, leaving a free vent.

VI. Mr. James C. R., aged forty-two, first seen Jan. 25, 1886. Four years ago he had a violent fall, striking on the right side of the forehead and supra-orbital region. There was extensive laceration of the soft parts and the bone was fractured. The vision of the right eye was affected at once and grew steadily worse, so that in the course of a few weeks it was reduced to perception of light. Since then it has somewhat improved. *Present condition. R. E.* V=$\frac{3}{200}$—cornea clear, iris fluttering, and pupil immovable. Lens in place and transparent. Vitreous crossed by a dense, broad membrane, running from the outer margin of disc downwards, forwards, and outwards. Projection good in every direction. Pupil easily dilated by atropia. *L. E.* V=$\frac{20}{20}$, media clear and fundus normal. Here the slender cataract-knife was plunged through the sclera on the nasal side below the internal rectus muscle, and a long cut made through the membrane, but the ophthalmoscope showed no gaping of the edges. Absolutely no reaction. On the sixth day there was a decided gape in the membrane and V=$\frac{20}{200}$, the hole being oval in shape. There was no further improvement. This patient was seen in May, 1888, and the condition of the eye remained the same.

VII. Mr. Wm. B., aged forty-five, first seen May 3, 1886. Patient syphilitic. Has had repeated attacks of iritis in both eyes, and for more than a year the vision in the *right eye* has been steadily failing, and for several months has been useless. *Present condition. R. E.* V=perception of light. Field wanting in supero-nasal quadrant. Cornea clear. Iris discolored and adherent to capsule of lens. Pupil irregular and immovable, and only partially dilated by repeated instillations of atropia. Lens apparently transparent. Filamentous membrane stretching across vitreous nearly in horizontal plane. Tension—1.

L. E. V = $\frac{20}{30}$+. Cornea clear, iris discolored and adherent to lens. Lens and vitreous apparently clear. A detachment of the retina was supposed to exist in the infero-temporal region, probably directly connected with the membrane. This gentleman was told of the bad outlook and that the chances of improvement were slight, while serious inflammation might follow the operation. He decided to risk it, and the small discission needle was plunged through the outer aspect of the sclera, and a single sweep from above downwards given to it, and it was then withdrawn. Somewhat violent reaction followed, which yielded to atropia, hot water, and bandage, but no ophthalmoscopic examination was made for three weeks. No change was discoverable in the membrane, owing to the adherent condition of the pupil, but the patient could distinguish the movements of the hand, and claimed that he noticed considerable improvement in the vision. He urged another attempt, but the danger of reaction was considered too great. The defect in the field continued the same.

VIII. Mrs. E. H., aged sixty-four, first seen May 10, 1886. Patient had never had any trouble with her eyes till about eighteen months ago, since which time the vision in both eyes had gradually failed, and she now complains of seeing everything through a mesh-work or veil. *Present condition. R. E.* V = $\frac{20}{30}$ unimproved. Ht. = D I. Cornea and lens normal, except at periphery of latter, where there are numerous peripheral opacities. Delicate cobweb-membrane extending across the vitreous from the nasal side downwards and outwards. *L. E.* V = $\frac{20}{30}$ unimproved — Ht. about D 1.75. Cornea and iris normal. Peripheral opacities in lens. Delicate cobweb-membrane in vitreous, not quite so extensive as in *right eye.* In this case an attempt was made to lacerate the membrane with the discission-needle in each eye separately, but although it was readily torn, there was no gaping of the holes in the right eye. In the left eye one of the lacerations gaped wide, but there was no improvement in the vision. The needle was introduced through the sclera on the temporal side in each eye. There was absolutely no reaction in either eye following the operation.

IX. D. C., aged fifty, first seen Nov. 28, 1887. Twenty-five

years ago this patient contracted syphilis, and had, among other constitutional symptoms, an inflammation in both eyes, beginning in the *left* eye, which ended in total blindness. The *right* eye was much less seriously affected. Both eyes remained quiet until six years ago, when the left became inflamed again. This attack subsided, and there was no further trouble till Sept., 1887, when the *left eye* became again inflamed and still remains so. *Present condition. R. E.* $V = \frac{20}{50}$ — cornea clear. Iris discolored but freely movable. Lens clear. Large membraniform opacity in the vitreous, attached by a broad base to the nasal margin of the optic disc. *L. E.* $V = 0$. · Tension +2. Iridocyclitis. Cornea cloudy. Lens opaque and lying in the anterior chamber. Iris dilated *ad maximum* and adherent to the lens. The left eye was enucleated as a necessary preliminary to the operation on the right eye. Two weeks later the needle with double cutting edge was introduced through the temporal side of the sclera, and an attempt was made to cut across the entire membrane, which, however, was only partially successful, as the membrane seemed to bend before the instrument. Some reaction followed and it was feared that the vision might suffer, but on the sixth day the eye had become entirely quiet and a laceration was discovered in the membrane which had already gaped a little. On the twelfth day $V = \frac{20}{40}$ and even improved a little beyond this in the course of the next few weeks.

X. Miss A. L., aged thirty-two, first seen Dec. 5, 1887. Two years ago the patient suddenly noticed a large black spot before the *left eye*, which rapidly obscured her vision. This has remained ever since, with alternate conditions of improved and deteriorated vision. Her sight is always worse at the menstrual epoch. *Present condition. R. E.* $V = \frac{20}{20}$. Media clear and fundus perfectly normal. *L. E.* $V = \frac{20}{50}$. Cornea, iris, and lens normal. At posterior pole there are spots of choroidal exudation, and stretching across the vitreous in every direction are numerous fine filamentous opacities, fixed at the ends but waving with the motions of the eye. The keratonyxis needle was plunged through the sclera at the point above indicated on the outer aspect of the eye, and the fine filamentous opacities

swept in every direction by the needle. An ophthalmoscopic examination immediately afterwards showed that apparently nothing had been accomplished, the filaments bending before the needle, instead of being torn. There was no reaction, and no improvement in vision.

XI. Mr. Geo. G., aged thirty-five, first seen Dec. 5, 1887. The patient has had defective vision in the *left* eye for several years, which came suddenly without any known cause, but which was probably a hemorrhage into the vitreous. Thinks the vision of the *right eye* has failed of late. Had a chancre nine years ago. *Present condition.* *R. E.* $V = \frac{20}{30}$+unimproved. Cornea, iris, and lens clear. Refraction hypermetropic. Faint dust-like opacities in the vitreous. Fundus apparently normal. *L. E.* $V = \frac{10}{200}$ unimproved. Cornea, iris, and lens normal. Broad but very delicate membrane in the vitreous, fixed but wavy, obscuring slightly the entire fundus. Remains of an old chorio-retinitis. The double-edged broad needle was introduced in the position of choice on the outer aspect of the eyeball, and a single sweep of the needle made from above downwards. There was no reaction from the operation, and on the eighth day the ophthalmoscope showed that the membrane had been entirely divided, and the ends had retracted on either side almost out of sight. $V = \frac{20}{40}$ and has remained so, the patient having been seen within the month, and the vitreous found almost clear.

XII. Mr. A. E., aged forty-four, first seen Jan. 16, 1888. Patient has had defective vision in *left eye* for five years, dating from a sudden attack of almost complete loss of sight. Three weeks ago he again had a sudden obscuration of vision in the *left eye*, which during the past week has begun to improve. *Present condition.* *R. E.* $V = \frac{20}{20}$. Media and fundus perfectly normal. *L. E.* $V = \frac{1}{200}$. Cornea, iris, and lens normal. A membrane, pierced by numerous holes, stretches across the posterior part of the vitreous, adherent posteriorly to the margin of the optic disk; and, floating in the vitreous, and at times obscuring nearly the entire fundus, are several blood clots. This patient has grave cardiac disease, both hypertrophic and valvular. It was thought best to wait until the recent hemor-

rhage had at least been partly absorbed. On February 14th the slender knife was introduced in the position of choice and several attempts made to lacerate the membrane in various directions. A somewhat violent reaction followed, and it was not until the fourteenth day that an ophthalmoscopic examination was made. There were still some blood-clots floating in the vitreous, but quite a large laceration was seen in the membrane and the vision was found to have risen to $\frac{20}{100}$. This slowly improved as absorption went on, and at the end of three months the vitreous was very much clearer and $V = \frac{20}{70} +$.

XIII. Mr. Wm. S., aged thirty, first seen Jan. 30, 1888. This patient had a chancre in July, 1886, and after numerous constitutional lesions, the *left eye* became affected in April, 1887, the attack having evidently been a choroiditis. The vision was markedly affected, but, since the subsidence of the attack, it has slowly improved. *Present condition. R. E.* $V = \frac{20}{20}$. Media and fundus perfectly normal. *L. E.* $V = \frac{20}{100}$. Cornea, iris, and lens normal. Some minute floating opacities in the vitreous, and a single strand of rather dense tissue extends directly from the temporal margin of the optic disc forwards and outwards towards the periphery. As the narrow membrane seemed to be rather thick and dense, it was deemed wise to employ the slender cataract-knife. This was introduced at the usual point in the outer side of the eyeball, and passed slightly upwards and then brought downwards and withdrawn with a single cut. The ophthalmoscope was immediately used and the membrane was seen to have been completely divided. No reaction followed, but the vision was not tested till the eighth day when it was found to have risen to $\frac{20}{40}$. An examination of the fundus showed that marked retraction had taken place in the membrane, especially in the peripheral fragment, which had almost disappeared from view. Subsequently the vision improved slightly to $\frac{20}{40} +$.

XIV. Mrs. M. H., aged twenty-four, first seen Feb. 21, 1888. This patient has both cardiac and pulmonary disease. Was confined with her first child fourteen months ago, and almost immediately afterwards had a sudden attack of loss of vision in the left eye. From this she slowly recovered, but this eye

never quite regained its normal vision. Early in January, 1888, she had a similar attack in the right eye, while nursing her child, from which in a week or two she began to recover. On February 14th she again had an attack in the right eye. This patient has no sign of any renal disease. *Present condition.* *R. E.* V = fingers at four feet. Cornea, iris, and lens normal. Dense membranous opacities, with wide meshes, stretching all across the fundus and obscuring every detail, and numerous large blood-clots fixed on the membrane, or floating in the vitreous. *L. E.* V = $\frac{20}{70}$. Cornea, iris, and lens normal. Broad, cobweb-like membrane in the vitreous, fixed posteriorly some distance below the margin of the disc, and attached anteriorly by a much broader base to the equatorial region upward and outwards. I regarded the right eye as being in an almost hopeless condition, but decided to operate on it before attempting anything on the left eye. Owing to the density of the membrane, the slender knife was used, introduced in the usual position through the sclera on the temporal side, and attempts were made to thoroughly divide the membrane in several places. The attempts were partially successful, but violent reaction followed the operation, accompanied by fresh hemorrhage into the vitreous, which reduced the vision to perception of light. This subsequently improved to about what it was before the operation, and the ophthalmoscope showed several holes in the membrane. One month later the left eye was operated upon at a corresponding point in the sclera, the keratonyxis needle being used, and the cobweb membrane was thoroughly lacerated. Vision improved almost immediately to $\frac{20}{40}$ +, the central retraction of the membrane being considerable. This patient is still under observation.

XV. Mrs. W. L., aged sixty, first seen March 14, 1888. This patient has had gradually failing vision in both eyes, without any decided or sudden inflammatory attacks, for more than two years. There is irregularity of the heart's action but no very decided organic lesion. *Present condition.* *R. E.* V = $\frac{20}{200}$. Well-marked arcus senilis. Faint opacities at periphery of lens. Delicate band of connective tissue extending across the vitreous from above and outwards, downwards, and inwards. Signs of

old choroiditis. *L. E.* V = fingers at two feet. Same conditions in cornea and lens as in the other eye. Broad, rather thick, irregularly shaped membrane in the vitreous, extending from near the nasal margin of the optic disc upwards and outwards to the equator. In this patient the operation was done on both eyes at the same time, as her stay in the city was limited. On the right eye the keratonyxis needle was used, while on the left eye the double-edged cutting needle was employed, the puncture being at a corresponding point on the outer aspect of each eye. There was some reaction following the operation on the left eye, which, however, subsided within the first week. An ophthalmoscopic examination showed complete division of the delicate membrane in the right eye with marked retraction of the divided ends, and a large hole through the thicker membrane in the left eye. One month after the operation an examination showed in the *R. E.* V = $\frac{20}{50}$, and in the *L. E.* V = $\frac{20}{200}$.

Of the seventeen operations done on fifteen patients, fourteen gave decided improvement in the vision and three proved failures. In no case was there any loss of vision from the operation. It seems proper to conclude that the operation is a suitable one in certain cases, and is justified by the results obtained. It would seem wise to wait in any case until all inflammatory symptoms have long subsided, before attempting to divide the resulting obstructing membranes, no matter whether caused by hemorrhages into the vitreous, or by a hyalitis, the result of choroiditis. The eye should be absolutely free from all irritation before attempting any such surgical interference.

DISCUSSION.

DR. GEORGE STRAWBRIDGE, PHILA.—I understand that the operation was performed without the use of the ophthalmoscope during the operation. I think that the operator was right in not placing much reliance on the ophthalmoscope during the operation. It is also very satisfactory to know that the operation is so free from risk.

DR. W. S. DENNETT, N. Y.—Ten years ago I had an operation to do near the fundus in which I used my ophthalmoscope as a head mirror with much satisfaction. The patient was not etherized and I had no difficulty in seeing. If I had another such operation to perform I should try the same plan.

DR. SAMUEL THEOBALD, BALTIMORE.—I would ask whether or not, in these cases, antiseptic precautions were employed? I should also like to know whether Dr. Bull found it possible to cut through the membranes by a sawing motion, or did he simply break them with a wide sweep of the knife?

DR. C. S. BULL, N. Y.—Modified antisepsis was used in all of these cases. The eye and face were carefully washed with a solution of the bichloride of mercury before the operation. In the eye, a 1 : 5,000 was employed, and on the face a 1 : 2,000 was used. The instruments were thoroughly sterilized. I was afraid to attempt any sawing motion lest it would enlarge the external wound and permit escape of the vitreous or lead to hemorrhage.

DR. W. F. MITTENDORF, N. Y.—I think that vascularity of the vitreous membrane should speak against operations of this kind. Vascularity, even if no signs of inflammation are present, would, I think, indicate a fatal prognosis. I have in mind several cases where membranes with great vascularity almost entirely disappeared in the course of one or two years, leaving useful vision. In these cases, the danger of hemorrhage which might interfere with the success of the operation, must speak against it.

DR. T. Y. SUTPHEN, NEWARK.—I might say in this connection that during the past year I have performed three operations for puncture of the retina, under antisepsis, the details of which I shall give later. In these operations there was no reaction whatever, and therefore would sustain the opinion that there was comparative safety in such a procedure as Dr. Bull advises.

AN ANALYSIS OF THE REFRACTION OF 576 HEALTHY HUMAN CORNEÆ EXAMINED WITH THE OPHTHALMOMETER OF JAVAL AND SCHIÖTZ.

By SWAN M. BURNETT,

WASHINGTON, D. C.

THE 576 eyes, an analysis of whose refraction is herewith presented, belonged to 301 persons whom I have examined in my private practice in a little over a year. They can, in no way, be regarded as selected cases since they are taken as they were recorded in my case book and represent very fairly, I think, the eyes that are brought to the oculist for examination. No eye was thus examined in which there was not some reason to suspect a refractive anomaly, and no eye is here recorded in which the cornea was not in a healthy condition. Those corneæ which were changed by inflammation or trauma (including operation) are excluded and reserved for future consideration.

The refraction of the cornea as determined by Javal and Schiötz's ophthalmometer is expressed in dioptries and fractions. I think this is preferable to the use of the radius of corneal curvature, since to the majority, who are not professed physiologists, the dioptry will convey a much more intelligible idea. We are all accustomed to the dioptry and it has a distinct and fixed value with us, whereas so many millimetres and hundredths of radius of curvature have a definite meaning to only a very limited number. For those however who may wish to know, for comparison or other reasons, the value of dioptries in corneal radius, I subjoin a table of the radii of corneal curvature corresponding to the dioptries, calculated from the data given by Javal in the construction of his instrument.

DIOPTRIES	RADIUS (*r*)	DIOPTRIES	RADIUS (*r*)
35	9.62^{mm}	43	7.83^{mm}
36	9.36	44	7.65
37	9.10	45	7.48
38	8.86	46	7.32
39	8.64	47	7.17
40	8.42	48	7.02
41	8.22	49	6.87
42	8.02	50	6.74

This table, it will be observed, differs from that published in Javal's first article in the *Ann. d'Ocul.*, Juil.–Auot., 1881. There he took 1.35 as the index of refraction of the cornea, whereas it should be 1.337, and in the construction of his later instruments it has been so accepted by him, though he has not, I believe, published any table based on the new data.

Assuming then that these data are correct and that we can measure the refracting power of the cornea to within 0.25 D, we are able to distinguish a difference in radius of corneal curvature from .03^{mm} to .06^{mm}, which is quite accurate enough for ordinary practical purposes.

For the object for which these examinations were made I did not think it necessary to consider less values than 0.25 D. It is possible however to obtain by means of the instrument, with a good light and expenditure of sufficient time and care, values approximating 0.10 D.

The corneæ thus examined, have been classified as belonging to eyes that were found upon examination to belong to the category of emmetropia, myopia, hypermetropia, simple myopic or hypermetropic astigmatism, compound myopic or hypermetropic astigmatism, or mixed astigmatism.

The corneal refraction was found to be the same, within 0.25 D, in both eyes, in 110 cases, and this irrespective of their general refractive condition.

The horizontal meridian (within 5°) was found to be the least refracting in 420 eyes (astigmatism according to the rule).

The vertical meridian (within 5°) was the least refracting in 20 eyes (astigmatism contrary to the rule).

In the remaining 88 eyes the meridians were oblique.

In 58 eyes there was a difference in the two meridians of less than 0.25 D.

EMMETROPIA.

In 101 eyes emmetropia was found on an examination of the general refraction. The greatest refraction in the least refracting meridian of the cornea was 47 D (with a focus of 24.02^{mm} and a radius of 7.17^{mm}); the weakest refraction in this meridian was 39 D (with a focus of 25.64^{mm} and a radius of 8.64^{mm}), being a difference of 8 D. The largest number, 30, had a refraction in the least refracting, or common meridian of from 44 to 45 D,[1] the next largest, 25, from 43 to 44 D; 20 had from 42 to 43 D. In all the cases of emmetropia the meridian of greatest refraction was the vertical. In those emmetropic eyes, 70 in number, which had astigmatic corneæ, the difference in the refraction of the two corneal meridians ranged from 0.25 D to 1.25 D. Of these there was a difference of 1.25 D in three, a difference of 1 D in 1, of 0.75 D in 6, of 0.5 D in 20, and of 0.25 D in 41. In 31 eyes there was an astigmatism less than 0.25 D.

BOSTON MEDICAL LIBRARY ASS'N. MAR 5 1889

SIMPLE MYOPIA.

In 55 eyes there was simple myopia or with an astigmatism less than 0.25 D. The strongest of the least refracting or the common meridian was 47.25 D; the weakest was 39 D, a difference of 8.25 D. The least refracting cornea had a M = 11; the strongest refracting cornea had a M = 5. The highest degree of myopia determined was 12 D with a corneal refraction of 43 D. There was corneal astigmatism greater than 0.25 D present in all but 17 eyes. In these 38 astigmatic corneæ there was a difference of 1 D in the two meridians in 8 eyes, a difference of 1.25 D in one. In 6 eyes the axis of the corneal astigmatism was oblique, in the others it was horizontal or vertical.

SIMPLE HYPERMETROPIA.

Simple hypermetropia, or with an astigmatism less than 0.25 D, was found in 59 eyes.

[1] With a radius of curvature of from 7.65^{mm} to 7.48^{mm}. The radius of normal cornea accepted by Reich and Stammeshaus is 7.829^{mm}, which would correspond closely to 43 D (7.83^{mm}).

The weakest least refracting or common meridian was 40.5 D (in two eyes with a determined H of 3 D and 1 D, respectively). The strongest refraction in this meridian was 46 D with a determined H = 2 D. The highest degree of H was 9 D with a corneal refraction of 43 D. In 6 eyes the cornea was non-astigmatic or astigmatic less than 0.25 D. In 4 eyes the corneal astigmatism amounted to 1 D. In one case only was the vertical meridian the weaker, by 0.25 D. In all the others the horizontal was the weaker meridian.

SIMPLE MYOPIC ASTIGMATISM.

Simple myopic astigmatism was found in 140 eyes. Of these 20 eyes had the vertical meridian weakest (contrary to the rule) and among these there was a corresponding corneal astigmatism against the rule in 9. In 66 eyes the horizontal meridian was the weakest, in the others (54) it was oblique.

In 4 eyes the general astigmatism was greater than the corneal. In 11 it was less.

The greatest corneal astigmatism was 7 D with a general astigmatism of 4 D, axis the same in both. The greatest general astigmatism was 6 D with a corneal astigmatism of 5 D, and a difference in axis of 40°.

In 14 eyes the difference in axis of the corneal astigmatism and the prescribed glasses was greater than 5°.

The weakest meridian of least refraction was 39 D, the strongest meridian of least refraction was 47 D.

SIMPLE HYPERMETROPIC ASTIGMATISM.

In 96 eyes there was simple hypermetropic astigmatism.

In 2 eyes the corneal astigmatism was less than the general. In 4 eyes it was greater. In 58 eyes the astigmatism was according to the rule, and in 11 it was against it. Among these latter, the corneal astigmatism was the same as the general in 2 cases, it was the opposite in 4, and in 5 there was no corneal astigmatism. The greatest astigmatism was 6 D, with a corresponding corneal astigmatism, and a corneal refraction of 43 D in the weakest meridian (horizontal). The axis of the corneal

astigmatism and of the prescribed glasses corresponded, to within 5°, in all but 9 cases.

COMPOUND MYOPIC ASTIGMATISM.

There was compound myopic astigmatism in 63 eyes.

The highest astigmatism was 3.5 D, with an average of less than 1 D. In 20 eyes it was determined by glasses to be according to the rule, in 10 contrary to the rule. 27 corneæ had an astigmatism according to the rule, 4 contrary to the rule, and 7 had an astigmatism less than 0.25 D. In all but 7 eyes the corneal and general astigmatism corresponded to within 0.5 D, and in the 10 eyes with astigmatism against the rule there was a corresponding corneal astigmatism against the rule in 5.

In 44 eyes the corneal and general meridians were the same to within 5°. The weakest corneal meridian was 38.5 D at 45°, with M = 8 ⌒ — 1.45°. The strongest weak meridian was 46.5 D with M = 1 ⌒ — 1.90.

COMPOUND HYPERMETROPIC ASTIGMATISM.

Fifty-five eyes were affected with compound hypermetropic astigmatism.

The weakest corneal meridian was 35 D, 75°, 165°.38 D, with H = 1.25 ⌒ + 3.590°. The highest corneal refraction at horizontal meridian (180°) was 47 D, 90°, 47.75 with H = 1.5 ⌒ + 0.5 180°.

The highest degree of general astigmatism was 5 D, with corneal refraction of 180°, 41 D, 90°, 41¾ D. The highest degree of corneal astigmatism was 3 D (in three cases) with a general astigmatism corresponding in degree and axis.

In 31 eyes the corneal and general astigmatic meridians corresponded to within 5°. Corneal and general astigmatism corresponded in all but 4 eyes, in 2 of which the corneal astigmatism was in excess.

In 37 eyes the corneal astigmatism was according to the rule, 4 against the rule, and one had no corneal astigmatism.

In 24 eyes the general astigmatism was according to the rule, in 4 it was against and in two of these latter the corneal was also against it.

MIXED ASTIGMATISM.

There were 8 eyes affected with mixed astigmatism.

The highest degree of astigmatism was 6 D, hypermetropic refraction predominating. In 4 cases the astigmatism was according to the rule; in none, against. The weakest refraction in the weak meridian was 38.75 D, 180°, 44.75, 90°, with a general refraction — 1 180° ⌒ + 5 90°; the strongest weak meridian was 44 D, 75°, 46¼, 165°, with correction of + 1 ⌒ — 2.5 155°. The corneal and general astigmatism corresponded to within 0.5 D in 4 cases. The corneal was less than the general astigmatism in 2, greater in 1. The corneal and general astigmatic meridians corresponded to within 5° in 5 eyes.

In 42 eyes the general astigmatism was against the rule, with a corresponding corneal astigmatism against the rule in 18 eyes. Of the 576 eyes examined, 182 belonged to the female *sex* and 119 to the male. The *ages* ranged from 6 to 65 years.

In one girl of 6 years the weakest corneal meridian was 105°, 43 D, 15°, 45.5 D, with a correcting glass of + 3.5 90. In one of 8 years 180°, 48 D, 90°, 49 D, emmetropia was found. In the two of 65 years one had 180°, 43.75 D, 90°, 45 D, with M = 6 D; the other had 180°, 42 D, 90°, 43¾ with + 1.5 90° as the correcting glass.

A MYDRIATIC,

it is noted, was used in 62 eyes. In these the astigmatism, as determined by glasses, coincided with the corneal astigmatism, to within 0.5 D, in all but 19 eyes. In these 19, the corneal astigmatism was the greater in 11, and the less in 8.

In 13 eyes the axis of the corneal astigmatism and of the prescribed glasses did not correspond by 5°.

It should be stated that these differences, in excess of what we found in eyes whose accommodation had not been paralyzed, cannot be considered as due solely to the effect of the mydriatic. The mydriatic was used only in cases where there was such a discrepancy in the findings by the various methods of examination — the ophthalmoscope, skiascopy, glasses, and the keratometer — as to lead to a suspicion of a lenticular astigmatism. Where the results of all or of a majority of the methods agreed

substantially, a mydriatic was not used, or was deferred until the glasses ordered had been tried.

REMARKS.

It will be seen from the above analysis, in the first place, that the corneal is by no means an index to the general refraction of the eye. In myopia it may be weak and in hypermetropia it may be strong; in fact, the refraction of the cornea may vary as much as 8 D in the same general refractive condition. This goes to substantiate the belief that has been held for a long time that in the vast majority of cases, ametropia is due to an alteration in the antero-posterior axis of the eye rather than to any deviation from an assumed standard of refraction in its optical apparatus.

Even in emmetropia the cornea has no standard uniform refraction. It varies from 39 D to 47 D, the average ranging from 43 D to 45 D.

On the other hand, the general astigmatism is, as a rule, expressed by the corneal, both as to its degree and the direction of the faulty meridian.

In 462 eyes affected with astigmatism of various degrees and forms, in only 36 did the corneal and general astigmatism differ by more than 0.5 D; while the axis of the faulty meridian and of the prescribed glasses corresponded to within 5° in all but 69 eyes.

There can be no doubt, however, regarding the existence of an astigmatism not corneal. This is shown not only by these cases, but also by those of emmetropia, hypermetropia, and myopia, in which there was a corneal astigmatism, and which must have been neutralized by an astigmatism of some other portion of the optical apparatus of the same degree but opposite character. This astigmatism has usually been referred to the lens, and has been deemed to depend upon a partial contraction of the ciliary muscle. In a number of instances this would seem to be true, but our statistics show that after the influence of the ciliary muscle has been eliminated by the action of a mydriotic there still remains a discrepancy between the corneal and general astigmatism in quite a number of cases. This, I think,

can be referred most properly to an oblique position of the lens. This, as is well known, was the original cause of astigmatism assigned by Young, and I believe it is a much more frequent factor in the production of lenticular astigmatism than we have been wont to think it. It will be observed, also, that but few corneæ are devoid of some amount of astigmatism. In only 68 out of the 576 was there no astigmatism or an astigmatism less than 0.25 D. It is also to be noted that corneal astigmatism is nearly always according to the rule — the vertical being the stronger meridian. In all the astigmatic corneæ the vertical meridian was the least refracting in 20, while in 440 it was according to the rule. It will be noticed, too, that in those cases of general astigmatism against the rule, in about one-half there was no corresponding corneal astigmatism against the rule. This would appear to substantiate Javal's dictum that astigmatism according to the rule is mainly corneal, while astigmatism against the rule is more apt to be lenticular. The other portion of this dictum, that the obliquity of the general astigmatic meridian is due to a decentering of the lens and cornea, I have not verified by any measurements of my own. The explanation, however, is a very plausible one.

In this same connection it may be of some interest to note that simple astigmatism preponderates quite largely over the compound forms and that the highest degrees of astigmatism are also found in the simple forms. Simple myopic astigmatism particularly is largely in excess of the compound form, and the average degree of astigmatism is much higher. These facts, it seems to me, should raise a doubt as to the importance that has been attached in some quarters to astigmatism as a factor in the development of myopia. If astigmatism were at all prominent in the production of myopia we should expect to find compound myopic astigmatism very greatly predominating over simple myopia. As a matter of fact, however, we find 55 cases of simple myopia to 63 of compound myopic astigmatism.

It further appears from a study of these statistics that astigmatism is, in the vast majority of cases, corneal, and this being so it is most important that we be able to determine it readily and accurately. My experience with the instrument of Javal

and Schiötz leads me to believe that in that ingeniously constructed apparatus we have a means by which this very desirable end can be accomplished with the least possible expenditure of time.

DISCUSSION.

DR. CARL KOLLER, New York. — Dr. Burnett stated that the refraction of the cornea had nothing to do with the refraction of the eye. I can confirm this. I have used this instrument and have measured many eyes with that of Helmholtz. I might use an illustration of Javal, that a mouse and an elephant may have the same refraction. We may have large eyes and small eyes but the refraction depends entirely upon the relation of the axis to the radius of curvature.

DR. HENRY D. NOYES, New York. — I have used the ophthalmometer of Javal and Schiötz with great satisfaction. I have, however, not preserved such data as Dr. Burnett has given us. It has been my habit to employ the ophthalmometer in every case where it was necessary to inquire into the state of the refraction. In a general way, I may say as follows: that the evidence of the ophthalmometer without the use of atropine has in the immense majority of cases corresponded with the evidence of the trial case. You obtain the amount of astigmatism and in a general way the axis of astigmatism. I say in a general way because sometimes discrepancies have arisen. Seldom have they been great, but sometimes they have amounted to as much as 15° or 20°.

Another thing that I have noticed in regard to the axis is that once in awhile the meridian of greater and less ametropia have not been at right angles. This would suggest cornical cornea, but there was nothing of this kind to be seen by other methods. One meridian may be at 85° and the other at 145°. When you discover that there is this abnormal irregularity in the cornea, you naturally conclude that you cannot bring the vision up to the normal point. If you get this with the ophthalmometer, it saves a large amount of labor in fitting glasses in the attempt to make $V = 1$.

It has also seemed to me that mixed astigmatism is more common than is usually imagined. After obtaining the sum-total of the astigmatism in the cornea, I have found it my business to make up that astigmatism with the trial glasses, but I have often not succeeded until I assumed that the astigmatism was of the mixed variety. That I would get without resorting to the use of atropine. The difference in the meridian would not be great, rarely more than 1 D, it may be .75 D. I have

learned to look for mixed astigmatism and to correct it more frequently since using this instrument than formerly.

Another circumstance that has arrested my attention is the influence of the eye-lids upon the curvature of the cornea. I have found the refraction to vary while the eye was under observation. Therefore if the vertical meridian has not continued to show the same refraction, I have asked an assistant to elevate the upper lid, and I have then obtained a fixed result.

I have also satisfied myself that the tension of the eye muscles in some instances modifies the curvature of the cornea. This accounts for the fact that we obtain such variable results when we test with glasses. We have ascribed this to varying conditions of accommodation. It is probably also due to the pressure of the lids and of the motor muscles.

The corneal astigmatism does not always correspond to the total astigmatism. If there is a marked discrepancy, I resort to atropine, but as a matter of fact, I use atropine much less frequently than formerly.

Another thing that I have noticed is that occasionally there is a pulsation of the corneal reflex. In other words, I have sometimes seen patients whose cornea was so thin that the circulation of the eye impressed itself upon the structure of the cornea itself. This, however, has been a rare occurrence, and has been seen more particularly in cases of conical cornea. With the ophthalmometer any variation in the cornea is at once manifest.

This is an extremely practical and valuable instrument. It saves an immense amount of time and when one has learned to use it, gives very little trouble. I now scarcely know how to do without it. The examination with it is much more rapid and satisfactory than under former methods.

There is another point. After getting the total amount of astigmatism, the proper cylindrical glasses can be put behind the ophthalmoscope; then the suitable spherical correction is made, and you can then determine with extremely close approximation the condition of refraction of the patient's eye. You then verify with the trial case the results obtained.

Dr. Samuel Theobald, Baltimore. — Dr. Burnett, in speaking of the cause of the discrepancy between the total astigmatism of the eye and that obtained by measuring the cornea, seemed to think that when a mydriatic is used the lenticular astigmatism is done away with. My experience does not agree with this. I am disposed to think that the asymetrical form into which the lens is brought by the action of the ciliary muscle does not disappear at once when the muscle is paralyzed.

I think that these cases of discrepancy between the total and the corneal astigmatism may be accounted for by this persistent asymetrical condition of the lens, which condition does not disappear until after astigmatic glasses have been worn for some time. Since my attention was called to this matter several years ago by Dr. Randall, I have been more and more impressed with the correctness of this view.

DR. CARL KOLLER, New York.—After measuring many eyes, I can state that in the great majority of cases the corneal astigmatism of presbyopic eyes and of atropinized eyes agrees almost exactly with the total astigmatism, while the corneal astigmatism of juvenile eyes does not agree with the total astigmatism but is larger than this. It seems to me that we may employ the term latent astigmatism. Just as through the action of the accommodation, hypermetropia becomes latent, so it is with astigmatism. You find that the astigmatism for near vision is not the same as for distant vision. In individuals over 45 years of age, the astigmatism agrees very well with the total astigmatism.

I have endeavored to find the explanation of those cases to which Dr. Noyes has referred where the axes do not include a right angle. I have found these cases where the angle includes but 70°. I think that it is due to a large angle α. When the axis of vision does not pass through the center of the cornea, but through its periphery, we can not expect anything different.

DR. B. ALEX. RANDALL, Philadelphia.—I can confirm Dr. Burnett's view that obliquity of the lens is sometimes responsible for a considerable degree of astigmatism. I may remind the Society of a case which I reported two years ago, of rupture of the choroid with slight dislocation of the lens. The oblique position of the lens was recognizable through the iris. There was a corresponding myopic astigmatism of 5 D or 6 D, which disappeared completely with the recovery of the normal movements of the pupil and of accommodation, both of which returned almost completely.

From what experience I have had I cannot agree with Dr. Burnett in reference to the predominance of simple astigmatism. At the University Eye Clinic, where in the last ten years we have had about 4,000 refractive cases, determined almost without exception under a mydriatic, the results have been that compound hypermetropic astigmatism constituted nearly 30% of all the cases, that compound myopic astigmatism embraced 20%, simple myopic and hypermetropic astigmatism about 8% and 12% respectively, and mixed astigmatism about 1% or 2%. The cases of compound astigmatism constituted at least 50% of all the refraction work.

Dr. Swan M. Burnett, Washington. — I can corroborate the observations referred to by Dr. Noyes as showing the influence of the lids on the cornea. I was astonished when I first discovered this. I tried to refer the effect to several other things but was finally forced to the conclusion that it was the lids that had made the difference. The appearance of the white bands would alter as much as 0.5 D through the action of the lids. I also thought that I observed in the horizontal meridian, alterations that could be due to strain of the lateral muscles. I think that there can be no question that the pressure of the lids does exercise an influence, and I think that it to a certain extent goes to show that the original cause of the astigmatism may be lid pressure.

In speaking of lenticular astigmatism, I tried to be as guarded in my statements as possible. I credited the greater part of it to partial action of the ciliary muscle, but I believe that there are grounds for supposing that there may be lenticular astigmatism other than that due to partial action of the ciliary muscle. If you find lenticular astigmatism in persons 45 to 50 years of age, particularly if the ciliary muscle has been paralyzed, you must conclude that there is an obliquity of the lens. It has been found by Javal and others that this partial action of the ciliary muscle which is undoubtedly often present in youth, disappears with age and therefore in persons over 45 years of age, with lenticular astigmatism, we can pretty certainly exclude any such partial action of the ciliary muscle.

Dr. Henry D. Noyes, New York. — That lenticular astigmatism may be due to an irregular contraction of the ciliary muscle is not a new observation, but dates back more than fifteen years to Dobrowlski and Woinow. Within the last five years it has been again brought forward and referred to as a new discovery.

There is another point, and that is that the astigmatism that is found in incipient cataract is necessarily in the lens and is due to more or less irregular sclerosis of the lens. We find astigmatism in these cases quite frequently.

A CASE OF PROGRESSIVE HYPEROPIC ASTIGMATISM.

BY J. B. EMERSON, M.D.

J. C., aged twelve, male, was brought to Dr. Roosa's office on Dec. 29, 1879. The following notes were made by the late Dr. Edward T. Ely:

The patient was complaining of asthenopic symptoms, from which he had been suffering from some months. His general condition was not good and his appetite was irregular.

Vision of each eye was $\frac{20}{20}$. — Wheel corrected and vision improved by a $+\frac{1}{60}$ c 180°.

The ophthalmoscope showed the optic disks to be hyperæmic. Atropia was advised.

December 31*st.* Atropia used two days. Vision each eye:

$$\frac{20}{70} + \frac{1}{48} = \frac{20}{20}.$$

He was advised to use $+\frac{1}{60}$ for his near work.

May 13, 1880. Eyes feel quite comfortable in reading with his glasses, but his distant vision is somewhat blurred:

$$V = \frac{20}{30}\ \frac{20}{20} \text{ with either } +\frac{1}{72} \text{ or } -\frac{1}{72}.$$

Advised to use his glasses all the time.

October 5*th.* Has been comfortable with his glasses, but has asthenopic symptoms when he does not use them:

$$V = \frac{20}{30} : +\frac{1}{60} = \frac{20}{20}.$$

The optic disks look hyperæmic and somewhat indistinct. By moving the light over the disks a delicate opacity filled with minute glistening specks can be seen, especially about the right disk. Maculæ are normal in both eyes. There is some conjunctivitis, for which nitrate of silver was advised.

December 18*th.* Complains that the glasses do not now relieve his eyes. Advised $+\frac{1}{48}$ for his near work. On

Nov. 9, 1883, he came under my care. He then complained

of indistinctness of vision, both for near and far, and pain on using his eyes. Vision each eye:

$$\frac{20}{50} - \frac{1}{60} = \frac{20}{30}.$$

Advised atropia.

Nov. 27th. Atropia sulph. (grs. iv to ℥i.) has been used in each eye, three times a day, for the past two weeks:

$$\text{R. V.} = \frac{20}{30} + \text{with} + \frac{1}{48}\,c\ 140^\circ.$$
$$\text{L. V.} = \frac{20}{30} + \text{"} + \frac{1}{60}\,c\ 40^\circ.$$

Ophthalmoscopic examination, both by Dr. Roosa and myself, showed the fundus to be normal. Advised the above cyl. glasses to be used all the time.

Aug. 3, 1885. His eyes have given him no trouble, but thinks that he cannot see as well with his right eye as with left:

$$\text{R. V.} = \frac{20}{100}.$$
$$\text{L. V.} = \frac{20}{50}.$$

Advised atropia.

Aug. 14th. Atropia has been used ten days:

$$\text{R. V.} = \frac{20}{100} + \frac{1}{18}\,c\ 165^\circ = \frac{20}{20} +.$$
$$\text{L. V.} = \frac{20}{70} + \frac{1}{36}\ 15^\circ = \frac{20}{20} +.$$

With both eyes using the above glasses, V. $= \frac{20}{15}$. These glasses were advised for constant use.

March 16, 1886. Is using his eyes about six hours a day for study and they give him no trouble: V $= \frac{20}{20}$, with his glasses.

October 20th. Has an acute attack of catarrhal conjunctivitis. Says that the sight of his right eye is failing:

$$\text{R. V.} = \frac{20}{40} \text{ with his glasses.}$$
$$\text{L. V.} = \frac{20}{20} \text{ " " "}$$

Atropia was again used for seven days, with the following result:

$$\text{R. V.} = \frac{20}{200} + \frac{1}{13}\,c\ 165^\circ = \frac{20}{30} +.$$
$$\text{L. V.} = \frac{20}{100} + \frac{1}{20}\,c\ 15^\circ = \frac{20}{30} +.$$

These glasses were advised and worn with comfort for about a year.

Dec. 13, 1887. Complains that for the past three months he has had some pain and blurring in his right eye:

R. V. = $\frac{20}{50}$ — with his glasses.
L. V. = $\frac{20}{40}$ + " " "
R. V. = $\frac{20}{30}$ + with + $\frac{1}{9}$ c 165°.
L. V. = $\frac{20}{30}$ + " + $\frac{1}{18}$ c 180°.

Using both eyes, V. = $\frac{20}{20}$.

It was not deemed necessary to use atropia, and the latter glasses were advised.

April 19, 1888. Has used his glasses constantly and has had no asthenopia, but says the sight of the right eye is not as good as it has been:

R. V. = $\frac{20}{40}$ + with his glasses.
L. V. = $\frac{20}{30}$ + " " "

Vision cannot be improved.

A NEW FORM OF CATARACT KNIFE.

BY EDWARD JACKSON, M.D.,
PHILADELPHIA, PA.

THE knife here shown (see Fig.) has a blade consisting of two parts, one beginning at the point and extending about 14 millimeters, like an ordinary Græfé knife, with a slender point, and becoming about 2 millimeters wide where it joins the other portion; the other spreading, by the addition of a triangular piece of metal to the back, the cutting edge forming a continuous straight line with the edge of the first part, until 28 millimeters back from the point the total width of blade is 6 millimeters.

These are the dimensions I have chosen for my own use. Slight modifications of them might better adapt the knife to a somewhat different incision.

The knife is substantially a combination of the Græfé and Beer knives. With it the puncture and counter-puncture are to be made, just as with the Græfé knife; and then the incision

is to be completed in much the same way as with the Beer's knife.

The idea of attempting to combine the advantages of the Græfé and Beer knives first occurred to me nine years ago, when I did my first cataract operations. It was then laid aside until I should feel more familiar with the established methods of operating. At first I thought of making the angle in the cutting edge; but this would have made a point in the cutting edge difficult or impossible to thoroughly sharpen. Later I thought of a curved cutting edge. But a few months ago I fixed on this form. I have used it in the few extractions I have since done, with great satisfaction, securing easily a smooth incision, and neat co-aptation.

The advantages it seems to possess are:

The puncture and counter-puncture are as perfectly under control as with the Græfé knife.

The flap may always be completed with the one forward thrust.

The escape of aqueous can be largely prevented until the incision is nearly completed.

The counter-pressure of the back of the knife balances the pressure of the cutting edge and aids materially in the fixation.

NEW EYE INSTRUMENTS.

BY J. OSCROFT TANSLEY, M.D.,
NEW YORK.

I DESIRE to show to the society several eye instruments, each of which have served me well in the cases where I have used them, and for that reason I bring them before you.

It consists of an ordinary barrel and piston syringe, an hypodermic or rubber bulb syringe can be used if desired, to which are fitted three canulae of different sizes (the peculiar construction of which constitutes the improvement), which are closed at their extremities with a solid bulbous point having the shape at the point of Theobald's probes. Just above the

bulbous point the canula is pierced by a number of small holes passing directly through the canula to admit of their being cleansed easily.

LACHRYMAL SYRINGE.



The size of these bulbous extremities is not material and they may be made to suit the user, but they should be considerably larger than the canula; the ones which I show you are No. 3½; No. 8 and No. 12 of the French scale.

If we fill the syringe with water and press the piston home, the water will be seen to leave the canula in fine jets and in a lateral direction.

My idea is that the bulbous point inflicts the least traumatism when introduced, and then, as it is much larger than the canula, it can be passed as far as desired into the canal or directly through into the nasal cavity, then be drawn back a little until the terminal bulb closes the extremity of the canal. Now, if the piston be pressed, the liquid passes laterally out of the small perforations, dilates the canal, and applies itself to every part, and finds its way upwards and out at the inner canthus, where it is caught with a napkin, and not a particle, or at most, only a drop or two, passes into the nose or throat of the patient.

In use, of course, that bulb should be chosen which will close most perfectly, yet pass into the canal.

The straight and open canulae which have been used previously will become so sharp by use at their open extremity that they will gouge out the mucous membrane and inflict considerable traumatism, and then when the liquid is injected it

passes directly through the canal, applying itself to but a limited portion of the mucous membrane and expending its greatest energies in the nose and throat of the patient.

The canulae of the instrument shown you are attached to the syringe by a bayonet catch, but a screw thread may be used so that a canula may be attached to an ordinary hypodermic syringe.

CANALICULUS COMPRESSOR.

In cases where we desire to get profound dilatation of the pupil, and to do so have to use atropine solutions, "*coup sur coup*," we are often troubled by the atropine passing down the canaliculus and causing excessive dryness in the patient's throat before we have secured the necessary pupillary dilatation.

I have tried previously to avoid this by causing the patient to hold his head to one side and by compressing the canaliculus with the finger, but this always fails.

The instrument I have devised to accomplish the object consists of two flat, heart-shaped pieces of silver, one of which slides up and down upon an upright, which is fastened to the other piece of silver at right angles to its plane. These two pieces of silver are held together, or rather caused to approximate each other, by a delicate spiral spring, wound upon the upright. When using, the lower piece of silver is passed under both canaliculi and the upper piece is pressed over and held upon the canaliculi by the spring, thus closing them both and preventing the passage of the solution into the nose.

The unpleasant feeling can be obviated by a drop of cocaine.

LACHRYMAL PROBE.

This is a modification of Weber's Probe, and consists simply in supplementing its size with one embodying the idea of Dr. Theobald of more thorough dilatation of the canal.

It is made of same shape as Weber's Probe, and the two embrace the following scale:

WEBER'S PROBE:

Small End (French scale),	Bulb - -	No. 3
	Base - -	No. 7
Large End,	Point - -	No. 6
	Base - -	No. 9

TANSLEY'S PROBE:

Small End,	Point - -	No. 8
	Base - -	No. 11
Large End,	Point - -	No. 10
	Base - -	No. 13

My idea in using the Weber shape is to dilate the canal as much as possible with least traumatism.

With the Weber-Tansley series we can pass up to Theobald's No. 16 size, with only four introductions, and get the easy conical dilatation which is least violent; whereas, by the Theobald series, sixteen introductions are necessitated.

LACHRYMAL STYLE.

This consists of a silver tube, the upper part of which is bent at right angles and cut away in a manner so as to leave a trough-shaped opening into which the tears can easily pass.

They have to be fitted to each individual case, first by ascertaining the length of the canal by means of a probe, and then cutting the tube off and leaving it barely long enough to pass out of the canal into the nasal cavity,

This longer end will also have to be bent — usually outwards and forwards — so as to take the direction of the canal and permit the shorter end to lay along the canaliculus.

The short end will also have to be cut off so that its point barely touches the ball of the eye and does not cause the ocular conjuctiva to crinkle upon movement of the eye in various directions.

DISCUSSION.

DR. SAMUEL THEOBALD, Baltimore.— I have here a set of aluminum lachrymal probes which I have used for eighteen months. They have been entirely satisfactory. They do not oxydize as much as silver probes and are very light. Their chief advantage, however, is that the aluminum of which they

are composed, is a very smooth and slippery metal; their introduction, therefore, is decidedly less unpleasant to the patient.

I also exhibit an aluminum style. I have been quite successful in instructing patients, who live at a distance and cannot remain sufficiently long under treatment, to introduce the probes themselves. In four cases, three females and one male, the patients, after I had dilated the strictured ducts, have used the probes themselves, introducing them once a week after their return to their homes.

DR. W. F. MITTENDORF, New York.—I think that the use of a perforated canula for syringing the lachrymal canal is not new. I have used it for some time, and I think that I am indebted to Dr. Noyes for the suggestion. I do not see the necessity for connecting it with a syringe, a simple rubber bulb is more satisfactory.

DR. J. O. TANSLEY, New York.—In using this instrument, the syringe is not essential. Any apparatus that is desired may be attached to it.

DR. SAMUEL D. RISLEY, Philadelphia.—I wish to relate an experience I had in connection with lachrymal probes some years ago. In the preparation of the material for a paper on lachrymal obstruction I sent to Dr. Harrison Allen for all the specimens of skulls that he had showing the lachrymal duct. He sent me six. I also procured a set of these probes. In these six specimens there was not one in which I could pass No. 16, and in some of them I could not get the smaller probes through the bony duct. We should, therefore, be careful in using these large probes; not to use violence.

DR. SAMUEL THEOBALD, Baltimore.—When I first investigated this subject, I began in that way. I went to the Anatomical Museum of the University of Maryland and ascertained, by trial, how large a probe could be passed through the bony canal. I found that I had to make, for this purpose, a series of much larger probes, as the ordinary ones were too small. The largest canal that I met with permitted the passage of a probe with a diameter of seven millimeters. The largest of my probes (No. 16) has a diameter of four millimetres. I also examined the subjects in the dissecting room, and found that in a number of cases, I could pass probes larger than No. 16. I have felt sometimes that, to be consistent, I should use even larger probes than I do.

DR. HENRY D. NOYES, New York.—In illustration of the great difference in anatomical development, I would state that I have in my possession a skull in which on one side I can pass a No. 5 probe only, while on the other side I can go above No. 16.

BRUISE OF THE EYE-BALL, LOCALIZED ŒDEMA OF THE CHOROID AND RETINA, TRANSIENT ASTIGMATISM, RECOVERY.

BY EDWARD JACKSON, M.D.,
PHILADELPHIA, PA.

GEORGE L., 30 years of age, an upholsterer, with left globe disorganized by a penetrating wound when he was 8 years old, sightless, but quiet since a short time after the injury, was struck on the right eye by a small stone or marble, about noon, March 9, 1888. He applied a few minutes later at the Philadelphia Polyclinic, where Dr. D. Greenwald, the clinical assistant then on duty, instilled a solution of atropia, and directed him to use cold water applications. I saw him four hours later. There was then moderate hyperæmia of the globe, involving both superficial and deep vessels; most marked just to the inner side of the cornea, where there was a slight abrasion of the conjunctiva, and a little sub-conjunctival effusion of blood. This was undoubtedly the point of contact, the lids being uninjured. The missile had struck quite obliquely, coming from the right side and somewhat in front of him. The pupil was well dilated and almost round, being slightly flattened toward the point of injury. The media were perfectly clear. The fundus presented in the temporal margin of the macula and the region immediately adjoining it, a number of rounded, pale, yellowish spots, over which retinal vessels were seen very distinctly. The larger of these spots were grouped in one long, and two short lines, having the direction commonly taken by choroidal ruptures; and at the upper end of the longer line the spots coalesced, making it continuous. Occupying the most of the area of the macula and stretching over almost to the disk, was an area of gray opalescent retina, sharply limited toward the spots just referred to, but fading off gradually in other directions. This hid entirely the smaller, and partially the larger retinal vessels. But at the fovea was a spot $\frac{1}{3}$ or $\frac{1}{4}$ of the diameter of the disk in diameter, where this gray veil was absent, which the normal dark red of this area made very noticeable. The disk was normal. *There*

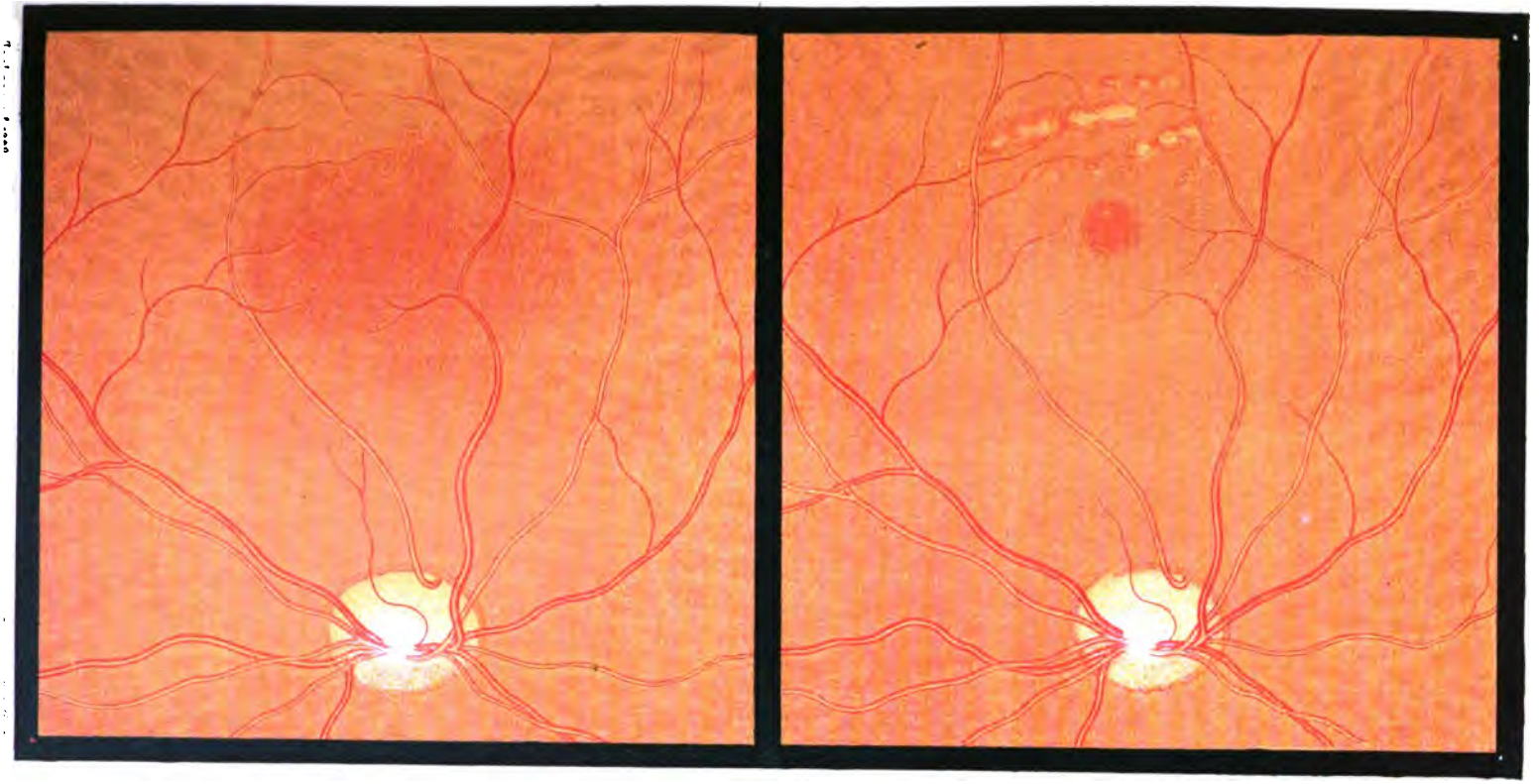

was no trace of hemorrhage. These appearances are shown in the upper figure, taken from a sketch prepared at the time. Dr. George C. Harlan, who saw the case about twenty-two hours after the injury, thinks the representation accurate, except that it exaggerates the retinal opacity, as he then saw it. But the retinal opacity was certainly greater when I first saw it than it was at that time. At twenty-eight hours the retinal opacity had greatly diminished; a day later it was entirely gone. At twenty-eight hours, too, the yellowish spots, choroidal spots I shall call them, were diminishing in size and prominence. Those which had been continuous were becoming discrete. From this time on they faded perceptibly from day to day, and at the end of one week they had entirely disappeared. From that time the fundus has continued normal, as shown in the lower figure, made about the end of the second week.

There was not, at any time, any marked scotoma. On the first day, a minus 0.75 sph. gave him V.$=\frac{15}{20}$ partly; but he was not carefully tested with glasses until the third day. It was then found: V.$=\frac{15}{20}$ partly, and with 0.75 cy. ax. 180°, $\frac{15}{10}$ partly. At the tenth day, V.$=\frac{15}{15}$ partly, with 0.37 cy. ax. 180°, $\frac{15}{10}$ mostly. At the end of three weeks he had V.$=\frac{15}{10}$, mostly, without any lens, the astigmatism being less than 0.25 D.

The superficial hyperæmia disappeared in the first two days; but at the inner side of the cornea over the ciliary region there remained a slowly diminishing deep hyperæmia, that passed gradually away in about two weeks. The pupil became quite circular in the first two days.

The treatment consisted in the use of atropia for three weeks, and protecting the eye from excess of light while the pupil remained dilated.

At the first inspection of the fundus, the question arose: Were these appearances anomalous or pathological? But the subsequent changes have seemed to me inconsistent with any supposition but that of injury of the retina and choroid leading to the effusion of serum, though not of the blood. It would be extremely interesting to know how a blow in the horizontal meridian caused shortening of the curve in the vertical meridian, of the cornea or lens. Was it a direct mechanical influence, or was it through the agency of an injured ciliary body?

SYMPTOMATIC MYOPIA.

BY DR. W. F. MITTENDORF,
OF NEW YORK.

THE fact that myopia, appearing as a symptom of certain diseased conditions of the eye, is so little appreciated, that very few text-books on ophthalmology or on refraction make mention of it, induced me to call your attention to it in this paper.

Myopia is usually divided into two classes; the first one is axial myopia, depending upon an increased length of the antero-posterior diameter of the eye, and the second class, refractive myopia, which depends upon increase of the refractive power of the lens. False myopia, due to spasm of accommodation, belongs to this class. In the third class, which I choose to call symptomatic myopia, the focusing of the rays of light in front of the retina is due to an advancement of the lenticular system toward the cornea, either by an increase of the contents of the vitreous chamber or by a swelling of the lens itself.

Another division of this state of refraction might be made into permanent and temporary myopia. The first class would be that of true axial myopia; the other would comprise the conditions due to spasm of accommodation and the symptomatic myopia due to changes in the lens itself or those brought about by an advancement of the entire lenticular system. This latter subdivision may be caused by a rupture of the Zonula of Zinn and subsequent dislocation of the lens, or by an increase of the contents of the vitreous chamber.

In symptomatic myopia a traumatism may be the cause of it, much more frequently, however, a diseased condition of the eye will give rise to it.

In some rare cases this result may have been brought about by a dislocation of the lens forward. The latter condition is very rare and as a rule accompanied by such disturbance of vision that it becomes difficult to demonstrate the existence of

myopia it produces. Cases of this kind have been reported by Donders, and later Noyes, Loring, and Meyer.

Of more frequent occurrence is a myopic condition due to the swelling of the lens, accompanying the beginning of cataract. In the very earliest stages of the formation of cataract, especially if the anterior portion of the lens is the first one to undergo cataractous changes, the swelling may be so marked as to lead almost to an obliteration of the anterior chamber. This is spoken of as cataracta intumescens. The swelling has been measured by Brailly in London in many instances. Myopia can very frequently be demonstrated in these cases, provided the central portion of the lens remains clear enough; and the failure of vision of such eyes is in many instances relieved by the temporary use of concave glasses. It is surprising to see sometimes how strong a concave lens is required by such patients. As cases of this kind are frequently enough met with by every physician, a few cases may suffice to illustrate this condition.

Case 1. Senator T., of Hamilton, Canada, 60 years of age, and a man in robust health, consulted me in January, 1886, in regard to his eye-sight. His vision began to fail him some ten months ago. Up to that time he had enjoyed excellent vision for the distance, and used a +18 lens for reading and writing. After consulting a specialist he was told that he had cataracts growing in both eyes. After traveling in Europe he came to see me on his way home. His condition was as follows: Broad radiating striae of opaque lens matter extended to the center, the intervening portions remaining quite clear. The vision was O. D. 15/cc O. S. 10/cc. Shortly after his eyes became affected he could not read with his reading glasses and after a while could see better without them. He reads now ordinary print at eight inches without glasses. In the street he saw much better with the ordinary smoked coquilles, partly because they were shading the pupil, partly on account of their concavity. On testing his vision I found that a —16 gave the right eye V = 20/40; the left eye was improved by a —10 from 10/cc to 20/cc. As one of the most annoying things was his inability to recognize people on the street, I ordered smoke-tinted concave lenses of the above

strength for him. In his case the anterior chamber was quite shallow but the tension had remained normal.

Case 2 of this kind is that of an old lady, Mrs. T. She came to me for a change of reading glasses. She had been using +15, which was the glass that her age would call for. In the distance she had had good vision, but lately objects had become very dim and cloudy to her. Examining her eyes I found the lenses of both eyes considerably swollen and slightly clouded by opacities projecting from the outer (temporal) half of lens toward the center. The vision was: O. D. 20/c O. S. 20/LXX. A concave glass 1/36 gave her 20/XL +. Having her read with her glasses, she brought the test-types very close to her eyes and I found that a +24 gave her much more comfortable vision and that they were greatly preferred by her.

Myopia makes its appearance as a symptom, furthermore, in that class of diseases of the eye in which an infiltration into the vitreous takes place; provided that this is in the shape of clear serous exudation, interfering but little with the clearness of the vitreous humor. Plastic exudations are usually of an opaque condition and interfere sufficiently with the structure of the vitreous to be followed by more or less marked impairment of vision, which of course would make it difficult to demonstrate the development of myopia. There is usually, accompanying the increase in the quantity of the vitreous humor, some increased tension of the eye. I have found it almost invariably, though often not in a marked degree, in the cases of symptomatic myopia that I have had occasion to observe.

Of the diseases, during the course of which we may observe the appearance of myopia, we have glaucoma, serous choroiditis and iritis.

Glaucoma in the very earliest stages may be mistaken for myopia. The patients complain that they see everything misty, and if the vision is not too much deteriorated we may find that concave glasses improve the sight considerably. As many of the eyes affected by glaucoma are hypermetropic, the actual appearance of myopia in such eyes is not of such frequent occur-

rence as it would be if mostly emmetropic eyes became afflicted with or attacked by glaucoma. However, I have frequently seen that patients who had been in the habit of using convex glasses constantly, were obliged to exchange them for weaker ones just after the first developments of glaucoma.

As an illustration of this I will refer briefly to two cases taken from my case book.

Case 3. Mr. H., 53, and manager of one of our large bookstores, consulted me in the spring of '78 on account of poor vision. He had noticed that his sight would be much better and then again worse at times. Of late he became more alarmed on account of the steady dimness of sight. His distant vision was O. D. = 20/L O. S. = 20/c. He could read with his glasses (+ 24) but he had to hold everything closer to his eyes than he used to. Examining his eyes I found a slight depression of the nerve, but no pulsation, not even venous, but the slightest pressure would produce decided arterial pulsation. His distant vision could be greatly improved by a — 42. V. = 20/XXX O. D. and 20/LXX O. S. The glasses proved of great help to him at the time (this was before eserine was known). Two months later the sight became suddenly worse and glaucomatous symptoms more alarming, so that after some delay he was operated upon in the left eye which greatly improved his vision, but his myopia had entirely disappeared after the operation.

Case 4 is that of Mrs. C., age 57. She complains that her right eye has given her much trouble, that its sight is dim, and that there is a sensation of pressure within the eye. The left eye is nearly emmetropic, she barely accepts a + 72 for the distance. V = 1. The left eye shows a beginning of a cupping on the outer side of the disc, with a faint scleral ring at the same side. V. = 20/c. — 24 improves, however, the vision to 29/XL. Tension was quite noticeable, but not more than T+1. An operation was mentioned to her, but she refused. I ordered her a weak solution of eserine, and did not hear from her for nearly a year when after a subacute attack of inflammation she consented to an operation, from which she recovered with a vision of nearly 20/LXX not improved by glasses; her myopia having entirely disappeared.

Serous choroiditis can only be accompanied by the development of myopia if the exudation remain chiefly serous and not in sufficient quantity to change the consistency of the vitreous as this would tend rapidly to marked impairment of vision. A few small flakes in the vitreous may, however, frequently be seen in such eyes. As the choroidal exudation is more likely to reach the posterior half of the vitreous first where the pressure of the lenticular system forward is modified and lessened by the anterior half of the vitreous, the appearance of myopia in choroiditis serosa is not often met with. Besides, considering the frequency of the appearance of choroiditis in myopic eyes we must not lose sight of cause and effect, and the development of symptomatic myopia can only be proven, if the refractive condition of the affected eye was known previous to the occurrence of the disease.

Mr. Joseph F. called on me May, '88, complaining that there was a blur before the right eye. This had come on a few weeks ago. Before the attack the eye was perfectly good, for some time ago his left eye became affected and he was treated for it in the city of Mexico. The doctor was then afraid that the right eye might become affected and tested it very frequently, but he could read 20/XX with perfect ease. The vision of the eye is now barely 20/LXX but with —36 it is improved to 20/XL. On examination the posterior half of the vitreous appears to be hazy and choroid and retina very œdematous. The left eye had been affected four years ago and shows two patches of choroiditis areolaris. The case was evidently one of choroiditis specifica. Even after the use of atropine the vision remained as before, and concave glasses improve the vision considerably.

Symptomatic myopia is perhaps most frequently observed in connection with iritis, partly because this disease is one of the more common affections of the eye, and partly because the infiltration into the vitreous occurs in its anterior portion, and the effect upon the lenticular system is consequently felt more directly. One of the first to call attention to the development of myopia during an attack of iritis and its subsequent disappearance after the inflammation had been cured, is Dr. J. Green. He observed it in his own case as well as in other patients, after his

attention had been called to it. There are certain forms of iritis where there is not much plastic exudation, and usually only a few peripheral synechiæ, where the aqueous as well as the vitreous humor appear perfectly clear, and yet the vision is abnormally poor. The anxiety of the patient is apt to be great on this account, although there may be little pain, and in fact very slight inflammatory signs. The ophthalmoscopic examination of such eyes may at times reveal a mild form of retinitis, which would account for the poor sight of the eye, but very frequently no disease of the deeper parts can be diagnosed, except perhaps a slight haziness of the vitreous humor, but enough of it to explain the failure of sight; nor would the mydriasis, the result of the atropine treatment, do it. If in such cases a concave glass is put before the patient's eye, the vision can be frequently improved, at times almost up to the normal, in other cases not so much. The myopic condition thus created is, however, not constant, it is apt to vary according to the decrease or increase of the inflammation. A relapse is, as might be expected, followed by a greater impairment of vision and a stronger concave lens may be required to improve the sight. On the other hand, an improvement of the inflammation brings about better vision, and a weaker concave lens is apt to give very much better results. After the iritis disappears, the normal sight is apt to be restored. The permanent use of concave glasses has, of course, not been resorted to, because rest of the eye is considered to be one of the most essential things in the treatment of iritis.

Long before Dr. Green made his report to this society I had observed similar cases, and of late my attention having been more thoroughly aroused, I have found the occurrence to be by no means so very rare. Myopia is of course only apt to show itself if the iritis attacks emmetropic or slightly hypermetropic eyes, for a higher degree of hypermetropia could hardly be overcome by a simple advancement of the lenticular system and there would hardly be room enough in the narrow anterior chamber of such eyes to produce a myopic condition.

The following cases, some of them referring to medical men who knew the refraction of their eyes, will perhaps better explain the peculiarities of this appearance. The condition existed not

only during the active inflammation, but also after an almost complete recovery and in spite of the fact that the eyes were thoroughly under the *influence of atropine*, and the accommodation appeared to be *completely paralyzed.*

Case 4. Mr. J. V., a merchant of this city, presented himself at my office May 5, '83, with a well developed iritis of the left eye. The eye had been painful and inflamed for three days and there were the usual objective signs of iritis. The initial lesion dates back four months and the secondary manifestations had been slight. After the use of atropine the vision improved, but remained very poor, the good eye had a vision of 20/XX and accepted a + 48. On the second visit, two days later, the pupil was well dilated, and only two fine synechiæ were seen at the lower section of the pupil, vision not tested. On the third visit the adhesions were very thin and elongated; but although the media appeared clear, the vision came barely up to 20/CC. On the fourth visit the synechiæ had almost disappeared, but the sight remained as poor as ever. I thought that there might be considerable hypermetropia, which had become manifest by the use of the atropia, and I expected to get some improvement by convex lenses. However, they appeared to make the sight worse. Concave glasses, however, made the vision much better. The exact number of the glass I did not write down in my case-book, remarking simply that weak concave lenses improved the sight to 20/XL, it had been 20/CC without glasses. A week later the patient returned; the eye being almost free of injection and the synechiae had given way entirely. The vision had improved to 20/L, and by means of weak concave lenses was raised to 20/XX. Two weeks later the patient called to tell me that he considered himself quite well; the vision was at the time of this visit 20/XX without glasses, and concave glasses did not improve it. Atropine was discontinued, and after the pupil had returned to its normal size the myopia had entirely disappeared, and concave glasses did not improve his sight, which was perfectly normal.

Case 5. Dr. M. G., a student of Bellevue, called on me Dec. 8, '86, complaining that his left eye had been a little sore, enough to prevent him from sleeping soundly, and that the pain

was greatly increased whenever he attempted to study or exposed himself to light. He had been treated for an eruption of the face and neck, which he considered to be of an acne-type. He denied specific trouble, but upon examining him carefully I found several mucous patches of the throat, that had not troubled him much, however, and enlarged post-aural glands. I diagnosed a beginning specific iritis, and ordered him to use inunctions of mercurial salve. There were several synechiæ that yielded promptly to the use of atropine with one exception; the eruption disappeared, but the eye did not change very much. The vision on the contrary was getting a little worse, having fallen from 20/XL to 20/CC. The media being very clear, however, I tried a concave lens which improved the sight at once. The right eye had a slight degree of hypermetropic astigmatism and vision of 20/XL. This eye had always been defective in sight and had given him trouble before. The left inflamed eye had a vision of 20/XXX with — 20 ⌒ C — 72 ax. 180°. After the iritis had entirely disappeared, I had occasion to test the eyes again and found that the left eye had a vision of 20/XX and accepted a C + 72 ax. 90, its myopia having entirely disappeared.

Case 3 is that of Dr. G. H., 25 years of age. The entry of this case reads as follows: Oct. 3, '87, iritis serosa specifica O. S. About four days ago the sight of the left eye became blurred. The redness had preceded this by a few days. There had been some supraorbital neuralgia, pupil narrow, O. D V = 20/XX + O S. V = 20/C. Fundus a little hazy, retina blurred. Corona veneris marked, post-aural glands large, hair in front falling out. — 20 improves vision of left eye to 20/XXX +. Oct. 10th, more inflamed, vision = 10/CC with — 20. V = 20/CC. Vitreous and aqueous hazy, iris discolored, one small synechia in a downward direction. Oct. 15th, several small dots on Descemet's membrane. V = 20/C with — 18. Nov. 18th. After using atropia, hot compresses and vigorous antispecific treatment his vision improved and is now 20/LXX, without glasses; — 36 or — 42 give a vision of 20/XX —48. V = 20/XX doubtful. Iris appears perfectly normal in every respect, punctate appearance of Descemet's membrane entirely

gone; vitreous appears a little hazy, fundus normal. Vision of right eye 20/xx as before. Facial eruption much better. Nov. 20th, vision alike in both eyes, = 20/xx without glasses.

Case 4. Mr. M. C., a book-keeper, consulted me early this spring. His eyes had troubled him for some time. The right one became blurred several weeks ago and the left a few days ago. He had to give up his occupation. The examination revealed a mild form of iritis with numerous fine spots on Descemet's membrane. After using atropine a few thread-like posterior synechiæ are seen on each eye. O. D. V = 15/cc O. S. V = 20/L. He denies having ever had a chancre. No signs of syphilis could be discovered. Atropine, hot compresses, and bichloride of hydrargyrum with tincture of Peruvian bark was ordered. One week later the left eye had become worse, its vision being now almost as poor as that of the right eye. Says that he sees much better with his smoked coquilles than without them. These glasses proved to be a very common pair of glasses, and had a marked concave effect. This called my attention to the fact that there was undoubtedly a myopic condition caused by the iritis; and a —30 improved the vision of the patient considerably. After increasing the dose of the bichloride the eyes began to improve slowly and in about four weeks the patient was able to return to his work again; the myopia had by this time entirely disappeared and his vision had become almost normal.

The foregoing cases prove beyond a doubt that a myopic condition may be brought about by certain diseases of the eye; that the myopia, however, is never permanent; in fact appears only as a symptom of a disease and that as the disease disappears, it disappears likewise, leaving the eye in the same refractive state it was in before it was attacked by the morbid change.

DISCUSSION.

DR. J. O. TANSLEY, New York. — Several years ago I had an interesting case bearing upon this point which I reported in the American Journal of Ophthalmology. This was a case of localized exudative choroiditis just beneath the macula. When first seen: V = 20/c. I did not see the exudative choroiditis at

the first examination, but I tested the vision and found that with — $\frac{1}{40}$ c. V = 20/XX —. I thought that the fundus looked suspicious and told him to return. Two or three days later, I found a spot of exudative choroiditis under the retina. V =20/c. With — $\frac{1}{30}$ c, 20/XX —. I tested the vision every time I saw him. On the next occasion V = 20/c, and with — 1/30c, 20/XXX. It passed on until — 1/20c was required to bring vision up to 20/XL. At this time the inflammation was at its highest point and the little spot of exudative choroiditis presented a woolly appearance. This gradually disappeared, and while this was going away he gradually went back in the same order, until finally when dismissed he had no inflammation, simply a spot of atropic choroiditis, about as large as the end of a pencil, and he would not accept any glass whatever, vision being 20/XX —, nearly as good as in the other eye.

I have one case which will be interesting to report in connection with this very valuable paper of Dr. Mittendorf.

I have met with a number of cases of symptomatic simple myopia, but the following is the only one which I ever met of symptomatic astigmatism. They probably occur often but are not recognized because the patient is not tested for refraction during the continuance of an inflammation.

This patient consulted me about seven years ago, complaining of a blur over the left eye.

L. V. 20/100; w — 1/30 c. ax. 90° = 20/30.

With ophthalmoscope no fundus lesion was found.

Second visit.

L. V. 20/100; w — 1/20 c. ax. 90 = 20/30.

Could not see as well with — 1/30 c.

Using the ophthalmoscope there was seen a spot of exudative choroiditis just below the macula and of about the same diameter as the optic nerve, over which the retinal vessels passed unaffected, and which was hypermetropic as compared with the general fundus.

Contrary to my usual custom in cases of acute fundus lesions I tested the vision and refraction of this case at each visit.

I did not use atropine at any time with this case.

Third visit.

L. V. 20/200; w — 1/20 c. ax. 90 = 20/40.

Sixth visit.

L. V. 20/100; w — 1/20 c. ax. 90 = 20/30.

Tenth visit.

L. V. 20/70; w —1/30 c. ax. 90 = 20/20.

Eleventh visit.

L. V. 20/30; w — 1/36 c. ax. 90 = 20/20.

Thirteenth visit.

L. V. 20/30; w — 1/48 c. ax. 90 = 20/20.

Fourteenth visit.

L. V. 20/20. Could not be made to accept any glass.

The exudative choroiditis had at this time all passed away, leaving a spot of atrophic choroiditis with pigment about its edges.

It will be noticed that the myopic astigmatism increased gradually up to —1/20 c, the cylindrical lens each time improving the vision greatly and then when the fundus lesion began to subside the refractive error gradually became less until the eye was perfectly emmetropic.

HYSTERICAL BLINDNESS IN THE MALE, WITH THE HISTORY OF THREE CASES.

By WILLIAM OLIVER MOORE, M.D.,
OF NEW YORK.

HYSTERIA is a term, the etymology of which is misleading, and, until quite recently, was considered a disease confined to women; Hippocrates, Landouzy, Monneret, and others, believing that the origin of the affection was in some perversion of the uterine functions; on the other hand, Rosenthal says: "We must admit that moral causes, which may often lead to hysteria in the female, may also produce the same disease in delicately constituted members of the male sex."

Briquet, in one thousand cases of hysteria, found fifty to occur in males, or one male patient in twenty of the number; other authors that one in fifteen not too high an average. Between the years 1875 to 1885, no less than five theses on hysteria in the male appeared in France.

The hysterical symptoms last longer in the male, and may occur in weak, or effeminate, or in strong, robust individuals.

Laségue has been led to apply the term peripheral hysteria to many cases, from the fact that any form of irritation in a patient predisposed to hysteria, may act as an exciting cause. For example, the presence of a foreign body on the cornea may

be sufficient to set up the full train of nervous symptoms. The object of presenting these cases to the attention of the society is to make more prominent the fact that hysterical blindness is prevalent not only in the female, but is to be frequently found also in the male, and that we should be on the alert for its detection. Both Harlan of Philadelphia, and Galezowski of Paris, have reported cases of this affection. Of course simulated, one-sided blindness is well-known in all countries where every healthy man is forced to do military service, and many wishing to evade such service resort to this subterfuge. Such cases as these are not to be considered under this head.

[illegible] histories are of patients coming under my

[illegible]

appearance, with pupils equal in size and responsive [illegible]
L. V.=o (patient's statement), R. V. = $\frac{20}{xx}$, Em.

The ophthalmoscopic picture in the right eye was normal, save a spot of opaque nerve fibre in the lower outer portion of the field close to the papilla. In the left eye the fundus was absolutely perfect and emmetropic. On testing with the candle and prism, vertical diplopia was demonstrated, and as there was no error in the R. E., this convinced us at once of the fact that vision was present in the L. E.

Pressure on one eye-ball by the finger to change the relation of the optic axes was made, and again diplopia was produced, showing conclusively that vision was present in the L. E., and that the blindness was *mental.*

The patient was informed that treatment for a few days would

Thirteenth visit.

L. V. 20/30 ; w — 1/48 c. ax. 90 = 20/20.

Fourteenth visit.

L. V. 20/20. Could not be made to accept any glass.

The exudative choroiditis had at this time all passed away, leaving a spot of atrophic choroiditis with pigment about its edges.

It will be noticed that the myopic astigmatism increased gradually up to —1/20 c, the cylindrical lens each time improving the vision greatly and then when the fundus lesion began to subside the refractive error gradually became less until the eye was perfectly emmetropic.

The remainder of this Discussion, having been mislaid at the time of printing, will be found on page 120, following the papers read at the New London meeting.

[illegible] says:

"[illegible] must admit that moral causes, which may often lead to hysteria in the female, may also produce the same disease in delicately constituted members of the male sex."

Briquet, in one thousand cases of hysteria, found fifty to occur in males, or one male patient in twenty of the number; other authors that one in fifteen not too high an average. Between the years 1875 to 1885, no less than five theses on hysteria in the male appeared in France.

The hysterical symptoms last longer in the male, and may occur in weak, or effeminate, or in strong, robust individuals.

Laségue has been led to apply the term peripheral hysteria to many cases, from the fact that any form of irritation in a patient predisposed to hysteria, may act as an exciting cause. For example, the presence of a foreign body on the cornea may

be sufficient to set up the full train of nervous symptoms. The object of presenting these cases to the attention of the society is to make more prominent the fact that hysterical blindness is prevalent not only in the female, but is to be frequently found also in the male, and that we should be on the alert for its detection. Both Harlan of Philadelphia, and Galezowski of Paris, have reported cases of this affection. Of course simulated, one-sided blindness is well-known in all countries where every healthy man is forced to do military service, and many wishing to evade such service resort to this subterfuge. Such cases as these are not to be considered under this head.

The three following histories are of patients coming under my notice during the past few years, and are as follows:

Case I.—J. C. B., male, age 25, farmer, married, with no children, residing at Long Ridge, Conn.; father and mother healthy; he is the third of five children; first seen by me June 16, 1886, when he gave this history: Has always been in good health until two years since, when he began to show nervous symptoms, being disposed to frequent quiet places and to be melancholy and morose; very fond of reading; did not smoke or have any vices; is happily married; on June 1, 1886, complained of failing vision in the left eye, and after two weeks noticed that not even light could be distinguished.

On examination, June 16th, both eyes had a normal external appearance, with pupils equal in size and responsive to light. L. V.=0 (patient's statement), R. V. = $\frac{20}{xx}$, Em.

The ophthalmoscopic picture in the right eye was normal, save a spot of opaque nerve fibre in the lower outer portion of the field close to the papilla. In the left eye the fundus was absolutely perfect and emmetropic. On testing with the candle and prism, vertical diplopia was demonstrated, and as there was no error in the R. E., this convinced us at once of the fact that vision was present in the L. E.

Pressure on one eye-ball by the finger to change the relation of the optic axes was made, and again diplopia was produced, showing conclusively that vision was present in the L. E., and that the blindness was *mental.*

The patient was informed that treatment for a few days would

be necessary with electricity, and that a complete restoration of vision in the L. E. could be promised.

A strong Faradic current was applied, one electrode being placed over the nape of the neck, and the other over the closed eye-lids of the L. E. The full force of the battery was applied quickly, and by rapidly breaking the current the shock was considerable. This treatment was a great surprise to him, and he jumped from the chair, exclaiming that already there was improvement in vision. This strong current was again applied the same day, only in the reverse order; first the mildest, then rapidly the strongest to be obtained. The effect now, as at first, was startling and marked, and after the second application, by the test type vision in L. E. $= \frac{20}{L}$ much to his satisfaction.

The next day one application of the Galvanic current was made to the cervical sympathetic, after which the patient declared his vision perfectly restored. By test it was $\frac{20}{XX}$; Sn. I read at ten inches. No limitation of the visual or color field. He returned home at the end of ten days well, without further treatment, and has never since had any difficulty, yet surrounded by the same influences.

Case II.— G. F., male, age 22, single, farmer and student, residing at West Woodstock, Vt., a large, well-formed and fine looking patient. On the paternal side insanity is present, one living uncle being an inmate of an asylum; his father and mother are well and of correct nervous organization.

He was first seen by me May, 1888, when the following history was obtained: Eighteen months before, having some difficulty in reading, he sought the advice of a physician, thinking that he might need glasses. Atropia was used by the physician and glasses prescribed. The mydriatic effect of the atropine so annoyed him from the blurring of near objects, that he became very much excited and thought that he would become blind, notwithstanding the assurances of the physician to the contrary.

From this time on he kept on smoked glasses, and finally bandages, and then kept secluded in a dark room, going out only at night, and then with numerous head coverings and with a guide. The lids were kept shut, and he declared that he was

blind. For ten months he kept this darkened room, and even then with shades over his eyes, so great was his fear that light would enter, it being a part of his fear that should light fall on the eye it would seriously affect the optic nerve. At no time was there inflammation of the eyes or eye-lids, nor any pain; nothing except the *mental photophobia*, but none actually (as tested by his attending physician).

When first seen by the reporter, May 15, 1888, he looked pale from the long stay in the darkened chamber, but otherwise healthy. He had what I have always noticed in hysteria: a great fondness for narrating the minute details of his condition, and spoke with that characteristic precision noticed in such nervous conditions.

He came a distance of forty miles to see me, and had a picturesque appearance with his colored glasses, and these in turn covered by a veil and shawl.

On examination the eye-lids were found shut; but not by spasm; the patient could open them, but did not do so for fear of light. The corneae were clear, conjunctivae slightly injected, pupils normal in size and responsive to light; patient claims to be blind in each eye. No ophthalmoscopic examination could be made, owing to the great dread of light.

The general appearance of the patient and the absence of ocular symptoms, led to the diagnosis of hysterical amblyopia. A prognosis was given that in one week he would be able to return home with eyes wide open and with perfect vision.

Canthoplasty on each eye-lid under ether was advised and accepted.

May 17, 1888, profound etherization was produced and a liberal canthoplasty performed, the lids being carefully inspected at the same time. On recovering from the effects of the ether he opened his eye-lids and looked at the surroundings, and by asking questions, showed that he saw clearly. When fully from under its influence, he was confidently told that the seat of the disease had been discovered and removed, and that in a few days he would be fully restored to health. In brief, he progressed most rapidly, and the second day after the operation was walking about the grounds of the hospital with eyes open and

protected only by a shade. On the 24th inst, he returned home alone with perfect ease, and without any eye-coverings. July 12, in a letter to me, he says: "I work daily about the farm and can read at night without fatigue; my eyes seem to be as well as ever."

He had no sexual vices and his home influences were pleasant.

Case III.—H. deB. W., age 15, male, schoolboy, the second son of nervous parents, living in a farming district, is fond of study; has a delicate appearance; of regular habits, especial pains having been taken to ascertain if there was any sexual perversion or excitement to account for the ocular symptoms; does not smoke, or use tea or coffee; a short time before had been disappointed in not receiving a prize at school, and from that time ocular symptoms manifested themselves gradually; he showed no aversion to attending school, but lacked the enthusiasm formerly shown; one month after this disappointment he became blind in the R. E.

May 7th, 1885, L. V. $=\frac{20}{xx}$, R. V. $=0$ (as stated by the patient). The eyes appeared normal in every particular, the ophthalmoscope showed no intra-ocular change; there was no limitation of either the visual or color field. The prism test brought out diplopia, and the displacing of the optic axes, by pressing with the finger, produced the same result. The test with the colored glasses and the test type also proved that the vision was present in each eye. The parents were told of the nature of the case, and the patient confidently told that he could be cured.

The administration of ether, as a means of treatment, was suggested and accepted, and on May 10th he was put under the influence of the anæsthetic profoundly, the L. E. bandaged, and he was then allowed to come from under its influence. When semi-conscious he opened the R. E. and looked about and shortly after asked various questions, showing that the vision was perfect. He could also read newspaper type.

Being assured that the seat of the difficulty had been discovered, he manifested great pleasure; and after treatment by electricity, cold douching, and general hygienic measures, he was allowed to return home May 28th, with vision normal in each eye.

He returned to school and has never had any similar trouble since.

The use of ether in the treatment of these cases was suggested by the experience gained by Dr. J. H. Hutchinson of Philadelphia, in 1864, who, by its repeated administration, cured a case of hysterical deaf-mutism.

In each of the three cases reported, the treatment consisted of some shock to the nervous system. In the first the strong electric current; in the second by the etherization and canthoplasty; and in the third by etherization alone.

In all, the assurance of the discovery of the cause, in my opinion, acted as an important factor in the case. It is a mistake to tell these patients that they have nothing the matter, and also to tell them that it is hysteria; for they are all anxious to be cured and do the best in their power to overcome the difficulty, but have not the requisite force. Any operation, or shock, is sufficient, as a rule, to cure them.

No. 128 *Madison Avenue.*

DISCUSSION.

DR. B. ALEX. RANDALL, Philadelphia.—It may be proper to call attention to those cases of amblyopia and apparently complete blindness in association with blepharospasm, and apparently due to the spasm. There has been a series of cases published under that heading.

DR. J. F. NOYES, Detroit.—This paper brings to mind a case which occurred in my region many years ago. A farmer was seized with aphonia. He was seen by a number of physicians without benefit. He answered questions by writing on a slate. The doctors believed that he could speak if he would and told him so. He finally went to the office of a physician who told him that he would try an experiment and would cure him by electricity. They passed the current through his throat and he began to talk at once, and from that moment was well.

DR. DAVID WEBSTER, New York.—It seems to me that many of the cases which formerly were reported as simulated amaurosis might in reality be instances of hysteria.

DR. EDWARD JACKSON, Philadelphia.—A delicate colored boy, about 12 years of age, was brought to the Polyclinic some months ago, with bare perception of light, according to his

statement. A very confident prognosis and the use of a mydriatic gave full vision, as the effect of the mydriatic passed off.

DR. SAMUEL D. RISLEY, Philadelphia.— I do not recall a case of hysterical blindness; but I have in mind one of hysterical photophobia in an individual who had suffered with hysterical aphonia until one of my patients took up her residence in the same house. The aphonia then disappeared and photophobia appeared. It was cured by a visit to the seashore and the threat to apply leeches if the photophobia continued. The sudden disappearance of the aphonia, and the equally sudden appearance of the dread of light, at once suggested the hysterical origin of the condition.

DESCRIPTION OF A SERIES OF TESTS FOR THE DETECTION AND DETERMINATION OF SUB-NORMAL COLOR-PERCEPTION (COLOR-BLINDNESS), DESIGNED FOR USE IN RAILWAY SERVICE.

BY CHARLES A. OLIVER, M.D.,
OF PHILADELPHIA.

As it is a well-known fact, both from theoretical and practical standpoints, that many "Color-Blinds," especially those of medium grades, have the power of differentiation, even by daylight, of the most difficult colors, when placed at the ordinary one-metre distance of wool selection employed in the detection and determination of "Color Blindness," the writer has been induced, through a hope to overcome the dangers that might arise from this power in situations, such as railway, marine, and naval service, where the safety of lives and the protection of property is ofttimes almost solely dependent upon proper recognition of color at great distances and frequently through the intervention of more or less translucent media, to combine two modifications of his method of color selection to a simplified plan of the former procedure by which the candidate is placed in the actual position of after-work and under exactly similar circumstances as during employment.

To effect this purpose in railway service, the method is divided into three parts:

First: The selection and registry of a definite number of loose wools from twenty-three pure and confusion match-skeins, thrown upon a dead-black surface at one-metre distance.

Second: The selection and registry of the same number of similar reflected colors under various intensities of diffuse day-light stimulus, placed at distances requisite for safety.

Third: The selection and registry of transmitted color under various intensities of artificial light-stimulus, placed at distances requisite for safety.

APPARATUS.

The material for the first part of the test is quite simple. It consists of all of the wools comprised in the first shades, together with the five test skeins, of the series of wools described by the writer at the 1886 meeting of the society, associated with a piece of dead-black muslin, an explanatory sheet with the colors arranged in their proper order, and a spectacle frame with a movable stop.

The second portion of the test will consist of a tier of twenty-three shallow, open wooden boxes painted dead-black, placed upon a horizontal beam, supported by vertical posts or rods fifteen feet high. Each box is to have its inside surface so arranged as to face an observer placed in a line with the center of the row at one thousand feet distance; every five boxes in the tier being separated by spaces equal to three times their own width, and every fifth box by double this width. Arranged above the middle of these, and at a height equal to six times the height of the lower boxes themselves, there is to be a large revolving box so made as to contain five partitions. The back face of each box is to have a greater space than the largest area of color to be exposed. The inner face of each side of the box will contain a slot, into which a wooden frame containing definitely sized areas of colored bunting equal to that which can be distinguished at the distance chosen by an average normal eye. Each color-frame will have stamped upon it the designation of the contained color in the same nomenclature as employed

upon the bangles attached to the wools. The partitions of the upper box will contain the proper sized surfaces of the five principal test-colors that can be recognized by the average normal eye at the employed distance. In addition, there are to be a series of London smoke-tint and translucent glass discs for use in the spectacle frame.

The additional material for the third part of the test will consist of twenty-three definitely sized chosen areas of transparent colored glass having surfaces composed of concentric prisms of not sufficient power to cause commingling of diffusion circles with fellow lights. These plates of glass are to be placed in the same character of wooden frames as those which are to be employed for the reflected colors, and each area of color is to have its proper color designation stamped upon its fame.

A series of registry blanks will accompany each set.

PROCEDURE.

The first part of the test is conducted by a modification of the ordinary Holmgren method,[1] and the result for each eye noted by reference to the attached bangle upon the first division of the registry blank. If the examination shows that the candidate has failed, then the entire test can be suspended, as the unfitness for work is plainly manifest, but in order to make the test complete, and thus serve as a check against any future legal disquisition, it is best in all cases to continue just as if the candidate had passed successfully.

For the second test, the fixed apparatus can be placed anywhere upon the railway grounds. The wooden frames containing

[1] The plan of procedure is as follows: Broad, diffuse daylight is necessary. The square of black muslin should be placed upon a flat table about thirty-six inches from the candidate's eyes, and the wools spread promiscuously upon its surface. The five large test skeins are to be separated from the rest.

One eye of the examinate is to be taken at a time The surgeon should place one of the large test-skeins a short distance from the other test-skeins (preferably commencing with the "green"). The candidate is now requested to select from the pile of wools, one skein which he considers the nearest match to the separated skein, and to lay it alongside of the test-skein. Frequently, as Holmgren says, "If the person examined cannot succeed in understanding this by verbal explanation, we must resort to action." We should go through the procedure and thus show the candidate exactly what is wanted, taking care, however, to so disarrange our choice that it will be impossible for him to gain any information by the selection The lettering upon the tag of the chosen wool is to be registered and placed upon the blank. This finished, the selected wool is to be replaced among the general mass, and the same method of selecting and registry continued with the rose, the red, the blue, and the yellow, until the examination is completed.

BLANK FOR THE REGISTRY OF THE COLOR-SENSE.

.....*Railroad Company.*

.....*Division.* .....*Station.*

No...... *Date,*.....

Name,..... *Age,*..... *Address,*.....

Social condition,..... *Present occupation,*.....

Applicant for.....

RIGHT EYE.			TEST COLOR.	LEFT EYE.		
Light chosen in Third Test.	Color chosen in Second Test.	Wool chosen in First Test.	Color Submitted.	Wool chosen in First Test.	Color chosen in Second Test.	Light chosen in Third Test.
			V			
			Ro			
			R			
			F			
			C			

Remarks,.....

.....

.....

....., *Examiner.*

Result,.....

....., *Superintendent.*

Report of Expert,.....

.....

.....

.....

the match colors of bunting are to be placed in the lower tier of boxes, in any order whatsoever, just as if we were to throw the wools upon a table. The five test colors of bunting in the wooden frames are to be slid into the slots in the partitions of the large upper box, and the "V" (pure green) area is to be wheeled into position. The candidate, employing one eye at a time, is now asked to designate by writing the number upon a blank used for the purpose, which color in the lower row (going from his left to his right) is the nearest match to the upper color. This experiment is to be repeated by each test color, preferably, but not necessarily pursuing the order of choice spoken of in the first test, until all have been obtained. These blanks are then to be handed to the examiner, who, after having obtained the names of the numbers chosen for the occasion by the attendant, places them in the second row of the registry blank. To obtain different percentages of light-stimulus and to simulate as near as possible changes in character of weather (fog, rain, etc.), variously tinted glasses can be placed in the spectacle frame, although it would be quite easy, and really proper, to test the candidate during these actual states of weather; yet, as these changes are so uncertain as to frequency and duration of happening, it will be best to limit this variety of experiment to those cases under suspicion.

The third test is to be conducted in precisely the same manner as the second, except that here the procedure will be made during darkness and by the substitution of the plates of transmitted color, and the lanterns for the areas of bunting.

An experimental track with five open switches, about a thousand feet away from the apparatus, so arranged that the sidings would pass directly beneath the colors, would be useful after the regular examination had been completed, thus practically testing color-vision from locomotives running at full speed, and deciding the ability to differentiate the ordinary white, red, and green signals at safe distances by the choice of track taken.[1]

Upon account of the above methods being strictly confined to the estimation of the color sense alone, the necessary apparatus for use in testing visual acuity for form, power, and range of accommodation, area and character of visual field, all so necessary to combine in complete trials for defective vision amongst railway employees, have been avoided and reserved for another paper in which the method of obtaining the power of the visual sense in its entirety with suggestions as to the employment of better working apparatus in such positions, will be fully explained.

ADVANTAGES.

In addition to the advantages shown, to refer to the first test alone,[1] the method may be said to have the following additional uses:

First — Much faster in time than any other proper method. In the first test there are but five selections amongst twenty-three wools, which will at once decide, without continuance, whether the candidate possesses sub-normal color perception for near colors; thus accomplishing in a few moments as much as the Holmgren method.[2] In order to greatly expedite the second and third tests, and in consequence render the entire plan faster than any other, a dozen or more candidates may be examined at the same time, by merely handing them all slips of paper upon which they are all at once to register their names and the number of color or light in the lower row matching the upper test color exposed; care alone being taken by proper guards that there is no intercommunication at the time.

Second — Selection of loose colors at a distance. There is no other plan that in any way gives choice by loose and changeable selection at a distance. This has been done by naming the colors, so that no matter how they are placed in the tier at the time of examination, they always hold their identity, and can be properly registered upon the blank.

Third — No necessity for an expert except in doubtful cases. Every "Color-Blind" candidate, as it were, becomes his own accuser and writes his individual verdict. The examiner at the station sends the properly filled blanks with his remarks to the

[1] The headings of these advantages, which have been described at length by the writer in the 1886 transactions of the American Ophthalmological Society, are as follows:

1. Five principal tests.
2. The wools are loose and separate.
3. The colors are all of equal relative intensity.
4. Each test-skein has its value expressed.
5. The test can be employed by any educated layman.
6. Accurate notings of passing color changes can be preserved and permanently kept for future comparison.
7. Written and verbal expression of the character and amount of sub-normal color-perception can be given.
8. All the wools are of the same grade of manufacture.
9. All the colors are from vegetable dyes.
10. The use of a black surface or ground for testing.
11. Any order of testing may be pursued.
12. Quantitative determination as well as qualitative determination obtained at one sitting.

[2] The equal intensity of the colors employed destroys any objection to the possibility of escape by reason of fewness of match-skeins.

superintendent of the division, who marks the case "approved" or "not approved," obtaining, if necessary, in doubtful cases the expert report before signing, whether passed or not.

Fourth — Employment of the same character of signal for testing as is used in daily routine. This is a great advantage, and also avoids any source of error that might be said to arise through the question of the supplemental use of touch or the presence of a characteristic dye odor.

Fifth — Placing the eye during testing at a distance necessary for future safety. This is one of the great claims for the adoption of the method, because by it we thoroughly avoid all dangers that might arise from the escape and employment of a class of subjects possessing what Wilson has so aptly termed "Chromic Myopia."

Sixth — Bringing the eye during testing directly before the true condition of weather experienced while it is upon duty. The color-sense is studied in the same place and under the same circumstances as it has given to it while it is in actual service; this is most decidedly a great gain. Moreover, as has been shown, it can even be made to give the best character of detection in those cases and in those situations where it is most needed, such as engineers and assistants placed upon running trains that are rapidly approaching fixed distant signals.

Seventh — Test and match-colors all graduated in proportionate size. This is important, as it is a well-known fact that two similar areas of different colors, placed at a definite distance or when surrounded by darkness, give misconceptions as to positions through difference in relative intensities, and thus tend to disastrous result. By carefully grading the test-colors, this complication is avoided, leaving the question of color, and color alone, to the competing candidate.

DESCRIPTION OF A CASE OF EMBOLISM OF THE LEFT CENTRAL RETINAL ARTERY.

BY CHARLES A. OLIVER, M.D.,

OF PHILADELPHIA.

The present case is added to ophthalmic literature, not as might be conjectured, to offer in any way another opportunity from which to further discuss the mooted question of differential diagnosis of thrombosis, embolism, or thrombosis and embolism of the retinal vessels by ophthalmoscopic appearances alone, which, as is well known, must remain *sub judice* and only answerable *post mortem*, until better differential points can be evolved by means of finer instruments of precision and more delicate methods of study, — but that a clinical picture which has been deemed sufficiently valuable to interest the student in such work, might be given for furtherance of researches in this direction. The title has been limited to that of embolism because the details of the eye-ground, when carefully read over, will be found to contain much more of the true significance and meaning of this type of disease than of thrombosis.

On the third of October, 1887, a young man aged twenty years, a weaver by occupation, came to me with the history of sudden failure of vision of the left eye twenty-six hours previously, unaccompanied by any ocular pain, phosphénes, or headaches; this having come on while the patient was slowly walking down a shaded road. He denied any previous serious illness, and to all appearances was a healthy and hearty man.

Upon examination it was found that the vision of the eye was reduced to very doubtful feeble light-perception in the outer field, while that of the right eye equaled full $\frac{20}{20}$. Upon double exposure both pupils were about two-thirds dilated, but that of the left side became more so when its fellow was shaded. The left iris was not so freely responsive to light-stimulus as the right, with seemingly no reflex to monocular efforts for accom-

modation for objects placed in the field remnant. Tension of each was normal. Ophthalmoscopic examination of the left eye without the use of a mydriatic, showed that the media were clear. The disc was seven by eight diameters in apparent magnitude, the long axis being at ninety degrees; the nerve substance itself was decidedly grayed in its tint. The edges were everywhere hidden by a fine and almost imperceptible thickening and marked œdema of the retinal fibres; this being less pronounced at the temporal side, where a faint trace of blackish pigment could be dimly seen through the œdematous swelling. The swelling of the retina extended for two or three diameters beyond the nerve entrance in all directions, and passed far out into the outer retinal periphery, embracing the entire macular region, where it seemed the densest and the thickest, giving the invaded region a grayish film-like appearance. All of the retinal arteries were reduced in size, especially the upper temporal, and held thin stationary columns of very pallid blood. Throughout the area of swelling the veins were contracted, becoming more and more so as they approached the nerve-entrance, but appeared more tortous, nearer normal in size, and seemingly holding darker colored blood in the untouched peripheral area. Both sets of vessels were frequently lost to view in the swollen retina on the inner side of the ground. The small macular twigs so ordinarily seen in healthy eye-grounds, were invisible. Upon careful focusing, an extremely slow and sluggish current of broken bead-like segments of blood in the superior temporal vein could be plainly seen flowing continuously toward the disc, this being beautifully shown upon a bend of the vessel as it passed over the corresponding artery. No blood current or pulsation could be provoked in the arteries by artificial increase of intra-ocular pressure. The characteristic cherry-spot in the macular region was plainly seen, it being small in size and irregularly horizontal oval in shape. It was bounded by a fine network of minute branching vessels, which appeared to have no connection with any of the main stems. About two and a half disc diameters up and out from the disc, just above the first bifurcation of the superior temporal artery, there was a small hemorrhage; immediately below this there appeared a

curious small dark red swelling, apparently in the vessel itself. The fundus of the right eye was normal. Careful physical examination failed to reveal any other organic lesion. Ten grains of iodide of potassium three times daily were ordered.

On the following day all light perception had gone, although the œdema seemed less and the cherry spot was not so marked. The lower macular artery had become patulous, and carried a slow beaded current of bright colored blood, while the current in the upper temporal vein had become quicker in motion. The veins appeared slightly fuller than the arteries.

On the next day a slow broken current could be distinguished at the primary bend of the inferior temporal vein on the disc, which was somewhat slower in movement than in the upper vein. The small swelling in the upper temporal artery had partially disappeared, and the vessel began to carry a broad bead-like current of bright blood. Both macular twigs became visible, enlarged, and carried interrupted blood currents. Color of the cherry-colored macule had faded to a brownish hue. The density and area of the œdema had markedly increased; the outer edges of the disc being much more hazy. Vision still remained absolutely nothing.

One day later (the fourth day of the attack) the cherry-colored macule had almost gone, and the surrounding vessel twigs had nearly disappeared. The area of the œdema was increased on the inner side, and the disc edges were entirely hidden. The inferior nasal vein began to carry a broken current of blood which, as it slowly passed over a bend just before its passage into the main inferior stem, did not fill the lumen of the canal. Two small fresh blood extravasations in the fibres of the retina upon the disc along side of the macular vessels, and one small fresh blood massing on or in the substance of the disc above the primary distribution of the upper nasal vein, manifested themselves. A fine cholesterin crystal, about pin point in size, could now be seen in the œdematous retina, immediately above the upper macular artery, between the disc and macula. The bead-like blood columns could be observed in all of the vessels except the upper nasal artery, which still remained impervious; the currents in the arteries being at times hidden by the

œdema, and again reappearing before being lost to view in the peripheral endings of the vessels. At this time the veins appeared very much larger than the arteries. The œdema now gained its utmost height, being 2.50 D to the inner side of the macular region, in contradistinction to 1 D, the level of the normal eye-ground in the periphery, while its color, especially about the macular region, had assumed a greenish tinge (gas-light illumination). No vision whatever could be obtained by the strongest light stimulus.

Three days afterward the lower vessels were carrying full columns of blood, though no pulsation whatever could be obtained by pressure. The hemorrhages had almost disappeared. The macular region had become more irregular in outline and seemed filled with almost imperceptible grayish massings. The retina was still markedly œdematous, though the macular region appeared to be depressed from the general œdematous level. The two macular arteries still remained enlarged and were visible almost directly up to the macula itself, but the vascular circle seen primarily surrounding it, had entirely gone. The eye still continued blind.

Four days later (the eleventh day) the blood currents were all re-established with the appearance of two fresh hemorrhages upon the lower temporal artery and lower temporal vein. Nerve substance rapidly undergoing degeneration, this being mostly marked to the outer side, while the retinal œdema was becoming striated, corrugated, and flattened in places. Eye still remained "black-blind."

One month later (six weeks from when first seen) the nerve substance had greatly shrunken — to such an extent that the scleral rings could be plainly seen, both to the nasal and the temporal sides of the disc, with blackish pigment groupings beyond. The œdema had almost gone, there being but a few faint traces of the swelling left, its position being occupied by numerous small cholesterin crystal studdings. The macular region was converted into a large irregular degenerative area. Vision remained *nil.*

During the entire time the patient had persistently used the iodide of potassium. The physical examination was kindly

made by Dr. James H. Hutchinson, of Philadelphia, and the eye-grounds were seen by Drs. George C. Harlan and William F. Norris.

DISCUSSION.

DR. W. F. MITTENDORF, New York.—I reported three such cases some years ago, and have seen two of them lately. In both of these the upper branch of the artery was alone obstructed, and in both the vision has returned to a considerable degree. I have had occasion to see several cases of embolism, but I never had a case in which there was such complete blindness as in the instance described by Dr. Oliver.

DR. SWAN M. BURNETT, Washington.—It has happened to me, as it has no doubt happened to many of you, to see two similar cases of a very unusual character within a short time. Within the past month I have seen two cases bearing a strong resemblance to embolism of the central retinal artery.

The first case was that of a man seventy-one years of age. Lying down one afternoon, he awoke completely blind in the left eye. He went to a physician who treated him four or five days and he then came to me. There was absolute blindness in the left eye and the pupil was dilated. In the region of the macula I found the characteristic cherry spot, although at this time it was somewhat darker than cherry color, and marked œdema of the retina. All of the arteries were very small. There was no complete disappearance of any artery except the inferior temporal branch. The other branches were small but easily seen. There was not much change in the condition of the veins. He is still under observation, and when last seen, a few days ago, there was some vision corresponding to the inner and upper half of the retina. By the tenth day after the occurrence of the attack, the cherry spot at the macula had disappeared, and when last seen the œdematous condition was disappearing.

The other case occurred in a woman eighty-six years of age, and came under observation ten days after the case just described. The same thing occurred as in the previous case. There was absolute blindness. The cherry spot and the œdematous condition were precisely as in the former case. I was able to detect some remnants of all of the branches of the artery.

Whether these are genuine cases of embolism of the central retinal artery we have no means of absolutely determining. I remember a discussion which occurred some years ago in which it was suggested that this condition might be due to thrombosis.

Whether or not if I had seen these cases at the commencement of the trouble I should have found emptiness of the arteries, I do not know. I wish simply to put these cases on record as falling in the category of embolism. I would also state that in the case of the woman I found, at my second examination, a small hemorrhage at the inner margin of the disc.

DR. W. F. MITTENDORF.—It is remarkable in what a short time the characteristic appearances in the retina take place. The last case that I saw occurred in a distinguished physician, a great writer who had been writing up to two o'clock one night. As he was retiring and was about extinguishing the light he discovered that the sight of one eye had gone. At seven o'clock in the morning he called and I found the typical picture of embolism. The œdema was marked, the cherry spot was distinct, and the arteries were more or less empty. It was impossible to produce any pulsation and the veins were tortuous. This was only five hours after the occurrence of the attack.

DR. HENRY D. NOYES, New York.—Autopsies show that in reality a large majority of these cases are due to thrombosis. About the only case which can be considered a true example of embolism is that published by Græfe. Seven or eight cases have been examined and thrombosis, arterial or venous, in the anterior segment of the nerve has been found. In one case the thrombosis commenced in the veins and there was secondary obstruction of the arteries. I have had occasion to look this matter up lately and the above is the result.

DR. SWAN M. BURNETT.—Nettleship's case also was, I think, one of true embolism. Cases of this kind are, I know, referred to either thrombosis or embolism, and I think that some time ago the balance of opinion was in favor of thrombosis. I might say with reference to the first case which I reported that the heart was examined by an expert and no valvular murmur found.

A CASE OF DOUBLE CONGENITAL IRIDIREMIA IN A CHILD WHOSE MOTHER EXHIBITED A CONGENITAL COLOBOMA OF EACH IRIS.

BY SAMUEL THEOBALD, M.D.,
BALTIMORE.

JAMES O'C., aged 18 months, was seen at the Baltimore Eye, Ear, and Throat Charity Hospital December 9, 1887. His mother, who brought him, seemed worried chiefly by the red appearance which the pupils of his eyes presented. Upon examination, besides a convergent squint of the left eye, complete absence of each iris was discovered. The lenses were clear, and there seemed to be, in the right eye at least, fairly good vision. A tenotomy was subsequently performed upon the squinting eye. The interest of the case lies in the fact, which was accidentally discovered during the examination of the child's eyes, that there existed in the mother a congenital coloboma of each iris. In the right eye the coloboma was a large one, its direction being directly upwards; in the left eye it was somewhat smaller, and was in an upward and outward direction. In neither eye was the choroid involved in the congenital defect.

The mother volunteered the information that she had another child, older than the one she had brought to the hospital, who seemed to her to have a similar defect in its eyes — the pupils exhibiting the same red appearance. Unfortunately, through an error in recording the residence in the hospital register, my efforts to hunt up this child, in order to ascertain whether the mother's description of its eyes was correct, were unsuccessful. From her account of the appearance of the eyes, it seems altogether probable, however, that to this mother with congenital coloboma there were born two children with absence of the irides.

DISCUSSION.

DR. DAVID WEBSTER, New York.—I think that the direction of the congenital coloboma in the mother's eye was unusual.

I have seen a number of cases of congenital coloboma of the irides, but in nearly all cases the coloboma was downwards. I do not recall a case in which it was upwards.

DR. B. ALEX. RANDALL, Philadelphia.—Having recently investigated this subject, I can state that there are a number of cases reported in which the coloboma has been inwards or outwards; but I have found none in which it was upwards. This case would seem to be unique in this respect.

PUNCTURE OF THE RETINA FOR DETACHMENT —THREE OPERATIONS, WITH THEIR RESULTS.

T. Y. SUTPHEN, M.D., NEWARK, N. J.

APRIL 1, 1887, J. R. W., a small, robust man, 62 years of age, sought treatment for a cloudy appearance before his right eye, which he had noticed but a few days; had been a bookkeeper for many years; always near-sighted, but had never used glasses for reading or writing; said he had been healthy and his eyes never troubled him until recently. Examination: R. S. = 15/100, raised to 15/20 w.—1/16. Field of vision defective downwards and towards the median line; tension slightly diminished. L. S. = 15/100, raised to 15/15 + w.—1/16. Field and tension normal. The ophthalmoscope showed myopia, with choroiditis in both eyes — the choroid being studded with numerous small, isolated spots of exudation,— while in the right the retina was found detached in its upper and temporal portion. The patient was informed of the serious nature of his trouble and urgently advised to undergo vigorous treatment in bed, with the hope of arresting the disease; but this he declined to do. As an alternative, while rest was enjoined, potassium iodide in bitter tincture was prescribed, the iodide to be slowly increased. During the next few weeks the detachment in the right eye gradually increased. Two months after the first visit patient returned with commencing detachment in the upper and temporal portion of the left retina. The man by this time being

thoroughly alarmed, consented to any treatment thought best except the use of mercury. He was kept in bed for two weeks with the eyes bandaged, while profuse diaphoresis was frequently induced by jaborandi or soda salicylate, his diet being light, but nourishing. At the end of this time, as his eyes were not benefited in the least, the patient was sent to the country and ordered to remain upon his back, as much he could consistently with health, the iodide being continued. Directions were given to occasionally produce marked diaphoresis by medication. In the early part of December the case was seen by Dr. Webster, who concurred in the diagnosis. October 1st, vision was limited to the outer and lower portion of the field in each eye. December 1st.—In the right there was perception of light only, while in the left vision was still confined to the outer and lower field. The advisability of operative interference as a "dernier resort," had already been suggested to the patient, and now he was not only willing, but anxious to have anything done which might lend a ray of hope. On this date puncture of the retina in the right eye was made from beneath the detachment. After thorough antiseptic care with a bichloride sol., 1 to 8,000, and the eye had been cocainized, a sickle shaped needle, previously dipped in the antiseptic solution, was gently thrust into the globe at its equator, between the insertions of the external and inferior recti muscles and on a plane with the lens. The needle was held with the concave cutting edge directed backwards, passed through the conjunctiva, sclerotic, choroid, and subretinal fluid, and well on until it was thought that the retina had been pierced, when it was gently withdrawn with a sweeping motion of the point backward, the wound of the sclerotic acting as a fulcrum, and the object being to enlarge the opening in the retina. In removing the instrument, sub-retinal fluid immediately escaped beneath the conjunctiva, forming a large vesicle. Atropine having already been instilled, both eyes were immediately closed with a compress bandage, while the patient was told to remain perfectly quiet upon his back. The next day, when the dressing was removed, the conjunctiva of the right eye was found slightly œdematous, but the sub-retinal fluid had disappeared. Field of vision was normal, a red reflex was ob-

tained from the fundus in every direction, and the patient could distinguish large objects about the room. Bandages reapplied. Two days later patient counted fingers readily at twelve feet. The retina appeared in its normal position, but the vitreous was quite cloudy. No hemorrhage was found, neither could the wound in the retina be detected. From this time on the bandage was changed daily, atropine being instilled, while vision in the right steadily improved. December 10th, ten days after the operation upon the right eye, a similar one was performed upon the left, in which no improvement had taken place; but in this case, unlike the one in the right, no fluid escaped outwardly. Examination on the second day showed a marked enlargement of the field of vision in the left, but it was not complete, and some detachment was still to be seen on the temporal side. December 16th, field of vision in each eye normal; no detachment of the retina in either. The patient remained in bed twenty-eight days, and I had every reason to believe him when he said that he had actually not as much as turned his head, except at the time of changing the bandages, when he was raised to a sitting posture for a few moments while his clothing was rearranged. December 28th, was allowed to go down stairs, where he remained for several days, lying most of the time upon his back. February 10th, two months after the operation, detachment began to develop again in the left eye. An examination made February 17th, resulted as follows: Right field of vision normal; no detachment; vitreous somewhat clouded. S.=15/50 w.—1/20. Left field defective upwards and towards the median line, with a break in the blind portion corresponding to the point of puncture. February 27th, S. R.=15/50 w.—1/20; reads Jaeger No. 5 at one foot w.+1/48. Left, counts fingers directly in front at five feet — increased to twelve by directing the line of vision toward the temporal side. March 3d, detachment in the left eye as large as ever, and needling done again, with very little, if any, escape of the subretinal fluid beneath the conjunctiva. Treatment pursued as before, with no reaction whatever. March 5th, field again normal; retina in apposition; vision, as stated by the patient, hazy. March 10th, with the left eye, counts fingers directly in

front at twelve feet. Eighteenth, S. R. and L. = 15/100, raised to 15/50 w.—1/24, Jaeger No. 5 at one foot. Patient describes a wrinkled appearance of objects seen with the right eye alone, while with the left everything seemed hazy. April 1st, partial return of detachment in the left. July 6, more than seven months after the first operation, S. R.=15/100, raised to 15/40 w.—1/20. No return of detachment; field of vision normal; vitreous contains numerous small opacities; reads Jaeger No. 4 at fifteen inches without glasses; color-test showed blindness for red, calling it brown or dark yellow. In the left there was found almost complete detachment of the retina. The patient has again resumed work, such as requires not more than one hour of writing daily; but he is able to support his family, while his joy at again seeing knows no bounds. I quote a few facts from a paper by McG. Robertson, Glasgow, London *Lancet* about 1884 or 5:

In 1850 Sichel recommended puncture of the sclerotic for detachment of the retina, making his cut directly through all the tissues. Kittel, in 1860, reported having tried Sichel's operation, but obtained rather poor results. In 1863 Von Græfe advised puncture of the retina from beneath, with the object of establishing communication with the vitreous chamber, which operation he had resorted to as early as 1857. Alfred Græfe returned to Sichel's method in 1876. De Wecker, in his book, published in 1870, favored combining Von Graefe's operation with that of Sichel's, viz.: puncture of the retina from beneath, with evacuation of the sub-retinal fluid outwardly. Wolfe, in 1878, advocated sclerotomy after dissecting off the conjunctiva, bringing the wound together with sutures after the puncture had been made. Other writers have advised the puncture of the retina from the opposite side of the globe. Of the operations herein reported, the first was a De Wecker, pure and simple, and proved eminently satisfactory; the other two, which were failures, would more properly be classed under Von Græfe's method, unless the subretinal fluid had slowly leaked out through the wound in the sclerotic, which seems to me very unlikely. The interesting facts are these: The apparently perfect safety of this operation under modern antisepsis. One

success and two failures, under exactly similar conditions, barring the escape of the fluid outwardly, in the successful one. The absolute freedom from all reaction with the direct puncture, avoiding the conjunctival wound and its stitches. The better prospects for a good result where the puncture of the sclerotic is sufficient to allow the outward escape of the sub-retinal fluid. Encouragement to try this operation in *otherwise incurable* cases. No doubt the most will be gained when the operation follows closely upon the subsidence of the acute affection immediately causing the detachment. I am persuaded that the chances of success would have been greater in the case of the left eye had there been a free escape of the fluid outwardly, and hereafter shall make this one of the chief objects of the operation. I can see no reason why a very narrow Græfe knife might not be used after accurately measuring the depth of the detachment, provided the point be so directed when puncturing the retina that the wound in that membrane should not rest directly opposite the scleral puncture. This would allow the retina to fall as a valve upon the outer wound, and thereby avoid a possible prolapse of vitreous. Little seems to have been written upon the cure of detachment by this operation during the last few years. No doubt it has been undertaken many times without the cases being reported. Still, wherever a success can be obtained, it seems best to have it recorded, as well, in fact, as the failures, for obvious reasons.

DISCUSSION.

DR. DAVID WEBSTER, New York.—I have had no personal experience in this operation of puncturing a detached retina in the hope of obtaining reattachment. Dr. Agnew never performed the operation, and I think that I can tell you the reason. Very early in his experience as an ophthalmologist, he assisted Dr. Noyes in such an operation, and the result was an inflammation which finally necessitated enucleation of the eye. This one operation and its result, I think, prevented him from ever attempting the procedure. I, however, see no reason why, with antiseptic precautions, the operation should not be done. Ever since Dr. Sutphen reported to me the result in his case, I have been looking for a proper case for the operation. Unfortunately since then all my cases have been instances of old detachment which

had existed for six months or more. I think that this operation should be performed only in cases of recent detachment, which have been present for only a few weeks or perhaps a month or two. After the retina has been detached for any length of time, there would not be much use in replacing it.

I saw the patient, whose case Dr. Sutphen has reported, and found detachment in both eyes and gave a very grave prognosis. I was therefore greatly pleased to hear the excellent result of the operation.

DR. EDWARD JACKSON, Philadelphia.—About four months ago I performed a similar operation on a young man who had been under observation and treatment for detachment of the retina for more than a year. It was done with a narrow Græfe knife and there was quite a free escape of subretinal fluid, but the retina was not replaced. There was no reaction of any importance, and I think, as Dr. Webster says, that under antiseptic precautions, we can do this operation with great confidence that it will not be followed by a serious inflammatory disturbance. My patient could not be kept in bed as faithfully as was Dr. Sutphen's.

DR. E. E. HOLT, Portland.—Some years ago Dr. Mittendorf read a paper on the treatment of detachment of the retina. The following fall I had a case in which there was detachment of the retina with myopia of 8 D. The patient had become blind in the right eye in June, and I saw her in October. I began the treatment suggested by Dr. Mittendorf, and in the course of a month the retina had become completely reattached. I have seen the patient within the past six months, and there has been no return of the trouble. I have had several cases where the detachment was almost cured by this method of treatment. I have never seen any permanent relief from operative procedures for the cure of this affection.

DR. J. F. NOYES, Detroit.—I have met with many cases of detachment of the retina, but in only one have I resorted to surgical procedures. This case occurred fifteen years ago in a patient who came from a neighboring state blind in one eye. The blindness had come on gradually. Turning the eye downwards, I could look over the detachment and see the red reflex of the choroid. I evacuated the subretinal fluid with a hypodermic syringe and the retina returned to its position, and he saw tolerably well. At a subsequent ophthalmoscopic examination, I detected, dimly, the outline of a small tumor about the size of a pea below the entrance of the optic nerve. The patient returned to his home. The retina again became detached, and the eye was enucleated one year later.

DR. SAMUEL D. RISLEY, Philadelphia.— A single experience which I have had may be of interest in this connection. In the cases reported the recurrence did not take place until the patient got out of bed. I had a case in which, after treatment for several months, there was an absorption of the fluid and replacement of the retina. I had in this case interdicted all work. One morning he started from home with vision about 20/XL, and much delighted that he could read fine print. When he came to the office he stated that he could see better in the open air than in the house. To my surprise, on looking into the eye, I found complete recurrence of the detachment. I then learned that he had been compelled to get off of the street car while it was in rapid motion. This had undoubtedly caused the recurrence of the trouble. Such cases, I think, illustrates the importance of preventing all energetic exercise during the treatment of detachment of the retina.

DR. T. Y. SUTPHEN, Newark.— An important element in my case was that I had a remarkably good patient who would submit to lying in bed. I did not feel warranted in reporting this as a success until some time had elapsed. Seven months have now passed since the operation. In the case mentioned by Dr. Noyes, the presence of the tumor would, of course, insure a return of the detachment.

GLIOMA: WITH REMARKS.

F. P. CAPRON, PROVIDENCE, R. I.

Elgenof Pierault, three years and ten months of age, was brought to me June 18, 1888, on account of a tumor growing from the orbit. The parents of the child being almost entirely without any knowledge of the English language, as well as ignorant and unobserving, could give but little account of the history of the case, but as far as one could judge from the report given the child had attracted some attention to itself for nearly a year past. The first point noted was an apparent headache, which continued to increase in intensity for several weeks before any protrusion from the orbit was manifest. When the tumor was once developed there was a rapid growth, and at the time of the first visit the mass was as large as a small adult fist,

over-lapping the brow, cheek, and a large portion of the nose, as will be plainly manifest from the accompanying photograph. There was considerable swelling of the glands in front of the ear, and a portion was suppurating. The odor from the growth was extremely nauseating, and the child was the picture of one enduring much suffering. Although the case was apparently hopeless, yet it was deemed best to attempt a removal of the tumor. Accordingly on the following day the mass was removed, the portion outside the orbit being cut off by the thermo-cautery, the remainder dissected out from the orbit in the usual manner. There was no very excessive hemorrhage, and the cautery easily kept this in check. The external portion of the growth was calcareous in its center, and offered considerable resistance to the cautery. The patient was kept in bed and cold compresses were applied over the orbit.

Two hours after the operation the temperature was 101.1, pulse rapid and weak. Stimulant enemas of digitalis and am. carb. were given, also brandy subcutaneously, tr. opii. camphor, p. r. n. for pain.

June 20. Temperature 102.6, pulse 150. Patient very weak and difficult to treat, screaming on the approach of any one save his father. Bovinine with milk was then given.

June 21. Temperature 101.2, pulse 120. The appetite of patient improved, and able to take some food. There was apparently little pain present.

June 24. Iodoform applied to the stump, and bowels moved by an enema, followed by an abundant discharge.

June 26. Temperature 100, pulse 120. Patient gaining strength daily. Syr. ferri. iod., ordered.

June 27. Patient discharged from hospital, or, rather, was taken away, as the parents were unwilling to remain away from home any longer.

Since the last date I have not seen the child, but heard from the patient about the middle of July, and was informed that the stump appeared nicely healed, but that a similar growth was forming over the glands near the ear, and that a new swelling was observed at the back of the neck.

My object in reporting this case is simply on account of the

extreme size attained by the growth at this age, and the fact that the patient was still alive after about a month. I have operated upon two other cases of glioma, one of which I was not permitted to treat until the eye became painful, although when first seen the tumor was undoubtedly confined to the globe. The second case was one where the growth had burst through the eye-ball some time before patient was seen. The former case had a recurrence of the growth in a short time, and after its removal another appeared, followed by death on the next day after its enucleation. The second case was alive for a year or more after being operated upon, with no sign of a recurrence, and is probably still living, now five or six years after operation.

Since reporting this case at the meeting in New London I have ascertained that the patient, Elgenof Pierault, died on the 24th of July, about five weeks after the operation.

DISCUSSION.

DR. J. F. NOYES, Detroit. — Some years ago I had a typical case of double glioma in its early stages in a child three years of age. I detected the glioma with the ophthalmoscope. There was some hardness of the balls and the child was totally blind. I therefore advised the removal of both balls. The father would not consent to this. The disease progressed and involved the whole of the eyeball and orbits so that the appearance of the child before death was much like that shown in this photograph. The child died in the course of a year after I made the diagnosis. I believe that if the operation had been performed the life of the child might have been saved.

DR. T. Y. SUTPHEN, Newark. — I may state that I have seen one child die with this trouble this year. I have also seen a case of what I supposed to be double glioma, but do not think that we are justified in calling every whitish tumor in the ball by that name — we cannot make a positive diagnosis without a microscopic examination. The case referred to was a child six months of age. It is a difficult thing to determine what should be done under such circumstances.

DR. ALEX. B. RANDALL, Philadelphia. — I have with me a drawing of the early condition of what I suppose to be sarcoma of the choroid. This is rarely met with as a lesion of the fundus distinctly recognizable as such, standing out in the *clear* vitre-

ous. I have therefore thought that it might be well to exhibit this. Dr. Knapp has, I think, published the report of such a case. The growth was apparently hemispherical, about five disc-diameters in breadth, and covered the posterior pole of the fundus, projecting 8 D. into the vitreous. The patient never returned to confirm or refute my unfavorable prognosis.

DR. SAMUEL B. ST. JOHN, Hartford. — I should like to know what reliance is to be placed upon the tension of the globe in differentiating between glioma and other conditions which lead to increased tension? My attention has been particularly called to this point by a case now under observation. The patient, a child four years of age, was quite sick some time ago with what was supposed to be malaria, although at the same time there was a brother sick with cerebro-spinal meningitis. The physician is confident that there was nothing like inflammation of the brain. The eye was quite red at the time that she was sick. Within a month after the recovery of the child a peculiar appearance of the pupil was noticed and two months ago she was brought to me. The iris was moderately dilated and adherent in many points, the anterior chamber was obliterated, there was a whitish mass nearly filling the vitreous chamber and there was at least normal tension, possibly sub-normal. If there had been increased tension I should have considered it a case of glioma. This case has puzzled me considerably and I should be pleased to hear the opinion of the members in reference to tension in glioma.

DR. DAVID WEBSTER, New York. — I have seen a number of cases of glioma of the retina, but I think that I have not been able to detect any increase in the tension until the second or inflammatory stage has been reached. I believe that there is then always increased tension. In at least two cases I have diagnosticated glioma of the retina by the increased tension in connection with the history, when no tumor could be seen, the cornea or lens being too opaque to be seen through.

Perhaps all present know that there is on record in the transactions of this society a case in which Dr. Agnew enucleated both eyes of an infant for glioma, at an interval of a few months. The microscopical examination showed that the diagnosis was correct. The child is now living at the age of fifteen years. The child was only a few months old at the time of the operation. It is certain that all cases of true glioma do not die from the disease. I know of one or two cases in which the diagnosis was made without enucleation, the operation being refused by the parents, and in which the disease never progressed, the patients still living. I think, however, all things

being considered, I should advise enucleation where there is a strong suspicion of glioma. If the disease returns, again enucleate and cauterize freely.

DR. SAMUEL THEOBALD, Baltimore.—What is Dr. Webster's explanation of those cases of glioma in which the eye was not removed, and the disease did not progress and death did not ensue?

DR. DAVID WEBSTER.—Retrogressive metamorphosis. I would ask the President, who knows more about the disease than most of us, whether or not retrogressive metamorphosis does not take place in some of these cases?

THE PRESIDENT.—My impression is that in true glioma complete retrogressive metamorphosis does not take place. We find fatty degeneration in places, but I know of no instance in which it could be supposed that the growth had entirely disappeared. I believe that such cases are instances of mistaken diagnoses, and that it is exceedingly difficult to make a positive diagnosis before the tumor has attained a sufficient size to enable us to recognize the vessels in it. I recall very distinctly a mistake of my own where I was called to see a case in consultation. The patient was a man forty years of age. It was agreed by all that there was probably an intraocular tumor and that enucleation was necessary. The eye was removed and no new growth found. There was a large patch of atrophied choroid under a detached retina. It had been supposed that there was sarcoma with detachment of the retina.

DR. S. F. MCFARLAND, Binghamton, N. Y.—A child two years of age was brought to me with a growth in the eye which had been discovered only a few days before I saw it. It presented the characteristic appearance of glioma. I enucleated the ball at once. The microscopical examination confirmed the diagnosis. The operation was done five years ago, but the patient is still a well-developed, healthy child. There was in this case no increased tension, pain or other disturbance, except the total loss of sight in the affected eye, and the steel gray reflex which was quite noticeable. The growth was about the size of a large pea.

DR. EDWARD JACKSON, Philadelphia.—I recall the case of a boy, who, after an attack of typhoid fever, was found blind in one eye, and with greatly impaired vision in the other. The blind eye presented a yellowish white mass pushing the lens forward until the anterior chamber was almost obliterated. On the front of the mass were blood vessels. The other eye presented choroiditis with considerable vitreous opacities, which cleared up, vision returning to nearly the normal. Here we

had but a pseudo-glioma, though the appearances and vascularity of the tumor indicated true glioma.

DR. SAMUEL D. RISLEY, Philadelphia. — I would ask, in view of the apparent safety with which puncture of the eyeball may be made as shown by the reports of Dr. Bull, Dr. Sutphen, and Dr. Noyes, would it not be justifiable in cases where the diagnosis is doubtful, as in the instance reported by the President, to resort to paracentesis and draw off the fluid. This would certainly aid in the diagnosis, and its performance in the case alluded to by Dr. Norris would have excluded the presence of a tumor.

DR. F. P. CAPRON, Providence. — I might mention two other cases of glioma which I have had. In one case the tumor came outside of the globe and filled the orbit. This was removed and six or eight months later there was no appearance of return.

The second case, a boy of four years of age, was brought for a peculiar appearance in one eye. There was a bright yellowish reflex. I stated that it was a cancerous growth and that the eye would have to be removed. The parents would not consent to this and subsequently visited New York where the same opinion was given. The child was again brought to me on account of the severe pain, and I removed the eye. I was satisfied from the appearance that the disease would soon recur. In six weeks the growth again filled the orbit. This was removed and in a short space of time another growth appeared. This was operated on by Dr. Miller, but the child died on the morning after the operation.

DR. W. F. MITTENDORF, New York. — Glioma must certainly be more frequent in certain localities than in others. I see very few of these cases. It might be interesting to have all of these cases reported as regards the localities and especially as regards hereditary tendencies. I think that if the society would take a step in that direction it would be useful.

MODELS CONSTRUCTED BY MR. C. F. PRENTICE FOR DEMONSTRATING REFRACTION BY CROSSED CYLINDERS.

BY SWAN M. BURNETT, M.D.
WASHINGTON, D. C.

REFRACTION by crossed cylinders is a problem which it seems few, even of professed physicists, have cared to take hold of. Stokes' formulæ (the first we have any knowledge of), so far as published, are not applicable to all possible cases, and though he most probably worked out some general formulæ, they are not to be found in his printed works.

It has seemed to me, however, that for class demonstration and for those whose knowledge of optics is not sufficient to enable them to follow out an intricate mathematical demonstration, a model-representation was possible which would give a correct and intelligible idea of the course of rays after refraction by any two known cylinders with their axes crossed at any given angle. As cylinders act on light rays in one direction only, and that towards the focal line, it would be easy in two combined cylinders of known strength with their axes at a given angle, to find the final path of a ray that had been acted upon by both, according to the simple law of the parallelogram of forces. In accordance with this idea I constructed some rude models with wooden lenses and copper wires representing the light rays, which I forwarded to Mr. Charles F. Prentice of New York, with the request that he carry out and further elaborate the plan. The result has been the set of beautiful models that I have the pleasure of showing to you now. These show: 1st, refraction by a simple cross cylinder of 7 D.; 2d, refraction by 2 cylinders of 10 D. with an axial deviation of 90°; 3d, refraction by 2 cylinders of 10 D., axial deviation 45°; 4th, refraction by cylinders of 7 D. and 10 D., axial deviation 90°; 5th,

refraction of cylinders of 7 D. and 10 D., axial deviation 45°. The lenses (of copper, gilded) have the same radii of curvature as the lenses they represent, and the direction of each ray after refraction is such as it would be in an actual lens of glass. On the focal planes (of gilded copper) are shown the amount and direction of deviation of each ray from its initial point of no-refraction, when acted upon by either lens separately, together with the parallelogram giving the extent and direction of deviation from the combined action of the two. On these models it is easy to follow any given ray after its refraction, and also to know the change in the form of a bundle of rays falling upon such a combination as well as the alteration in the position and direction of the focal lines with each change in the axial deviation of the two cylinders.

Mr. Prentice has, furthermore, at my suggestion, taken up the question mathematically and worked out, on the basis of this geometrical construction, formulæ which are found to be applicable to all possible cases of crossed cylinders. This work is found in the book[1] which I have the pleasure to show the members, and is to be commended on account of the thoroughness and simplicity with which the subject is treated. I think it can be said that there is no problem in connection with crossed cylinders which we are not now in a position to solve.

DISCUSSION.

DR. CARL KOLLER, New York.—I have always been much interested as to the best way of representing the rays after refraction by cylinders. Two or three years ago I observed some phenomena in the refraction of cylinders which had not been before observed. These phenomena were rather complicated and I tried to make them capable of being understood. I found that the simplest way was by the method of descriptive geometry. In this you have two or three planes at right angles to each other. In this way you can construct not only the focal lines but also the position and size of the images. The action of cylindrical lenses inclined to each other is also readily obtained.

[1] Dioptric formulæ for combined cylindrical lenses, applicable for all angular deviations of their axes, with 6 original diagrams and 1 photograph, by Chas. F. Prentice, pp. 48, James Prentice & Son, 178 Broadway, New York, 1888.

DR. EDWARD JACKSON, Philadelphia.—I think that in our *Transactions* of two years ago, the general formulæ for all possible combinations of cylindrical lenses will be found worked out. The adoption of wires in these models constitutes a great improvement. There is one thing that I have done with thread models which might be done with the wires, that is, to have the wires passing through one quadrant of one color while those that pass through other quadrants are of other colors. This makes the different relations of the rays more evident.

When Stokes devised his lens, I think there can be no doubt that he worked over the whole problem, but as he was only calling attention to that particular lens, he published nothing that did not relate directly to it.

The method of determining the resultant of two cylinders is extremely simple. Take for instance a cylinder of plus 2 D. combined with a cylinder of plus 1 D. at an angle of 30° between their axes. To determine graphically the equivalent it is only necessary to lay off a line representing 2 D. Then at an angle equal to twice the angle between the cylinders, making in this case 60°, lay off a line representing 1 D. and complete the parallelogram. The diagonal will then represent the cylindrical equivalent both in its cylindrical effect and the relative direction of the axis. If one cylinder is minus 1 D. instead of plus 1 D., the minus 1 D. is to be laid off in the opposite direction. In this way we can determine the cylindrical effect of a combination of any two cylinders at any angle between their axes with sufficient accuracy for practical purposes. If it is desired to determine it with greater accuracy the necessary formulæ will be found in the Transactions of two years ago (p. 273). The working out of these problems by descriptive geometry was pretty thoroughly done by Hooweg, who published his results in Græfe's Archives in 1873.

DR. CARL KOLLER.—I do not wish to say that I invented this method by descriptive geometry. I have quoted the one who first gave us the idea of treating these problems in that manner, that is Reüsch, but it had not been used in regard to the position and size of the images, etc. I have done this in a paper on the theory of cylindrical lenses.

DR. EDWARD JACKSON.—The phenomenon that Dr. Koller refers to is one with a part of which we are all familiar in testing cylindrical lenses to determine the axis. I remember his full explanation of it in Græfe's Archives.

DR. CARL KOLLER.—The phenomena which I observed were not known at that time, at least in Europe. Donders did not

know them. When you look through the lens, holding it away from you, at an object and turn the lens the object rotates with twice the quickness of the lens. This is due to images which are not real but virtual. Every point of such an image consists of a real image point and a virtual image point.

DR. B. ALEX. RANDALL, Phila.—It may be of interest to allude to a very simple form of a model illustrating astigmatism. It is difficult to get students to understand this subject from diagrams, while it is easy with a model astigmatic eye. The model consists of an ordinary gas globe of clear glass—one having a *wide* opening below. On placing an oval of plane glass within one side of it, and filling the lenticular space so formed with fluid, it gives a good idea of astigmatism. When filled with water you have a focal length of about 5 D. in one and about 3 D. in the opposite plane. You get thus a hypermetropic astigmatism of about 2 D.—the axis of the globe being 33 C. M. By filling it with glycerine you get a myopic astigmatism. By filling the vitreous chamber with smoke you can demonstrate very beautifully the passage of rays by the use of the stenopaic slit. An astigmatic crystalline is also readily formed by placing together two of the convex ovals of thin glass, used in mounting colored photographs, and filling the interspace with fluid—and properly placed the correction of corneal by lenticular astigmatism is easily demonstrated.

DR. SWAN M. BURNETT, Washington.—The diagram that Dr. Jackson has placed on the board is exactly identical with that used by Stokes. Before the transactions of that year were published I had been working at the problem of a formula applicable to all cases. I found myself in difficulties, for I make no claim to be a mathematician. I therefore took the subject to Professor Harkness of the Naval Observatory. As soon as the papers of Drs. Jackson, Hay, and Oliver were published, I asked him to examine and see whether these formulæ were absolutely general. He said that there were certain cases to which he did not think these were applicable, and promised to work out some formula which would be applicable. He, however, did not do so. I had already constructed these models which I thought would certainly show the direction of any ray through any cylinders crossing at any angle. I sent them to Mr. Prentice, and he worked out the beautiful models you have before you. I have not had time to go over these formulæ of Mr. Prentice, but I think that if they are examined they will be found to be different from those previously published, and that they are applicable to all classes of cases. Mr.

Prentice has taken samples of all kinds and verified them practically with lenses according to the formulæ. What I wanted in the construction of the models was to show my students in a simple way the manner in which cylindrical lenses refract light. In regard to the suggestion of Dr. Jackson that the wires be colored, I think that it is a good one, but as they are, there is no difficulty in following out the course of the ray.

CASES OF OUTGROWTH ON THE OPTIC DISC.

DR. B. ALEX. RANDALL.

Having met little notice in ophthalmic literature of congenital outgrowths upon the optic disc, I have thought it perhaps worth while to report some of the cases which I have met where the anomaly seemed congenital, as being probably not at all rare and hence deserving notice. The first two are cases of tiny cyst. A case of a small cystic outgrowth was reported a couple of years ago by Dr. Kollock (Med. News, Oct. 23, '86), shortly after the observation and sketch of my first case, Fig. 1, Pl. I., and I have since seen another case illustrated in the second drawing, Fig. 2. In both of these cases the little pellucid vesicle stood out upon one of the retinal vessels, and was probably the cystic remains of a hyaloid artery; although the vessel apparently concerned is a vein in Fig. 1.

Three of the cases are of outgrowths of dense, white tissue upon the disc, but slightly prominent, and hiding, more or less completely, the underlying vessels. The last case, Fig. 6, shows a large, prominent outgrowth from the lower outer quadrant, extending down and out some five disc-diameters, and standing out some 6-8 D. into the vitreous. Here there is considerable evidence of pathological lesion.

PLATE I.

PLATE II.

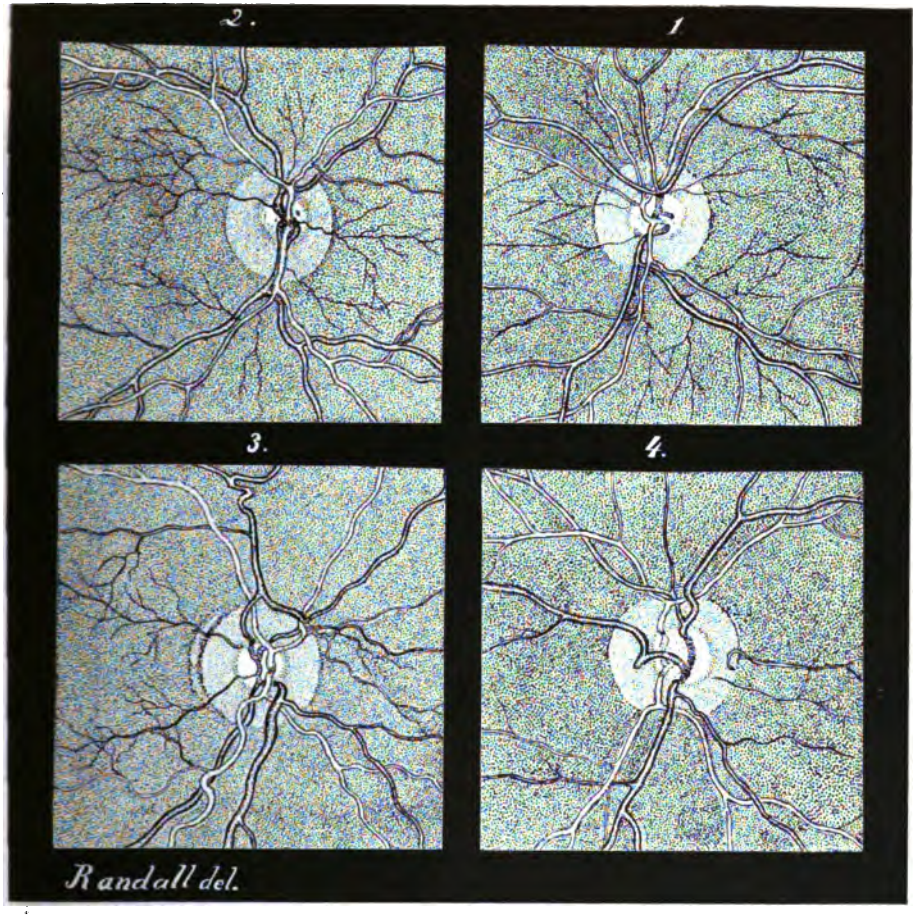

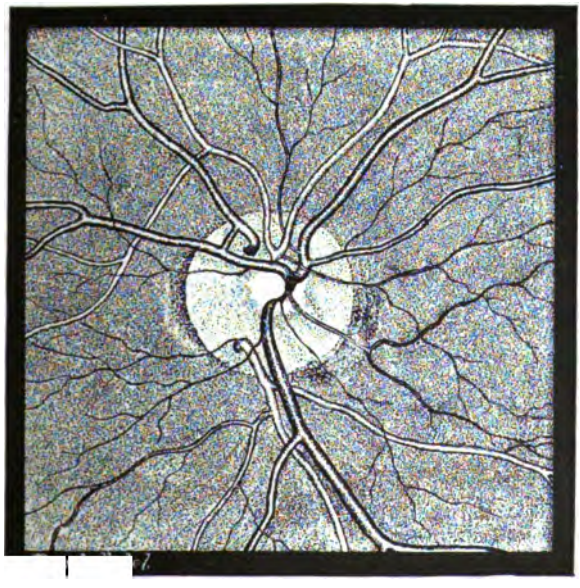

ANOMALIES OF THE VEINS UPON THE OPTIC DISC.

DR. B. ALEX. RANDALL.

As the retinal veins rarely bifurcate in their passage toward the disc, I have brought together here three such cases which have met my notice. In two of these (Figs. 1 and 2, Pl. II.) the division took place just before the vein in question entered the disc; but in the third (Fig. 3) the division took place at the upper margin, and after forming a considerable vascular circle, into which small veins entered, the branches re-united to enter the disc as a single vessel. A fourth anomaly seems worth citing (Fig. 4), where a considerable anastomotic branch united the central vein with an aberrant vein penetrating the inner part of the disc. A similar case published two years ago* is shown in Fig. 5. No similar cases on record have met my notice; but a third case has been observed quite recently.

A CASE OF EXTRACTION OF PARTIALLY ABSORBED CALCAREOUS LENS, COMPLICATED BY SYNECHIA POSTERIOR, WITH RESULTING VISION OF $\frac{20}{20}$.

By DAVID WEBSTER, M.D.,
NEW YORK.

On March 15, 1888, Miss Cora C., aged 23, came to the Manhattan Eye and Ear Hospital, having been referred to Dr. Agnew and myself by a New York ophthalmologist.

Her left eyeball was shrunken, tender on pressure, and had, for some time, been more or less painful, while in the right eye were the chalky looking remains of a mostly absorbed crystalline lens, with a discolored and apparently atrophic iris at-

* "Medical News," Philadelphia, September 11, '86.

tached to the membranous mass behind it by strong adhesions. Vision, ability to count fingers at two feet, with good visual field.

Cora gave a history of loss of sight of her left eye from a blow of a whip-lash at the early age of two years. She saw well with her right eye up to the age of fourteen, when a painful sympathetic inflammation set in, producing cataract and causing loss of all but perception of light.

At the age of sixteen she went to Cincinnati and placed herself under the care of an eye surgeon there, who, in reply to a letter from Dr. W. H. Way, House Surgeon of the Manhattan Eye and Ear Hospital, writes as follows: "The girl was then totally blind, one eye being disorganized and cicatricial, and the other cataractous. The story of the girl was that when two years old her father whipped her and injured her eye. Afterward the other got inflamed and became blind. When she entered the clinic she could not go from one room to another without a guide. After an operation and six or eight weeks' treatment she could see enough to take care of herself, distinguish colors, etc. . . . The cataract was liquid (soft) and was freed from its capsule with a needle sent through the cornea. The lens was like that of congenital cataract. I had no hope of the traumatic and cicatricial eye, etc., etc."

A year and a half ago a second needling was done on the right eye by a Buffalo eye surgeon by which the sight was considerably improved.

On March 16th Dr. Agnew enucleated the atrophied eyeball, and, upon opening it, found a small, calcareous lens, and in the choroid, a large, calcific plate.

While the patient was still under ether he performed an iridectomy upon the right eye, removing a portion of the iris outward and slightly upward, that being the direction in which the pupillary margin seemed most free from adhesions.

March 24. There has been very little reaction in the right eye, and the stump of the left is healing kindly.

March 31. The patient is doing well. Doctor Agnew says he will not be in a hurry to operate upon her again.

April 27. Having dropped in cocaine and cleansed the eye

with a solution of the bichloride of mercury, I introduced a Knapp's knife-needle and severed two or three of the adhesions, one of which, in the form of a string, was in such a state of tension that when cut it separated with an *audible snap*. Before withdrawing the instrument I tried to puncture the pupillary obstruction with it, but so tough was the mass that it receded before the point of the knife-needle, and I had to withdraw it without having made an opening in the cataract. There was considerable blood effused into the anterior chamber from this operation.

April 28. The blood has been absorbed from the anterior chamber. There has been very little pain or reaction.

May 14. Having placed the eye under cocaine, I made a small opening through the cornea, near its nasal periphery, with a Græfe's knife, introduced a sharp hook and caught the membranous mass by its temporal border and tried to draw it out of the opening, but the membrane was too thick to come out of so small a wound and so slipped off the hook and was left behind.

May 22. The eye has improved constantly, there being some partially clear pupillary space.

June 6. Having again thoroughly anæsthetized the eye with cocaine, I made a wound at the supero-nasal border of the cornea as for iridectomy, using a keratome bent on the flat, and introducing a pair of back-toothed iris forceps I seized the infero-temporal border of the cataractous mass, and turning it over on itself, pulled it out of the eye, and putting it on the stretch cut it off with scissors close to the cornea. The attached portion of the mass receded leaving a clear pupil. No vitreous escaped. This operation was followed by some pain lasting several hours.

On the fourth day after the operation the patient again complained of pain in the eye. It was soon relieved, however, by the application of iced cloths.

June 18. Fundus normal, no floating bodies in the vitreous, but the remaining portion of the pupillary membrane extends backward horizontally and flops up and down with the movements of the eye. This membrane was thick and tough, and

probably of capsule, lens matter, and plastic exudation, all of which had undergone degenerative changes.

June 22. Vision $= \frac{22}{20}$ with $+ \frac{1}{84}$.

Reads Jaeger No. 1 with $+ \frac{1}{24}$.

June 26. Discharged wearing the above spectacles.

This case scarcely needs any comment. The completeness of the history would make it interesting even if the result had not been so unexpectedly good. In all my experience, extending over nearly twenty years, I never before saw an eye, whose vision had been reduced to perception of light by sympathetic inflammation, have the sight restored to $\frac{20}{20}$ by operative interference.

AN UNUSUALLY LONG EYE-LASH.

BY DR. SAMUEL THEOBALD.

The other day a patient came to the Baltimore Eye, Ear, and Throat Hospital complaining of some irritation about the eye. I was struck with the length of one single eye-lash in the upper lid. This I removed, and now exhibit. It is fully three-fourths of an inch long. The remainder of the ciliæ were of the ordinary length.

The society then adjourned.

The following Discussion, having been accidentally omitted from its proper place, should follow that on page 80:

DR. B. ALEX. RANDALL, Phila. — As bearing upon the question of myopia in growing cataract, the incomplete history of a case may have some points of interest. The patient was a lady 50 years of age, seen four years ago. There were well-marked striae in the periphery of the lens, with hypermetropia of 1.25 D. in the left eye; while reading glasses of the same strength for each eye and the patient's statements gave pretty strong evidence that both eyes had been alike; but that there had been recent and rapid change. She at this time had myopia of 1.25 D.

in the right eye — difference of 2.5 D. between the two eyes. There were unequally shallow anterior chambers and other evidences that the difference was due to swelling of the lens. She was under treatment for some eighteen months with iodide of potassium at intervals — no change occurring in the conditions. After treatment had been suspended for some time she returned with myopia of 4.5 D. in the right eye and unchanged vision in the left eye. While the swelling of the lens had increased, there was no increase in the opacity. Suitable concave glasses brought the vision up to 20/XXV as before. There seemed a strong probability that the eye had become myopic something like 6 D. without any increased opacity of the lens substance.

Dr. Carl Koller, New York.—I have seen myopia of from 1 D. to 3 D. in iritis just as Dr. Mittendorf has observed, but I think that its cause is different from that suggested by him. He suggested infiltration in the vitreous body. I think that it is due to irritation of the ciliary muscle. There is hyperæmia of the ciliary body as well as of the iris, and as the irides are contracted in iritis it is reasonable to suppose that the ciliary muscle also is contracted and that the myopia is nothing more than a phenomenon of spastic accommodation due to inflammation.

Dr. S. D. Risley, Phila. — In a few instances it has seemed to me that the myopia was due to the dread of light and the cramp-like closure of the lids upon the balls in these cases of iritis and choroiditis. Some years ago, I reported a case in which 2 D. of hypermetropia in the vertical meridian had been overcome during the existence of choroiditis. I have seen the same thing in another instance. In numerous instances I have seen patients with iritis show increase of refraction in the vertical meridian.

I would ask Dr. Mittendorf whether or not he tried concave cylinders with the axis horizontal in his cases, and if so whether or not there was any improvement of vision. In my experience, where the error has seemed to be simple myopia, it has been found to be myopic astigmatism.

Dr. S. D. Risley. — I should like to call attention to a fact which others must have also observed, viz.: — the difficulty in these inflammatory cases of keeping the pupil dilated, notwithstanding the most thorough instillation of the mydriatic. You may secure dilatation of the pupil, but in twenty-four hours it will have again contracted. I think that in all forms of inflammation of the eye with photophobia, that the spasm of accommodation will remain in spite of the most vigorous use of

mydriatics. So in these cases of iritis, we may not have entire relief of the spasm of accommodation just as we do not have complete dilatation of the pupil.

DR. JOHN GREEN, St. Louis.—I would in this connection refer again to two attacks of iritis which I experienced myself and which are mentioned in last year's Transactions. The first attack, which was binocular, occurred in 1867; in the second attack, which occurred in 1887, only the left eye was involved. In the first attack after the more acute inflammatory symptoms had begun to subside, and I could look about with a certain degree of comfort, I found that distant vision was greatly impaired and that there was a distinct myopia in both eyes which had not been present before. This acquired myopia, which was equal to about 2 D, was observed at a time when both pupils were still fully dilated by atropia. It continued for a time after the use of the mydriatic was suspended and then gradually diminished, so that by the time the pupils had returned to their normal size, the myopia was decidedly less. The disappearance of the myopia was complete at the end of four or five weeks after it was first observed. Since that time, I have frequently observed the same thing in other cases of iritis, when the conditions for accurate observation have been favorable.

My second attack, in which only the left eye was affected, afforded an opportunity for comparative testing. Myopia, of about 2 D, was again observed, during the acute stage of the disease and under full mydriasis; it continued for about six weeks, and for at least two weeks after the acuteness of vision had become normal. In view of the fact that the myopia attained its maximum of 2 D at a time when the mydriasis was absolute it would seem necessary to reject any explanation based upon the theory of spasm of the accommodation.

That transient myopia is not an uncommon symptom of iritis I feel satisfied, from the fact that I have found it not infrequently during the past twenty years. In commenting upon my communication last year Dr. Wadsworth stated that he also had observed it. In a conversation with Dr. E. G. Loring, a few weeks after our meeting in 1887, he too assured me that he remembered similar cases. The occurrence of this form of symptomatic myopia seems not to have been recorded until I called attention to it a year ago.

DR. W. F. MITTENDORF.—I thought that spasm of the accommodation could be excluded, from the fact that the eyes were under the influence of atropine, which had been used for

weeks. While in inflammation of the eye, it would not have the same effect as in the normal eye, still when the inflammation had subsided somewhat, the myopia was still present. I therefore thought that the myopia was more probably due to advancement of the lenticular system.

In one case there was compound astigmatism. The cases reported are only a few of those that have been under observation and were selected on account of their well-marked character. This case of compound myopic astigmatism had, after the inflammatory stage, slight hypermetropic astigmatism in the opposite meridian.

SPECIAL MEETING.

[At Washington, D. C., Sept. 19th, in connection with the Congress of American Physicians and Surgeons.]

MORNING SESSION.

The meeting which was held in one of the parlors of the Arlington Hotel was called to order by the Secretary at 11 A. M., and in the absence of the President, Dr. H. W. Williams was elected President *pro tem.*

This being a meeting only for the reading of scientific papers, no business was transacted. The following papers were read and discussed:

"Some Tenotomies for the Correction of Heterophoria, with Results" — Dr. Webster.

"Is Astigmatism a Factor in the Causation of Glaucoma?" — Dr. Theobald.

"Treatment of Ulcers of the Cornea" — Dr. Callan.

AFTERNOON SESSION.

"Meridional Astigmatism" — Dr. Jackson.

Report of committee appointed to consider the proposition to designate Prisms according to their refractive powers.

"Acute Cocaine Conjunctivitis" — Dr. Mittendorf.

Exhibition of apparatus for diagnosis of Refraction — Dr. Burnett.

"Blepharo-spasm" (by invitation) — Dr. Koller.

"Monocular Optic Neuritis" — Dr. R. H. Derby.

"Five cases of removal of the dislocated crystalline lens with the bident" — Dr. Pomeroy.

The following members of the Society were present:

Drs. P. A. Callan, D. Webster, Edward Jackson, S. B. St. John, W. F. Mittendorf, D. C. Cocks, O. D. Pomeroy, F. M. Wilson, L. H. Taylor, J. O. Tansley, C. W. Kollock, H. W. Williams, B. L. Millikin, S. Theobald, J. S. Prout, C. A. Oliver, W. W. Seeley, S. O. Richey, H. D. Noyes, John Green, F. B. Loring, R. H. Derby, W. S. Dennett, S. M. Burnett.

Adjourned.

S. B. St. John, *Secretary.*

IS ASTIGMATISM A FACTOR IN THE CAUSATION OF GLAUCOMA?

BY SAMUEL THEOBALD, M.D.,
BALTIMORE.

Before entering upon the consideration of the subject proper of this paper I wish, by way of preface, to state my conviction, based upon somewhat extensive observation, that in astigmatism the direction of the meridians of greatest and least refraction determines to a very marked degree the amount of the asthenopia and other ill consequences which usually attend this form of ametropia. That is to say, an astigmatism in which the meridian of least refraction is vertical, or nearly so, will, as a rule, give rise to very much more trouble — more asthenopia, more headache, and a greater likelihood of pathological changes occurring in the eye — than will one of equal, or even greater degree in which the meridian of least refraction is horizontal, or nearly so. What the explanation of this fact is I am not prepared to say, unless it be, as seems altogether probable, that the former variety of astigmatism is a wider departure from the normal or emmetropic eye than the latter, and for this reason the eye is more intolerant of it, and endeavors more actively and more persistently to overcome it. There can be no question, of course, that the latter variety — in which the meridian of lowest refraction approaches the horizontal — is the more common, and, in my own mind, there is as little question that the non-asthenopic astigmatic eyes, which we all recognize as being by no means rare, belong almost wholly to this group. On the other hand, experience has convinced me that when the boundary line is over-stepped to even a very small degree, when there is the slightest amount of what has been correctly termed astigmatism against the rule — that is, astigmatism in which the lowest refraction is vertical, or nearly so — asthenopic symptoms are almost sure, sooner or later, to make their appearance.

So fully convinced am I of the correctness of this view, that my practice, in dealing with astigmatic cases, has been for some time influenced by it. For example, if I find in an asthenopic patient even a quarter-dioptre of astigmatism of this unusual variety, I feel that I have discovered a satisfactory explanation of the symptoms, and I prescribe glasses for the correction of this slight error of refraction with the utmost confidence that they will give decided relief. If, on the contrary, with so small an amount of astigmatism as this, the meridian of lowest refraction be about horizontal, I hesitate to decide that it is the true cause of the asthenopia; and, if I order correcting glasses, it is not without misgivings as to the result.

Another characteristic of this — as I am sometimes disposed to call it — topsy-turvy astigmatism is that, for some reason, — perhaps, because the effort to accomplish it is more persistent than in the commoner variety — the eye seems to be capable in an eminent degree of hiding it away, so to speak, of rendering it latent through the action of the ciliary muscle upon the lens, so that its detection and its correction by means of glasses are more than usually difficult; and, when we have prescribed such lenses as seem to be indicated, we can never feel sure that there is not an additional portion which we have been unable, even by the liberal use of a mydriatic, to render manifest, and which we shall eventually have to take into account. Still another of its peculiarities is that, even though it be of very low grade, relief from the asthenopic symptoms which it induces is seldom obtained unless the correcting glasses be worn constantly — in distant, as well as in near vision; a fact which I invariably take into account in directing how the glasses shall be used.

Lastly, I may add that by far the greater number of pronounced cases of choroido-retinitis from accommodative strain that I have met with, have been associated with this variety of astigmatism; and, in view of this experience, I need hardly say — and this brings me back to my proper subject — that I have attached more significance to the cases of glaucoma associated with astigmatism which I have met with, and have been less disposed to regard the co-existence of the two as accidental,

because, in almost every instance, the astigmatism has proven upon examination to be of this troublesome sort.

I shall not, in this paper, attempt to discuss the almost innumerable theories of the etiology of glaucoma which have been advanced from time to time. It is, perhaps, safe to say that no one of them contains the whole truth, and that most of them are not wholly at fault. When our knowledge of the subject becomes more complete, we shall doubtless be able to draw a much broader distinction than we now do between the very different conditions which, at present, are grouped under the common name of glaucoma, and then we shall probably learn that these different conditions are by no means to be traced to a common cause. Even with our present imperfect knowledge, I think we are justified in believing that in most cases there are two factors which have to do with bringing about the glaucomatous condition: first, a defect or inadequacy in the drainage apparatus of the eye, which it is likely may be either congenital or acquired, and which must be regarded as the predisposing condition, and, second, an excessive formation of fluid in the posterior chamber of the eye, which probably may be brought about in a variety of ways, and which is to be looked upon as the immediate or exciting cause.

Among the conditions which have been suggested as capable of producing such an undue formation of fluid in the vitreous chamber, hyperæmia of the ciliary body and choroidal coat occupies a prominent position. Now, if there be an anomaly of the eye better qualified to produce this condition of hyperæmia, or which, so far as the ophthalmoscope indicates, does more systematically produce it, than astigmatism — and particularly that variety of astigmatism upon which I have laid especial stress — it has not been my fortune to meet with it. It is in this way, then, that I believe astigmatism acts as a factor in the causation of glaucoma.

The cases which I shall briefly refer to as sustaining this view, I realize are not numerous enough or of such a character as to afford conclusive evidence; but, they are, at least, suggestive, and deserve, I think, not to be dismissed without consideration. Perhaps the list would have been longer if the

subject had not so recently attracted my attention. With but two exceptions they have all been observed within the last twelve months, and all but one have occurred in my private practice. As will appear, they are of two classes, first, cases of pronounced glaucoma in which astigmatism was found to be present, and, second, cases of astigmatism in which there were discovered signs at least suggestive of a threatening of glaucoma. To me, they have seemed of such significance that in future, whenever I encounter a case of glaucoma, not so far advanced as to render such an examination out of the question, I shall feel that I have not done my whole duty until I have carefully tested for the existence of astigmatism, and have accurately corrected any appreciable amount of it which the test may have shown to be present.

CASE I.—Mr. P., age 49. L. eye, chronic glaucoma, with posterior-polar lens opacity. When first seen V of L. eye was 20/LXXX; V of R. eye, 20/XXX (?). L. eye + T 1; R. eye + T 1 (?). Has suffered with neuralgic pains in temple, especially on left side. Ah $\frac{1}{24}$, was found to be present in the L. eye, Ah $\frac{1}{36}$ in the R. eye, the meridian of lowest refraction being exactly vertical in the former, and at 85° in the latter. Correcting glasses were prescribed (Feb. 16, 1888), which brought the V of the L. eye up to 20/XLV (?), and that of the R. eye to 20/XV (?). Subsequently an iridectomy was performed upon the L. eye. Notwithstanding this, however, the glaucoma has progressed in this eye, but the R. eye has done well. When last seen (Sept. 10th) the media of the L. eye were misty and its T + 1. The R. eye, with his astigmatic glass, which he has worn constantly, had, by a very poor light, V = 20/XX (?); exhibited no changes in the fundus suggestive of glaucoma; and had Tn.

CASE II.—Mr. J. P., about 75 years of age. R. eye absolute glaucoma, with secondary cataract; absence of light perception; intermittent ciliary neuralgia; + T 2. L. eye + T 1 (?), with slight contraction of nasal half of visual field, and V = 20/C (?). Examination revealed compound Ah in this eye, lowest refraction nearly vertical. Patient declined operation.

Prescribed eserine for this eye, and for the L. eye ordered + $\frac{1}{72}$c axis 35°, combined with + $\frac{1}{36}$s for distant and with + $\frac{1}{8}$s for near vision. The former improved V to 20/XLV.

CASE III.—G. H., age 74. Chronic, non-inflammatory glaucoma. R. eye + T 1 (?); V = light perception. L. eye + T 1 (?). Found in the L. eye compound Am., lowest refraction vertical. Prescribed spectacles, for constant use, R. eye, plain glass; L. eye — $\frac{1}{72}$c ax. 90°, which left M. = $\frac{1}{15}$ uncorrected; but, this was convenient for his work (varnishing furniture) and was sufficiently satisfactory to him in distant vision. In spite of the glass, however, and the systematic use of eserine, his V, with correcting glass, has declined slightly, from 20/XL (?) in January last, to 20/LX on Aug. 15th. [At a subsequent visit (Oct. 7th), V was brought up to 20/XL (nearly) by increasing the strength of his cylinder to — $\frac{1}{36}$ and combining with it a spherical glass to correct the myopia.]

CASE IV.—Mrs. C., age 61. R. eye, absolute glaucoma; + T 2; with intermittent attacks of pain, notwithstanding she had previously submitted to the performance of an optico-ciliary neurotomy upon this eye. In the L. eye, which exhibited symptoms of incipient glaucoma, compound Am. was found to be present, the meridian of lowest refraction, in this instance, being horizontal. Correcting glasses were prescribed—for distance, L. eye — $\frac{1}{20}$s ⌒ — $\frac{1}{60}$c axis 180°; for reading, + $\frac{1}{72}$s ⌒ + $\frac{1}{60}$c axis 90°. These gave V = 20/XL (?) and J. No. 1 with difficulty. The subsequent history of the case is not known.

Three other cases of astigmatism associated with glaucoma have recently come under my observation, but, as two of them were not seen, and the refraction of the other was not tested, until after the eyes had been iridectomized, and it is very possible the astigmatism may have been due to the operation, they do not deserve to be cited in this connection.

The cases which follow are examples of asthenopic astigmatic eyes in which, although glaucoma did not actually exist, there were present symptoms which, at least, were suggestive of its imminence.

CASE V.—Mr. B., age 52, merchant. Asthenopia of long standing. Ah $\frac{1}{72}$ in L. eye, lowest refraction at 60°; Ah of

same amount in R. eye, lowest refraction at 135°. Anterior chambers very shallow; + T 1 (?) in each eye; suspicious cupping of both discs. Glasses both for near and distant vision were prescribed, and the asthenopic symptoms were promptly relieved.

CASE VI.—Mrs. M. B. Compound Ah $\frac{1}{60}$ in one eye, lowest refraction at 100°; Ah $\frac{1}{72}$ in other eye, lowest refraction at 145°; presbyopia; asthenopia. Each eye had + T 1 (?), and each disc was hyperæmic and suspiciously cupped. There was also in each eye an easily detected venous pulse.

CASE VII.—Mrs F., age 43. Asthenopia and headache of long standing. Ah $\frac{1}{18}$ in L. eye, lowest refraction at 33°; Am $\frac{1}{144}$ in R. eye, lowest refraction at 15°; optic discs very hyperæmic. The more astigmatic (L.) eye showed a marked pulse in the larger retinal veins; in the other eye the pulse was perceptible, but less marked.

CASE VIII.—Mrs. T., age 47. Hypermetropia of high grade in L. eye; compound Ah (H of high grade) in R. eye, meridian of lowest refraction nearly vertical (at 105°); asthenopia and headache of long standing. The astigmatic eye exhibited a well-marked venous pulse, which was not present in the fellow eye. The T of each was above normal.

CASE IX.—Miss D., age 40. Compound Ah $\frac{1}{36}$ in each eye, lowest refraction about horizontal; asthenopia of long standing, more pronounced in L. eye. In the L. eye there was a very distinct venous pulse, and suspicious cupping of the optic disc. In the R. eye the disc was hyperæmic, but not cupped, and there was no venous pulse. Tn in each.

CASE X.—Mrs. K., age about 35. Ah $\frac{1}{72}$ in R. eye; compound Ah $\frac{1}{144}$ in L. eye, lowest refraction nearly horizontal in each; asthenopia, chiefly in more astigmatic (R.) eye, and headaches. The optic disc of the R. eye was extremely hyperæmic, and exhibited a suspicious cupping, which was not present in the other eye.

CASE XI.—Mrs. S., age 33. Marked anisometropia; Am $\frac{1}{18}$ in R. eye; M $\frac{1}{20}$, with Am $\frac{1}{60}$, in L. eye, lowest refraction about horizontal in each; persistent asthenopia, in spite of pre

viously prescribed astigmatic glasses. Each eye showed a suspicious cupping of the disc.

CASE XII.—Mrs. L., age about 38. Asthenopia of long standing. M $\frac{1}{20}$, with Am $\frac{1}{16}$ in R. eye, lowest refraction nearly horizontal; Ah $\frac{1}{36}$, lowest refraction nearly vertical (at 85°), in L. eye. Well-marked choroido-retinal changes at posterior pole of R. eye, with numerous floating opacities in vitreous. Smaller and less numerous opacities in vitreous of L. eye. Has attacks of pain, from time to time, in L. eye and left side of face and head, and has observed a halo about candle flame. While under observation the left disc became somewhat cupped and a venous pulse became established in this eye. The T, however, was never found appreciably above normal in either eye, and the sight of the L. eye remained good. The astigmatism was corrected; small doses of biniodide of mercury with iodide of potassium were given, from time to time, for long periods, and pilocarpine (gr. ij to ʒj) was applied to the eye; and gradually the glaucomatous symptoms, including the venous pulse, disappeared, and when the patient was last seen a period of six months had intervened without any signs of a relapse.

DISCUSSION.

DR. SWAN M. BURNETT of Washington.—According to my observation that kind of astigmatism gives most trouble in which the meridians are oblique. In my paper read before this Society in July, I showed that for the most part the astigmatism with oblique meridians, and particularly that contrary to the rule, was not corneal, but lenticular. I believe also in a great many instances this lenticular astigmatism is due to an oblique position of the lens. This change in the position of the lens may be associated with a crowding of the iris angle into Fontana's space, thus interfering with filtration. Priestly Smith of Birmingham, England, has elaborated this idea.

DR. W. F. MITTENDORF.—My experience coincides with Dr. Theobald's, that the most annoying symptoms are caused by hypermetropic astigmatism, with the axis at 180°. I am sorry to say that my experience with its relation to glaucomatous conditions is not large; I have not paid much attention to it, thinking that heredity has usually played a most important part. But the explanation of Dr. Theobald is undoubtedly one that would suggest the thought that irritation of the ciliary body might lead to glaucomatous attacks.

TREATMENT OF ULCERS OF THE CORNEA.

PETER A. CALLAN, M. D.,
NEW YORK.

The importance of this subject is a sufficient apology for a paper on so well written a theme.

There are, as you well know, many varieties of corneal ulcerations, differing in essential points from each other. Some are accompanied by a train of inflammatory symptoms, while others are quite indolent and torpid in character. Some are very painful, others almost *painless*; some deep enough to cause perforation of cornea and iris prolapse; others of the most superficial nature involving only the epithelium. Some clean in appearance, others ash color, called by different names on account of the fancied resemblances: Onyx, Ulcus serpens, etc.; we find ulcers due altogether to constitutional disease, others traumatic and local in character. Foreign bodies, lid inflammation, pressure or lachrymal sac catarrh are also causes.

The ulcers occurring during childhood and the growing period are phlyctenulæ corneæ. There are exceptions to this, however, severe catarrhal or gonorrhœal conjunctivitis, and ophthalmia neonatorum result in ulcerations at times, severe types of the exanthemata, diphtheria, cerebro-spinal meningitis, and other debilitating diseases are at times accompanied by corneal complications that partake of the nature of sloughs.

The phlyctenular exudations in the cornea owing to too great friction of eyelids, neglect, or improper treatment result in ulcers deep enough to cause corneal perforation. I can only recall one instance during a practice of over 14 years, where perforation took place. It was in the case of a child of five, whose eye had been neglected and the phlyctenular ulcer became quite deep; while to complete matters, the child must needs fall down a flight of cellar steps.

Ordinarily, the treatment of these ulcers needs nothing different from that employed in phlyctenular keratitis. Regulate

the home life, as much as possible, as to food, sleep, and exercise; no dark rooms nor bandages, cocaine and atropine. Yellow oxide salve between eyelids, 2 per cent. to 10 per cent. once or twice daily, coquilles for photophobia, iron and cod liver oil internally. I push the use of the salve whether the eye is inflamed or not, and direct its use for six months after all apparent trouble has passed. Instead of daily, once or twice a week is sufficient. This aids in removing opacity and tends to prevent relapses.

Corneal ulcers due to granulated lids, oph. neonatorum, blenorrhea or foreign bodies demand that we remove the pressure and friction from the cornea, and subdue the inflammatory condition of the eyelids. Ice applications with section of outer canthus of lids without sutures, so as to encourage the bleeding from cut surfaces, is often the best treatment. Astringents pr. n and extreme *cleanliness.*

There is a form of corneal ulceration—neuro-paralytic keratitis (due to trophic changes in 5th nerve) of which I have seen some cases, in fact, I have two now under my care; I have not been able to do them much good. The condition, according to my experience, can last for years, greatly impairing vision, but not impairing the vitality of the globe. Ground glass will express the appearance of the cornea better than anything else I can think of. Those affected are not especially debilitated, but they are middle aged and beyond — I cannot recall any cases under forty years of age.

We have another form of ulcer, due to malaria, syphilis, or some debilitating form of disease. In other words, those not due to lid pressure or erosion. Besides the constitutional treatment which is necessary in all these cases, local treatment is of the utmost importance. Some of the agents most in use are eserine, atropine, cocaine, hot water, hydrarg. bichloride solutions, scraping surface of ulcers, Sæmisch operation, Paquelin or galvano-cautery. In case there is much hypopyon accompanying the ulcer, it should be evacuated; all are in accord on this point. The aim of all treatment is to change the destructive character of the process, prevent extension and perforation of cornea from taking place and bring about repair

of the corneal substance which has suffered. Various forms of cautery have been used to prevent extension of the disease. Dr. Dehume, a Frenchman, is most enthusiastic about the working of the galvano-cautery. In case that the ulcer is accompanied with hypopyon, he plunges the cautery through the ulcer into the ant. chamber, enlarging the opening in cornea in order to permit the pus to escape. As yet he has not furnished us with any statistics as to the number of traumatic cataracts resulting from this practice.

As a safe substitute for all forms of cautery, I have been using during the past year, with satisfaction to myself and benefit to the patient, the following method: I first thoroughly clean the ulcerated surface with a piece of absorbent cotton firmly bound on a holder, using some pressure to clean the surface, then with another piece of cotton, saturated in a solution of Nit. Argenti 10 gr. to one ounce of water I repeat the swabbing process to all parts of the ulcer. The eye must be brought under the full effects of cocaine before any cleansing or swabbing is attempted. By this means, I only attack the ulcerative process; healthy corneal tissue is not impaired, the action of the silver is confined to the ulcer. It may be necessary to repeat this a few times.

The use of eserine even in weak solutions has not proved satisfactory in my hands. I use cocaine and atropine, hot water bathing of eye, and if there is much eyelid irritation use astringents. Bandage the eye. In looking up the literature of this subject, I find that Scarpa, in his book published in 1801, advises the use of Nitras Argenti in solid form, crayons, making an eschar of the ulcer. Sæmisch's operation, published in 1869, was essentially performed by Monteath early in the century.

Prognosis. In subjects not passed beyond middle age, the chances are good, but in the old, feeble, and debilitated, a certain number of eyes will be lost, through corneal ulcers, notwithstanding our most strenuous endeavors.

DISCUSSION.

DR. TANSLEY.— I am surprised to hear Dr. Callan mention cocaine in the treatment of ulcerative keratitis; my experience

with it has been rather discouraging, used in that way, and I cannot think it acts beneficially. The reaction is too great as a rule, and it often has caused more irritation of the conjunctiva than I desired.

When cocaine first came out I thought we had the "beau ideal" for keratitis with photophobia but an extensive trial satisfied me that its action was injurious in all inflammatory affections of the ear or eye.

The doctor says also that he does not use solutions of eserine. In my hands weak solutions of eserine have acted most kindly in all cases of phlyctenular ulcerations.

DR. WILLIAMS of Boston.—I first studied ophthalmology 42 years ago, and my experience extended over several countries at that time. I saw then the methods which still savored somewhat of the period when harsh remedies were in vogue, such as dusting the eye with calomel. This gave more or less pain. We considered it was only because the disease was so great, and we did not attribute it to the remedy. I cannot help feeling that the remedy, which was the routine treatment in Vienna, did cause a great deal of suffering to the children. I don't mean to say that it does in all cases, certainly it does in some. It is also liable to accumulate in masses, and become a source of injury to the eye. Then the nitrate of silver was used in very strong solutions. On my second visit in 1863, that was absolutely the routine treatment with Græfe and with many other ophthalmologists. Ten grains to the ounce was not considered a strong solution. Græfe used it in considerable strength. He used it in cases of ulceration of the cornea as a routine treatment; neutralizing it afterward by a solution of chloride of sodium. Then the treatment by atropia came into vogue, which was a great improvement as far as the physical suffering was concerned, because it did not cause the great pain that even the weak solutions of nitrate of silver caused generally, and in so far it seemed to be an advantage. My own experience, however, from the time I began to practice, led me to discard atropia in ulceration of the cornea in young children, for the very fact of photophobia was a reason for not using a mydriatic which allows an influx of a vast amount of light on the sensitive retina, except in the cases where central perforation of cornea is threatened. I never felt assured that it acted as a sedative to the cornea, as considered by some, on the other hand, it did increase the photophobia and thus increased the friction of the lids on the corneal ulcer, by the extreme contraction of the orbicularis occasioned by the photophobia.

When the myotics were brought into use, within a recent period, I saw at the clinique of Prof. Donders at Utrecht, the first application, and had the application on my own eyes, of the extract of calabar bean some of which was sent to him for trial. I thus had an opportunity of watching the effect of the remedy from its early inception. It seemed to me that this would theoretically give an extremely valuable agent in these cases, by diminishing photophobia, by its contraction of the pupil and shutting off of light. I was extremely satisfied with the results of that treatment, especially in the more convenient form of solutions of eserine and of pilocarpine. I think it important to keep the cornea clean and to wash away all the secretion that accumulates in the eye, and for this purpose have used solution of borax (10 grains to the ounce) dissolved in camphor water, which seems also to act as a sedative to the cornea. I used the borax with the pilocarpine or eserine and had very advantageous results.

Speaking of eserine as compared with pilocarpine, I found in application to my own eyes, that extract of calabar bean and eserine often caused a neuralgia of the supraorbital nerve after application. That was one reason why I prefer the use of pilocarpine, which has a sufficiently myotic effect. Children did far better under these applications than under the atropia treatment, and better than under the treatment with borax solution without any atropia having been used. I think that the treatment of these ulcerations of children is not essentially different from the treatment under other circumstances where the injury is traumatic, or is caused by general disease; for instance, where it comes on as sequel of exanthematous disease. I think it will apply well in those cases, where there is loss of power in the fifth nerve, so that the orbicularis does not act and the cornea is liable to become ulcerated from exposure to dust and wind, I find that a solution of borax or some similar thing answers better than anything else to cleanse and lubricate the exposed cornea.

In the secondary ulceration from friction by granulating lids I have been satisfied with the results of combining with the local treatment of the cornea pretty active treatment of the granulations, so as to get rid of what caused the friction.

I come to one other terminal item of my experience,—the introduction of cocaine—I think it extremely beneficial in the treatment of these cases. It seems to me capable of superceding other treatment in a large number of instances. It diminishes the sensitiveness of the cornea and the photophobia, and lessens the discomfort and injury from the friction of the lid;

seems to diminish the calibre of the vessels and has a favorable curative action. I have not usually found it necessary to use pilocarpine in connection with it. With cocaine alone I have been extremely well satisfied; but I think the combination would be extremely serviceable in many instances.

I have seen such a variety of treatment for so long a period, I thought it worth while to compare my own observation and results, with those of others, in regard to different modes of procedure.

DR. MITTENDORF. — I think there are two forms of ulcerations where the electro-cautery is undoubtedly of the greatest benefit—(*a*) sluggish ulceration; (*b*) that in which the ulcer has a tendency to spread. In both the electro-cautery has done such charming service that I think it should be used by everybody in certain cases. I think I have saved many eyes that otherwise would have gone to destruction.

Another point is the frequency with which some physicians will use sugar of lead preparations, especially in the central part of America, where this is so constantly in vogue that I recall at least five or six patients coming from the south with such dense opacities of the cornea that I had to scrape off dense firm layers of this. I think the more we can make the profession understand what a dangerous preparation this is, the more good we shall do.

DR. WILSON. — I would like to inquire if any of the gentlemen have used or are using antipyrine, administered internally for photophobia and pain in adults. Antipyrine was first used to reduce temperature, and later for headache. I first administered it for the relief of pain in the head, but was surprised to find it also relieved pain in the eye. I have not administered it enough times to give any experience, but I have been much gratified when I have given it. I have given it in five-grain powders to be taken once an hour, or once in two hours, until relieved.

DR. TANSLEY. — Permit me to rise a second time and answer Dr. Wilson's inquiry, and say that for the past year I have treated all my cases of pain in the eye from ulceration of the cornea and iritic inflammations, with antipyrine, and with most excellent results. I use it in place of opium preparations, and thus avoid the bad results of the latter drug. I usually give it in doses of ten or fifteen (10 or 15 gr.) grains, and repeat in one or two hours if necessary. I never have had to give more than three doses, and never had any bad results, although some of my friends consider it a dangerous drug.

I recently treated a case of bad and painful iritis in a lady who had had the confirmed opium habit for the past ten or fifteen years. I was able to control all pain and procure most refreshing sleep by the use of antipyrine, and by discontinuing the opium, was able to get a widely dilated pupil with my atropine solutions, which I was not able to obtain while she was taking the regular amount of opium.

If any one will use it in the severe pain of iritis, they will be charmed with the result. The ability of antipyrine to allay pain, stop headache, quiet hysterical nervousness, and procure sleep where the patient has or has not been in the habit of using opium, makes it a most valuable drug, and the fact should be widely known, because it does away with the use of the hypodermic which is much too common in the hands of many of us.

DR. WILLIAMS. — In supraorbital neuralgias I have never used a larger dose than ten grains, but had that repeated in an hour if necessary.

I forgot one thing about cocaine. I think that advantageous in just these cases: I have been in the habit of advising a 2% solution to be put into the eye once in five minutes for half an hour if necessary; that will relieve the suffering and pains of iritis. I have seen case after case since I have had cocaine on my list of remedies where I have used it in old cases of rheumatic iritis, where the patients had attack after attack; they have had often to take three or four doses of opium or morphia in the night to quiet the nocturnal supraorbital pains, and in nearly every one of these the use of cocaine in this manner — 2% solution once in five minutes — will control these severe supraorbital pains. In a few cases where the 2% solution was not sufficient, I have used a 4% solution. I have found it answered extremely well; so that I have not found it necessary to give antipyrine in so many of these cases.

I forgot to say that I do believe in using atropia in cases where corneal perforation is threatened; but the frequency of that has been exaggerated, I think, and the cases were really very few where we needed to resort to treatment of that kind. I agree with the gentleman as to the value of antipyrine.

DR. LEWIS H. TAYLOR. — I want to add to what has been said upon the use of antipyrine, a remark upon one case in which I employed it a few days ago with very happy result in relieving pain in the eye. I here gave fifteen-grain doses every three hours until the pain was relieved. In this case there was considerable fever, an elevation of more than 2°. I have used it

frequently in similar cases, and have never, as yet, had occasion to regret its use.

I would like to say a word in reference to the galvano-cautery in treatment of these ulcers. I recall the time when I first used it with some fear and trembling, almost afraid to make the application, and yet doing so with excellent results. I have since used it occasionally, but never for sluggish ulcerations. My use of it has always been in those cases where there was a decided tendency for the ulcer to spread, where there was some formation of pus, and frequently hypopyon. In such cases I believe it to be a very efficient remedy.

DR. WILSON. — My reason for giving so small doses was that there have been a considerable number of cases reported where single doses of fifteen grains have produced alarming results. I have known one or two personally; and as five grains once an hour seems to relieve the pain, I give it in this way altogether now.

DR. CALLAN. — With regard to the use of the galvano-cautery: I have used it freely and carefully, and I have done damage by it. I have increased the opacity, naturally resulting from ulcer, by destroying healthy tissues, which it is impossible to avoid. My object in substituting a simpler remedy is to avoid that and have a safe remedy, which I have found to act like a charm.

I don't altogether agree with the same treatment applying to treatment of the corneal ulcers in young and old. Phlyctenular ulcers, which only occur in youth, should not be bandaged. Photophobia is increased; the eye does worse with than without it. If I am not sure of my patient, I put in atropine with the yellow oxide, mix it so I can see the effect on the pupil. Bandages should not be used in the cases of lid-erosion or lachrymal sac troubles; the proper place for bandages is in those constitutional ulcers, where the lid should be kept quiet.

With regard to the novelty of the treatment: it is not new. I use 2% solution. I localize it. To older people put it in *ad libitum* into the eye. I localize it to the ulcer, and no more; and I claim no more than I have said for it.

SYMMETRICAL ABERRATION OF THE EYE.

(*Meridional Astigmatism.*)

BY EDWARD JACKSON, M.D.,
OF PHILADELPHIA.

From among the various defects of the dioptric media, grouped by Donders under the one name, "normal irregular astigmatism," it seems of practical importance to isolate and habitually study alone the defect, or factor of defect, to which attention is here directed. To facilitate such separate study, I propose to designate as *Symmetrical Aberration,*[1] *that defect of the dioptric system of the eye which causes the rays of an incident pencil piercing the cornea in the same meridian, but at different distances from the axial ray, to intersect the axial ray at different distances behind the cornea, while rays piercing different meridians of the cornea, but at the same distance from the axial ray, intersect it at the same point.*

A similar fault in the surfaces of a spherical lens causes what is known as spherical aberration, in which the rays, which pass through the lens near its optical center, are focused farther

[1] The term originally proposed was "Meridional Astigmatism;" astigmatism because Donders had included the defect with irregular astigmatism, and meridional because it is essentially a want of mutual adaption of the curves of different parts of the same meridian, to focus at a single point, the rays piercing it. The criticism of the term, offered by Dr. S. M. Burnett and Dr. John Green in the discussion which followed the reading of the paper, and which is appended, led the writer to carefully reconsider the subject, and to adopt the term here used; and feeling the importance of avoiding any unnecessary multiplication of terms, he has ventured to substitute the one so adopted for the one previously used in preparing this paper for the press The defect in question is certainly a part of the monochromatic aberration of the eye, and it is symmetrical, with reference to the axis of the incident pencil. The term "aberration" is older than "astigmatism," and although Donders would include all the monochromatic aberration of the eye under astigmatism, I know of no good reason for excluding the older term from Ophthalmology, when it may be used to designate a defect so different in its practical bearings from astigmatism, either "regular" or *truly* "irregular."

It is not to be understood that in any eye all of the aberration is symmetrical; there is always present, in addition to the symmetrical aberration, a certain portion that is asymmetrical; just as we never find an eye presenting regular astigmatism without an appreciable amount of irregular astigmatism; and for practical purposes, just as it is of importance to separate from the whole astigmatism that part which may be corrected by cylindrical lenses, and call it regular astigmatism; it is important to consider alone that part of the total monochromatic aberration to which the term symmetrical properly applies; and as astigmatism without any qualifying adjective is used when regular astigmatism is meant, aberration alone may be taken to indicate symmetrical aberration.

from the lens than those incident at points more remote from that center. On account of this, a spherical lens is "stronger" toward the margin, "weaker" toward the center. In the 12 D. lens of the ordinary trial-case the margin acts as a 13 D. lens.

There are two *forms* of symmetrical aberration. In one, which I have called the *positive*, and which is the more common, the marginal refraction is stronger than the central, as it is with the spherical lens; that is, the center of the pupil is more hyperopic, or less myopic than the periphery. In the other, rarer, form, which I have called *negative*, the reverse obtains, the eye being less hyperopic, or more myopic for rays entering through the center of the pupil than for those coming through the margin.

Symmetrical aberration may be studied subjectively, with the refraction ophthalmoscope, or by skiascopy.

The subjective method has been employed by Young, Helmholtz, Donders, and others. To the descriptions of the method by the above named writers, and by Landolt (*Refraction and Accommodation of the Eye*), Burnett (*Treatise on Astigmatism*), and Exner (*Græfe's Archiv.*, 1888, *page*), I have nothing to add. So far as I have read, those who have tested their eyes in this way have all discovered the positive form of aberration, the distribution of light being similar to that caused by spherical aberration.

To recognize and estimate aberration with the refraction ophthalmoscope, a convenient point in the fundus of the eye is selected, and its refraction measured; first, as viewed through the center of the pupil; then as seen through some part of the periphery, the difference between the two determinations indicating the amount of aberration.

But it is by skiascopy, the "shadow-test," that symmetrical aberration is mainly to be studied. The other methods, though of some scientific interest, are of no practical importance for ordinary clinical work. If a black dot on white paper be looked at through a strong convex lens, say the 20 D. lens of the trial-set, the dot being first placed closer to the lens than the focus conjugate to the position of the observer's eye, an erect image of the dot is seen. Upon gradually withdrawing the dot

from the lens this image becomes larger, and progressively less distinct, until as the conjugate focal distance is reached it becomes so diffuse and faint as to be entirely lost. But before the focal distance for the center of the lens has been reached, the focal distance of the more refractive margin of the lens has been passed, and there appears an inverted image of the dot in the form of a ring; or segment of a ring, if the dot and the observer's eye are not kept on the principal axis of the lens. This ring is at first extremely faint and indefinite, but becomes more strongly marked and distinct as the dot is withdrawn; and when the conjugate focal distance for the center of the lens has been passed, and the erect image has entirely disappeared, this inverted image contracts to a dot seen through the center of the lens.

In skiascopy (using the plane mirror) we have the black dot of the above experiment replaced by the small illuminated area of retina, and the lens replaced by the dioptric media of the eye, with a convex lens added, if needed to make the eye myopic. Placing the observing eye within the conjugate focus of the retina (the point of reversal) of the observed eye, an erect image of the illuminated area is perceived, that grows larger and fainter as the point of reversal is approached. Now, if symmetrical aberration of the positive form be present, we will have a reproduction of the phenomena studied with the lens and dot. Before the erect image has entirely faded away, as the point of reversal for the center of the pupil is approached, an inverted image of the light area appears as a luminous circle at the margin of the pupil, which grows brighter and encroaches more and more on the central area of the pupil, where the erect image is fading away; and after the erect image has disappeared, and the point of reversal for the center of the pupil has been passed, the inverted image comes to be seen in every part of the pupil. By measuring the distances from the eye to the points of reversal for the center of the pupil, and for the margin, the refraction of each is determined, and the difference between the two states of refraction is the aberration. Where regular astigmatism exists, it is well to correct it before attempting to estimate the amount of aberration. Most eyes, too,

present, in addition to the symmetrical, a noticeable amount of asymmetrical aberration, causing corresponding asymmetry of the ring of light at the pupillary margin.

Frequency and Amount.—The following table gives the relative frequency of different amounts of symmetrical aberration in 100 eyes tested consecutively, in which full vision was obtainable by spherical and cylindrical correcting lenses:

Symmetrical Aberration,	Negative,	1. D.	- -	2
" "	"	0.50	- -	7
" "	either way,	0.25 or less,	-	13
" "	positive,	0.50	- -	44
" "	"	1.	- -	19
" "	"	1.50	- -	9
" "	"	2.	- -	4
" "	"	3.	- -	2

There are very few eyes that do not show a perceptible amount of symmetrical aberration certainly less than one per cent. As with other kinds of ametropia, the two eyes, as a rule, present about the same amount of defect; but to the rule there are exceptions. I do not remember to have noticed the positive form in one eye, and the negative form in the other eye of the same individual. High degrees of aberration do not appear to be associated with especially high degrees of ametropia of other kinds.

A fact not indicated in the above table is, that high degrees of symmetrical aberration, of the negative form, are frequently caused by the lens-changes, that occasion senile myopia, so-called "second-sight," and run on to the formation of nuclear cataract. Sometimes the increase of refraction may occur equally in all parts of the lens, but usually it will be found to be confined to the nucleus, the refraction at the margin of the dilated pupil remaining substantially unchanged. In such cases I have observed a negative aberration of three to five dioptries.

Conical cornea causes the highest degrees of negative symmetrical aberration; but high degrees of either form will, under certain conditions, give that peculiar arrangement of light and shade in the pupil which has been regarded as characteristic of

conical cornea. To obtain this peculiar play of light and shade, the observer's eye should be comparatively near the point of reversal for the margin of the pupil, and, comparatively, far removed from the point of reversal for the center of the cornea. When this is the case the illuminated area will seem to move rapidly near the margin of the pupil, and slowly at the center; so that the light area will appear to wheel back and forth about the center of the cornea, or apex of the cone, with every movement of the mirror. It is probable that some cases heretofore supposed to be of conical cornea, of such low degree that the conicity was not apparent when the eye was viewed in profile, are really examples of the positive form of symmetrical aberration, highly hyperopic at the center of the pupil and nearly emmetropic at the margin.

The usual seat of the defect is the crystalline lens, the influence of which is generally toward positive aberration. On the other hand the extreme margin of the cornea is flattened, but this flattening does not usually extend over the margin of the dilated pupil sufficiently to cause a negative aberration.

The practical importance of symmetrical aberration does not lie in any lowering of visual acuteness that it commonly causes. In the majority of cases the statement of Donders, as to "normal irregular astigmatism," is correct, that "The acuteness of the power of vision suffers very little under it." In the large majority of eyes it is probable that the perfect correction of all aberration would cause no perceptible improvement of visual acuteness, as determined in a full light; and in the cases in which it does impair visual acuteness, the impairment is not proportioned to the degree of aberration. It is well-known that, in irregularities and partial opacities of the cornea or crystalline lens, a small area of regular surface, and perfectly transparent media, will give good vision, no matter how irregular and opaque other portions may be; and if there be a portion at the center of the pupillary area, free from aberration, while the refraction of the parts around this varies so that the light entering them is generally diffused upon the retina, the image produced by the central portion will be distinct and clearly recognizable,

although the light going to form it be but a small proportion of all that enters the pupil. It is, rather, where the aberration is of low degree, so that the light which does not go to form the definite image is massed closely around it, instead of being evenly diffused over a wider area, that the perception of the image is most interfered with, the visual acuteness most impaired.

It may readily be conceived that aberration, causing different kinds or different degrees of ametropia in different parts of the pupil, might add to the difficulty of determining refraction, and render uncertain the results obtained, especially when the pupil is widely dilated. I am satisfied that many cases of difficulty of determining the exact refraction, which in former years I ascribed to stupidity on the part of the patient, or imperfect mydriasis, were really instances of troublesome aberration; and I suppose the same to be true of the experience of others. Where the patient's answers, or the results obtained by various tests, seem contradictory, this defect should always be suspected.

The way in which aberration interferes with skiascopy is readily understood from the description of the method of recognizing it by the "shadow-test." Of course the portion of the dioptric system to be accurately corrected is, in general, the portion which transmits rays through the undilated pupil; but as the point of reversal for the central portion of the pupil is approached the light area in it becomes very faint, and the direction of its movement difficult to determine, while the brighter ring or segment of light near the margin of the pupil, constituting a more noticeable object and often moving in the opposite direction, is liable to lead the observer into error, unless he be on his guard against it.

In measuring refraction with the ophthalmoscope, it is only needful to bear in mind that apparent variableness, apparent astigmatism, apparently contradictory results, may be due to aberration and the looking at different times through different parts of the pupil.

With the trial-lenses, working in a good light, even with the pupil fully dilated, aberration does not, in most cases, prevent

the selection of the proper correcting lens. In most eyes there is a considerable area at the center of the pupil, over which the refraction is uniform, which transmits the light that forms the retinal image, and beyond this, the aberration rapidly increasing toward the pupillary margin, prevents the formation of a clear image on the retina by the aid of any lens other than the one correcting the central area; but in some eyes the aberration begins very close to the center of the pupil and the change of refraction toward the margin is more uniform and gradual; so that the light entering through the margin of the pupil may, by its proper correcting lens, be almost as perfectly focussed on the retina as that which enters near the center of the pupil can be by the lens which best suits it. In such eyes the determination of the refraction by the use of trial-lenses, unsupplemented by skiascopy, is necessarily puzzling, difficult, and unsatisfactory.

Positive symmetrical aberration is present in a large majority of all eyes, and in a considerable proportion its influence is such that they are able to get their best vision with a distinctly stronger convex lens, or weaker concave, when the pupil is contracted than when it is dilated. In my own eyes the difference is quite 0.25 D. in this direction. I have seen young persons who, when the pupil was contracted, had full vision with a convex lens 0.50 D. stronger than they would accept with complete mydriasis and paralysis of accommodation. While among those who by age have all their hyperopia rendered absolute, such a difference between the dilated and the contracted pupil is not rare. The only record of a similar, previous observation, is by Lord Rayleigh, who states (*Encyclopædia Britannica*, Optics) that in a dark room he is distinctly short-sighted, although in a good light his eyes present no trace of such defect. But it is very common for persons wearing convex glasses that fully correct their hyperopia, to complain that the glasses interfere with distant vision when the light is dim; and this complaint continues long after the period of adaptation has elapsed. It would appear that in a dim light it is of more importance to utilize a larger proportion of the rays entering the dilated pupil, than to secure accuracy of focus for those entering the central portion; and the larger part of the rays is utilized by striking a mean be-

tween the focus for the center and the focus for the margin of the pupil. This makes the eye, when the aberration is positive, less hyperopic, or more myopic, by a dim light.

There is a class of patients who have hyperopia and suffer eye-strain, especially at near work and during exposure to bright light; that is, when they have to see with a contracted pupil. And these are not fully relieved, even by wearing constantly the full correction for their hyperopia, as determined under a mydriatic. In the few cases of this kind, occurring since my attention was directed to the subject, I have found the refraction markedly influenced by positive symmetrical aberration. They were all notably more hyperopic when the pupil was contracted. Now we know that an emmetrope, placing temporarily before his eye a weak, say 0.50 D. concave lens, will feel much more inconvenience from the additional stress of accommodation it occasions, than will the hyperope who, by reason of his hyperopia, is compelled to sustain the same stress of accommodation continuously. These patients who, with a contracted pupil are more hyperopic, work under much the same disadvantage as the emmetrope with a concave lens before his eye, and may reasonably be expected to suffer more than those who have an equal amount of constant hyperopia. They may be relieved by wearing stronger lenses for near-work, and when in a bright light; or the stronger lenses may be worn all the time if the patient prefers imperfect distant vision by a moderate light to the frequent changing of glasses.

In negative symmetrical aberration, so uniform and involving the center of the pupil sufficiently to influence the choice of a correcting lens, when the pupil was contracted, the patient would not be able, even with the accommodation fully relaxed, to get full distant vision with the glass that allowed him full distant vision through the dilated pupil. A hyperope with this kind of aberration could never become accustomed to use without a mydriatic, the lens that fully corrected his hyperopia with a mydriatic. I do not doubt but that such cases occur, although from my experience in the full correction of hyperopia, as determined under a mydriatic, they must be very rare; and it seems to me that an understanding of this subject of negative symmetrical

aberration will render superfluous the supposition of a "tone of the ciliary muscle" that can be overcome by a mydriatic, but returns when the mydriatic passes off, that has been invoked to explain these cases.

DISCUSSION.

DR. BURNETT. — The paper interests me very much, because it shows that Dr. Jackson has been working in the same line as I have myself for some time. At the outset, however, I think I should differ from him in regard to nomenclature. I was much misled by the title of his paper. He calls it Meridional Astigmatism. This it may be in a certain way; but if I get the meaning of his paper, it is only a difference of the refraction between the center of the cornea and the periphery. That couldn't, I think, be strictly called astigmatism, as we now consider it. I have gone into the matter somewhat in my treatise on astigmatism, and have shown that, as a general rule, the aberration, in any one meridian, results from the meridian being in the form of an ellipse, and that the difference between the refraction at the center and periphery of this meridian may be very considerable.

Prof. Harkness has made some calculations as to the form of refraction of the horizontal meridian of the cornea from data taken from Mauthner's book. He shows what the monochromatic aberration of one meridian of the human eye is. Aubert has made some very extensive observations upon that point also, and published them in *Pflüger's Archives.* He shows that there are two distinct areas of the cornea — a central and a peripheral, — whose curvature appear to be different.

While not calling in question the results of the observations of Dr. Jackson, I think he has given a wrong name to it.

DR. JACKSON. — Perhaps I do not understand just what Dr. Burnett means by "meridional astigmatism," but I fail to see that we are entirely at variance as to the phenomena to which we would give that name. Doubtless we approach the subject from different directions. My data have been the results of objective investigation with the shadow-test, dealing with the total refraction of the eye, and not with that of the cornea or lens separately.

DR. GREEN. — In connection with Dr. Jackson's lucid discussion of a class of refractive anomalies, hitherto but little studied, I would take exception only to the name which he proposes to give to it. Analogy would seem to require that we designate the phenomenon in question by the name "aberration" rather

than "astigmatism." Spherical aberration is, of course, a particular case which at once suggests itself; but in the eye we have to do with a great variety of possible deviations from the ideal form of the arc, by whose revolution the refractive surface is generated; hence we should seek for a qualifying adjective comprehensive enough to include all such possible cases. The name "astigmatism" should, I think, be restricted to its two familiar applications: regular and irregular astigmatism, as defined by Donders.

DR. JACKSON. — The discussion of the name for this defect is timely. We may learn from experience with the shadow-test, the importance of having a good name from the start. For its likeness to spherical aberration, I called it, for a time, spherical astigmatism. It has heretofore been included with irregular astigmatism, and comes within the general definition of astigmatism as "a defect of refraction which renders a homocentric pencil of rays heterocentric." I called it "meridional" because the inequality of refraction was between different parts of the same meridian.

DR. GREEN. — The objection is based simply on the fact that the word "astigmatism" is now in common use in a comparatively restricted meaning. I do not think it admissible to extend that meaning so as to cover the phenomena now under discussion.

REPORT ON THE DESIGNATION OF PRISMS BY DEGREE OF REFRACTIVE POWER.

The useful quality of a prism is its deviating, or refractive power. In designating a prism we always desire to designate one with a particular refractive power. The present system, of numbering by the refracting angle, allows the refractive power to vary, with the index of refraction of the glass of which the prism is made. The index of refraction of optical glass varies from 1.51 to 1.72, and that of crown glass, from which prisms are usually made, varies from 1.51 to 1.55. Hence prisms of the same refracting angle, of the same number according to the present system of numbering, must vary 6 per cent. and might vary 40 per cent. in refractive power. Examination shows that variations of 20 per cent. or 30 per cent. are common in the prisms of our trial-sets.

Extreme variations may be due to inaccurate grinding, but it is not easy to prove it. To test a prism as now numbered, by neutralization, is not admissible scientifically, and, in the present state of our trial-sets, is a very loose way practically. Were prisms numbered according to their refractive power, that is by the number of degrees of "minimum deviation" they produce upon rays of light passing through them, the exact strength of those in the trial-set could be ascertained by the method given below; and others could be tested by neutralization with these.

To ascertain the "minimum deviation" produced by a prism: Place a convex spherical lens so that it will receive rays from a distant point of light, lying in its axis, and focus them on a screen perpendicular to that axis. Place the prism to be tested so that it covers half the lens, and with the plane which bisects its refracting angle perpendicular to the axis of the lens. This causes a second image of the point of light to appear on the screen. The distance between corresponding points of the two images will be the linear deviation, or tangent of the angular deviation with a radius equal to the distance from the prism to the screen. The following table gives the linear deviation for different degrees and half-degrees according to the proposed system of numbering, when a 2 D. convex spherical lens is used, and the prism is placed just one half-metre from the screen.

Degrees of Deviation.	Distances between images.		Degrees of deviation.	Distances between images.	
0.5	4.3	millimetres.	5.	43.7	millimetres.
1.	8.7	"	6.	52.5	"
1.5	13.1	"	7.	61.4	"
2.	17.4	"	8.	70.1	"
2.5	21.8	"	10.	88.1	"
3.	26.2	"	12.	106.3	"
3.5	30.6	"	15.	133.9	"
4.	34.9	"	20.	182.	"

The main objection to the adoption of a new system of numbering glasses is, usually, the temporary confusion due to the use of both systems during the transition from the old to the new. But to express deviations of the visual axis the two kinds

of degrees are already in common use. Degrees of deviation were used by Donders, and by some other writers, exclusively; they have the same significance as degrees used in other departments of science and art. Degrees of refracting angle are used by some recent writers, our prisms being designated by them. The use of two kinds of degrees, having very different values, causes confusion and uncertainty in the literature of the subject. We cannot avoid degrees of deviation; but, by numbering our prisms by degrees of deviation, we can get rid of degrees of refracting angle, leaving them only to be considered by the optician in connection with the index of refraction of the glass of which he makes prisms.

In view of the facts bearing on this matter, we recommend the Society to endorse the following propositions, and urge their universal adoption as rapidly as may be practicable:

1. Prisms ought to be designated by the number of degrees "minimum deviation" they produce.

2. Where intervals of less than one degree are desired, half-degrees and quarter-degrees should be used.

3. To indicate that degrees of deviation are meant the letter d. should be added: thus prism 2° d. will indicate a prism that produces a minimum deviation of two degrees.

EDWARD JACKSON,
SWAN M. BURNETT,
HENRY D. NOYES.

DISCUSSION.

DR. GREEN. — As I understand one of the resolutions it is that we appeal to the body of manufacturers of spectacle glasses, from which trial cases are made up, to furnish us with prisms numbered according to their deviating power. What does that mean? It means that the manufacturer shall test every batch of glasses, and shall modify the angles of his prisms to conform to variations in the refractive index of the particular glass which he uses. We have tried that experiment in another way. We used always, in the matter of spherical glasses, practically to accept what the manufacturing opticians gave us, namely, a glass which, in the double-convex or concave form, had a radius of curvature equal to the numbers which we prescribed. We

have changed from that system to the metric, and we now prescribe glasses according to their principal focal length. Thus in prescribing a glass of one dioptric, we mean one whose principal focal length is exactly one metre, etc., but the manufacturers actually furnish us with glasses varying considerably in focal length, although possibly exactly equal in radius of curvature. In other words, the maker provides his set of tools for grinding spherical surfaces, and, assuming that these tools remain unchanged by wear, every variation in the refractive index of the glass necessarily entails some variation in the focal length of the lens. Whenever it is a question of nice work, whether in the case of spherical or cylindrical lenses, we take the precaution of testing them by a direct measurement of the principal focal length. In the case of lenses with curved surfaces the opticians have certainly not taken any step to adjust the radius of curvature to the variations in the refractive index of the particular glass used; nor do I think they would do any better in the matter of prisms. I think we should get in the market prisms nominally of 1°, 2°, etc., deviating power, but with just as great differences in the actual deviating power as we now find when we order prisms of 1°, or 2°, etc., angle. We, of course, in our work, consider angles of deviation all the time, and we calculate the required angle of the prism by an almost unconcious mental act. The resolution does not seem to me to be of importance enough to make it worth the while to try to lay down rules for the manufacturers of glasses which they will practically ignore.

Dr. Burnett.—As the third member of the committee I would like to state the reasons that influenced me in signing the report. They were these: We had a method of numbering prisms which was unscientific and inaccurate. I believe there is nobody that will deny that proposition.. We have a method here offered which is accurate and scientific and which expresses what we want in practice. As between those two I don't see how any one can have any hesitation in adopting the one which is scientific and accurate and at the same time practical. I don't think, moreover, this society will do itself any harm in going before the public in a proposition of this kind, even if it is a small affair, as has been intimated. I think if we are accurate in small things it will suppose we are accurate in things of greater importance. I don't see that the society has anything whatever to lose in the adopting of this proposition.

Dr. Noyes.—My feeling is that this matter is rather one which may be decided by considerations of utility and practical

value, than one of strictly scientific correctness. All the statements made in the report are, of course, accurate and correct; and as a scientific assertion the whole report might properly be signed not only by myself but by the members of the society at large, because it is true, as the chairman has stated, that an error arises in the effect of lenses from the changes which you are liable to find in the refractive index of the glass that you use. It appeared to me upon consideration that, if we do issue the report and a recommendation of this kind, it may be judged that we are attempting something over nice, which will not receive any valuable consideration and attention — as much as we would like to have this society's recommendations receive from the public at large; because what we do as a society is the embodied wisdom of American Ophthalmologists, and if we take a step of this sort we don't want to put ourselves in the attitude of announcing ourselves upon things many would regard as trifles. Let me explain. In the first place the error by this difference in refractive degree is, for the most part, of unimportant proportion. We deal with small degrees. The deviating power of the prism, if you assume its refractive power to be 1.50, is one-half the angle of the prism; and that makes a rough way of coming at the result of deviation; but when the refractive index rises to 1.54, which has been assumed by some writers as being the customary refractive index, if we come to 1.54 it results that the deviating power of the glass is increased by a proportion which is about $\frac{1}{12}$; that makes it $8\frac{1}{2}$ per cent. and the calculation is easy. What does that amount to? In a prism of 6° the amount will be divided between the two eyes, and you therefore have to deal with a prism of 3°. That is what is for the most part a very liberal allowance for patients that happen to wear prisms continually. I have gone so high as a prism of 7° for each eye, making a total correction of 14. I found no difference between the glasses for trial case and the glasses he received from the optician. The amount of error is practically of no moment. It may be remarked if you are determining the muscular power of the eye, say the adduction, which may reach 60°, you get an error of 5° between an index of 1.50 and an index of 1.54. When we deal with the muscular apparatus of the eye we deal with factors essentially variable in their character; and it is not at all similar to the case of dealing with spectacle glasses where the factors are of fixed character. When correcting myopia if the optician sends a glass of 3 dioptries and his index is 1.54 and yours 1.50, you get a serious difference. Muscular errors are susceptible of such variation that this precision is not important when it comes to the lower degrees.

These are some of the reasons which have influenced me in this matter. I do not object to signing the report as a statement of fact; but my feeling is rather against a resolution that we should make such an announcment as this pledges us to do. If the society does not have the feeling which coincides with mine I shall simply sign the report.

ACUTE COCAINE CONJUNCTIVITIS.

BY DR. W. F. MITTENDORF,
NEW YORK.

Idiosyncrasies exist in various individuals for certain remedies, or even for certain articles of food. The luxury of eating a few strawberries or a small piece of fish, is, at times, followed by an extensive urticaria. The odor of ipecac, or even that of fragrant flowers, will, in some persons, produce a severe attack of spasmodic asthma. Iodoform, even, will in some patients excite alarming symptoms of poisoning, even if used in very small quantities at a time. The peculiar power of atropia to set up a severe attack of inflammation of the eyes, not confined to the conjunctiva, but spreading from the margin of the lid in a very short time to the cheek and brow, causing most alarming symptoms and such œdematous infiltration of the lids that the eyes can hardly be opened is, perhaps, known to you from personal observations in your practice. The object of this paper is to add cocaine to the list of such drugs. Only recently introduced as a therapeutic agent, through the efforts of our esteemed colleague, Dr. Koller, its use has at once become universal and frequent, and it is one of the highest recommendations to its usefulness, that so very few accidents have followed its use. It is safe to say that within the last three years I have used this remedy at least fifteen thousand times, and with the exception of a few cases, when its application to the conjunctiva was rapidly followed by a peculiar taste, dryness of throat, difficulty of deglution and, in one or two instances, even in an asthmatic attack and great nervous excitement, I have only met with three cases where its continued use was followed by actual inflamma-

tion of the conjunctiva. No similar cases have ever been published.

The first case where any acute inflammation was observed to follow the use of cocaine was that of a lady afflicted with dislocated cataract. In order to examine the fundus of her eye I dropped a few drops of cocaine into it. She returned in the afternoon in a state of great excitement. The eye was red and the lids swollen to such an extent that she could not open them. There was some chemosis, and an acrid discharge of hot tears with flocculi of mucus was discharged freely on opening the lids. The discharge was of such an irritating nature that not only the integument of the eyelids, but also that of the cheek with which it came in contact, was red. The entire skin of the lids, however, was red, glossy, and tense. In fact, the picture of the eye was such as we are apt to see in atropine conjunctivitis. An alkaline solution in this case, made of bicarbonate of soda and ice compresses speedily relieved the symptoms.

The second case is that of an elderly lady, who consulted me on account of impairment of vision, due to incipient cataract. The opacity being more or less central, the improvement of vision caused by the dilatation of the pupil, which was due to cocaine applied for diagnostic purposes, was so marked that she begged to have an order for it to take out of the city during the summer season. I gave her accordingly an order for a 4% solution, which, as the druggist assures me, was the most reliable preparation he could get — Squibbs, if am not mistaken. A few days had hardly elapsed when a letter arrived, informing me that the lady had evidently taken cold on her trip, the eyes being badly inflamed and very itchy. As the lady was spending the summer at Lake George, far from the local physician, I ordered her a boric acid wash, to be used freely. The trouble did not improve, however, on the contrary it increased considerably, so that she was compelled to come to the city for relief. The lady was in a most deplorable condition. I found not only a very marked thickening of the conjunctiva, both of the lids and eye-ball, but the outer portion of the lids were covered with eczematous patches extending down to the cheek. The principal symptom, aside from the annoy-

ing mucoid discharge, was the intolerable itching, which was only relieved, and this temporarily only, by the use of cocaine. I resorted at once to the most vigorous treatment; applied nitrate of silver and iced compresses, and succeeded in reducing the inflammation considerably, so that the lady was able to go back to Lake George, after a week's treatment. However, not recognizing the true nature of the inflammation, I did not forbid the use of cocaine, and the lady had hardly returned to the country when the disease began to gain again and to annoy her so much that she had to cut short her vacation and return for treatment. This time the peculiar glossy appearance of the integument of the lids was so striking, that I began to suspect the cause of her trouble. I stopped the use of cocaine, avoided all harsh application, used the crystal of alum once every day or two, and in less than a week the inflammation of the lids as well as of the conjunctiva had entirely disappeared. The lady returned to the same locality this year, but has not had the slightest trouble with her eyes, which would indicate that the locality, as had been suspected at one time, had nothing to do with the eye trouble.

The third case is that of Mr. G., a liquor merchant, suffering from beginning atrophy of the optic nerve, due to locomotor ataxia. He imagined that he could see a little better and that his eyes felt better after an application of cocaine, which I had used to dilate the pupil with. He requested me to give him a cocaine solution for him to use at home. In this case I combined cocaine with boric acid, so as to have the solution keep longer. The next day the patient was brought back to the office with his eyes in a terrible condition, the integument of the eyelid being so tense, swollen, and glossy that the cause of the conjunctivitis was at once clear to me. I told him to discontinue the drops, use a mild borax lotion, and, surely, within two days the eyes were as well as before cocaine was used. The same patient returned a month or so later, when, without thinking, I applied a few drops of cocaine solution, which I had used in my office for several days and which I had made myself with the best crystallized cocaine that I could obtain. The patient had hardly returned home when the eyes began to tear

and to be so itchy, that he returned at once to let me see them. In order to investigate this peculiarity of his further, I requested him to return in two weeks, when I used a freshly made solution of salicylate of cocaine; using water, which was boiled, before adding the cocaine, and which I thought would make it aseptic enough to exclude the idea that any germs or cocci contained in the solution might have been the causative agent, but the result was the same as before, a severe conjunctivitis followed.

Another even more remarkable case was related to me by a colleague of mine of the aural staff of the N. Y. Eye and Ear Infirmary, who told me that whenever he used a spray of cocaine to his nose, it would be followed by the most distressing throat and eye symptoms, which invariably wound up in an attack of granular lids, as he called it. At my request he used an aseptic solution of salicylate of cocaine, but the effect was the same, although the tension of the eye-ball and the conjunctivitis were not quite so marked, he thinks, but I suppose this is due to the fact that the solution was weaker than the one used on previous occasions. In his case the entire mucous membrane seemed to be affected, extending to the rectum and urethra, and even the heart's action seemed to be affected.

The mode of action of cocaine in these cases I am unable to explain, except that the drug may, in some persons, have a paralyzing effect on the sympathetic nerve-fibres; that the vasomotor nerves not acting on that account, a capillary stasis is produced, which leads to exudation into the surrounding tissues and subsequent inflammation of the parts.

DISCUSSION.

DR. GREEN.— We are all of us sufficiently familiar with the irritation and inflammatory condition which follows the use of atropia in certain patients. There seems to be for a time a tolerance; then sudden conjunctival irritation is set up, with discharge and swelling of the skin. In certain cases in which this irritation has occurred I have tried the obvious experiment of changing the mydriatic. I first tried daturia — an alkaloid chemically identical with atropia — but without advantage. Then we came in possession of duboisia; but cases which had proved to be intolerant of atropia or of daturia were quite intolerant of this. When cocaine came into use I found a small

proportion of cases in which the same conjunctival affection, with swelling of the skin, followed its application. Afterwards we came to think of bacterial infection as a cause of inflammation of mucous surfaces, and I adopted various methods to render these different solutions aseptic, but it made no difference. I am at a loss to account for the production of this form of conjunctivitis with infiltration and swelling of the skin. But as far as the clinical appearances and clinical history of such cases go, the inflammation from atropia, daturia, duboisia, and cocaine seems to be identical. I recognize it at sight nowadays and accept it as an indication for ceasing the use of any mydriatic.

Shortly after we came into possession of cocaine a druggist's clerk consulted me for a slight superficial irritation of the eye with a feeling of discomfort. I had previously given relief in several attacks by prescribing a borax solution. On this occasion the irritation was somewhat greater than usual and I gave him a prescription for cocaine — not a strong solution — cocaine hydrochlorate of the strength of two per cent. I told him that he might use this occasionally, when the feeling of discomfort came on; the first applications seemed to afford relief. At the end of a year I saw him with extensive hyperæmia of the conjunctiva, which had persisted for many weeks; questioning him I found that he had fallen into the habit of dropping the cocaine solution into the conjunctival sac several times daily. He felt more comfortable each time, and had continued it for nearly a year. In this case there was nothing but a very marked hyperæmia of the conjunctiva, which passed away very rapidly upon discontinuing the cocaine. This was a case of long continued abuse of the drug and entirely different from the cases of inflammation to which Dr. Mittendorf refers. I am sure that conjunctival inflammation is a not very uncommon result of the protracted use of cocaine.

DR. WILLIAMS of Boston.— My own experience has corresponded with that of the gentleman, although I never use anything stronger than a 2% solution in any ordinary circumstances. Occasionally in iritis I use a 4% solution; but for extraction of cataract and for ordinary uses I use the 2% solution. In one of the cases of 4% solution, I think there was a little bit of apparent erosion of the cornea, but that is the only unpleasant result I ever had. I am satisfied that there is an idiosyncrasy in certain individuals which prevents our making use of it.

DR. SEELEY.— I would like to ask whether he tried any other preparations in these cases where he had irritation from cocaine, such as atropia or morphia? Some cases published by myself in '66, of irritation from atropine, showed that almost

anything else put on to the conjunctiva produced a similar sort of irritation of the conjunctiva.

So far as cocaine irritation goes, I have never seen any case of that sort. I use a great deal of it in the nose and in the eye, of course. I agree perfectly with Dr. Williams, when he says he finds a 2% solution strong enough. I think we waste a great deal of cocaine.

As for this reaction, I don't think I have noticed that which Dr. Jackson speaks of. The first action is to contract the blood vessels; and, I think, there is exactly where the benefit comes in in its use.

As for the number of times which these things are used in the eye for the relief of ordinary inflammation, it strikes me that you use cocaine as you use eserine, for example, once a day. I think what you don't get out of one or, at most, two applications in a day, you don't get out of any number of applications. In my judgment, the poisoning and irritation depend on the strong solutions and too frequent use.

DR. MITTENDORF.—I never use anything else than crystallized cocaine. I think the mode of action of cocaine is to be explained by its effect on the sympathetic nerve fibres entirely; this is evident by the retraction of the upper lid, dilatation of the pupil and the blanched condition of the bulbar conjunctiva. I think that we may explain the action upon the sensitive nerve fibres in the following way: It produces a capillary anæmia around the terminal fibres of the sensitive nerves. If we have anæmia occurring in the retina, we know that vision is at once lost. Let us get embolism of the central artery of the retina and vision is at once gone. So I think the action of cocaine might be explained on the terminal fibres of the nerves in producing this capillary anæmia. This can only be produced by irritation of the vaso motor nerves. The contraction, due to the irritating effect of the cocaine, will be followed by a relaxation, and this produces the hyperæmia that we have heard of here; and in some weak individuals it may lead to paralysis of the vaso motor nerves and stasis of the circulation, and then we get these inflammatory symptoms very marked and suddenly.

DR. JACKSON.—In the Transactions of the College of Physicians of Philadelphia for 1887, I published a case, which started as an acute conjunctivitis, for which a 4 per cent. solution of cocaine was prescribed, to be used every four hours. The patient, finding that its application gave temporary ease, had it repeated as often as the discomfort returned, and was using it as often as once an hour. When I first saw the case, there was a peculiar, narrow, very dark, purplish pericorneal zone, and half the surface of the cornea was occupied by a per-

fectly superficial ulcer. The bottom of this ulcer was faintly gray, not infiltrated, and bore patches of gray, sloughy membrane, continuous at the margin of the ulcer, with the sound surface of the cornea beyond. I have seen the same pericorneal hyperæmia, with a smaller ulcer, in another case, after similar very frequently repeated instillations of cocaine. I think that in the majority of cases cocaine causes in the normal eye a conjunctival hyperæmia, which reaches its height three or four hours after the introduction of the drug. My attention was first drawn to it in my own eyes by the smarting attending it. I have found it in most of the eyes examined from two to four hours after the instillation of a four per cent. solution. Such cases and facts led me to avoid placing cocaine in the hands of the patient and to prohibit its use for the relief of constant or recurring pain or discomfort in the eye.

BLEPHAROSPASM.

BY CARL KOLLER.

NEW YORK.

By invitation.

Mr. President and Gentlemen:

Having been honored by an invitation from your president to read a paper before you, I regret I have nothing more novel than the old subject of "Blepharospasm" to claim your attention. Blepharospasm, as a disease by itself, is in the minority, whereas it occurs mostly as a symptom in conjunctival and corneal troubles; and when it does, it is clinically the most striking feature. I trust its importance will justify the distinction I have given to it by making it the subject of special study, and I hope that what I have to say on the nature and treatment of this symptom will prove of some interest.

It is not my intention to speak of the fibrillar contractions of the orbicular muscle, occurring mostly at the external angle, which trouble and alarm so much their possessor, neither do I wish to refer to the clonic spasm of the orbicularis, which occurs sometimes in children and sometimes in old people, and which is so very difficult to remove. It is of the tonic blepharospasm,

the continuous closure of the eye-lids by contraction of the orbicular muscle, I wish to speak.

The great majority of cases can be brought into three groups. The first of these has been described by Græfe in the 4th and 9th volume of his Archives, and can be called a reflex-neurosis. The patients previously suffered from neuralgia of the trigeminus, mostly in the region of the supraorbital nerve or the supramaxillary nerve. But there are some cases where no neuralgia existed. Gradually closure of the eye-lids sets in, and when the case is advanced, there is also spasm of the orbicular muscle of the other side and other facial muscles. To the passive opening of the eye by drawing up the upper lid, the patient offers resistance, but allows, without any resistance, the opposite movement. Pressure upon some particular branch of the trigeminus will check the spasm, and this can be effected by general narcosis. I do not know if subcutaneous injection of cocaine will accomplish the same, but I surmise it will. There is thus a reflex spasm of the orbicular muscle, caused by a condition of irritation — perhaps a neuritis — of a sensitive branch. Following the advice of Romberg, Græfe divided in such a case the supraorbital nerve within the orbit. The effect was to cure the blepharospasm. This operation has been repeated by him and others on the supraorbital, and also on other branches, with success. Græfe located the irritation in those nerve-fibres which supply the muscular sensibility. The reason why he did so is not quite clear to me.

The second form of blepharospasm, the so-called hysterical, concerns almost exclusively females up to middle age. Both eyes are spasmodically shut; one not more than the other. There is no inflammation or irritation of the eyes present and no pain. When the spasm is overcome the retina is found in a healthy condition. From all this one can draw the conclusion that we have to deal with a functional neurosis. When any part of the face is pressed upon — not particularly so-called nerve-points — and the patient is at the time ordered to open the eyes, she does it, and she will even do so when the pressure is made upon some remote part of the body. And when this has been done a number of times the patient obeys the mere

order, even when the pressure is omitted. It is evidently a phenomenon of suggestion, so much mentioned in our day. It is known to you that in hypnosis, paralysis or contracture of limbs or muscles, can be suggested to the subjects, and it is even well known that there are kinds of paralysis and contracture which can be checked by suggestion, with and without hypnosis; and as the suggestion works upon the representation only, it must be concluded that those diseases exist only in the representation. I am of the opinion that the kind of blepharospasm in question is due to representation.

The third form of blepharospasm is the most frequent one; it concerns all cases in which an inflammation or irritation of the conjunctiva or cornea exists, and it is to be considered as a reflex spasm, caused by irritation of the terminal ends of sensitive nerves in the conjunctiva and cornea; it is the morbid increase of a normal reflex, which might be considered as a protection for the tender parts of the eye. When, as in general anæsthesia or in local anæsthesia, the peripheral ends of sensitive nerves are paralyzed, this reflex action is checked. This sort of blepharospasm occurs especially when foreign bodies are present in the conjunctival sac or in any superficial inflammation of conjunctiva and cornea, and the intensity of the spasm is often not in proportion to the intensity of inflammation. The eye-lids are spasmodically shut, the head bent forwards, the patient strives to protect himself against light, and struggles against passive opening of the eye. In the light the spasm increases; in the dark its intensity decreases. It is an interesting question how much photophobia has to do with this sort of blepharospasm, as this latter is brought about by the sensitive nerves of the conjunctiva and cornea, and not by the optic nerve, as Græfe has already emphasized. It is evident that, by the long persistent closure of the eye, the retina becomes hyperæsthetic, and this might be one reason why light increases the spasm. Another reason might be found in the irritated condition of the iris, existing so often in corneal disturbances, which makes contraction of the iris painful.

One of the most frequent and obstinate forms of blepharospasm is that which occurs in the phlyctenular, so-called

scrofulous ophthalmia, of children, and every practitioner knows how obstinate the spasm can be, and in all eye-clinics cases are seen which often, for many months, resist every kind of treatment. There is something enigmatical in the obstinacy with which the spasm persists, although the primitive cause, the corneal or conjunctival disease, is almost removed, conditions which often can be brought to evidence only by narcosis. A therapeutical measure (plunging of the head in cold water) has been recommended, and it indeed mitigates the spasm, although only for a short time; it soon comes back in the old strength.

When I made my first experiments with cocaine-anæsthesia, I hoped that cocaine could be successfully used with this form of blepharospasm; but it soon became evident that this expectation was delusive. When with much effort a few drops of the solution are instilled, they are washed away by the tears, and only by very frequent instillation, made by the physician himself, one might succeed in checking the spasm for a short time. When the effect of cocaine has passed away the spasm comes back.

The pathology and therapeutics of this form of blepharospasm was satisfactory to me, until my attention was called by my friend, Dr. Nordmann of Helsingfors, to a small fissure at the external commissure, sometimes at the internal commissure, which exists in most of these cases of blepharospasm scrofulosorum. It then became clear to me.

It is well-known to you that a fissure at the anus causes a very strong reflex spasm of the sphincter ani, and it is the same with the spasm of the sphincter cunni, which so often is caused by fissures of the vulva. As long as the edges of this fissure are kept in contact by spasm, it cannot heal; it is just the same as with the fissures between the fingers which persist for months, and when nothing more is done than to put a wad of cotton between the fingers the fissure heals; therefore, the indication would be to keep the edges of the wound from each other, and as in the case of the anus this cannot well be effected by tamponing, surgeons cut through the sphincter and consider it the only way to cure the spasm. As you know also in the therapy of the blepharospasm the same means have

been applied, although the connection of cause and effect seems to me not to have been a clear one.

There is no serious objection to the performance of this operation other than that in our case it is not necessary, and that other means which attack the cause lead quicker to the end. In therapeutics it is always our aim to recognize and remove the cause of disease.

Before speaking of the therapeutics, I desire to say a few words on the production of this fissure. At first the continuous closure of the eye-lids is maintained by the inflamed condition of the cornea and conjunctiva, the secretion of tears being very abundant in such inflamed eyes; the mucus produced at the same time lies over the stomata of the Meibomian glands and obstructs them; the tears therefore find their way across the eye-lid and produce eczema—apart from the fact that the phlyctenular ophthalmia often is but a part of an eczema eruption in the face. For the establishment of eczema, the neighborhood of the palpebral fissure is a very favorable part. The skin at this part, when the lids are firmly closed, shows a deep groove, *quasi*, a continuation of the palpebral fissure; the tears are drawn into this groove by capillary action, and their continual corrosive action causes the fissure; similar circumstances in a lower degree are present at the internal commissure. These fissures, as well-known, are very painful, and just as in the case of the anus the irritation of the exposed nerves causes reflex spasm; the spasm on its part prevents healing of the fissure. Thus the blepharospasm continues, although its original cause, the corneal or conjunctival trouble, may be recovered from. The indication for the therapeutics of this condition is therefore plain, assuming that no deeper corneal trouble exists, which would demand a particular treatment. To check the production of mucus the conjunctiva is treated with 1–2–5 gr. solution of nitrate of silver; in most cases one or two days will be sufficient. The diseased eye-lashes are to be removed after the crusts have been softened by luke-warm water. The eczematous skin around the eyes and nose, after the softening and removal of the crusts, are brushed with 25–50 gr. solution of nitrate of silver, carefully dried, and then yellow ointment is

applied. The treatment of the fissure requires an especially careful attention. By stretching the skin the fissure is opened and the small wound is cauterized with bluestone, in order to produce a superficial scab; cauterization cleans the wound and causes it to heal from the bottom, and yellow oxid ointment is to be applied to prevent the admission of tears. When fissures are present at the external nares they are easily cured by tamponing with cotton, which is covered with any ointment, best with yellow oxide ointment. The secretion of the nose, which is often so abundant, is checked by this proceeding. With this treatment until to-day I have always succeeded in getting the better of the blepharospasm in scrofulous ophthalmia in a very short time, mostly in four or five days, when no deeper corneal affection is present. The chief condition of success is the physician doing everything himself and not trusting to the patient or his friends.

CASE OF MONOCULAR NEURO-RETINITIS.

DR. R. H. DERBY,

NEW YORK.

Patient, a well developed, intelligent girl of twelve, who had never menstruated, came to me March 15, 1888. She stated that that morning on waking the edge of the door looked indistinct; she closed the right eye and then all seemed in a grey mist; this defect of vision grew less in the course of the day. When seen there was a central scotoma of left eye, an inch in diameter, measured at the reading distance. Vision less than .2, while that of left eye was normal. The ophthalmoscope showed nothing. Four days later, on March 19th, light neuro-retinitis; March 22d, central scotoma measures 10° in each direction; March 24th, only perception of light outwards. There is now an optic neuritis, the most prominent part of papilla seen with + 7 D, the eye being emmetropic. By statement of family physician, patient's father had lues. Mercurial inunctions and iodide of potash internally in increasing doses were ordered. March 30th, no light perception in left eye. April 9th, patient was taking 192 grains of iodide of potash daily, with no disa-

greeable results, and the mercurial inunctions have not been omitted. To-day patient sees movements of the hand over the entire periphery of field. April 13th, counts fingers outwards. The disc has already begun to resume a normal appearance and the most prominent part of nerve is seen with + 3 D. April 29th, V = .1. May 2d, reads Snellen No. 7. May 4th, V = .2, and no demonstrable scotoma. May 23d, V = .4.

Before June 1st the traces of neuro-retinitis had disappeared and the general condition of the patient had, in every respect, greatly improved.

Cases of monocular neuro-retinitis, that are not referable to a neoplasm within either the cranial or orbital cavity, are rare. In this case there were no signs of inherited syphilis.

That the optic neuritis bore some relation to the efforts of nature to establish the catamenial period, seems more than probable.

DISCUSSION.

DR. SWAN M. BURNETT, of Washington.—I have now under observation a case somewhat similar to that narrated by Dr. Derby. The man was affected with carbuncles and complained of soreness in the left orbit and dimness of vision. V = $\frac{1}{36}$. Decided, but not very great swelling of disk. No exophthalmia No history of syphilis. He is gradually improving.

THREE CONSECUTIVE AND SUCCESSFUL EXTRACTIONS OF LUXATED LENSES BY MEANS OF THE AGNEW BIDENT, WITH TWO ADDITIONAL CASES FROM OTHER SOURCES.

BY OREN D. POMEROY, M.D.
NEW YORK.

CASE I.—John Dalrymple, aet. 58, had his right eye struck by a large sized buckle, between four and five years ago. Eye became red and painful; counted fingers at twelve inches only; soon got better and the eye gave no trouble until two months ago, when it became red, with constant pain, which continues until the present time. Lens found in anterior chamber. I sent him from my house to the hospital: on arriving the lens had escaped into the vitreous chamber. I then ordered the patient to lean his head upon a chair-back, hoping to induce the lens to pass into the anterior chamber. In about two hours the lens was found lodged in the anterior portion of the eye, and eserine was instilled so as to contract the pupil and imprison it in front of the iris. This was soon accomplished. The patient was then placed in an operating chair and etherized partially, in an upright position; the bident was then passed behind the lens, the latter being securely fixed in the anterior chamber. (Previous manipulations had convinced me that on the slightest provocation the lens would again pass into the vitreous chamber.) The patient was then placed in a recumbent position. An incision was made by a Græfe knife in the lower margin of the cornea. This being my first operation of the kind, and never having seen it done, I made the mistake of pushing the lens so far into the anterior chamber as to make an adequate section of the cornea difficult. I believe Agnew experienced the same difficulty in one of his cases, when the cor-

neal wound was enlarged by scissors. The lens being in front of the iris, and the latter being untouched by the Græfe knife, no iridectomy was done. The lens was delivered by means of a sharp hook, after other instruments had failed to accomplish this result. Not more than a drop or two of vitreous was lost. The speculum was removed before the bident, the latter being removed by means of the fingers, as the last act in the operation. Bandage applied. There was considerable reaction, requiring iced applications on several occasions. The pupil was circular, except below, when a few adhesions were found. By Feb. 18th (nineteen days after operation) patient was discharged, with V. $\frac{20}{200}$, the eye-ball perfectly quiet and apparently sound.

CASE II.— Charles Heppelef, aet. 62. Two years previous to Aug. 22, 1887, was struck on the right eyebrow with a piece of iron, which evidently injured the eye, for pain and photophobia soon appeared, with gradual diminution of sight. On above date was found to have a luxated and cataractous lens, which had fallen sufficiently to expose the fundus at the upper portion of the pupil. The iris was noticeably tremulous.

Owing to the fact that the lens had settled so much, the bident was introduced below the center of the cornea, so as to be directly behind the lens. Care was taken not to press the lens too far towards the cornea, for fear of wedging it into the anterior chamber, as I had previously done. This would make an adequate corneal section difficult, and embarrass the operator in removing the lens. Section of the cornea below in the usual manner. On the completion of the section, the lens suddenly tilted upwards, so as to rest mostly on the upper prong of the bident and threatening to fall into the vitreous chamber.

To deliver the lens a wire spoon, forceps, and a sharp hook were used, the latter only succeeding. The lens was smaller than usual. A very slight amount of vitreous was lost on removing the speculum. The bident had been previously removed. In my later operations I have removed the bident as the last step, catching it with the fingers. Seven days after the operation there had been no pain, and the reaction was very moderate. Done antiseptically. The recovery was uninterrupted

and the patient was discharged Oct. 7th, six weeks after entering, with V. $\frac{20}{70}$. Eyeball appears perfectly normal.

CASE III.—Michael Feely, aet. 56. Three months since received an injury to both eyes. The left was so seriously injured by a lacerated wound in the upper ciliary region that phthisis had already commenced; there was much limitation of the field and naturally no hope of restoration of sight could be entertained. The lens of the right was luxated by the same agency that had destroyed the fellow, but remained nearly in position, being so far cataractous as to make it difficult to see to go about.

Eyeball of normal tension, and projection perfect. On June 20, 1888, I extracted the lens by means of Agnew's bident.

Antiseptic precautions were adopted (Panas' fluid). Ether was used, the spring speculum was inserted and the bident was pushed just behind the lens, being entered at about a line and a half behind the margin of the cornea, on the temporal side. Knowing that the instrument was well behind the lens, the prongs were swept forward, so that the anterior chamber was filled with lens and iris. This necessitated a counter puncture a little nearer the cornea than the first puncture. The handle was then removed and a lower section of the cornea was made by a Græfe knife. The anterior chamber being encroached upon by the lens and iris, the latter was cut through by the knife. An irregular iridectomy was then done. The lens was removed by means of the hard rubber spoon, as pressure on the eyeball in all these operations is contra-indicated in removing a lens. Previous to the use of the spoon a sharp hook had failed to deliver it. The subsequent treatment was about as usual and no excessive reaction occurred. The vision, nineteen days after the operation, was $\frac{10}{200}$, with correction.

Feeling now sure of one useful eye, I enucleated the left, which had grown somewhat irritable. On July 27th I divided a pupillary membrane with Kapp's knife-needle; no reaction worth mention. July 30th discharged, with V. $\frac{20}{70}$. Eyeball seems perfectly healthy.

CASE IV.—The following case is one operated upon by the

late Dr. Agnew, which I found in the case book at the Manhattan Hospital.

Pierce Power, about a month previous to July 11, 1887, received a blow on the outer side of the left eye, after which he could not see anything directly in front of him. The vision of both eyes had been failing for two years, the left first. Both cataractous; left lens luxated to upper and outer side. V. R. $\frac{3}{200}$. L. V. perception of light—field good. On July 13th the patient was etherized, the bident introduced, and the lens carried into the anterior chamber. A section of the cornea at its lower portion was made with a Græfe knife. A wire spoon was first introduced in order to remove the lens. This failing, the bident was partly withdrawn, with the view of delivering the lens. This also failed, and the instrument was removed. Most of the lens was subsequently delivered by means of the spoon. A small portion remaining was subsequently removed. Only a small amount of vitreous was lost. Ordinary bandage used in dressing the eye. July 14th, no reaction. July 15th, a little vitreous seen hanging from the wound; pressure bandage applied. July 16th, snipped off this portion of protruding vitreous; atropine used. July 20th, eye looks well; pupil dilated. August 6th, eye still irritable; lens matter remaining is slowly absorbing. August 19th, eye quiet and patient discharged. Vision not noted, but if it had been absent some note would undoubtedly have been made. I find reference to another bident operation by Dr. Agnew, but cannot find the case.

CASE V.—This case is from Dr. Webster: A. W. Hills, aet. 23, on March 18, 1886, was struck on the right eye by a piece of coal. On the next day, when he visited the hospital, his cornea was somewhat hazy, with a horizontal linear opacity on lower portion; pupil dilated; conjunctiva reddened and somewhat chemotic; lens transparent and in position. No fundus lesions. Put in bed, with atropine and iced cloths for treatment. Counted fingers at one foot. March 21st, chemosis nearly gone; otherwise, as before. On March 22d, no change until 2 P. M., when hæmorrhage into anterior chamber, with luxated lens, is noticed; fundus not seen. March 24th, lens

luxated upwards and outwards; fundus seen with + 5 D. — cornea less hazy.

On consultation with Drs. Pomeroy and Emerson it was decided to remove the luxated lens. The patient was etherized and Dr. Agnew's bident was passed behind the lens, bringing it well into the anterior chamber. The pupil was widely dilated with atropine and cocaine, and did not contract after the section was completed. The section was made in the *upper* portion of the cornea and was somewhat small. The lens was removed with the fenestrated scoop and came away in pieces, a little being left behind; a few drops of vitreous lost. May 27th, patient had a little pain last night and this morning; eye deeply injected, lids swollen, pupil small, anterior chamber partially refilled — iced cloths and atropine. November 28th, iced cloths continued — eserine t. i. d.; temperature 99⅜ — aconite administered. There was an opaque film projecting from the wound yesterday. November 30th, a portion of the lens protruding from the wound; hyd. chlo. mit., followed by Rochelle salts. March 31st, portion of lens removed. April 7th, some protrusion of lymph and vitreous: mercurial inunctions. April 18th, eserine continued, with atropine once a day. April 22d, pain this morning; tension +, lymph presented from the wound and was removed. May 7th, membrane over the pupil, but counts fingers rapidly — discharged.

This seems a very practical operation: The case of Feeney, with V. $\frac{20}{70}$, with only this eye remaining, is most gratifying. The two remaining cases on record, in the Transactions of the American Ophthalmological Society for 1885, one by Dr. Agnew, where a sightless eye had the lens extracted by means of the Agnew bident, with the result of quieting an eye, threatening its fellow and preventing enucleation, and the other, in the same Transactions, by Dr. Webster, where V. of $\frac{2}{10}$ was obtained, is a most satisfactory showing. The original bident of Agnew's was only used here in one case. A modification of this instrument has been made by Dr. J. A. Andrews of New York, in which the handle is fastened on by a delicate spring, admitting of much more nicety of manipulation than when the Sands needle holder, of the original bident, is used. The handle

should certainly *not* be re-applied to remove the instrument from the eye, the fingers of the operator allowing of the removal in a much more delicate and safe manner.

Where the lens has escaped to the region of the fundus, it is advisable to allow the patient to spend some time with the head bent forwards, so as to throw the lens as far as possible into the anterior portion of the eye. This manœuvre should be performed while the eye is cocainized, as the indications are to introduce the bident behind the lens, as soon as we have evidence that the latter has passed sufficiently forwards for that purpose, and of course before the head is lifted from its bent position, for fear the lens should again return to the deeper parts of the eye. In most of the operations so far done, there has been a tendency to press the lens too far into the anterior chamber, so that in performing the section the iris and lens are liable to be cut through or that the section may be insufficient in size. By this manœuvre, also, the lens is so wedged between the bident behind and the cornea in front as to be difficult of delivery, especially as the prongs of the bident are likely to make deep indentations into the lens and prevent its easy exit from the eye. In the delivery of the lens, it has been seen that a variety of manipulations have been practiced. It is apparent enough that pressure on the eyeball will be inoperative in extruding the lens under these conditions. A wire spoon or sharp hook are as likely to remove the lens as any instrument; the indications being to remove the latter by traction, or by passing some instrument behind it so as to push it out—for the latter purpose a probe or curette may suffice. It may be urged as a theoretical objection, that puncture in the ciliary region is likely to inaugurate a state of sympathetic irritation or inflation in the fellow eye. So far this has not been the case, and the fact that the so-called Hancock's operation for glaucoma has never resulted in sympathetic trouble, as mentioned by Webster, encourages us in the belief that there is no danger, especially when we remember the very small size of the punctured wound made by the bident. In all the cases thus far observed, the wound made by the bident has seemed quite unimportant. Besides the indication for removing a luxated lens in a general way,

I believe it to be proper to use the bident whenever we are assured there is fluidity of the vitreous and a consequent likelihood of its escaping in considerable quantities by other methods of operation.

It seems to the writer that there is very little danger of any considerable escape of the vitreous, provided the bident is carefully used. The late Dr. Agnew suggested that this instrument might be used in extracting a foreign body from the eye. Where the lens is lodged in the anterior chamber with a firm and well contracted iris, with little danger of the lens escaping into the vitreous chamber, we may possibly dispense with the bident, but in a general way I should feel much more secure in using it. The downward section has generally been used in these extractions, partly, perhaps, because it is less difficult. Inasmuch as this is one of the operations that taxes the resources of the operator more than most others, any suggestion that simplifies the steps is to be recommended. Most of the cases operated on seem to show that the eyeballs are likely to remain in a fairly good condition, without danger of phthisis.

NOTE.—Since reporting the preceding cases, I have one more to add: Bridget Hengstler, age 55, has a luxated lens in right eye which is cataractous. Other eye has incipient cataract. Has had iritis in right which has left several synechia, which were ruptured by atropine; at sup. nasal portion of pupil the fundus was visible through a gap of about two lines caused by the falling downwards and outwards of the lens. November 7, 1888, the lens was extracted by means of bident. Care was taken not to press the lens too far into the anterior chamber. Although the lens had somewhat fallen from its position, the section was done above, and the lens was delivered readily with a sharp hook, somewhat larger than the one ordinarily used. No iridectomy; no vitreous lost; lens somewhat small, and no soft lens matter left behind. The bident was removed after the speculum, while the lids were nearly closed. The first essay to remove it failed, and it had to be grasped quite firmly and was drawn out with some thing of a jerk which resulted in the loss of a few drops of vitreous. Done aseptically (boric acid and instruments immersed in boiling water). There was no excessive reaction, but the recovery was somewhat protracted, being extended to about six weeks. Iris was incarcerated in the wound, and at one time slightly prolapsed, but not sufficiently to necessitate iridectomy. V. 4 200, with a membrane which is about to be operated upon, and with the prospect of fairly good vision.

DISCUSSION.

DR. WEBSTER.—This operation advised by Dr. Agnew has seemed to fall flat on the profession. I don't know of anyone who has done it but Dr. Agnew, Dr. Pomeroy, Dr. Andrews, and myself; and all who have used the instrument have been very much pleased with it. Dr. Andrews has done it three or four times. He has been very much gratified with it. I don't

think we need to apprehend danger from wounding of the ciliary body with the sharp needles.

The last case was in a considerably inflamed condition when I operated and the traumatism increased the inflammation and the man was in the hospital perhaps five or six weeks. When he went out he could count fingers, but had more or less obstruction in the pupil. He went to sea. I have not operated for a long time, because no case has turned up suitable. Cases of dislocated lenses, which can't easily be got at without the bident, are rather rare in my practice.

DR. CALLAN.— A few remarks in connection with this case: I had a patient with almost similar conditions. A boy of 12 years was struck on the right eye with a frozen potato. The iris was detached outwards to the extent of 5^{mm}, and the zonula of the lens immediately behind was torn. This made the lens act like a door on hinges, every motion of the eyeball brought the detached iris and moving lens in contact. I saw him three months after the accident; then the eye was glaucomatous and very irritable. The question to decide, was, what to do? It was suggested to remove the lens, which was transparent. Instead, I made a large iridectomy of the detached portion of the iris. This reduced the tension of the globe to normal, the eye lost its irritability and everything progressed favorably.

DR. JACKSON.—I would like to ask Dr. Pomeroy whether the corneal incision lay close to the limbus throughout its whole extent? Would not the resistance to the extraction of the lens come from the prong of the bident nearest the apex of the corneal flap? If such were the case, would not the making of a shallower corneal flap, so that its apex should be just opposite this prong of the bident, avoid this difficulty?

DR. POMEROY.—Yes; this was one of the best cases for pressing the lens out. The lens was lying in the lower part of the eye, close to the iris. If there ever was a case where you could press out the lens without losing vitreous, this was one. If vitreous is in front of the lens, it generally remains there and will be extruded by the pressure, the lens remaining behind. Of course I ran the risk of spoiling the eye.

SOME TENOTOMIES FOR THE CORRECTION OF HETEROPHORIA, WITH RESULTS.

BY DR. DAVID WEBSTER,

NEW YORK CITY.

In presenting this paper to the American Ophthalmological Society, I wish it to be distinctly understood that I do not commit myself to the indorsement of the justness of the claims made for the division of ocular muscles for the cure of epilepsy, chorea, or insanity. As a member of the committee of the New York Neurological Society, which has the subject under advisement, any expression of opinion, on my part, would be immature, injudicious, and inappropriate.

The nomenclature of Dr. Stevens, which has not yet been accepted by any scientific body of men, is only used for *convenience* in narrating my experience in the way of investigation as to the merits of the question.

Since the first of July, 1886, a period of a little over two years, I have performed the operation of tenotomy for the correction of heterophoria, or latent or dynamic squint, in forty cases. Twenty-five patients were operated upon only once each, while sixteen had a second tenotomy performed, making fifty-five tenotomies in all.

These tenotomies are classified as follows: of the inferior rectus, 3; of the superior rectus, 7; of the external rectus, 19; of the internal rectus, 26.

Three of the cases had been previously operated upon by Dr. C. R. Agnew, one by Dr. E. G. Loring, and one by Dr. G. T. Stevens. Dr. Stevens had done two tenotomies on his case,

and Drs. Agnew and Loring one each on theirs; so that in the forty cases, sixty-one tenotomies were done.

The tenotomies performed by me were all, or nearly all, done according to the method described by Dr. George T. Stevens in his paper read before the New York Neurological Society in April, 1886. The tendon was button-holed at its center, and divided both ways until its attachment to the sclera was entirely severed, and then, if necessary, it was further freed from its attachments at either side until the heterophoria was corrected. I always aimed at a slight over-correction, and generally hit the mark; but in three cases there was too great an over-correction, and I had to do the operation, which I had seen Dr. Stevens do, for readjustment.

Nearly all the patients operated upon were more or less benefited, some only temporarily, some apparently permanently. In only one case had I reason to regret that I had operated, and that was a case in which, having cut both externi, I got an over-effect after the second tenotomy, and had to readjust the muscle. The patient has since complained of diplopia on looking far to the right or the left. I have seen a case of irremediable diplopia produced by tenotomy, but I think the operation performed must have been like the old one for squint. The diplopia came on after such an operation by a western ophthalmologist, and Dr. Stevens had failed to remedy it by nineteen (19) subsequent operations, according to the patient's statement; so that I thought the case might properly be set down as incapable of cure. I think there is little, if any, danger of diplopia following an operation done after Stevens' method. The operation should always be done under cocaine, and the effect produced should be measured at intervals during the operation, and the surgeon should be ready to stop cutting when he has got just enough effect. Three of my tenotomies were done under ether or chloroform; two in the case of a child, and one in the case of a man whose continued semi-convulsions prevented him from keeping still enough for a delicate operation upon the eye.

Four of the patients operated upon were epileptics. The

epilepsy was *not cured* by the operation in any case, though the fits were temporarily suspended in one case. In another case the fits were favorably modified, although the epilepsy was organic. In a third case there was temporary improvement, but later the patient was worse than ever. In the fourth case the fits had been suspended for over six months, and the operation was done more for the relief of asthenopia than for epilepsy, and with very good result.

There certainly can be no objection to restoring the proper balance of the ocular muscles, when it has been lost, in cases of epilepsy and chorea, but judging from my *personal* experience it does not cure either disease. Aside from the cure of the disease, however, enough good results in relieving asthenopic symptoms to justify the procedure.

One or two hysterical cases were operated upon at Dr. E. C. Seguin's suggestion with surprisingly good results. One gentleman, a civil and mining engineer from the west, had come to Dr. Seguin with a diagnosis of "incurable spinal disease" Dr. Seguin found "spinal irritation" of extreme degree. He had been unfitted for business by "semi-periodical paroxysms of excruciating pain, in which he made contortions, semi-involuntary, which had been termed convulsions." I found him in one of these attacks when I went to his room prepared to operate upon one of his interni. I sat with him over an hour, during which the agony and the plaintive cries and the apparent convulsions continued without remission, the patient constantly writhing in the most intense pain, until Dr. Seguin arrived, and we gave him chloroform and divided the tendon. From that time to the present, so far as I can learn, he has had but one attack, and that a very mild one, and after sufficient physical abuse to account for a recurrence.

Another gentleman who suffered from attacks which Dr. Seguin thought were hysterical, was much relieved by the operation.

A physician who had five or six years before been subject to frequent attacks simulating petit mal, and who had now developed blepharo-facial spasm with asthenopia, was operated upon first by Dr. Agnew, and afterwards by myself, with some relief of his asthenopia, but none of his nervous disorder.

One man who had been an inmate of an insane asylum, and who had sailed around Cape Horn for the rest it would afford his nervous system and his eyes, had an internus cut by me, but without relief.

But the majority of the cases operated upon and relieved

were cases of headache, varying in degree, character, and location. It would lengthen out this paper beyond all reasonable limits were I to go on commenting on the cases. I have written them out with some care, and hope to have printed in their completeness for reference for those who wish to know all about them. But I shall read here only brief notes of each one, unless the society wish otherwise. I may, before proceeding to read my cases, be allowed to formulate my present opinions in regard to tenotomy for heterophoria.

1. No person should have a tenotomy performed simply and solely because he is the subject of heterophoria; that is, unless some annoying symptom, local or general, is present that *may* be due to the want of harmony in the action of his ocular muscles. There must be a reason for the operation in addition to the existence of the condition to be corrected.

2. Very slight degrees of heterophoria may and should be corrected where troublesome symptoms exist which may be due to the too great use of nervous force in co-ordinating the eyes.

3. It is well that all other means that afford any prospect of relief should be tried before resorting to a tenotomy, although no time should be lost by unnecessary dilatory treatment.

4. Tenotomies for the correction of heterophoria should always be performed under cocaine, so that the effect of the operation may be accurately measured and properly limited.

5. In judiciously selected cases, where the operation is properly performed, the average results will be quite as satisfactory as the results of most other surgical operations.

CASES OF EPILEPSY.

Case I. — Mrs. B. A. H., age 47, was referred to me by Prof. M. Allen Starr, M.D., at the New York Polyclinic, October 19, 1887. She had been subject to epilepsy for many years, the attacks occurring with varying frequency and severity. Dr. Starr had diagnosticated hypermetropia and hyperphoria, and desired that the patient might have the benefit of their correction.

Upon examination I found: R. V. $= \frac{20}{20}$; Hm. $\frac{1}{24}$. L. V. $= \frac{20}{30} +$; Hm. $\frac{1}{20}$. Hyperphoria, R. 2°. No esophoria or exophoria. Fundus normal.

On November 3, 1887, I performed a *tenotomy of the right superior rectus*, and two pairs of glasses were prescribed, one correcting the hypermetropia, to be worn constantly for distant vision; and a stronger pair for near-work, taking into account the patient's presbyopia. She remained free from epileptic seizures for several weeks after the operation, and then relapsed

and was as bad as before. Another examination showed a recurrence of the hyperphoria of the same eye and in about the same amount as before the tenotomy. This I corrected by dividing the *inferior rectus of the left eye.* Again the fits were suspended for several weeks, but then returned and were quite as frequent and as severe as before any operation had been done. Several subsequent testings showed a condition of orthophoria, so that no indications existed for further operative interference. The patient was heard from about a year later, when she was said to be no better, but, if anything, worse.

Case II. — C. W. B., age 16, American, reported at my office September 14, 1887, with a letter from Prof. W. S. Kendrick, M.D., of Atlanta, Ga. He had been an epileptic since three and a half years old. No cause was known. The fits have occurred as often as twenty-five in twenty-four hours. They last from a few seconds to a minute or two. He is said never to have bitten his tongue, and ordinarily does not froth at the mouth. He is as bright as ever after an attack, when not under the influence of bromides. Three or four years ago he had no fits for a period of over six months. Master B. had just recovered from an attack when he came to my office, and being also pretty thoroughly brominized, was so stupid that I examined his eyes with difficulty. Both eyes had vision $\frac{20}{20}$, and were apparently emmetropic. No hyperphoria; esophoria 2°; abduction 6°; adduction 12°. Atropine developed hypermetropia 1 D. each eye, and esophoria 12°. I referred him to Dr. E. C. Seguin for examination, and got the following reply:

"Your patient has organic epilepsy, as is shown by the presence of remains of infantile hemiplegia (small right hand and short right leg; attacks beginning on the right side). Consequently it is clear that nothing can cure him. The tenotomy may be useful as a help, removing one strain on the nervous system. I should advise it." September 15th. — Esophoria 10°. I now placed the right eye under cocaine and divided the internus, thus correcting the esophoria. September 17th. — Esophoria 3°; abduction 10°; adduction 18°. The patient soon after returned to his home, and I did not hear from him until April 2, 1888, when Dr. W. S. Kendrick wrote me as follows: "C. W. B., was not very much improved by the tenotomy. His mind is quite active and his attacks somewhat modified. Of course he will never be well, but we only hoped for some amelioration of the attacks, which has, in a measure, been attained."

Case III. — Samuel Q. B., age 17, American, came to me on September 15, 1887, with the following letter from Dr. Seguin:

"The bearer, young Mr. B., has had an occasional attack of nocturnal epilepsy (?) in the last four months. Five years ago I apparently cured him of similar attacks, and he has had no relapse for four years. He has had no bromides or other medicine for two months. His last attack occurred in the night of the 10th inst. I think I find astigmatism. Will you kindly examine his eyes fully and let me know the result?"

Upon examination I found: R. V. = $\frac{20}{30}$ +; $\frac{20}{15}$ with +0.75 D. cyl. ax. 90°. L. V. = $\frac{20}{30}$; $\frac{20}{15}$ with +0.75 D. sph. Hyperphoria, R. 1°; esophoria 1°; abduction 5°; adduction 8°.

Ophthalmoscopically, no lesion. Under homatropine I found: R. V. = $\frac{20}{40}$; $\frac{20}{15}$ with +0 75 D. sph. ⌒ +0.75 D. c. ax. 90°. L. V. = $\frac{20}{100}$; $\frac{20}{15}$ with +1.75 D. sph. No hyperphoria; esophoria 2°; abduction 4°; adduction 8°. September 16th.— Esophoria 3°; ordered glasses Rt. +0.50 D. sph. ⌒ +0.75 D. cyl. ax. 90° ⌒ prism 1°, base out. Lft. +1.25 D. sph. ⌒ prism 1°, base out. April 10, 1888. — Has not been especially benefited by the glasses. The attacks now occur every night. He is nervous and jerks all over for a few moments, and then the convulsions confine themselves to his right arm. These spasms continue a minute or two. He seldom loses consciousness, the last time being three or four weeks ago. Tested to-day: R. V. = $\frac{20}{15}$ + with 0.75 D. sph. ⌒ +0.75 D. c. ax. 90°. L. V. = $\frac{20}{15}$, with +0.75 D. sph. ⌒ +0.50 D. c. ax. 180°.

No hyperphoria; esophoria 3°; in accommodation, none; abduction 2°; adduction 14°. April 12th. — Abduction 3°; adduction 14°. April 13th. — Esophoria 3°; adduction 17°. April 14th. — Esophoria 3°; adduction 18°. April 16th. — Adduction 21°. April 19th. — Adduction 19°. April 23d. — Adduction 19°; abduction 4°; esophoria 2°. April 24th. — Adduction 19°; abduction 3°; esophoria 5°. April 26th. — Abduction 3°; adduction 19°; esophoria 3°.

Under cocaine I divided the right internus, leaving orthophoria with abduction 9°. April 27th. — Esophoria 1°; abduction 6°; adduction 21°. April 28th. — Esophoria 5°; abduction 4°; adduction 23°. May 1st. — Esophoria 2°; exophoria in accommodation, 2°; no hyperphoria. R. V. = $\frac{20}{15}$ with +1.50 D. sph. L. V. = $\frac{20}{15}$ with +1.25 D. sph. May 3d. — Esophoria 4°; abduction 3°; adduction 22°. The left eye was now placed under cocaine, and just before operating there was esophoria 2° and abduction 5°. I divided the left internus, leaving orthophoria with abduction 9°. May 4th. — Esophoria 1°; abduction 8°; adduction 19°; ordered glasses without prisms. May 8th. — Esophoria 1/2°; abduction 6°. May 24th. — The patient says he seemed to be considerably improved until last Monday, since

which he has been worse than ever, having had four or five bad attacks every night. He is now under the influence of the bromides.

His muscular condition is orthophoria with abduction 6°. I gave him a wash for a slight conjunctivitis he had developed, and he went to his distant home. "October, 1888. — When last heard from, at end of June, young B. had more attacks than ever before — several every night — in spite of treatment by bromides and tonics. After a careful consideration of the nature of the seizures and their resistance to ordinary treatment, I am strongly inclined to consider them (as I did those 'cured' in 1882) of hysterical nature. E. C. S."

Case IV. — P. J. M., age 26, American, came with a letter to Dr. Agnew from Dr. W. R. Pryor, January 2, 1888: "Mr. M. has had several attacks of a true epileptic character; but one which he has recently had leads me to believe that possibly some of his trouble comes from errors in the eyes; therefore I send him to you. He had a chancre six years ago. His first epileptic attack was on September 10, 1887. His loss of consciousness was complete. His second attack was in October last, beginning as weakness in the left leg, then left hand, and general loss of nervous sensation; muscular action all right; tendon reflexes exaggerated; ankle-clonus not marked; co-ordination perfect. He is taking hydrarg. iodid. gr. ¼ t. i. d., potas. iodid. gr. xxx, t. i. d., and potas. bromid. gr. xxx, at bedtime. Please let me know the result of your examination." Has trouble when he reads; it brings on a tired feeling, as though he was going to have an epileptic attack; not so much in his eyes as in his head; four years ago Dr. Knapp treated him for catarrh of the eyes; being myopic, he wears glasses for distant vision, but reads without; has some twitching of his lower lids. R. V. $=\frac{20}{100}$; $\frac{20}{15}$ with -1.75 D. L. V. $=\frac{20}{200}$; $\frac{20}{15}$ with -2.25 D. February 3d. — Hyperphoria L. ¼; esophoria 2°; none in accommodation; abduction 6°; adduction 25; sursumduction R. 2; L. 2; ophthalmoscope shows myopia 2 D., both; no lesion. February 4th. — Under atropine, the vision and refraction remain unchanged. Hyperphoria R. 1; esophoria 2 to 3; abduction 8. February 6th.— Esophoria 1 to 2; abduction 8; adduction 20.

Dr. Agnew communicated with Dr. Pryor is regard to Mr. M., and he did not return until July 26th. Examination then showed: R. V. $=\frac{20}{15}$ with -1.75 D. L. V. $=\frac{20}{15}$ with -2 D. No hyperphoria; esophoria 3° to 4°; exophoria in accommodation 4; sursumduction R. 2°; L. 2°; abduction 5°; adduction 32°. He complained that reading caused him to have vertigo.

July 27th.—If he reads a few minutes there is a slight pain through his temples, and upon continuing to read, vertigo comes on. He can sometimes read for ten minutes without vertigo. Esophoria 3° at 1′; ordered prisms R. 1°; L. 2°, base out; these having enabled him to read fifteen minutes in the office without vertigo August 7th.—Esophoria, with or without correction of refraction, 3° to 4°; abduction 4 to 5°; adduction 30°. He reports that he now reads with more difficulty than ever before.

Tenotomy of the right internus was done leaving esophoria ½°, with abduction 10°. On the 8th, 9th, and 10th, his esophoria was 2° and his abduction 8°. He says, "he gets along with less uncertainty," and that "he walked more yesterday than he had in any day in several months." August 11th.—Says he does not get about with the same certainty to-day. Esophoria 2° to 3°; abduction 8°. August 13th.—Esophoria 2°; abduction 8°. August 17th.—Esophoria and abduction unchanged; read twenty-five or thirty minutes this morning, with no pain other than the headache he got up with. He has vertigo just about the same as before the operation. Dr. Pryor has diagnosticated "syphilitic endarteritis of the right middle cerebral artery." The diagnosis has been confirmed by Dr. E. G. Janeway. August 24th.—Esophoria 2°; abduction 7°; adduction 24°. August 30th.—The patient says he can read much better than before the operation, but not so well as before he had any head trouble. Writing gives him more trouble than reading. September 15th.—Esophoria ½°; exophoria in accommodation 2°; abduction 8°. The patient says he can read much better than before the operation; and, on the whole, considers himself very much benefited. October 9th.—Esophoria 1°; abduction 6°; patient can read much better than when here last, and considers himself greatly improved.

CASES OF CHOREA.

Case V.—Jack S., age 6 years, was brought to me April 9, 1887, with a letter from Dr. E. C. Seguin, who said: "Mr. and Mrs. S. bring you their little boy, Jack, whose chorea, not due to organic disease, I believe, has resisted a thorough arsenical treatment, with rest, tried last fall. He has never had converging power, and there is a probability that this insufficiency and constant strain is the chief cause of the chorea. Some doubts have been expressed as to his acuteness of vision, but I think he sees fairly well. You will notice that his mother has the same ocular defect to a less degree. Will you examine the eyes thoroughly and undertake the operation.

The parents understand that not too much is expected from the operation. The child takes no medicine now." His mother says he never walked well, and did not walk at all until he was over two years old. He was circumcised a year ago, but it had no effect on the chorea."

It was somewhat difficult to test and examine Jack, as his eyes rolled about on attempting to fix, and were altogether uncontrollable. With the right eye he counted fingers correctly at three feet. With the left I could not get him to count fingers at all. Homatropine was dropped into both eyes to facilitate an ophthalmoscopic examination. It was found that there was atrophy of both optic nerves, the left being the whiter of the two. Dr. Seguin gave the child ether, and I divided the left externus. April 29th. — His mother says he "talks better and walks better" since the operation. May 19th. — Tenotomy of the right internus under ether. "October, 1888. — The final result in this case was very satisfactory, as regards the motor disorder. The chorea entirely passed away, leaving a slight atonic condition of hands, and some uncertainty in walking. This, I believe, was present from the start, and was obscured by the chorea. It should be added that the child had systematic treatment by rest, arsenic, and gymnastics, besides the ocular treatment. Vision not improved, though fixation is better done. E. C. S."

Case VI. — Miss Annie W., age 26, came to consult me on March 29, 1887, on account of chorea with asthenopia. Her eyes had troubled her "quite sometime." She had "quite a good deal" of pain in them, and black spots floating before them all the time. There is a heavy feeling about the eyes constantly, and a "miserable feeling down the back of the head and neck." She used to think she would "go crazy" with it. She has been nervous and run down for over a year, and most of that time she has been under the treatment of various physicians for general chorea. Catamenia normal; bowels regular; eats well and sleeps well; R. V. $= \frac{20}{15}$; Hm. $\frac{1}{72}$. L. V. $= \frac{20}{15}$; Hm. $\frac{1}{60}$. No hyperphoria; exophoria 5°; in accommodation, 5° to 9; abduction 10°; adduction 10°. Ophthalmoscopic examination shows physiological excavation and venous pulsation both eyes, but no lesion. April 5th. — Under atropine, R. V. $= \frac{20}{15}$ with $+\frac{1}{42}$. L. V. $= \frac{20}{15}$ with $+\frac{1}{48}$. April 14th. — Exophoria 3°; abduction 10°; V. $= \frac{20}{15}$ each; no Hm.

Tenotomy of the left externus, leaving orthophoria with abduction, 4°. April 16th. — Abduction 8°; has been more quiet since the operation. April 25th. — Abduction 10°; adduction

8°; exophoria 3°. May 16th.—Exophoria 3° to 5°; abduction 9°; adduction 14°; hyperphoria L. 1°.

Tenotomy of right externus, leaving orthophoria. May 18th.—Much less nervous and back of head and neck better; abduction 8°; exophoria 2°; no hyperphoria. August 10th.—Was quite a good deal better before the warm weather; has the chorea "not nearly so bad," and has very little headache. Orthophoria; abduction 8°; adduction 10°; put on increasing reading tasks. September 10th.—Chorea was better all summer, but has been pretty bad for the last week. R. V. = $\frac{20}{15}$; made clearer by 0.25 D. cyl. ax. 180°. L. V. = $\frac{20}{15}$; Hm. 0.25 D. sph. Hyperphoria L. 2°; exophoria 2°; ordered R. + 0.25 D. cyl. ax. 180°; L. + 0 25 D. sph. ⌒ prism $1\frac{1}{2}$°, base down, for all the time. December 6th.—Chorea decidedly improved; exophoria 3°; in accommodation 8°; abduction 9°; adduction 5°; hyperphoria L. 1°; sursumduction R. 0°; L. 1°; put upon prism gymnastics. January 7, 1888.—The patient writes that she overcomes prisms 50°, base out. March 19th.—Orthophoria; is much improved.

HYSTERICAL CASES.

Case VII.—E. S. A., age 41, civil engineer, came to me on May 8, 1887, with the following letter from Dr. E. C. Seguin: "This note will be handed you by Mr. A., who came to me from the West a few days ago with a diagnosis of incurable 'spinal disease.' I find that he has spinal irritation of extreme degree, most developed in the sacral region, but also marked in occipito-cervical region. He has quasi-periodical paroxysms of excruciating spinal pain, in which he makes contortions which have been termed "convulsions." He has suffered much from using his eyes, and a partial examination made some time ago revealed some faults. I hope that many of Mr. A.'s symptoms are due to eye-strain, and shall not give him much treatment until after you have had a fair chance at his eyes." May 9, 1887: R. V. = $\frac{20}{200}$; $\frac{20}{50}$ with + $\frac{1}{42}$ c. ax. 180° ⌒ — $\frac{1}{15}$ c. ax. 90°. L. V. = $\frac{20}{20}$; $\frac{20}{15}$ with — $\frac{1}{60}$. Hyperphoria 0°; esophoria 3°; in accommodation 3°; abduction 2°; adduction 9°; and sursumduction R. 0°; L. 0°.

Ophthalmoscopic examination shows congenital cataract right; no lesion of left. May 11th.—Under atropine. R. V. = $\frac{20}{40}$ with + $\frac{1}{24}$ c. ax. 15° ⌒ — $\frac{1}{15}$ ax. 105°. L. V. = $\frac{20}{50}$; $\frac{20}{15}$ with + $\frac{1}{60}$ sph. ⌒ + $\frac{1}{72}$ c. ax. 145°. Esophoria 3°; abduction 1°; adduction 9°. May 12th.—Tenotomy of right internus under cocaine and chloroform, after three hours' of fearful semi-convulsions, writh-

ing with pain referred more especially to "small of back," which Dr. Seguin had failed to relieve by hypodermic medication. May 13th. — Patient more comfortable to-day than for years. May 14th. — Orthophoria; abduction 8°; adduction 9°; he has diplopia on looking to the left. May 21st. — Ordered glasses; R. + $\frac{1}{42}$ c. axis 5° ⌒ — $\frac{1}{15}$ c. ax. 95°; L. + $\frac{1}{60}$ sph.

The state of orthophoria remains. September 21st. — Orthophoria; abduction 8°; chalazion right lower lid, excised; he had only one slight attack of semi-convulsions since the tenotomy, and has attended to business as before the attacks began. "October, 1888. The suffering of this patient in his attacks was manifested in such an extraordinary way as to suggest exaggeration or self-delusion. He had a nurse with him whose duty it was to give him chloroform whenever an attack occurred. Hypodermic injection of $\frac{1}{50}$ grain of hyoscyamia undoubtedly controlled the attacks in my hands. He was given strychnia in large doses for several weeks, and went away perfectly well, except that the lumbar spine was still tender. In a few days after the tenotomy the patient expressed himself as feeling better than for two years, claiming that almost immediately after the operation "something gave way" or relaxed in the spinal region. After a severe piece of railroading a short relapse took place in September, 1887, relieved by medical treatment, and I heard in June last that the attacks of Mr. A. had once more returned, under the observation of a physician in Colorado. E. C. S."

Case VIII. — E. S. K., age 35, came to me October 11, 1887, with a letter from Dr. Seguin, who wrote: "I have treated Mr. K. for general symptoms of cerebral fatigue and peculiar attacks, which, I trust, are hysterical. He also has occasional occipital headaches. I find out to-day, by cross-examination, that for several years moving objects, such as scenery out of a car window, vehicles in a crowded street, revolving machinery, etc., have caused distress in head, nervousness, and almost dizziness. He has instinctively avoided such sights for two years or more. I think this justifies an examination of Mr. K.'s ocular muscles."

Examination showed: R. V. = $\frac{20}{20}$; $\frac{20}{15}$ with — 0.25 D. cyl. axis 90°. L. V. = $\frac{20}{20}$; $\frac{20}{15}$ with — 0.25 D. cyl. axis 90°. No hyperphoria; esophoria 2° to 3°; abduction 5°; adduction 20°. October 13th. — Under homatropine: R. V. = $\frac{20}{40}$; $\frac{20}{15}$ with + 0.50 D. sph. + 0.50 D. cyl. axis 180°. L. V. = $\frac{20}{70}$; $\frac{20}{15}$ with + 0.75 D. sph. + 0.50 D. cyl. axis 180°. Esophoria 4° to 5°. October 18th. — Pupils normal. R. V. = $\frac{20}{15}$ with + 0.25 D. cyl. axis 180°.

L. V. = $\frac{20}{15}$ + with + 0.25 D. cyl. axis 180°. Esophoria 2° to 3°; abduction 5°. October 19th. — I cut the right internus in presence of Drs. Agnew, Townsend, Eliot, and J. B. Knapp, leaving his eyes in a condition of orthophoria. October 20th. — The patient reports that he slept well last night, and "feels like a fighting-cock." October 28th. — Orthophoria; abduction 7°. The patient states that he felt well until he went to work at his desk, day before yesterday; then when he went home at night he had a tired head, but not the old headache. December 21st. — Esophoria 1°; abduction 7°; the improvement seems to be permanent.

BLEPHARO-FACIAL SPASM WITH ASTHENOPIA.

Case IX. — T. J. C., age 32, physician, came to Dr. Agnew May 13, 1887. He stated that from the age of 22 to the age of 27, he had frequent attacks simulating *petit mal.* Sometimes, while going about, he would hear a sound like a thunder-clap, sometimes in both ears simultaneously, sometimes in one ear after the other, and sometimes in one ear only. These attacks would often be accompanied by no other symptoms; sometimes a feeling of "rush of blood to the head," with vertigo, and a feeling as though he would fall, but he never fell. These attacks sometimes came half a dozen times a day, and sometimes not for a week, seeming to depend upon the condition of his digestion. He had a great deal of sick headache, usually coming on in the afternoon and lasting until he went to sleep at night. He slept badly, ate moderately, and has a tendency to constipation. He has had an occasional chill; never venereal disease. His eyes were perfect so far as he knows up to seven or eight years ago, when he first noticed blurring of vision in reading. He consulted a New Orleans oculist, who gave him "slight myopic glasses." Seven or eight months later, as his eyes still troubled him, he had them examined under atropine, and got an order for "hypermetropic glasses." He has had one or two changes in his glasses since, but has never gotten along satisfactorily. He has had frequent attacks of conjunctivitis; and has, for several years, been subject to spasm of the eye-lids and cheeks, which, he says, is largely *voluntary*, or under his control. He uses no tobacco, and alcohol only very moderately.

R. V. = $\frac{20}{20}$ +; Hm. $\frac{1}{24}$. L. V. = $\frac{20}{20}$ +; Hm. $\frac{1}{20}$. Esophoria 8°; none in accommodation; sursumduction R. 0°; L. 0°; abduction 4°; adduction 9°. He is wearing Rt. + $\frac{1}{36}$; Lft. + $\frac{1}{24}$. The ophthalmoscope shows no lesion. May 14th. — Dr. Agnew divided what he estimated to be nine-tenths of the left internus,

leaving esophoria 1°; abduction 8°; and adduction 15°. May 15th. — Esophoria 3° to 4°; abduction 8°; changed glass over right eye to + $\frac{1}{24}$. May 19th. — Esophoria 5°; abduction 7°. He does not yet appreciate any improvement from the operation. May 22d. — Esophoria 3°; abduction 7°. June 21st. — Extracts from letters of this date from Dr. J. L. Minor: "He ws at first largely relieved, but is now suffering as much as ever. I enclose the results of my testings on June 3, 1886, and on June 2, 1887.

"*In June*, 1886: + 1.50 D. sph. V. = $\frac{20}{20}$ o. u.; without glasses at 20′ with vert. dipl. 2° convergence; adduction 15°; and abduction 7°. With glasses at 20′ with vert. dipl. there is equilibrium; abduction 6°; adduction 20°. At 14″ vertical dipl. 2° convergence; abduction 22°; adduction 40°.

"*In June*, 1887: R. & V. unchanged. Without glasses, at 20′, vertical diplopia 3° convergence; adduction 30° and abduction 4°. At 20′, with glasses, vertical diplopia 2° convergence; abduction 4°; adduction 30°. With glasses at 14″, vertical diplopia gives equilibrium; abduction 20°; adduction 40°."

May 14, 1888. — Dr. C. returned to me, saying he had not been permanently improved by the tenotomy. Esophoria 4°; abduction 4°; adduction 24°. May 15th. — Adduction 24°. May 16th. — Adduction 25°. May 17th. — Tenotomy of the right internus, leaving exophoria 2°; abduction 10°. May 20th. — Exophoria 10°; abduction 18°. I now readjusted the cut tendon by a stitch, and got homonymous diplopia 6°. There was some reaction following the readjustment: far more than I have seen in any other case of the kind. I had to give him a hypodermic of morphine, and apply iced cloths, atropine, and leeches to the temple. May 23d. — The reaction has passed off, and the patient comes to the office. Esophoria 1° to 2°; abduction 8°. May 24th. — With his glasses, orthophoria at 20′, and in accommodation; abduction 8. June 2d. — Esophoria 1°; abduction 5°. The blepharo-facial spasm seems unaffected by the operation, but the patient can already read with more comfort than before.

INSANITY.

Case X. — T. M. M., age 30, was referred to me at the Manhattan Eye and Ear Hospital by Dr. Seguin, on October 31, 1887. Mr. M., who was a mechanical engineer, and whose business involved the most trying use of his eyes, had completely broken down some years before, in his eyes and in his nervous system. He was unable to use his eyes for more than a minute or two at a time, and his ocular disability wholly unfitted him for profes-

sional work. He had, in consequence, developed melancholia, and had attempted suicide. He had been left for some time in an insane asylum by his friends, and, after his discharge, had been sent on a voyage round Cape Horn. He returned in better condition mentally, but still could not resume work on account of his eyes.

Examination showed: R. V. = $\frac{20}{15}$; Hm. $\frac{1}{60}$. L. V. = $\frac{20}{15}$; Hm. $\frac{1}{48}$. Esophoria 1°; in accommodation 0°; abduction 10°; adduction 18°; sursumduction, R. 4°; L. 5°; ophthalmoscopically normal. November 4th. — Under atropine: R. V. = $\frac{20}{15}$ with + $\frac{1}{72}$. L. V. = $\frac{20}{15}$ with + $\frac{1}{60}$ cyl. ax. 90°. Esophoria 3°. November 11th. — Esophoria 1°. November 18th. — Esophoria 20°; in accommodation 10°.

R. V. = $\frac{20}{15}$; Hm. 0.50 D. L. V. = $\frac{20}{20}$ +; $\frac{20}{15}$ with + 0.50 D. cyl. ax. 90°. The right internus was now divided, leaving a condition of orthophoria, or of slight esophoria. December 1st. — Esophoria 2°; in accommodation 0°; abduction 7°; adduction 35°; sursumduction, R. 1°; L. 1°. December 31st. — Esophoria 1°; abduction 10°; ordered Rt. + 0.50 D. Lft. + 0.50 D. cyl. axis 90°, for constant use. The patient was kept under observation for some time, and, although placed upon reading tasks, which he failed to perform, he finally disappeared without having been especially benefited so far as we could tell.

HEADACHES, ASTHENOPIA, ETC.

Case XI. — Nellie C., age 20, came to me at the Manhattan Eye and Ear Hospital on February 17, 1888. For several years she had suffered from severe headaches, which occurred almost every other day. The pain was principally across the forehead, and very seldom extended to the back of her head. The headaches last two or three hours, and are usually brought on by reading, but sometimes occur without any exciting cause. She has a great deal of facial neuralgia also. Within the past seven months she becomes sleepy after using her eyes in reading or sewing any length of time. She is very often taken with fainting spells, fainting away and becoming quite unconscious. Eight days ago she had two or three such fainting spells. The first fainting spell was about four years ago, when she was attacked with it while grinding coffee. She has usually had these spells not more than once or twice a month. She was ill during the whole of last summer. She was cashier in a store at the time and got very weak.

R. V. = $\frac{20}{30}$; $\frac{20}{20}$ w. + $\frac{1}{72}$. L. V. = $\frac{20}{30}$; Em. Hyperphoria, R. 3°; esophoria 2°; abduction 3°; adduction 16°; sursumduction, R. 4°; L. 5°. February 25th. — Divided the right superior

rectus, leaving the hyperphoria exactly corrected. The patient fainted twice during the operation. February 26th. — She had some headache after reading this morning. February 27th. — Orthophoria; abduction 6°; adduction 16°; sursumduction, R. 3°; L. 3°. March 2d. — Orthophoria. September 14, 1888. — The patient states that she has had no headaches or fainting spells since the operation, a period of nearly a year.

R. V. = $\frac{20}{30}$ —; $\frac{20}{20}$ with + $\frac{1}{60}$ c. ax. 90°. L. V. = $\frac{20}{20}$; Hm. $\frac{1}{60}$. Orthophoria; abduction 5"; adduction 16°; sursumduction, R. 3°; L. 3°.

Case XII. — Rev. F. D. G., age 30, missionary to China, was referred to me by Dr. E. C. Seguin, with the following letter, dated December 27, 1887: "Rev. Mr. G. has congestive symptoms about the head and a degree of nervous prostration — now relieved. Since eight years he has noticed occipital pain and distress on the prolonged use of his eyes, symptoms suggestive to me of muscular insufficiency in accommodation. He has good vision, and to me, his eyes are about emmetropic."

Upon testing Mr. G., I found: R. V. = $\frac{20}{15}$; E. L. V. = $\frac{20}{15}$; Hm. 0.25 D.; hyperphoria, L. 1°; esophoria 1°; exophoria in accommodation 4°; abduction 4°; adduction 14°; sursumduction, R. 3°; L. 2". December 28th. — Under homatropine: R. V. = $\frac{20}{15}$ with + 0.50. D.; L. V. = $\frac{20}{15}$ with + 1 D.; hyperphoria, L. $\frac{3}{4}$°; abduction 7°.

Ophthalmoscopic examination shows physiological excavation of both discs and pulsation of the retinal veins in both eyes. There was no lesion of either eye except a small white spot just above the right macula. December 30th. — Hyperphoria, Left 1°; tenotomy of the *left superior rectus*, slightly over-correcting the hyperphoria. January 3, 1888. — Abduction 7°. January 6th. — Esophoria 2°; hyperphoria, L. $\frac{1}{2}$°; abduction 5°; adduction 18°; sursumduction, R. 4°; L. 3°. He was instructed to exercise his interni daily with prisms. January 9th. — Abduction 1°; adduction 50°; esophoria 6°; in accommodation 6°. January 13th. — Abduction 5°; esophoria 2° to 5°. January 20th. — Abduction 7°; hyperphoria, L. 1°; ordered glasses Rt. + 0.25 D. Lft. + 0.25 D. ⌒ prism 1°, base down, to wear all the time. January 27th. — Abduction 6°; hyperphoria, L. 1°. He said he had experienced relief from the use of the glasses although reading with them for three hours brought on occipital headache, and after continuing the use of them four hours longer, the headache was as bad as ever.

Tenotomy of right inferior rectus, leaving a slight over-correction. February 10, 1888. — He reported that his headache had been better and that he read six or seven hours the day before

without headache. The tests show orthophoria; ordered glasses + 0.25 D., both eyes, without any prism. March 15th. — The patient says his head symptoms have almost disappeared. For a month or more the eyes have been "sore to the touch," and more or less red, especially on rising in the morning. The redness disappears after a while. He has had these inflammatory symptoms since wearing the glasses. He was now advised to stop wearing the glasses, and the camphor and borax wash was prescribed for him. Examination showed orthophoria. June 15th. — I met the patient outside my office and he informed me that he had no special trouble with his head, although he had been hard at work for some months, and that he anticipated a speedy return to his missionary duties. October 2d. — Orthophoria; esophoria in accommodation 6°; abduction 5°; adduction 30°; sursumduction, R. 2°; L. 2°. Mr. G. was unavoidably detained in this country. He considers himself greatly benefited by the tenotomies, and is doing full work with his + 0.25 D.

Case XIII. — Miss Carrie M., age 27, teacher, American, was referred to me by Dr. J. B. Harrison on March 31, 1888. She complained of frontal headache, and that her "eyes get very tired after reading, and that she requires a very strong light."

R. V. $=\frac{20}{15}$; Em.; L. V. $=\frac{20}{30}$; improved by + 0.50 D. cyl. axis 90°; hyperphoria, R. 1°; exophoria in accommodation 4°; sursumduction, R. 3°; L. 2°; abduction 10°; adduction 13°. Ophthalmoscopic examination shows old corneal opacities of left eye; ordered, for right eye a plane glass; and for left eye a prism 1°, base up; ordered, also, an eye-wash for a slight conjunctivitis. On May 14th following, Dr. Harrison wrote: "Miss M. is about the same. She has used the glasses constantly, has faithfully applied the eye-wash, and has favored her eyes all a school teacher could. She complains still of constant discomfort and imperfect vision." July 20th. — R. V. $=\frac{20}{15}$ —; Em. L. V. $=\frac{20}{30}$; made $\frac{20}{20}$ with + 0.50 D. cyl. axis 90°; hyperphoria, R. $1\frac{1}{2}$°; exophoria 3°; abduction 10°; adduction 15°. July 21st. — Under atropine: R. V. $=\frac{20}{15}$; E. L. V. $=\frac{20}{40}$; $\frac{20}{30}$ with + 0.50 D. cyl. ax. 90°; hyperphoria 0°; exophoria 2°, sursumduction, R. 3°; L. 2°; abduction 9°; adduction 19°. July 31st. — Exophoria $\frac{3}{4}$°; in accommodation 5°; ordered for right eye plane glass, and for the left eye + 0.50 D. cyl. ax. 90°. August 20th. — Patient says she has had a great deal of pain for the last ten days. It seems to be right across the balls of both eyes. She also has a very annoying *burning* sensation in the eyes, which is worse when she is out in the open air. Hy-

perphoria, R. $\frac{1}{2}^{\circ}$; exophoria 3°; sursumduction, R. 3°; L. 2°; abduction 10°; adduction 15°.

Tenotomy of right superior rectus, very slightly over-correcting the hyperphoria, and leaving exophoria 1°. August 21st. — No hyperphoria; exophoria 1°. August 23d. — No hyperphoria; exophoria 1° to 2°; patient has had no pain since the operation. August 30th. — The patient says she has a peculiar feeling in her eyes. She tried to sew and that feeling came over them and she had to stop. No hyperphoria; exophoria 1°; abduction 10°. September 13th. — Eyes have the same peculiar feeling, though not so often. No hyperphoria; exophoria 2°; in accommodation 6°; abduction 12°; adduction 15°; sursumduction, R. 2°; L. 3°.

Tenotomy of left externus, leaving esophoria 1°, and abduction 6°. September 14th. — Orthophoria; eyes feel very comfortable; to go on with her teaching. October 2d. — No hyperphoria; exophoria $\frac{1}{2}^{\circ}$; abduction 10°. The patient volunteers the statement that for several years she has been subject to attacks of nausea and vomiting. These attacks have been worse for the last two years. She has had only one attack since the tenotomy, and that immediately after.

Case XIV. — Miss Sadie B., age 27, came to my clinic at the Manhattan Eye and Ear Hospital on April 11, 1887, with granular lids and pannus of three years' standing. R. V. $= \frac{20}{200}$; Hm. $\frac{1}{36}$. L. V. $= \frac{20}{40}$ with $+ \frac{1}{40}$ c. ax. 90°. January 23, 1888. — The trachoma and pannus have been cured for some time, but with resulting corneal opacities. For more than a year she has had almost constant pain through her temples and in the back of her eyes. Her eyes feel as if they were "rolling about," even when closed. R. V. $= \frac{18}{200}$; no improvement with glasses. L. V. $= \frac{20}{40}$; no improvement with glasses; hyperphoria, L. 2°. January 25th. — Hyperphoria, L. 2°; *tenotomy of left superior rectus*, making an accurate correction of the hyperphoria. January 26th. — The hyperphoria remains corrected. January 27th. — Hyperphoria, L. 1°. The patient states that she has less headache since the operation, and that the rolling sensation has disappeared. February 3d. — Hyperphoria, L. 1°. The headaches are better. February 13th. — Hyperphoria, L. 1°. The eyes still roll some, but within the last week there is less pain back of them. February 29th. — Hyperphoria, L. 1°. The patient says the pain in the left eye is less, but as bad as ever in the right. March 9th. — Hyperphoria, L. 2°; exophoria 3°. Her eyes have felt very well up to to-day, when both "have hurt her a great deal." March 20th. — Hyperphoria, L. 3°;

tenotomy of right inferior rectus, correcting the hyperphoria. May 25th. — Orthophoria; considerable conjunctivitis. There has been no sensation of rolling since the last operation, but the eyes feel sore and ache, and tire easily.

Case XV. — Josephine C., age 23, came to my clinic at the Manhattan Eye and Ear Hospital, complaining of having been disturbed for the last two years by "wavy lines, up and down," which appeared at a distance of three or four feet out on either side of the head. September 9th. — R. V. $= \frac{20}{70}$; $\frac{20}{50}$ with $+ \frac{1}{14}$. L. V. $= \frac{20}{20}$; Hm. $\frac{1}{18}$; exophoria 5°; in accommodation 9°; abduction 2°; adduction 6°; sursumduction, R. 16°. September 12th. — Hyperphoria, R. 12°; exophoria in accommodation 9°. November 2d. — *Tenotomy of right superior rectus.* After the tenotomy there remained hyperphoria, R. 3°; exophoria 3°; in accommodation 3°; sursumduction, R. 9°; abduction 8°; adduction 7°. November 7th. — Hyperphoria, R. 3°; esophoria 2°. November 9th. — Hyperphoria, R. 5°; esophoria 10°; abduction 10°; adduction 30°; sursumduction, R. 5°; L. 6°.

Case XVI. — Mrs. Dr. E. C. H., age 21, consulted me about her glasses on December 30, 1880. Her myopia came on at the age of 8 or 10. She complained that her eyes bothered her when doing fancy worsted work and when reading at night, and she thought she was becoming more near-sighted. She had been subject to sick-headaches and had a peculiar sensitiveness along the dorsal spine. V. $= \frac{20}{200}$ with her glasses, $- \frac{1}{13}$. Ophthalmoscopic examination showed a high degree of compound myopic astigmatism. Homatropine was dropped into both, when we found: R. V. $= \frac{5}{200}$; $\frac{20}{50}$ with $- \frac{1}{12}$ s. $\frown - \frac{1}{12}$ c. ax. 45°. L. V. $= \frac{8}{200}$; $\frac{20}{50}$ with $- \frac{1}{11}$ s. $\frown - \frac{1}{16}$ c. ax. 160°. January 7, 1881. — Ordered: Rt. $- \frac{1}{11}$ s. $\frown - \frac{1}{16}$ c. ax. 160°. Lt. $- \frac{1}{11}$ s. $\frown - \frac{1}{15}$ c. ax. 160°. July 21, 1884: R. V. $= \frac{20}{40}$ with $- \frac{1}{10}$ s. $\frown - \frac{1}{15}$ c. ax. 150°. L. V. $= \frac{20}{40}$ with $- \frac{1}{12}$ s. $\frown - \frac{1}{10}$ c. ax. 150°. The above glasses were ordered for all the time. January 7, 1888. — The patient, having broken her glasses, came to see if any change should be made in them before ordering another pair. She incidentally spoke of her severe and frequent headaches, and I proposed to test the muscular condition of her eyes, which had heretofore been overlooked. I found hyperphoria, R. 2 ; abduction 9°; no esophoria or exophoria. January 9th. — Hyperphoria, R. 3°; exophoria 1°; in accommodation 14°; abduction 10°; adduction 33°; sursumduction, R. 5°; L. 3°. R. V. $= \frac{20}{70}$ with $- \frac{1}{10}$ s. $\frown - \frac{1}{15}$ c. ax. 50°. L. V. $= \frac{20}{50} +$ with $- \frac{1}{12}$ s. $\frown - \frac{1}{24}$ c. ax. 150°.

This patient saw in consultation Dr. W. Oliver Moore, Dr. J. S. Norton, and Dr. George T. Stevens, all of whom found

from 6° to 8° of hyperphoria of right eye, and all of whom advised its correction by tenotomy. Dr. Moore found that the red glass over one eye brought out vertical diplopia.

January 28th. — *Tenotomy of right superior rectus*, Drs. Harwood and Gruening being present. Immediately before the operation the hyperphoria was 8°; immediately after it was less than ½°. There was an unusual amount of bleeding under the conjunctiva. The next day I visited this patient at her house, and found her reading the newspapers. January 30th.— She called at my office, was examined, and then went down town. January 31st. — Hyperphoria, R. 1°. February 9th. — Hyperphoria, R. 3°. She had a severe headache a week ago, the only one since the day after the operation. June 2d. — Hyperphoria, R. 1°. The patient had a severe attack of *erythema nodosum* coming on soon after her last visit to my office and confining her to bed for several weeks. She has had only two headaches — one eight weeks ago and one yesterday. September 13th. — Hyperphoria, R. 3°. She has suffered a good deal with facial neuralgia through the summer. She had a headache caused by a long ride on the rail cars. September 23d. — *Tenotomy of left inferior rectus*, leaving a correction of the hyperphoria. The bleeding was excessive, as before. September 24th. — Confined to her bed with a severe cold and bronchitis. September 25th. — Is better, though still confined to her room. September 26th. — Hyperphoria, R ½°. October 5th. — Hyperphoria, R. 2°; has had no headache or neuralgia since the attack she was suffering from at the time of the last operation.

Case XVII. — Dr. W. S. K., age 32, consulted Dr. C. R. Agnew on April 25, 1877. He stated that he had no trouble with his eyes until September, 1876, when neuralgic pains about the root of his nose set in while reading. Then there was a feeling of severe tension over his brow while reading. He used belladonna ointment over his brows until his accommodation grew weak, and he had to give up reading altogether. He then became excessively nervous all over. He consulted Soelberg Wells, who dilated his pupils and found his fundus normal, but that he had Ht. $\frac{1}{30}$ each eye. He has worn + $\frac{1}{30}$ constantly since.

Dr. K. says his eyes first "broke down" while working all day with the ophthalmoscope and microscope, and then reading late at night. At Christmas he observed that he would become worse when the gas was lighted. He went to church on one occasion, and the bright light caused great infra-orbital neuralgia and neuralgia of the third division of the fifth nerve. This

has been confirmed a dozen times. Reading or walking in bright sun-light invariably brings on pain in the inferior maxillary region, the pain being more especially referred to the front teeth below. His teeth were never tender in mastication, and he has only one carious tooth, the first molar on the right side, and that is well filled. He is troubled with spasms about his internal canthi when he lies down. His digestion seems to be good. Never venereal disease. His father was rheumatic and perhaps gouty. He says he is as nervous as a hysterical woman. He jerks and starts when he goes off to sleep. He suffers from sciatica of the left hip, but he attributes that to a fall from a horse when a boy.

V. = $\frac{20}{20}$ each with + $\frac{1}{24}$. No insufficiency. Ophthalmoscopic examination gives him excruciating pain, lasting twenty-four hours or less.

The patient was referred to Dr. E. C. Seguin for an opinion. Dr. Seguin wrote:

"April 25, 1877, Dr. K.'s case has seemed very interesting to me. I am disposed to look upon his hyperæsthesia (face and limbs) as due primarily to insufficient nutrition. He has worked hard and used a diet, which I look upon as perfectly fitted to develop anæmia and neuralgia. I would suggest beefsteak and roast meats twice a day, ale or claret for dinner, and not much starchy food. Thompson's solution of phosphorus may also do good, and relief may be had by the positive pole of the galvanic battery. I don't find the usual symptoms of asthenopia."

April 26th. — Hm. $\frac{1}{24}$ each. Cooper, and Wells, and Purvis, of London, all examined his eyes under atropine and found that his Ht. was + $\frac{1}{24}$. April 19, 1887. — The patient returns to me with a letter from Dr. A. W. Calhoun of Atlanta. He stated that he got no relief from his glasses, and finally discarded them altogether. Since ten years ago he has suffered agony every hour that he has been awake, and he has been kept awake many nights with pain through the temples, through the roots of the nose, and through the teeth and molar bones. The main pain is through the malar bones and nose No pain in top of head or in occipital region. R. V. = $\frac{20}{20}$ —; $\frac{20}{20}$ with + $\frac{1}{40}$; L. V. = $\frac{20}{20}$ —; $\frac{20}{20}$ with + $\frac{1}{48}$. No hyperphoria; esophoria 2°; abduction 2°; adduction 12°. May 7th. — Esophoria 4°; in accommodation 0°; hyperphoria, R. 1°; abduction 4°; adduction 13°; sursumduction, R. 0°; L. 0°. The patient was now referred to a physician skilled in diseases of the nose, who found that he had a deviated septum and operated upon it. He also operated upon his hypertrophied turbinated bone, but without much apparent benefit. May 12th. — *Tenotomy of right internus*, leaving ortho-

phoria, with abduction 8 ; as found on testing half an hour after the operation. May 13th. — Went to bed last night with a freedom from pain, which he has not experienced for years. Esophoria 4° ; abduction 8°. May 21st. — Orthophoria ; abduction 7° ; adduction 19° ; much improved. April 2, 1888. — The patient writes, "I have done a hard winter's work in the college and with my practice, and my eyes have held up very well."

Case XVIII. — J. P. S., age 25, came to the clinic at Manhattan Eye and Ear Hospital in November, 1877, complaining of an almost constant pain in both eyes. He was a theological student, and after studying all day the pain was much worse. His eyes felt hot and inflamed, and the heat of the fire seemed to aggravate the condition We found: R. V. = $\frac{20}{20}$; $\frac{20}{10}$ with + $\frac{1}{60}$ c. axis 75° ; L. V. = $\frac{20}{20}$; $\frac{20}{10}$ with + $\frac{1}{60}$ c. axis 105° ; abduction 6° ; adduction 6° ; sursumduction, R. 2° ; L. 2°. The above glasses were ordered for constant use.

December 27th. — The symptoms are only partially relieved by the glasses. Under atropine: R. V. = $\frac{20}{30}$; $\frac{20}{10}$ with + $\frac{1}{48}$ c. ax. 75° ; L. V. = $\frac{20}{30}$; $\frac{20}{10}$ with + $\frac{1}{48}$ c. ax. 105° ; abduction 9° ; adduction 8°. Put on prism exercises daily of his interni. December 28th. — Adduction 13°. December 29th. — Adduction 14°. December 30th. — Adduction 19°. December 31st. — Adduction 23°.

January 1, 1888. — Adduction 28°. January 2d. — Adduction 56°. January 4th. — Adduction 90°. January 5th. — Adduction 108°. January 6. — *Tenotomy of right internus*, leaving abduction 8°, with exophoria 2°. January 7th. — Abduction 8° ; esophoria 3° ; adduction 58° ; prisms over one eye, 108° prisms over both. January 13th. — Orthophoria ; abduction 8° ; adduction 120°. The patient now uses his eyes in studying without pain, and expresses himself as satisfied with the result. March 1st. — The patient says his asthenopic symptoms are now as bad as ever. Orthophoria ; abduction 7° ; ordered the cylindrics, which corrected his astigmatism under atropine, for constant use. March 28th. — He still has some pain in his eyes, though not as severe as formerly.

Case XIX. — B. M. G., age 22, consulted Dr. Agnew and myself on October 27, 1887, on account of his eyes. He was a theological student and had got so that he could not read "any length of time," with or without glasses, without bringing on headache and nausea. His glasses, which were ordered by Dr. Culver of Albany, were a good correction, — were: R. + 0.75 D. cyl. ax. 45° ; L. + 0.50 D. cyl. ax. 150°. These glasses raised his V. from $\frac{20}{40}$ to $\frac{20}{20}$ with his right eye, and from $\frac{20}{30}$ to $\frac{20}{10}$

with his left eye. Ophthalmoscopic examination showed physiological excavation and venous pulsation of both. Hyperphoria, R. 1°; esophoria 4°; abduction 4°; adduction 30°; sursumduction, R. 1°. October 28th. — Under homatropine: R. V. = $\frac{20}{20}$; $\frac{20}{10}$ with + 0.75 D. axis 45°; L. V. = $\frac{20}{40}$; $\frac{20}{20}$ with + 0.50 D. axis 150°. Abduction 3°; adduction 9°; esophoria 9°; with or without his glasses. October 31st. — Dr. Agnew did a careful tenotomy of the right internus at the Manhattan Eye and Ear Hospital. Immediately before the operation he had esophoria 6°; abduction 5°; adduction 25°; hyperphoria, R. 1°; sursumduction, R. 2°; L. 1°.

November 3d. — Esophoria 5°; hyperphoria, R. 1°; abduction 6°; adduction 25°; sursumduction, R. 2°; L. 2°. November 9th. — Esophoria 2°; abduction 5°; adduction 32°; sursumduction, R. 2°; L. 2°; hyperphoria 0°.

January 18, 1888. — Esophoria 2°; abduction 4°; adduction 43°; no hyperphoria. January 19th. — No hyperphoria; esophoria 5°; abduction 5°. January 20th. — Muscular condition unchanged. The patient can now do near work for more than an hour without discomfort.

March 13th. — Mr. G. writes: "Before I went to the hospital I got so I was unable to read fifteen minutes without severe headache and a peculiar feeling that seemed to prevent my brain from operating. Sometimes this was accompanied by nausea, and I was under constant nervousness that was very trying. For a time after the operation was performed the headaches continued. Then they gradually decreased until, at the present time, I am able to use my eyes for from two to three hours with very little unpleasantness. For the past three weeks I have been assisting in revival services, and have, during that time, done the study and work required to get up a sermon without once thinking of my eyes."

May 29. — Esophoria 4° to 10°; abduction 5°; adduction 90°; hyperphoria, 0°; sursumduction, R. 2°; L. 2. As there was some return of the asthenopic symptoms, I now *divided the left internus*, leaving abduction 8°, with esophoria 12°. May 30th. — Esophoria 14°; abduction 5°. May 31st. — Esophoria 4° to 9°; abduction 7°.

August 24th. — A letter from Mr. G. says: "My eyes are now in a condition of orthophoria. Of prisms, base out, I can overcome as much as ever; base in, I have gone as high as 10°, but that varies. I have more use of my eyes than just before the last operation. I can use them for a couple of hours a day for a week or more, and then they gradually run down and I have to rest them again."

Case XX.—A. J. C., age 20, single, artist, came under observation May 17, 1887. His eyes broke down in January and he consulted Dr. Miller of Providence, who had him under treatment for two months; gave him glasses, and advised tenotomy of an internus. My examination showed: R. V.$=\frac{20}{10}$; Hm. $\frac{1}{48}$; L. V.$=\frac{20}{10}$; Hm. $\frac{1}{48}$. No hyperphoria; esophoria 20°; in accommodation 20°; abduction 5°; adduction 30°; sursumduction, R. 2°; L. 2°; ophthalmoscopically, no lesion. After trying both eyes together, I ordered + 1.50 D. ⌒ prism $2\frac{1}{2}$°, base out. May 23d.—No relief from the glasses; *tenotomy of right internus.*

June 6.—Esophoria 8°; in accommodation 12°; abduction 7°. June 8th.—Under atropia: R. V.$=\frac{20}{40}$; $\frac{20}{20}$ with $+\frac{1}{20}$; L. V.$=\frac{20}{70}$; $\frac{20}{10}$ with $+\frac{1}{36}$ s. ⌒ $+\frac{1}{60}$ c. axis 90°. July 18th.—Esophoria 4°. July 27.—Esophoria, with refraction corrected, 4"; without, 5°. March, 1888.—Esophoria 4°; abduction 7; adduction 36°. The patient says he has been greatly relieved by the operation and the prisms, but that he cannot do his work without his glasses. August 10th.—He worked at his art from January 1st to June 1st, but not more than three hours a day. His eyes broke down again in June. August 11th.—Esophoria 6° to 18'; in accommodation 14°; abduction 5°; *tenotomy of left internus*, leaving orthophoria and abduction 10°. August 12th.—Orthophoria; abduction 10°; sursumduction, R. 2°; L. 2°, with correction of the hypermetropia; without correction, esophoria 6°; abduction 8°. October 6th.—Esophoria 3°; in accommodation 6°; abduction 6°. With correction of refraction, exophoria $\frac{1}{2}$°; esophoria 9° in accommodation; abduction 8°; can work three hours a day; has not the same tendency to lose the focus by crossing of the eyes as before the operation.

Case XXI.—Wm. H., age 44, married, merchant, came May 23, 1887. Mr. H. was troubled with headache all his life, and supposed it was due to indigestion until three years ago, when it was suggested that it might be due to eye-strain. He then went to Dr. Stevens, who gave him glasses and exercised his ocular muscles with prisms. The glasses relieved his headaches; but recently he has had a relapse. If he reads at all without his glasses, or even three minutes with them, "his head is wrong," and he becomes intensely sick all over, but does not vomit. His general health is good, his bowels regular; he sleeps well. He never had any disease except malaria. R. V. $=\frac{20}{20}$; Hm. $\frac{1}{60}$; L. V.$=\frac{20}{20}$—; $\frac{20}{20}+$ with $+\frac{1}{60}$ c. ax. 90°. Esophoria 3° to 6°; in accommodation 15°; no hyperphoria; abduc-

tion 2°; adduction 23°; sursumduction, R. 0°; L. 0°. His glasses are prisms, base out. May 24th. — *Tenotomy of left internus*, leaving orthophoria.

September 20th. — Mr. M. thinks he was helped very much by the operation, but is not entirely relieved. September 21st. — Esophoria 6°; abduction 2°; adduction 22°; *tenotomy of right internus.*

October 10th. — No headache since the last operation; wears no glasses, and uses his eyes with comfort; orthophoria.

Case XXII. — John H., age 42, brother of the last patient, consulted Dr. Agnew and myself on April 9, 1888. He had always been subject to headache more or less, and had thought it "due to his liver," until attention was called to his eyes. He had worn glasses for two years, prescribed by Dr. Stevens, and the Dr. had cut both his interni. His headache had, in this way, been partially relieved. R. V. $=\frac{20}{20}$; $\frac{20}{15}$ with -2.25 D. s. $\frown$ 0.25 D. c. ax. 180°; L. V. $=\frac{20}{40}$; $\frac{20}{20}$ with -1 D. cyl. ax. 180°. April 14th. — Under atropia: R. V. $=\frac{20}{15}$; Em.; L. V. $=\frac{20}{100}$; $\frac{20}{15}$ with $+0.50$ D. c. ax. 90° $\frown$ -1.50 D. c. ax. 180°. No hyperphoria; esophoria 6°; abduction 8°; adduction 18°.

September 6th. — Mr. H. says his headaches now occur about once a month, generally on waking in the morning and lasting over four hours. After reading a long time he has a "feeling of tightness" in the head. With his refraction corrected he has esophoria 7°; in accommodation 4°; abduction 8°; no hyperphoria; without glasses, esophoria 5°; in accommodation 3°; abduction 8°; *tenotomy of left internus*, leaving orthophoria and abduction 12°. September 7th. — Esophoria 10°; abduction 8°; no hyperphoria. October 4th. — Esophoria 3°; abduction 8°; has been wearing concave cyls. with prisms, base to nose, and is not relieved; changed glasses to — cyls. with prisms, bases out.

Case XXIII. — R. H. O., age 47, consulted me on May 8, 1888. His eyes pain him a great deal at times if he uses them much. Preceding the pain his eyes blur, and following the pain in the eyes is a headache. He uses $+2$ D. both for reading. R. V. $=\frac{20}{20}$; $\frac{20}{15}$ with $+1.25$ D. s. $\frown$ $+0.50$ D. c. ax. 180°; L. V. $=\frac{20}{15}$; the same with $+0.75$ D. s. $\frown$ $+0.50$ D. c. ax. 180°. No hyperphoria; esophoria 3°; in accommodation 0°; abduction 4°; adduction 45°; sursumduction, R. $1\frac{1}{4}$°; L. 2°; ophthalmoscopically, no lesion. May 10th. — Under homatropine: R. V. $=\frac{20}{70}$; $\frac{20}{15}$ w. $+1.25$ D. s. $\frown$ $+0.50$ D. c. ax. 180°; L. V. $=\frac{20}{70}$; $\frac{20}{15}$ w. $+1.25$ D. s. $\frown$ $+0.25$ D. c. ax. 180°. No hyperphoria; esophoria 3°; abduction 4°. May 14th. — R. V. $=\frac{20}{20}$ with $+$

1.25 D. s. ⌒ + 0.25 D. c. ax. 180°; L. V.=$\frac{20}{20}$ with + 1 D. No hyperphoria; esophoria 3°; abduction 5°. May 15th.—V=$\frac{20}{15}$ with + 1 D. each. For the distance, ordered + 1 D. ⌒ prism 1°, base out, each. For reading, + 2.75 D., both. May 31st.—Has less headache, but still has a good deal of pain in the eye-balls; ordered + 1 D. ⌒ prisms 1½° each, base out, and medium smoke glasses for bright light.

August 21st.—Has more or less headache and pain in eye-balls on using his eyes. Esophoria 4°, with hypermetropia corrected. Without correction, esophoria 8°; abduction 5°; adduction 22°; sursumduction, R. 1°; L. 1°. August 22d.—Muscular condition unchanged; *tenotomy of left internus*, leaving orthóphoria, with abduction, 10°. August 23d.—Esophoria 1°; abduction 8°. In coming over from Brooklyn this morning, he did not have the usual strained feeling in looking about at various objects. September 5th.—Eyes have have "felt first rate." Hyperphoria 0°; esophoria 5°, without correction of hypermetropia. With correction, esophoria 1°; abduction 5°.

Case XXIV.—Miss Alice A., age 27, consulted on June 13, 1887. After using her eyes she has headache. She cannot look steadily at anything. Her father died insane. His mother, sister, and cousin also were insane. She has a cousin in an insane asylum. She broke down after a hard winter's work, and has since had headache almost without intermission. She has a feeling in the back of the head and neck as if her head were being drawn back. She also has a "jumping headache" all over the top of her head. The jar of walking hurts her. Sometimes she feels "sort of lost," as if she did not know anything. For many years she has observed that her left pupil is a little smaller than the right. R. V. = $\frac{20}{20}$ —; Hm. $\frac{1}{48}$; L. V. = $\frac{20}{20}$ —; Hm. $\frac{1}{48}$. Spectacles + $\frac{1}{40}$ were prescribed, and she was put upon increasing reading tasks.

August 20th.—She now reads four hours a day with her glasses. Exophoria 12°; abduction 15°. She has single binocular vision in reading. *Tenotomy of left externus*, leaving orthophoria. June 21st.—The headache she had yesterday before the operation was forgotten after it, and has not come on since.

August 27th.—She has done her usual work as governess since last here. She has experienced none of the "drawing feeling" in the back of the head and neck, but she had a tired feeling. Orthophoria; abduction 10°; adduction 12°.

Case XXV.—Bridget C., age 43, came to the clinic at the Manhattan Eye and Ear Hospital on October 2, 1885. She complains that she cannot see well; that her eyes ache after

use; that she has a swimming sensation, and has pain through her temples. R. V. = $\frac{20}{30}$; Hm. $\frac{1}{18}$; L. V. = $\frac{20}{20}$; Hm. $\frac{1}{10}$; reads J. 1 at 9″ with + $\frac{1}{10}$. Exophoria 12°; in accommodation 29°. Ophthalmoscopic examination shows no lesion. Glasses Rt. + $\frac{1}{18}$; Lft. + $\frac{1}{20}$ were ordered for the distance, and + $\frac{1}{10}$, both eyes, for near work.

June 4, 1886.—Exophoria 12°; in accommodation 28°. The patient says the glasses gave complete relief from the pain in her eyes and head, and also from the dizziness for five or six months, and then the symptoms returned and were as severe as before. She has been advised to have a tenotomy of an external rectus, but refused. July 2, 1886.—Exophoria 7°; in accommodation 14°; *tenotomy of right externus.* July 23d.—Orthophoria; exophoria in accommodation 3°. The patient states that the tenotomy did not give immediate relief, but after three or four weeks relief was complete, though she was compelled to continue the use of her glasses to insure comfort.

April 6, 1888.—The patient says she does not see with her glasses so well as at first, and that for the last three or four months she has had occasional attacks of pain in the eyes and in the head, but the pain is not constant nor so severe as it used to be. Orthophoria; R. V. = $\frac{20}{100}$; $\frac{20}{15}$ with + $\frac{1}{10}$; L. V. = $\frac{20}{100}$; $\frac{20}{20}$ with + $\frac{1}{15}$; reads Jaeger No. 1 at 8″ with + $\frac{1}{9}$; prescribed + $\frac{1}{15}$ for the distance, and + $\frac{1}{9}$ for the near.

Case XXVI.—W. J. T., age 30, consulted me on August 9, 1887. His eyes have had a strained feeling and the lids would get red. The surface of the eye-ball is bloodshot, especially over the internal rectus. In 1879 and 1880 he suffered greatly from headaches, which were relieved by glasses. He is now wearing Rt. prism 2°, base in; Lft. — $\frac{1}{18}$ s. ⌒ prism 4°, base in. R. V. = $\frac{20}{20}$ —; $\frac{20}{20}$ + w. + 0.50 D. c. ax. 90°; L. V. = $\frac{15}{200}$; $\frac{20}{15}$ w. — 2 D. ⌒ — 1.50 D. c. ax. 180°. Exophoria 10°; in accommodation 15°; abduction 15°; adduction 5°. August 10th, — *Tenotomy of left externus.* August 11th.—Exophoria 15°. August 12th.—Exophoria 6°; abduction 15°. August 13th. —Exophoria 8°; abduction 15°; adduction 22°. August 14th. —Exophoria 15°; abduction 15°; adduction 25°; ordered Rt. + 0.25 D. c. ax. 90° ⌒ prism 4°, base in; Lft. — 2 D. ⌒ — 0.50 D. cyl. ax. 180 ⌒ prism 2°, base in.

August 30, 1888.—The patient has just returned from an European tour. He has had no headache since the tenotomy. He has worn the glasses constantly. No hyperphoria; exophoria 20°; abduction 24°; adduction 20°. He has no redness of his eyes, and no trouble relating to his eyes or head since the tenotomy.

Case XXVII. — Mrs. H. W. B., age 44, consulted Dr. Agnew January 9, 1888. She complained that, on using her eyes, a pain would come in them and then the sight would get dim. There is constant sense of weight in her eyes. If she sews or reads things get double, a phantom or shadow following the real object. She has much headache and feels better when lying down. R. V = $\frac{20}{20}$; E.; L. V. $\frac{20}{20}$; E. Abduction 2°; adduction 12°. January 10th. — Esophoria 1°; abduction 1°; adduction 16°; hyperphoria 0°; sursumduction, R. 1°; L. $\frac{1}{2}$°. Ophthalmoscope shows physiological excavation; no lesion.

March 6th. — Esophoria $\frac{1}{2}$°; exophoria in accommodation 6°; abduction 2°; adduction 16°; no hyperphoria. March 7th. — Esophoria 2°; abduction 2°; *tenotomy of left internus by Dr. Agnew*, leaving exophoria 1°, and abduction 5°. March 9th. — Esophoria 2°; abduction 2°. March 10th. — Esophoria 3°; exophoria in accommodation 6°; abduction 1°; adduction 18°. March 14th. — Esophoria 3°; abduction 2°. March 23d. — Esophoria 1°; abduction 2°.

April 4th. — Esophoria 1°; abduction 2°; adduction 14°.

May 14th. — Esophoria 2° to 3°; exophoria in accommodation 2° to 3°; abduction 2°; adduction 14°; sursumduction, R. 1°; L. 1°. May 7th. — Esophoria $\frac{1}{4}$°; abduction 2°. May 18th. — Esophoria 4°; exophoria in accommodation 2°; abduction 2°; adduction 22°. May 24th. — Esophoria 1° to 2°; abduction 2; adduction 21°; *tenotomy of right internus*, leaving abduction 8° and exophoria $\frac{1}{2}$°. May 25th. — Esophoria $\frac{1}{2}$°; abduction 5°; adduction 18°. May 26th. — Bleeding occurred from the wound at 4 P. M. The blood also came from the nose and mouth. The bleeding continued two hours and a half, and was much more than at the operation. May 28th. — Esophoria $\frac{1}{2}$° to 2°; abduction 5°; adduction 19°. May 31st. — Esophoria $\frac{3}{4}$°; abduction 3°; adduction 18°. A letter from Mrs. B., dated August 4, 1888, says: "For about two weeks after I saw you my eyes were comfortable. Then the feeling of drawing of the muscles and the aching began again, and I have seldom been free from pain since, in greater or less degree. Abduction 2°; adduction 18°."

Case XXVIII. — Miss Jane C., age 23, came on August 10, 1887. Her trouble began five years ago while at school. She complains of "heaviness in the head" and of "a very peculiar feeling where the neck joins the head, like a tightening, as if a screw were put in." Towards the end of the day it gets worse. The top of her head feels "as if the muscles were drawn up together and tied in a knot." Often she has a burning sensation there. Her hands and arms are weak, and when she is tired

they tremble. Menstruation scanty; no pain; digestion poor; has to take violent exercise in order to digest anything. R. V. $=\frac{20}{15}$; E.; L. V. $=\frac{20}{15}$; E. Hyperphoria, L. $\frac{1}{2}°$; exophoria 1°; abduction 9°; adduction 18°; sursumduction, R. 3°; L. 3°. August 13th. — Exophoria 2°; abduction 8°; adduction 15°. August 15th. — Hyperphoria, R. 1°; exophoria 3°; abduction 8°; adduction 22°. Glasses were prescribed. Rt. prism 1°, base down; Lft. prism 2°, base in, to wear all the time. August 24th. — A great deal of the pain has left the back of her head, but there is still "quite a pulling."

September 7th. — Exophoria 8°; abduction 10°; *tenotomy of left externus.* September 27th.—Exophoria 2°. This patient was only partially relieved by the tenotomy and by glasses.

Case XXIX. — W. G. B., age 46, came with the following letter from Dr. E. C. Seguin September 30, 1887: "Mr. B. has, besides anemia and dyspepsia, certain head symptoms, which I think are asthenopic. Convergence hurts his head; moving objects cause dizziness and nausea. He had a short period of diplopia in May last. I find no positive evidence of organic cerebral disease." Mr. B. says he never had any trouble with his eyes till very recently. R. V. $=\frac{20}{20}$; $\frac{20}{15}$ with + 0.50 D. c. ax. 90°; L. V. $=\frac{20}{15}$; sharper with + 0.50 D. c. ax. 90°; A. $=\frac{1}{12}$. Abduction 4°; adduction 16°; esophoria 1°; hyperphoria, R. °1. Ophthalmoscopically, no lesion; optic discs look hyperæmic.

October 1st. — Under atropia: R. V. $=\frac{20}{70}$: $\frac{20}{15}$ with + 0.75 D. s. ⌒ + 0.50 D. c. ax. 90°; L. V. $=\frac{20}{70}$; $\frac{20}{15}$ with + 1.50 D. s. Hyperphoria 0°; sursumduction, R. 0°; L. 0°; esophoria 2°; abduction 3°; adduction 18°. October 3d. — *Tenotomy of right internus*, leaving exophoria $\frac{1}{2}°$ and abduction 10°. October 4th. — Orthophoria; abduction 6°; adduction 10°. October 11th. — The patient thinks his head has felt better since the second day after the operation. There has been less of the dizzy feeling. It makes him dizzy now to look to one side. He still has the pain in the back of his head. Esophoria 1°; abduction 5°; adduction 20°. Glass for the distance + 0.25 D. c. ax. 90° ⌒ prism $\frac{1}{2}°$, base out, both eyes, were ordered, and for the near, + 0.25 D. c. ax. 90° ⌒ + 0.50 D. s. October 14th. — The glasses for distant vision misplace objects and have made him very uncomfortable. Abduction 3°; adduction 22°; esophoria 3°; *tenotomy of left internus*, leaving esophoria $\frac{1}{2}°$, with abduction 6°. October 15th. — Abduction 5°; esophoria $\frac{1}{2}°$. His head symptoms have been better since the last cutting. October 19th. — Orthophoria; abduction 5°. October 28th. — Esophoria 1° to 2°; abduction 3°. Attempts to exercise the muscles with prisms produced nausea, pain in the occiput,

confusion, and drowsiness, which would last several hours. The prism exercise was omitted one day and he had a very comfortable day, though doing quite a deal of business down town. The following is from a letter dated January 3, 1888, and written by his wife: "Mr. B. has put off writing, hoping to report more favorably than his condition has as yet justified. His eyes have given him great discomfort, and are now more painful than they have ever been. To look at anything nearer than twenty inches, with or without his glasses, or the slightest pressure on his nose or scalp, causes an aching pain in the eye-balls that lasts for hours, sometimes for two days, accompanied by severe pain at the base of his brain and down to his shoulders, pulling the eye-balls towards the back of his head, a sensation as though a lot of hooks were in the eyes drawing them back. This makes him very nervous. His eyes are more painful when lying down, even on the softest pillow."

October 8, 1888.—For sometime after the operation there was much sensitiveness of eyes and deep in orbits, and Mr. B. felt as if the operation had done him harm. During the late spring this idea was dispelled; and in the months of July, August, and part of September, he was quite free from occipital pain and paraethesia. These have returned somewhat since at raising eyes in looking at a bright moving object last month; has been able to write for two or three hours, but not to read in last few months; general health much improved; movements in eye-balls in following my finger are painful in all directions. It would seem as if we had to deal in this case with weakness or paresis of all the ocular muscles, to be benefited more by general treatment than by any mechanical means. E. C. S.

October 9th.—Orthophoria; abduction 3°; adduction 21°.

Case XXX.—Mrs. J. A. M., age 27, came to me on April 28, 1888, presenting the following letter from Dr. Seguin: "This note is presented by Mrs. M., who has been under the care of an eminent gynaecologist and under mine for three years. Her ovarian trouble is cured, and there is no great uterine displacement. Neurasthenia, with a great variety of symptoms, is the complaint for which I am treating her, mostly by tonics and food. Asthenopia has been prominent from the first. I have long urged that her eyes be examined. The case is peculiarly one of those in which a doubt may exist as to which is primary, the asthenopia or neurasthenia"

Mrs. M. says that for three or more years she has been seeing double; that when her mind is concentrated on the object looked at it remains single, but as soon as she ceases to concentrate, it becomes double. R. V.$=\frac{20}{30}$; E.; L. V.$=\frac{20}{40}$; E. Hy-

perphoria 0°; esophoria 10° to 14°; orthophoria in accommodation; adduction 0°; adduction 20°. A red glass over one eye brings out diplopia. Ophthal.: Physiological excavation, venous pulsation; no lesion.

April 30th.—Under homatropine: R. V.=$\frac{20}{20}$; $\frac{20}{20}$ with + 0.50 D. c. ax. 45°; L. V.=$\frac{20}{40}$; $\frac{20}{20}$ with + 0 50 D. c. ax. 135°. Esophoria 12°; abduction 3°; adduction 30°; sursumduction, R. 1°; L. 1°.

May 1st.—Esophoria 12°; abduction 1°; adduction 31°; *tenotomy of right internus*, leaving esophoria 4° and abduction 5°. May 2d.—Patient had excruciating pain in the eye operated upon, which lasted from 1 P. M. to 5 P. M. Esophoria 4°; abduction 4°; adduction 27°. May 3d.—Esophoria 5°; abduction 5°; adduction 34°. May 4th.—Abduction 5°; adduction 36°; esophoria 6°. May 7th.—*Tenotomy of left internus*, leaving esophoria 1° to 2°, with abduction 13°. May 8th.—Abduction 9°. May 9th.—Patient says she has gotten rid of a certain "bound-up feeling in the back of her head," which she used to have for days and for weeks in succession. Her headache has not been so bad since the operation. Esophoria 3°; abduction 6°; adduction 35°. May 15th.—Esophoria 2° to 9°; abduction 6°; adduction 30°. The patient says she has no trouble with her menstruation since the operation.

Case XXXI.—Mrs. D. L., age 40, consulted me January 6, 1887. She has for years been a great sufferer from periodic headaches, from which she has experienced only partial and temporary relief by medication and change of climate. Her physical condition is bad. She is anæmic and thin. Her physician, Dr. E. J. Bermingham, thinks her headaches may be due to eye strain. The pain commences in the back of the left eye and goes down the back of her neck, more especially after reading or sewing. Ophthalmologically, no lesion; R. V.=$\frac{20}{20}$; E. L. V.=$\frac{20}{20}$; E. Orthophoria; abduction 7°; adduction 9°; accommodation $\frac{1}{8}$°; slight conjunctivitis. January 12th.—Under atropine: R. V.=$\frac{20}{40}$; $\frac{20}{20}$ with + $\frac{1}{36}$ s.; L. V.=$\frac{20}{70}$; $\frac{20}{20}$ with + $\frac{1}{36}$ s. ⌒ + $\frac{1}{60}$ c. ax. 180°. Glasses + $\frac{1}{36}$ were ordered to be worn all the time. January 26th.—The attacks of pain are not so severe and do not last so long. Put upon reading tasks by Dyer's method. Exophoria 4°; abduction 7°; adduction 14°; no hyperphoria.

March 1st.—Abduction 8°; adduction 14°; is reading half an hour twice a day; exophoria 4°; *tenotomy of external rectus of left eye*, followed by excessive bleeding into subconjunctival connective tissue.

April 13th. — Has had two of those terrible attacks since the operation. She reads an hour twice a day. Abduction 14°; adduction 8°.

May 11th. — Exophoria 2°; none in accommodation; no hyperphoria; abduction 9°; adduction 8°; no sursumduction; has had a great deal of pain since here. May 23d. — Exophoria 6°; in accommodation 9°; abduction 9°; adduction 8°.

August 17th. — Exophoria 5°. Headaches continue.

September 2d. — *Tenotomy of external rectus of right eye.* The operation was followed by so much hemorrhage as to necessitate the application of a pressure bandage for three days. September 23d. — There still remains much extravasated blood. The headaches are somewhat relieved, but far from being cured. Exophoria 1°. I now sent her to Dr. Seguin, who attributed much of her neurotic condition to the habitual use of opiates and other narcotics, and who interdicted their use, but without avail, as she thought she could not endure her pain without them.

October 13th. — Exophoria 5°. October 24th. — Dr. Seguin writes: "You remember Mrs. L. whom you sent to me recently. After a very few questions I discovered one reason (probably the chief reason) why your work on her eyes has been thrown away. For three years she has taken morphia for each attack, and at intervals frequently for insomnia, chloral, and bromides. Like some other cases I have seen treated in this way, she has observed an increasing degree of pain. These remedies weaken the nervous system greatly, and I believe from a series of observations, exert a peculiarly weakening effect upon the interni. No treatment will do her good until she dispenses with these drugs."

November 16th. — Headaches are as bad as ever, but different and more general. Exophoria 1° to 2°; in accommodation 4°; abduction 9°; adduction 7°. Mrs. L. soon after went to California. In a letter, dated February 23, 1888, she says that the attacks of neuralgia continued for some time, but that she recently had a longer interval of relief than at any time in two years; that she had done a good deal of reading, writing, and sewing, as well as other work, and that she attributed the relief more to the operations upon her eyes than to the change of climate.

Case XXXII. — Mrs. S. B. C., age 36, came to me on May 12, 1888, with the following letter from Dr. Seguin: "Will you kindly examine Mrs. C.'s eyes? She has rather an odd form of migraine, and describes other symptoms produced by attempts

to write and sew." R. V. = $\frac{20}{30}$; $\frac{20}{18}$ with + 0.75 D.; L. V. = $\frac{20}{30}$; $\frac{20}{18}$ with + 0.50 D. No hyperphoria; exophoria 2°; in accommodation 0°; abduction 14°; adduction 30°; sursumduction, R. 1°; L. 1°. Ophthalmologically, no lesion. May 15th. — Under atropine: R. V. = $\frac{20}{70}$; $\frac{20}{20}$ w. + 1.50 D.; L. V. = $\frac{20}{70}$; $\frac{20}{20}$ w. + 1.25 D. Abduction 18°, with correction of H., 12°; adduction 18°, the same with correction; orthophoria. May 17th. — Exophoria 17°; abduction 20°; adduction 25°; no hyperphoria. May 22d. — Exophoria 2°; abduction 18°; *tenotomy of left externus*, leaving exophoria 2°, with abduction 12°. May 24th. — Exophoria 3°; abduction 16°; adduction 14°. May 26th. — Orthophoria; abduction 14°; adduction 20°. May 29th — Exophoria 2° to 4°; abduction 18°; *tenotomy of right internus*, leaving orthophoria, with abduction 3°. I put in a stitch to prevent over-correction. May 31st. — Exophoria less than 1°; abduction 8°.

June 2d. — Esophoria 3°; in accommodation 1°; abduction 9°; adduction 20°; R. Hm. 1 D.; L. Hm. 0.75. With the above glasses, esophoria 6°. June 6th. — Esophoria 2° to 3°; abduction 10°; adduction 30°. June 22d. — Esophoria 1°; in accommodation 2°; abduction 10°; adduction 34°; no hyperphoria. The patient has been wearing glasses, correcting her manifest hypermetrophia. She says her headaches seem to be very much the same as before the operations; if anything more frequent, and in severity about the same. A letter received from Mrs. C., dated September 2d, says: "Since the first of August, when I left New York, I have been much better. Before that time my headaches were as persistent and severe as usual, but the change of air seems to have done me good. I can use my eyes for an hour or more for reading, etc., without fatigue, excepting after an attack of headache. In that case I can only read a few lines of printed letters without their becoming blurred and unsteady. This lasts from one to ten days, according to the amount of pain in the head.

Case XXXIII. — C. W. G., age 21, was referred to me by Dr. Seguin on October 8, 1886. He had been wearing convex cylindrics for nearly a year. While studying technology in Boston he broke down in March with pain in the back of his head and neck, which became constant. He had not noticed that it was made worse by the use of his eyes. He has slight frontal and temporal pain on use of his eyes. He is troubled with dizziness. R. V. = $\frac{20}{40}$; $\frac{20}{18}$ with + $\frac{1}{48}$ c. ax. 180°; L. V. = $\frac{20}{20}$; $\frac{20}{18}$ with + $\frac{1}{80}$ c. ax. 90°. Esophoria 4°; in accommodation 4 to 8°; no hyperphoria°; abduction 2°; adduction 17°. Ophthal.: Physiological excavation of hyperæmic optic discs.

October 11th. — Under atropine: R. V. = $\frac{20}{30}$; $\frac{20}{20}$ with + $\frac{1}{48}$ c. ax. 180°; L. V. = $\frac{20}{20}$; $\frac{20}{15}$ with + $\frac{1}{60}$ c. ax. 180°. Esophoria 13°. October 18th. — *Tenotomy of right internus.* October 20th. — Esophoria 5°. October2 3d. — Esophoria 2°. The patient says he has less pain in the back of his head, and feels better generally.

November 9th. — Esophoria 3°; ordered glasses: Rt. + $\frac{1}{60}$ c. ax. 180° ⌒ prism 1½°, base out; Lft. + $\frac{1}{60}$ c. ax. 180° ⌒ prism 1½°, base out. November 26th. — Abduction 4°; adduction 17°. November 29th. — Patient much relieved in back of head.

Case XXXIV. — Sarah G., age 25, came to the clinic at the Manhattan Eye and Ear Hospital on April 20, 1887. She complained of dimness of vision and blurring of sight when reading or sewing, but disclaimed headache or pain in or about the eyes. R. V. = $\frac{20}{20}$; Hm. $\frac{1}{72}$; L. V. = $\frac{20}{20}$; Hm. $\frac{1}{72}$. No hyperphoria; exophoria 11°; in accommodation 0°; abduction 10°; adduction 16°. Ophthalmoscopically, no lesion. April 27th. — Exophoria 10°; in accommodation 12°; *tenotomy of left externus,* leaving homonymous diplopia 14°. April 29th. — Esophoria 4°. May 2d. — Esophoria 3°. May 4th. — Exophoria 4°; abduction 8°; adduction 16°. May 6th. — Exophoria 3°; in accommodation 0°; abduction 8°; adduction 16°. May 9th. — Exophoria 4°. May 13th. — Exophoria 4°; abduction 8°; adduction 18°.

October 10th. — Exophoria 8°; in accommodation 16°; abduction 18°; adduction 9°; *tenotomy of right externus,* leaving esophoria 8°. October 12th. — Homonymous diplopia 18° to 20°. The right externus was now advanced to nearly its former place of insertion. October 13th. — Esophoria 2°. October 14th. — Orthophoria. October 17th. — Esophoria 5° to 6°. The patient has glasses correcting her manifest hypermetropia. She says she has more headache than before the operations upon her eyes. October 28th. — Exophoria 1°; in accommodation 3°; abduction 10°; adduction 20.°

November 23d. — Orthophoria; abduction 8°; adduction 27°; sursumduction, R. 3°; L. 3°.

January 13, 1888. — Esophoria 5°; in accommodation 0°; abduction 4°; adduction 23°.

May 9th. — Esophoria 4°; in accommodation 0°; abduction 3°; adduction 18°; no hyperphoria. The patient complains of diplopia when looking to the right or left. She has noticed this since the last tenotomy. She has no pain in the eyes or head, but her eyes tire after reading or sewing.

August 1st. — The patient says her double vision on looking to the right or left troubles her a great deal, both on the street

and in the house. She has pain in the eyes, some days all day, and some days none at all. Esophoria 4°; abduction 1°; adduction 20°. Advancement of an externus was advised.

Case XXXV. — Mr. J. O., age 30, was referred to me by Dr. Seguin on October 17, 1887, with the following note: "Mr. J. O., who presents this note, has been under my care, off and on, for two or three years for malarious symptoms, anæmia, constipation, etc., but also for headaches, which no medical treatment improves. Scores of experiments go to show, clinically, that the headaches are from his eyes, and I would therefore ask your help for the problem." R. V. = $\frac{20}{40}$; $\frac{20}{20}$ with + 0.50 D. c. ax. 90° ⌒ — 0.50 D. c. ax. 180°; L. V. = $\frac{20}{50}$; $\frac{30}{20}$ with + 0.50 D. c. ax. 90° ⌒ — 0.75 D. c. ax. 180°. No hyperphoria; esophoria 3°; in accommodation 3°; sursumduction, R. 1°; L. 1°; abduction 3°; adduction 20°. The ophthalmoscope shows numerous very small yellowish spots scattered about over a large area at the posterior pole of both eyes. October 20th. — Under homatropine: R. V. = $\frac{20}{70}$; $\frac{20}{18}$ with + 1 D. s. ⌒ + 1 D. c. ax. 90°; L. V. = $\frac{20}{70}$; $\frac{20}{18}$ with + 1 D. s. ⌒ + 1. 25 D. c. ax. 90°. Esophoria 6°; abduction 3°. October 25th. — Has been exercising his externi with prisms. He has found that mornings he could overcome 5°, while evenings he could overcome only 3°. Esophoria 2°.

November 14th. — He has had less headaches since here than for a long time before. Esophoria 1.°

December 14th. — Esophoria 2° to 3°; exophoria in accommodation 1°; abduction 3°; adduction 18°; sursumduction, R. 1°; L. 1°. December 15th. — Adduction 24°. December 16th. — Adduction 25°. December 1 th. — *Tenotomy of right internus*, getting orthophoria, with abduction 8°. December 20th. — Has + $\frac{1}{36}$ c. ax. 90° both, for constant use. December 31st. — Esophoria 1°; abduction 6°. December 25th. — Mr. O. wrote: "My eyes are getting along nicely, and for the last two days there were no signs of headache. If this pleasant state continues it will be all that I could possibly desire." December 30th. — Orthophoria; exophoria in accommodation 4°; abduction 6°; adduction 20°. I have recently heard that Mr. O. does not think he was made better or worse by the tenotomy.

Case XXXVI. — Miss A. G. P., age 29, came on December 29, 1886, with the following note from Dr. Seguin: "Miss P. suffers from neurasthenia with a strong predominence of asthenopia. Her general condition has so much improved that she can go to your office and stand testing pretty well. I have found no very evident optical defect, and suspect the interni of being

at fault." Miss P. states that she has suffered from nervous prostration since July last. At times her eyes feel tired, and then rested again without use. At other times they feel tired after reading, and there is a general feeling of lassitude. She had a similar attack three years ago. R. V. $= \frac{20}{20} +$; E. L. V. $= \frac{20}{20} +$; E. Orthophoria; abduction 10°; adduction 12°. Ophthalmoscopically, no lesion. December 31st. — Under atropine: V. $= \frac{20}{20}$; E. both. Orthophoria; abduction 8°; adduction 14°.

January 10, 1887. — Orthophoria; esophoria in accommodation 5°; abduction 10°; adduction 16°. January 12th. — A. $= \frac{1}{5}$ each; read five minutes, but eyes got very tired before the five minutes were up. Abduction 10°; adduction 15°; *tenotomy of left externus*, Drs. Seguin and Way present. January 22d. — Orthophoria; abduction 7°; adduction 20°. January 29th. — Orthophoria; abduction 10°; adduction 20°; ordered glasses $+ \frac{1}{72}$ for both eyes, and to read five minutes twice a day and increase the task two minutes daily.

February 3d. — Read ten minutes this morning; eyes got a little tired. Orthophoria; abduction 8°; adduction 17°.

March 25th. — Has continued reading half an hour twice daily and is much improved Abduction 7°; adduction 16°; orthophoria.

April 25th. — Miss P. writes: "Since my return home, four weeks ago, I have improved greatly. My eyes are much stronger than when I last saw you. I now read forty-five minutes, both morning and afternoon. I find I read forty-five minutes now easier than I read thirty minutes four weeks ago."

October, 1888. — A relapse followed in the summer, and later the patient was placed somewhere for a rest cure; result unknown. I had satisfied myself that much of this patient's invalidism was connected with unfavorable moral home conditions (discontent, irritation, etc.). E. C. S.

Case XXXVII. — DeWitt D., age 29, clerk, married, consulted us in June 10, 1887, for asthenopia. He complained of his head. Sometimes he cannot see what he is writing; the letters run together. R. V. $= \frac{20}{30}$; $\frac{20}{20}$ with $- \frac{1}{72}$; L. V. $= \frac{20}{30}$; $\frac{20}{20}$ with $- \frac{1}{72}$. June 13th. — Under atropine: R. V. $= \frac{20}{50}$; $\frac{20}{15}$ with $+ \frac{1}{24}$; L. V. $= \frac{20}{70}$; $\frac{20}{15}$ with $+ \frac{1}{30}$ s. $\frown + \frac{1}{60}$ c. ax. 60°. June 22d. — Ordered glasses $+ \frac{1}{30}$ s., both eyes, for all the time.

January 16, 1888. — Patient wore the glasses all the time for five or six weeks. He then left them off for the distance, because his eyes were more comfortable without them. He could

not see well in the distance with them, and they made his eyeballs feel sore. He used them for near work up to within four weeks, and then found he could see better and more comfortably without them. But now he has got so that he cannot get along with or without them. His eyes begin to pain as soon as he begins to use them, and after a few minutes he has to close them and keep them closed. He has headache three or four days out of a week over the eyes and back of the ears. R. V. $=\frac{20}{20}$; $\frac{20}{15}$ with + 0.25 D. cyl. ax. 40°; L. V. $=\frac{20}{15}$; $\frac{20}{15}$ with + 0.25 D. cyl. axis 60°. Esophoria 3°; in accommodation 1°; hyperphoria, R. $\frac{1}{2}$°; abduction 5°; adduction 18°; sursumduction, R. 2°; L. 1°. Ordered glasses + 0.50 D., both, and to exercise ocular muscles with prisms. January 20th. — Abduction 5°; adduction 18°. January 31st. — Esophoria 9°; in accommodation 3°; abduction 4°; adduction 18°.

February 8th. — Esophoria 6°, abduction 3°. February 17th. — Esophoria 7°; in accommodation 2°; abduction 3°; adduction 25°; *tenotomy of right internus*, leaving orthophoria, with abduction 8°. February 18th. — Esophoria 7°; abduction 4°; adduction 18°. February 20th. — Esophoria 4°; exophoria in accommodation 1°; abduction 4°; adduction 15°.

May 14th. — Esophoria 3°; abduction 5°; adduction 16°; ordered glasses: Rt. + 0.25 D. ⌒ + 0.25 D. cyl. ax. 180°; Lft. + 0.25 D. cyl. ax. 60° ⌒, prisms 3°, base out. May 22d. — Patient has furuncle of brow.

April 17, 1888. — Mr. D. says he is entirely rid of his headaches, but lately he has been using his eyes without the glasses and print begins to blur, and he begins again to have pain over his eyes. Esophoria 3°; no hyperphoria; abduction 5°; adduction 18°. R. V. $=\frac{20}{15}$; Hm. 0.50 D.; L. V. $=\frac{20}{15}$; Hm. 0.25 D. Ordered the glasses last above for all the time.

Case XXXVIII. — Dr. W. M. L., age 33, was fitted with glasses by me many years ago, for compound myopic astigmatism. On September 5, 1888, he stated that his eyes had been examined at the Manhattan Eye and Ear Hospital several months since, and that he had been found to have hyperphoria R. 10°, and exophoria 18°. Examination on this date shows hyperphoria R. 18° and exophoria 18°. The second image is brought out by placing a red glass over either eye. Left eye swings out and down, and the dragging sensation is a source of considerable annoyance to the doctor. The eye also gets very tired on reading a short time. *Tenotomy of left externus*, leaving exophoria 7°. September 6th. — Exophoria 7°; hyperphoria, R. 13°. With hyperphoria corrected the exophoria is 6°. September 7th. — Hyperphoria 12°; exophoria 7° to 9°. With

hyperphoria corrected there is exophoria 4°. September 8th. — With the hyperphoria corrected the exophoria is 6°. September 28th. — Hyperphoria, R. 14°; exophoria 14°; *tenotomy of left inferior rectus*, leaving hyperphoria, R. 3°, with exophoria 14°. The bleeding began as soon as the center of the tendon was snipped with the scissors and greatly embarrassed the rest of the operation. At the completion of the tenotomy the lower portion of the ocular conjunctivæ bulged as from a high degree of chemosis. September 29th. — Hyperphoria, L. ½°. The patient complains of constant and extremely annoying diplopia. September 30th. — Hyperphoria, L. 8°; exophoria 20°. With exophoria corrected, hyperphoria, L. 4°.

October 1st. — Hyperphoria, L. 6°; exophoria 18°. With exophoria corrected, hyperphoria, L. 3° to 4°. October 2d. — Hyperphoria, L. 6°; exophoria 20°. The diplopia continues to be very troublesome, making the patient dizzy if he attempts to move about with both eyes open. After consultation with Dr. George T. Stevens, I advanced the *left inferior rectus* with a single stitch, leaving hyperphoria, R. 10°. The bleeding during this operation was even greater than it had been at the tenotomy. October 3d. — Hyperphoria, R. 3°; great distension of lower half of ocular conjunctiva by sub-conjunctivæ hemorrhage. October 4th. — With his refraction corrected and red glass over left eye, images fused by prism 8°, base in, over right. With red glasses over right eye, images fused by prisms 15°, base in, and 4°, base up, over left. October 5th. — Swelling and redness much less. The patient has not suffered from diplopia, nor has he had any pain since the advancement. October 6th. — Removed the stitch; no diplopia. Sub-conjunctival hemorrhage is being rapidly absorbed. October 8th. — Swelling gone and eye clearing up. At 20′ lights are fused by prism 19°, base in, and 2°, base up, over left eye, with red glass over right. No diplopia without red glass over one eye, or unless brought out by prisms.

Case XXXIX. — Miss Augusta W., age 34, teacher, consulted me May 2, 1888. She complained of seeing objects double at times. She was not the subject of headache, but she had been long afflicted with dyspepsia and nervous exhaustion, which, she said, Dr. E. G. Loring had told her was due to the constant effort she made to keep her eyes looking in the same direction. Reading gives her a sensation of exhaustion in the stomach. Dr. Loring did a *tenotomy of the right internus* in November, 1887, and told her she must have the left cut later. R. V. $= \frac{8}{200}$; $\frac{20}{15}$ with — 5 D.; L. V. $= \frac{20}{30}$; $\frac{20}{15}$ with — 1 D. c. ax. 45°. She is wearing the above correction over the left eye,

with a plane glass over the right. Hyperphoria, L. 1°; esophoria 2°; in accommodation, 6°; sursumduction, R. 0°; L. 0°; abduction 0°; adduction 2°. Ophthalmoscopically, no lesion, except staphyloma posticum. Professor W. Oliver Moore, M.D., kindly sent me, from Dr. Loring's records, the following note: "Miss A. L. W., October 29, 1887, R. — $\frac{1}{6}$ V. = 1. L. — $\frac{1}{24}$ cyl. 35° V. = 1. Insuf. Exter. 10° between two eyes. Candle comes together in 3′; 20′ insuf. 10°; abduction 17°; 1′ insuf. 6°; adduction 10°; cut left internus 1st November.

December 23d. — Rt. plane; Lf. — $\frac{1}{36}$ c. ax. 35°. Ord.

April 23, 1888. — Insuf. still 10°. Images come together in three feet."

May 8th. — Esophoria 3°, with or without her glasses. With red glass over either eye there is homonymous diplopia. Red and yellow light brought together by prisms 5°, base out, and 1°, base down, over left eye. *Tenotomy of left internus*, leaving exophoria 3° and hyperphoria less than $\frac{1}{2}$°.

August 30th. — Miss W. writes: "I can say that my sight has been much benefited by the operation. The double vision does not trouble me, and my general health is improved. I still feel, however, the exhaustion after reading, of which I complained in the spring. I can use my eyes for sewing or painting without having any unpleasant feelings."

October 9th. — Hyperphoria, L. 1°; esophoria $\frac{1}{2}$°. The symptoms of indigestion have disappeared. After using her brain she still has a feeling of exhaustion in her chest. She can use her eyes a long time without trouble.

Case XL. — Miss Lulu T., age 18, consulted me June 6, 1888. Right eye always very near-sighted. Pain in both eyes; more in right. In February, 1887, had so much pain that she was compelled to give up studying. Her general health has been good. She has had headaches "quite a good deal," and think it due to her eyes. She is wearing over the right eye a plane glass, and over the left + 1.50 D. c. ax. 90° ⌒ — 1.50 D. c. ax. 180°. R. V. = $\frac{4}{200}$; $\frac{20}{40}$ with — 7 D. ⌒ — 1.25 D. c. ax. 135°; L. V. = $\frac{20}{70}$; $\frac{20}{15}$ with + 1.50 D. c. ax. 90° ⌒ — 1.50 D. c. ax. 180°. No hyperphoria; exophoria 16° to 20°; abduction 18°. With red glass over one eye, prism 16°, base in, fuses images. She has had occasional diplopia for over a year. Ophthal.: Rt., staphyloma posticum with choroidæ changes. Myopic 10 D. Lft., no lesion; *tenotomy of right externus*, leaving exophoria 12°. The patient fainted during the operation, though she declared that she was not hurt. June 7th. — Crossed diplopia 16°; *tenotomy of left externus*, leaving homonymous diplopia 12°. June 8th. — Homonymous diplopia 10°.

June 9th. — Homonymous diplopia 15°. Motion outward of left eye restricted. I now *advanced the left externus* by a single stitch, and got homonymous diplopia 3°. June 10th. — Homonymous diplopia 2°. June 12th. — Homonymous diplopia 6°, with or without red glass over one eye. At one foot crossed diplopia of 7°. June 13th. — Homonymous images at 20′ fused by prism 4°, and crossed images at 1′ fused by prism 4°. June 15th. — Homonymous images 3°. Has had no headache for three or four days. June 16th. — Homonymous diplopia 1°, with red glass over one eye.

August 3d. — In a letter dated August 1st, Miss T. says: "The swelling on my left eye did not disappear entirely until one week ago. The eye is still a little red, but it does not trouble me any, and I have had but little headache since I left the city. I still see things double, and this is decidedly annoying, for the right one seems to turn out. I have had to give up all fine work, and can read only very little at a time, as my eyes ache so badly if I use them."

DISCUSSION.

DR. RICHARD H. DERBY, . — After listening to the paper just read and the history of the cases therein detailed, the impression is conveyed that in insufficiency of the ocular muscles we have tests sufficiently delicate to measure an insufficiency as slight as a fraction of a degree, and that, moreover, in the operation for the relief of the insufficiency we can so graduate our tenotomy that the operation shall produce an effect not greater than one-half a degree. To this view I would most certainly protest. There can be no doubt that in cases of insufficiency of the ocular muscles, both of those that move the eyes in the vertical as well as the horizontal plane, we have, both in the use of prisms and in a tenotomy, a most valuable method of treatment for the relief of muscular asthenopia and the establishment of comfortable binocular vision. In the case of insufficiency of the inferior rectus, I have on various occasions made a partial tenotomy of the superior. In such cases, where the difference in height of the two eyes has been measured by two or three degrees at the first examination, I have, before operating, directed the patient to wear in turn successively stronger prisms before the one eye, until a prism of six, eight, and even ten degrees, with its base down, could be worn and binocular sight be still maintained. Then, and not till then, have I operated, dividing the muscle close to its scleral insertion, and leaving a few fibers either outwards or inwards,

according as there was a possible dynamical divergence or convergence. If these observations have then been correct it would seem that the correction produced by a partial division of an ocular muscle may be represented by a prism of as much as six to eight degrees. I am well aware, Mr. President, that we do not by any means secure such a result from every even complete division of a muscle. I would especially urge the importance of repeated examinations of our patient suffering from muscular asthenopia, and especially insist upon the use of prismatic glasses and carefully noting their possible usefulness before proceeding to surgical interference. I can but feel that overzeal in the practice of the operation for the relief of dynamical strabismus may cause a most useful surgical procedure to fall into disrepute.

DR. THEOBALD: — I was struck with the fact that among the cases reported by Dr. Webster there were so many in which in addition to the tenotomy astigmatic glasses were prescribed. This leaves the matter open to question whether the correction of the astigmatism was not the more important factor in relieving the troublesome head and eye symptoms. I also noticed that in a considerable number of the cases in which mention was made of the direction of the astigmatism, the + (plus) cylinders were placed with the axis horizontal and the — (minus) cylinders with the axis vertical, or approaching vertical. It would be anticipating what I have to say in my own paper, but it has a bearing upon this point: that when the meridian of lowest refraction approaches the vertical we may expect very much more trouble from accommodative strain than when it approaches the horizontal. In these cases, too, I have frequently found what seemed to be insufficiency of the external recti muscles; but this apparent insufficiency has disappeared when the excessive accommodative strain was relieved by correcting glasses.

I was surprised to learn that in the slight degrees of hetorophoria described the complete division of the tendon had so slight an effect. I should feel that I were pretty certain in such cases to throw the balance of power very much more the other way by cutting through the whole tendon.

DR. E. C. SEGUIN: — I am afraid what I shall say will not be of much interest. I will direct my remarks to the medical aspects of some of the cases Dr. Webster has spoken of; and it will bring up the question as to the present position of the question — whether we can expect much benefit in nervous cases from these operations, — cases of headache, etc.

I will speak more particularly of three cases as I recognize them in the description of Dr. Webster.

1. The case of Jack. That little fellow has been practically cured of all the choreic manifestations; but as he grew in strength and lost his chorea it became evident that there was a certain degree of ataxic incoördination present in his arms and legs — a condition which together with the atrophy of the optic nerves makes me fear that the child is the subject of organic cerebral disease. The rapidity of his improvement after the tenotomy was striking. He had had arsenical treatment before the operation; and subsequent to this the arsenical courses were repeated and the doses carried to quite an extent. So that the two factors combined to bring about what I may call a cure of the choreic manifestations. As I look back upon the case there was a combination of chorea and ataxic disorder.

2. The case of the engineer with spinal irritation and neuralgic attacks in the spine was not simple. The attacks of neuralgia lasting for several hours, for a week or ten days, disabled the man practically. That was a very mysterious case, and remains so to my mind to-day. The gentleman has remained well, at least so far as I know was well last Spring. He had a relapse, brought about by rapid traveling to and fro between Boston and Chicago. In this case I must confess I have had very grave doubts as to the reality of the patient's complaint. It is a thing I never told his brother or the patient himself. The attacks of neuralgia, the quasi-convulsions and contortions were excessive, and altogether beyond the limitations of neuralgic suffering; and the effects of various treatments which had been tried excluded the diagnosis of simple spinal irritation. He had been made worse by counter-irritation and all sorts of tonic treatment; and the relief from tenotomy struck me to be too rapid. Dr. Webster will recollect that the man said on the evening of the operation that he had "felt something give way in the spinal column and felt better than for three years." That man, it seems to me, was subject largely to delusional nervous suffering; and the question will arise whether the operation did not do good partly by "suggestion" as well as it may have helped in the physical way.

3. Another case, which I recognize in Dr. Webster's account, was one in which all the muscles of the eye-ball were remarkably feeble, and in which dizziness, attacks of a fainting nature, and confusion of mind were the chief nervous symptoms. In this case all efforts at correction proved unavailing. That was one of the cases which brings up the question strongly in the mind of the neurologist, whether the condition

of the eye muscles might not be the result of neurosis and the condition of the patient. This patient was anæmic and had a feeble heart. It is possible that some of the cases so unsuccessfully treated by tenotomy may be cases in which the general condition is more to blame than the asthenia of one or more of the ocular muscles.

As to the influence of tenotomies upon chorea and epilepsy, I will beg to be excused from expressing conclusions or opinions I may entertain, from the fact that I am on the committee of the Neurological Society, which is at present coöperating with Dr. Stevens in a study of this question. It would be out of place to express myself in this connection.

From my standpoint, as is evident in some of my notes, I have not been over sanguine as to the possible results to be obtained in many nervous cases from tenotomies. I thought it was a very desirable thing to try in the cases I sent to Dr. Webster; and I shall still further prosecute that line of inquiry. I have had even more brilliant results from adaptation of glasses to some of my patients. And my position must be neutral as between the extravagant claim that neuroses are curable by tenotomies and spectacles, and the position which assumes that these means are useless.

In conclusion I would suggest that in cases where all the ocular muscles are feeble, as in the third case of which I have spoken, tenotomy is not a hopeful procedure.

DR. HENRY D. NOYES: I am gathering material which I shall lay before the Society in detail at a future time; and I don't propose to bring any until it has been sifted by long experience, because I have watched cases for a sufficient period to know that six months is too short a time, and it is sometimes necessary to watch them two or three years before you know the ultimate result of surgical interference.

There are some points with reference to modes of examination which may be mentioned.

1. When endeavoring to determine whether there is deviation of one eye or the other above or below the horizontal line I think the spirit-level is entirely supererogatory. And the reason is this: A very large proportion of persons, if one takes the trouble to examine, in whom any recognizable deviation in the vertical sense exists, it will be found that this is brought about simply by the anatomical malformation of the bones of the face and head. I have discovered that point upon examination in a number of instances. We all know how unsymmetrical is the form of the cranium in the majority of instances,

how right or left side will bulge more or less. The orbits are not infrequently upon a plane that is not horizontal; and you may find that these persons carry the head sidewise. They do this in order to compensate for the irregularity that the insertions and origins of the muscles have in the movements of the globe, especially in the antero-posterior axis. I have determined this fact over and over again. Their habit is a compensation for anatomical malformation; and that, to my mind, renders absolutely useless resorting to the spirit-level, because the person corrects his deviation by simple inclination of the head.

2. Then I have never paid any attention to these slight deviations in the vertical sense which amounts to one or two degrees. I have had occasion to treat individuals with deviation in the vertical sense of 3° or 4° or more, and have operated upon superior and inferior recti many years ago. I have given such persons prisms with the bases vertical to correct the error, and have found that very few of them were benefited, but became satisfied that they were relieved better by prisms with the bases outward. These have usually been cases of paresis of the superior oblique muscles. And my objection to the nomenclature recently introduced by Dr. Stevens is that it tends to spoil accuracy of diagnosis. I don't want to operate blindly, but want to know whether it is superior oblique or inferior rectus which is at fault; and I think it tends very much to clear our minds as to what we have to do. I think it desirable that we should have clearly pictured to ourselves what is the muscle at fault when about to perform an operation.

3. The term "esophoria" has not, to my mind, been clearly defined. I mean this: the most valuable testings should be made at 20 feet, as Graefe long ago declared; at the same time they must be supplemented by examination at ⅓ metre — 13 inches — because the two are not by any means always in correspondence. When you test for distance by the prism vertically before one eye, and the two images are not vertical to each other, according to Graefe's nomenclature, the prism required to bring the two images into the vertical line measures the insufficiency of the muscles. When you put a prism with the base vertical before one eye and you add a prism which shall bring the two images into the vertical line, it will follow that the patient will accept the additional prism without change of place in regard to perpendicularity. I put before one eye a prism of 5° and measure the amount required for insufficiency of the externi of additional prism to bring the two images into the vertical line. Suppose, with images one higher than the other at 20 feet, I require 3° to bring the images into verti-

cality. To that 3° I may also find that I can put before the patient an additional prism of 3° or 5° without changing their vertical relation. There are two separate factors: *a*, spontaneous deviation; *b*, deviation which comes on unconsciously in the patient as you go on and attempt to make out the total amount of deviation. You may call one "manifest" and the other latent, as Loring has done many years ago. These two things have to be considered. I have performed tenotomy and found remaining a latent deviation; and the patients sometimes have not been relieved because there remained that latent deviation.

My objection to the use of these terms "esophoria" and "orthophoria" is that they lump things together. When there occurs an error I prefer to say that in the vertical line there is so much "manifest deviation", and likewise of "latent deviation" as found by introduction of prism which the patient will accept without any conscious effort, and which you know is a fact of permanence, because repeated from day to day. The analogy with the facts of hypermetropia is self-evident.

4. It has happened in my experience, both recent and in years long past, that division of the tendon exclusively may not be attended with any displacement in the optic axis; and the reason lies in the fact that an essential mechanical factor is the ocular fascia or capsule of Tenon. All of the good dissections and recent careful studies show clearly that the action of the muscles upon the eye is very materially influenced by the anatomical structure of this tissue; so that it is very important that we keep close to the eye-ball in tenotomy, and important likewise that we don't disturb the lateral connections when small effects are desired.

5. As to the method of operating, I have always used a hook, and within the last three years very small hooks, and employ a stitch to get the result I wanted. My tenotomies for muscular insufficiency have been done with pointed and curved scissors, with very small hooks, and I have cut simply through tendon and conjunctiva simultaneously, and, introducing hooks above and below, cut off the margin of muscle; on finding what effect is obtained I put in a stitch and regulate before the patient goes away the precise muscular equilibrium. The conjunctival wound is made extremely small.

6. Another thing in respect to tenotomies. One patient is in my mind. She had astigmatism years ago, and she came to me with symptoms of a muscular type, for which I did tenotomy on one internal rectus; this gave relief for some time and then the original symptoms relapsed and I did tenotomy

of the other side, and then got another period of relief, and now she has fallen back to the same condition of discomfort as before. What have I got? I have got the most perfect normal conditions of equilibrium on the median line; nevertheless, she is uncomfortable. The moment you turn her eyes from the median line about 45° you find crossed diplopia. The interni work to disadvantage in the associated lateral movements of the globe. I have more than one case of this sort; I have seen this in several cases, and herein is one reason for my saying that you must watch your patient more than six or twelve months before you can make up your mind as to the ultimate development of the case.

In a general way I have satisfied myself thoroughly by experience of four years that insufficiencies of the external recti muscles are by far the preponderating troubles to be dealt with. This is often associated with slight degrees of hypermetropia and astigmatism, and may occur with emmetropia. It is a notable fact that the correction of ametropia does not relieve the muscular symptoms, and I have had patients come who have been corrected for ametropia and have come with asthenopic symptoms, and I have seen it was a matter of muscles, and I have done tenotomies in some instances, and in some given prisms. I have come out of the difficulties of my cases with far greater satisfaction during three or four years with the ordering of prismatic glasses than I expected to; and I have performed comparatively few tenotomies.

I would say this: as a general rule I am not willing to operate in any case in which there is not a manifest surplus on the side of the muscle I propose to cut. It was my reason for asking him [Dr. Webster] what was the state of adduction and abduction. I would not perform a tenotomy unless there was a very distinct surplus of power in the muscle I propose to cut. Neither is that fact emphasized sufficiently in the reports of cases we have. We hear the patient had so and so in muscular conditions, and an operation is done. We don't always get a statement of exactly what the muscular condition may be at the time of the operation and a sufficient time afterwards. I operate when I am satisfied that there is still a considerable muscular power, but that it is wrongly placed, and I am at liberty to interfere with a strong muscle for the benefit of a weak one — I would not interfere when the muscles on both sides are weak. I have ventured to do it in one or two instances. The results were very bad. I have divided muscular cases, I see, into *a*, cases purely neurotic, and *b*, cases purely muscular. I have satisfied myself that a large proportion of

the cases are mainly due to nerve exhaustion and not to pure muscular error, and that the symptoms on the part of the muscles are developed in consequence of nerve exhaustion, and they are not suitable cases for tenotomy. These are some of the cases which pass from office to office and undergo a series of tenotomies, and with very peculiar results in some instances.

DR. OREN D. POMEROY: Since the use of cocaine in the division of a tendon of an ocular muscle, great exactness in the result may be reached. My rule is to cut until the proper effect is obtained.

It seems to me impossible ordinarily to determine whether a tendon is entirely divided, by simple inspection. I have apparently divided the whole of a tendon without obtaining a particle of result, even when prisms were used to measure the effect. I have called in a colleague who coincided with my opinion that all the tendon was apparently cut.

Subsequent dissections with the scissors in the direction of Tenon's capsule have enabled me to obtain abundant effect. I cut a little, then try with prisms, stopping when sufficient effect is produced. An over effect may be corrected by a suture.

I had an illustration of this point recently. The patient had an insufficiency of the superior rectus of the right eye. She complained that after using her eyes for a time the right eye would turn downward and she saw double. The insufficiency was 15° for distance. I divided the superior rectus tendon, as far as I could observe, completely, without diminishing the insufficiency a particle. I then made a few snips with the scissors at either end of the wound previously made, and at once gained 9°, that is leaving 7° uncorrected.

DR. JACKSON: I would confirm the observation, that complete division of the tendon alone does not always lessen the deviation, or tendency to deviation. This surprised me when I first noticed it. I had made a small conjunctival incision, cut through the tendon at the center of its insertion, without separating it from the conjunctiva; and then divided it subconjunctivally each way to the margin. Finding no limitation of movement, I divided freely all bands of tissue that could be raised on the hook, both laterally and beneath the tendon; but still there was no effect. Next day, however, the conjunctival wound gaped widely as it could, and beneath the conjunctiva the tissues were so retracted and thinned as to reveal a belt of white sclera four or five millimetres in width; while movement in the direction of the muscle was markedly limited. Perhaps few cases are quite like this; but I have repeatedly noticed

after division of what I thought the whole tendon, that the test with prisms showed no immediate effect. I believe that very often the graduation of effect rests more on the graduation of division and cicatrization in the surrounding tissues, than in the "slipping back" of the tendon itself.

I dislike the carrying over from hyperopia of the term "latent," and applying it in a supposed similar sense to deviations, or tendencies to deviations. In hyperopia we are dealing with the contraction or relaxation of a single muscle; in heterophoria we have to do with the balance of opposing muscles, which is really dependent on the relative proportion of nervous impulses directed toward those muscles. Here is an important difference; and the use in this connection of the term "latent," without divesting it of the idea of an exact and positive limit such as bounds latent H., will certainly lead to false conclusions. I think Dr. Seguin's suggestion that heterophoria may often be a symptom of a neurosis comes near the heart of its pathology. From what we know of the behavior of voluntary muscles in all other parts of the body, of their capacity to increase enormously in bulk and power under increased demands, and by a truly physiological hypertrophy to render themselves equal to any work habitually required of them, it seems improbable that the fault in heterophoria is really muscular. I believe that not only in tendency to deviation, but also in actual squint, the fault lies usually in the nerve centers or paths by which impulses come to the muscles; and that the crippling of a muscle by tenotomy is a clumsy device, that is far from attacking the primary pathological tendency. Still we may, in our ignorance of anything better to do, often give great relief by tenotomy. I have done it several times for heterophoria, and have not regretted resorting to it in any case. I have always had the patient under observation previously for several weeks, usually for several months; and have tried the effect of prisms and of other lines of treatment. As to the ultimate result of tenotomy, it cannot be determined within a few months. Generally there is, during cicatrization, a diminution of the primary effect; and I, also, aim at a slight overcorrection shortly after the operation.

DR. WEBSTER: I am gratified with the discussion that has been brought out; and I think it has been instructive whether the paper was or not. In regard to Dr. Derby's case, I think I should have treated it as he did. I think he did wisely in bringing these images together with prisms, and enabling the patient to attain binocular vision; and if the prisms did all that

was necessary I think he was right in dividing neither the inferior nor superior rectus.

In regard to his remark about the operation, whether we should go around the border of the muscle with the long strabismus hook and cut the externus, I don't think I agree with him. I would not dare to operate by that method, for 1° or 2° of insufficiency. I remember a case of insufficiency of the internus, where one eye wandered way out occasionally. Dr. Agnew operated, and cut the externus by that method, and got quite a convergence and troublesome diplopia. He did the operation very delicately, too. I would always operate for *insufficiency* by commencing at the center of the tendon and cutting both ways. I don't think that anything that any other gentleman said calls for comments on my part.

A DISK OF LENSES TO BE USED IN DETERMINING REFRACTION BY MEANS OF SKIASCOPY.

BY DR. SWAN W. BURNETT.

I assume that skiascopy has come to stay as one of the easiest and most accurate objective methods of determining the refraction of the eye. I believe, however, that one serious drawback to its general employment is the loss of time and the annoyance necessary in changing the lenses in the trial frame in the usual manner of employing the test. Doyne's disk of lenses, exhibited here at the International Congress, a year ago, by Mr. Cross, and some others that I have heard of but not seen, are designed to obviate this difficulty, and, I learn from those who have used them, do so very effectually. These apparatuses, however, are not to be had in this country, and would be, I infer, rather expensive. I have, therefore, designed for my own use this simple affair which I have now used for some months with perfect satisfaction, and which I feel justified in commending to those members who practice the shadow-test,

as a great time and labor-saving appliance. It consists, as you see, of a hard rubber disk 12 inches in diameter, containing 23 lenses, each 3 cm in diameter on its border. The numbers go from 0.25 D to 6 D plus and minus, with additional 7, 8, and 10 minus. The disk is movable on a brass rod 3 feet long, which is fastened at either end to two other brass rods 2 feet long, at right angles to it. These latter are hinged to a board which is fastened to the wall of the ophthalmoscopic room near the light. The hinges allow the apparatus to be turned back against the wall and out of the way when not in use. The rod on which the disk slides could be attached to a stand like a photographer's head-rest if so desired.

The manner of using it is so apparent as hardly to need description. The disk, after being adjusted to the proper height, can be rotated in front of the eye under examination, bringing the glasses in succession before it, either by the patient or by the examiner himself. A tape-measure is attached to the disk, which enables the operator to tell his exact distance from the eye under examination, and thus to practice the method according to the manner described by Chibret and by Jackson.

My own instrument was made at the establishment of Mr. J. A. Maloney of this city, and he tells me that their cost need not exceed $20.

TRANSACTIONS

OF THE

AMERICAN

OPHTHALMOLOGICAL SOCIETY.

Twenty-fifth Annual Meeting.

BOSTON MEDICAL
FEB 21 1890
LIBRARY ASS'N.

NEW LONDON, CONN., 1889.

HARTFORD:
PUBLISHED BY THE SOCIETY.
1889.

845

PRESS OF
THE CASE, LOCKWOOD & BRAINARD CO.
HARTFORD, CONN.

CONTENTS.

Members of the Society, ... 227
Minutes of the Twenty-fifth Annual Meeting, ... 231
Memorial notice of Dr. E. Williams, ... 237
An Analysis of 90 cases of Simple Chronic Glaucoma, etc., by Charles S. Bull, ... 243
Iridectomy in Glaucoma, by Dr. E. Gruening, ... 287
Use of the Curette in Inveterate Pannus, by Dr. E. Gruening, . . 304
A Contribution to the Management of Initial Myopia Acquisita, by Dr. S. O. Richey, ... 306
Enucleation during Panophthalmitis Suppurativa, by Dr. H. D. Noyes, ... 314
Caries and Necrosis of the walls of the orbit, by Dr. H. Knapp, . 319
Multiple Cysts of Iris in both eyes, by Dr. H. W. Williams, . . 326
Hysterical Blindness of ten years' duration in a healthy male subject, by Dr. G. C. Harlan, ... 327
Further observations on Malarial Keratitis, by Dr. C. J. Kipp, . . 331
Irrigation of the Anterior Chamber, by Dr. J. A. Lippincott, . . 341
Two cases of Extraction from the Vitreous of Steel which had passed through the lens, by Dr. O. F. Wadsworth, ... 349
An Analysis of some of the Ocular Symptoms observed in so-called General Paresis, by Dr. C. A. Oliver, ... 355
Case of Hemianopsia with peculiar cerebral symptoms, by Dr. S. B. St. John, ... 359
Simple Tests of the Ocular Muscles, by Dr. B. A. Randall, . . 362
Contributions to the subject of Tumors of the Orbit and neighboring Cavities, by Dr. C. S. Bull, ... 368
Case of Double Choked Disc due to intracranial tumor with autopsy, by Dr. C. S. Bull, ... 378
Spastic Torticollis, apparently due to faulty position of the eyes, and cured by tenotomy, by Dr. O. F. Wadsworth, ... 381
Partial Tenotomies in cases of Neurasthenia with insufficiencies of the ocular muscles, by Dr. Myles Standish, ... 388
Mydriasis of one Eye, with intact accommodation lasting four months after application of Homatropine to both eyes, by Dr. O. F. Wadsworth, ... 408
A new Rotary Prism, by Dr. S. D. Risley, ... 412

The inefficiency of Hydrobromate of Homatropine in controlling Accommodation, by Dr. E. Holt, ... 413
The Decentering of Lenses for accurate Prismatic Effects, with tables, etc., by Dr. E. Jackson, ... 417
A new method of Numbering Prisms by Dr. W. S. Dennett, . . 422
Extensive Vascular Growth in the Vitreous, by Dr. G. C. Harlan, . 426
Some Vagaries of Accommodation, by Dr. D. Coggin, . . . 429
Periscopic Cylindrical and Sphero-cylindrical Glasses, by Dr. G. C. Harlan, ... 433
The absolute Static Refraction of the Eye, by Dr. E. Jackson, . . 435
The Employment of the Oleate of Veratria to facilitate the determination of Errors of Refraction, by Dr. S. Theobald, . . . 442
On certain Stereoscopic Illusions evoked by prismatic and cylindrical spectacle glasses, by Dr. John Green, ... 449
A case of Sarcoma notable chiefly for its size and shape, by Dr. T. Y. Sutphen, ... 457

MEMBERS

OF THE

AMERICAN OPHTHALMOLOGICAL SOCIETY, 1889-90.

ACTIVE MEMBERS.

Dr. F. W. Abbott,	Buffalo, N. Y.
Dr. A. Alt,	St. Louis, Mo.
Dr. J. A. Andrews,	New York, N. Y.
Dr. S. C. Ayres,	Cincinnati, Ohio.
Dr. William T. Bacon,	Hartford, Conn.
Dr. Edwin W. Bartlett,	Milwaukee, Wis.
Dr. H. W. Bradford,	Boston, Mass.
Dr. Charles S. Bull,	New York, N. Y.
Dr. F. Buller,	Montreal, Canada.
Dr. Swan M. Burnett,	Washington, D. C.
Dr. Peter A. Callan,	New York, N. Y.
Dr. F. P. Capron,	Providence, R. I.
Dr. W. H. Carmalt,	New Haven, Conn.
Dr. D. C. Cocks,	New York, N. Y.
Dr. David Coggin,	Salem, Mass.
Dr. H. Culbertson,	Zanesville, Ohio.
Dr. George R. Cutter,	Brooklyn, N. Y.
Dr. David D. Beck,	Cincinnati, Ohio.
Dr. W. S. Dennett,	New York, N. Y.
Dr. Hasket Derby,	Boston, Mass.
Dr. Richard H. Derby,	New York, N. Y.
Dr. Lewis S. Dixon,	Boston, Mass.
Dr. Stephen Dodge,	Halifax, Nova Scotia.
Dr. Abram Du Bois,	New York, N. Y.
Dr. J. B. Emerson,	New York, N. Y.
Dr. L. Webster Fox,	Philadelphia, Pa.
Dr. B. E. Fryer,	Kansas City, Mo.
Dr. John Green,	St. Louis, Mo.

Dr. Emil Gruening,	New York, N. Y.
Dr. A. D. Hall,	Philadelphia, Pa.
Dr. H. F. Hansell,	Philadelphia, Pa.
Dr. George C. Harlan,	Philadelphia, Pa.
Dr. David Harrower,	Worcester, Mass.
Dr. Gustavus Hay,	Boston, Mass.
Dr. Albert G. Heyl,	Philadelphia, Pa.
Dr. Edward L. Holmes,	Chicago, Ill.
Dr. E. E. Holt,	Portland, Me.
Dr. Lucien Howe,	Buffalo, N. Y.
Dr. Edward Jackson,	Philadelphia, Pa.
Dr. B. Joy Jeffries,	Boston, Mass.
Dr. Samuel J. Jones,	Chicago, Ill.
Dr. Charles J. Kipp,	Newark, N. J.
Dr. H. Knapp,	New York, N. Y.
Dr. Carl Koller,	New York, N. Y.
Dr. Charles W. Kollock,	Charleston, S. C.
Dr. J. A. Lippincott,	Pittsburg, Pa.
Dr. F. B. Loring,	Washington, D. C.
Dr. C. J. Lundy,	Detroit, Mich.
Dr. M. V. Marmion,	Washington, D. C.
Dr. Arthur Mathewson,	Brooklyn, N. Y.
Dr. S. F. McFarland,	Binghamton, N. Y.
Dr. Charles H. McIlwaine,	Trenton, N. J.
Dr. R. J. McKay,	Wilmington, Del.
Dr. C. S. Merrill,	Albany, N. Y.
Dr. B. L. Milliken,	Cleveland, Ohio.
Dr. H. G. Miller,	Providence, R. I.
Dr. J. Lancelot Minor,	Memphis, Tenn.
Dr. W. F. Mittendorf,	New York, N. Y.
Dr. William O. Moore,	New York, N. Y.
Dr. Russell Murdoch,	Baltimore, Md.
Dr. William F. Norris,	Philadelphia, Pa.
Dr. Henry D. Noyes,	New York, N. Y.
Dr. J. F. Noyes,	Detroit, Mich.
Dr. Charles A. Oliver,	Philadelphia, Pa.
Dr. Henry S. Oppenheimer,	New York, N. Y.
Dr. O. D. Pomeroy,	New York, N. Y.
Dr. Thomas R. Pooley,	New York, N. Y.
Dr. M. H. Post,	St. Louis, Mo.
Dr. J. S. Prout,	Brooklyn, N. Y.

Dr. B. Alexander Randall,	Philadelphia, Pa.
Dr. William Rankin,	Newark, N. J.
Dr. R. A. Reeve,	Toronto, Canada.
Dr. Stephen O. Richey,	Washington, D. C.
Dr. Charles E. Rider,	Rochester, N. Y.
Dr. Samuel D. Risley,	Philadelphia, Pa.
Dr. Edmund C. Rivers,	Denver City, Col.
Dr. D. B. St. John Roosa,	New York, N. Y.
Dr. John D. Rushmore,	Brooklyn, N. Y.
Dr. Robert Sattler,	Cincinnati, Ohio.
Dr. H. S. Schell,	Los Angeles, Cal.
Dr. G. E. de Schweinitz,	Philadelphia, Pa.
Dr. W. W. Seeley,	Cincinnati, Ohio.
Dr. Henry L. Shaw,	Boston, Mass.
Dr. J. A. Spalding,	Portland, Me.
Dr. Francis B. Sprague,	Boston, Mass.
Dr. Myles Standish,	Boston, Mass.
Dr. George T. Stevens,	New York, N. Y.
Dr. Samuel B. St. John,	Hartford, Conn.
Dr. George Strawbridge,	Philadelphia, Pa.
Dr. T. Y. Sutphen,	Newark, N. J.
Dr. J. Oscroft Tansley,	New York, N. Y.
Dr. Lewis H. Taylor,	Wilkes Barre, Pa.
Dr. Samuel Theobald,	Baltimore, Md.
Dr. William Thompson,	Philadelphia, Pa.
Dr. John VanDuyn,	Syracuse, N. Y.
Dr. J. J. B. Vermyne,	New Bedford, Mass.
Dr. O. F. Wadsworth,	Boston, Mass.
Dr. Leroy Pope Walker,	New York, N. Y.
Dr. David Webster,	New York, N. Y.
Dr. Robert Willard,	Boston, Mass.
Dr. Charles H. Williams,	Chicago, Ill.
Dr. Henry W. Williams,	Boston, Mass.
Dr. F. M. Wilson,	Bridgeport, Conn.
Dr. J. P. Worrell,	Terra Haute, Ind.
Total,	104.

HONORARY MEMBER.

Dr. C. Schweigger,	Berlin, Prussia.
Whole Number,	105.

MINUTES OF THE PROCEEDINGS.

TWENTY-FIFTH ANNUAL MEETING.

PEQUOT HOUSE,
NEW LONDON, July 17, 1889.

The Twenty-fifth Annual Meeting of the Society was called to order at 10 A. M. by the President, Dr. WILLIAM F. NORRIS, who announced the following committees:

Committee on Bulletin — Drs. J. A. ANDREWS and C. A. OLIVER.

Committee on Membership — Drs. JOHN GREEN, ARTHUR MATHEWSON, SAMUEL THEOBALD, W. H. CARMALT, and C. S. BULL.

Auditing Committee — Dr. E. GRUENING.

The Treasurer's Report was read and referred to the Auditing Committee, and subsequently accepted and ordered to be placed on file.

Voted, — That the assessment for 1889–1890 be $5.00.

Drs. J. B. Shapleigh of St. Louis, C. M. Culver of Albany, and E. Friedenberg of New York, were invited to attend the meetings of the Society at this session and take part in the discussion.

The question of admitting two papers which had been read before other societies was discussed, and being left to the President to decide, the papers were admitted.

The Committee on Bulletin reported, and the following papers were read:

1. "An Analysis of ninety cases of simple Chronic Glaucoma, with special reference to the effects of iridectomy upon the acuity of vision and the visual field," by Dr. C. S. Bull. Discussed by Dr. Knapp.

2. "Iridectomy in Glaucoma," by Dr. Gruening. Discussed by Drs. Richey, Knapp, Bull, Theobald, Randall, Risley, Wadsworth, Lippincott, Hansell, Gruening, H. D. Noyes, Seely, Theobald, Matthewson, St. John, and Williams.

3. "Curetting of the Cornea in cases of Trachomatous Pannus," by Dr. Gruening. Discussed by Dr. St. John.

4. "Corneal Abscess," by Dr. Hansell.

5. "Observations on Malarial Keratitis," by Dr. Kipp. Discussed by Drs. H. D. Noyes, Sutphen, Green, Gruening, Theobald, Williams, Knapp, Kipp, and Miller.

6. "Irrigation of the Anterior Chamber," by Dr. Lippincott. Discussed by Dr. Gruening.

7. "Contribution to the management of initial Myopia Acquisita," by Dr. S. O. Richey.

8. "Exhibition of a spectacle frame," by Dr. Noyes. Discussed by Dr. Theobald.

9. "Suppurative Panophthalmitis," by Dr. H. D. Noyes. Discussed by Drs. Kipp, Williams, and Knapp.

Dr. Webster showed two sword-fishes' eyes.

Adjourned at 2 P. M. to meet at 4 o'clock.

Meeting called to order at 4 P. M.

The Auditing Committee reported the Treasurer's accounts to be correct and properly vouched for, and the report was accepted and ordered to be placed on file.

The reading of papers was then resumed.

10. "Treatment of Caries and Necrosis of the Orbit," by Dr. Knapp.

11. "Multiple Cysts of the Iris in both Eyes," by Dr. H. W. Williams.

12. "Case of Sarcoma of the Optic Nerve," by Dr. T. Y. Sutphen.

13. "Extensive Vascular Growth in the Vitreous," by Dr. Harlan.

14. "Two cases of extraction of bits of Steel from Vitreous by Magnet," by Dr. Wadsworth.

15. "Two cases of Corneal Transplantation," by Dr. Tansley. Discussed by Drs. Fox and Pomeroy.

16. "An Analysis of some of the ocular conditions in the so-called General Paresis of the Insane," by Dr. Oliver.

17. "Case of Hysterical Blindness of ten years' duration occurring in a Male Subject," by Dr. Harlan. Discussed by Drs. Webster and St. John.

18. "Case of Hemianopsia with peculiar Cerebral Symptoms," by Dr. St. John.

19. "Case of double purulent Choroiditis," by Dr. Sutphen. Discussed by Drs. Knapp and H. D. Noyes.

20. "Notes on simple tests of the Ocular Muscles," by Dr. Randall.

Adjourned at 6 P. M. to meet at 8.30 o'clock.

Meeting called to order at 8.30 P. M.

Executive Session.

Dr. Green reported for the Committee on Admissions, that the following gentlemen were recommended for election to the Society: Dr. CARL KOLLER, Dr. B. A. REEVE, Dr. DAVID HARROWER, Dr. GEO. E. DE SCHWEINITZ.

Upon ballot, all of the above-named gentlemen were elected members of the Society.

The Committee on Membership made the following nominations:

For President — Dr. HASKET DERBY.
For Vice-President — Dr. GEORGE C. HARLAN.
For Corresponding Secretary — Dr. J. S. PROUT.

For Recording Secretary — Dr. S. B. St. John.

For Publishing Committee — Drs. D. B. St. John Roosa, W. S. Dennett, and the Secretary (*ex officio*).

The above officers were unanimously elected.

The Committee recommended as the place of the next Annual Meeting, The Hotel Kaaterskill, and it was so voted.

Adjourned to 9 a. m. 18th July.

Meeting called to order by President at 9.45 a. m.

The reading of papers was resumed.

21. "Contribution to subject of Tumors of the Orbit and neighboring Cavities," by Dr. C. S. Bull. Discussed by Drs. Knapp, Mittendorf, Randall, Reeve, and Risley.

22. "Case of Double Choked Disk with Intra-cranial Tumor, with Autopsy," by Dr. Bull. Discussed by Dr. Knapp.

23. "Case of Spastic Torticollis cured by Tenotomy of Sup-Rectus," by Dr. Wadsworth. Discussed by Drs. Risley, Wadsworth, and Randall.

24. "Partial Tenotomies in cases of Neurasthenia with insufficiency of the Ocular Muscles." Discussed by Drs. Risley, Harlan, Theobald, Jackson, Wadsworth, Harlan, and Standish.

25. "Notes of some vagaries of Accommodation," by Dr. Coggin.

26. "Effect on Accommodation of Patient's Eyes during Ophthalmoscopic Examination caused by looking into a mirror set obliquely in the room," by Dr. Holt.

27. "Paralysis of Sphincter Iridis of one eye without affection of accommodation, lasting several months, and following instillation of Homatropine in both eyes," by Dr. Wadsworth. Discussed by Drs. Theobald, Risley, Seely, St. John, Wadsworth, and Holt.

28. "Geometrical constructions illustrating certain cases of Oblique Pencils refracted at Cylindrical or Spherical Surfaces," (by title) Dr. J. Green.

29. "On some of the Stereoscopic Illusions evoked by unequal glasses placed before the two eyes," by Dr. Green. Discussed by Drs. Wadsworth, Lippincott, and Jackson.

30. "The employment of Oleate of Veratria to facilitate the determination of errors of refraction," by Dr. Theobald. Discussed by Drs. Mittendorf, Armalt, Randall, and Standish.

31. "Exhibition of Revolving Prisms," by Dr. Risley.

32. "The Inefficiency of Hydrobromate of Homatropine in controlling the accommodation of the eye for the purpose of fitting glasses," by Dr. Holt. Discussed by Drs. Jackson, Gruening, and Randall.

33. "Ametropia as determined under complete Mydriasis," by Dr. Jackson. Discussed by Drs. Dennett and Callan.

34. "Accuracy in the Prescription of Prisms," by Dr. Jackson.

35. "A new unit of angular measurement suggested for Prismatic Glasses," by Dr. Dennett. Discussed by Dr. Dennett.

36. "Exhibition of Periscopic Cylindrical and Sphero-cylindrical Glasses," by Dr. Harlan.

37. "Case of Amblyopia," (by title) Dr. Mittendorf.

The records of the meeting were read and adopted.

Adjourned at 1 P. M.

Members present at the Twenty-fifth Annual Meeting:

Dr. J. A. ANDREWS,
Dr. WILLIAM T. BACON,
Dr. CHARLES S. BULL,
Dr. PETER A. CALLAN,
Dr. F. P. CAPRON,
Dr. W. H. CARMALT,
Dr. D. C. COCKS,
Dr. DAVID COGGIN,
Dr. GEORGE R. CUTTER,
Dr. W. S. DENNETT,
Dr. LEWIS S. DIXON,
Dr. J. B. EMERSON,
Dr. L. WEBSTER FOX,
Dr. B. E. FRYER,
Dr. JOHN GREEN,
Dr. EMIL GRUENING,
Dr. H. F. HANSELL,
Dr. GEORGE C. HARLAN,
Dr. GUSTAVUS HAY,
Dr. E. E. HOLT,
Dr. EDWARD JACKSON,
Dr. CHARLES J. KIPP,
Dr. H. KNAPP,
Dr. J. A. LIPPINCOTT,
Dr. ARTHUR MATHEWSON,
Dr. S. F. MCFARLAND,
Dr. H. G. MILLER,
Dr. W. F. MITTENDORF,
Dr. WILLIAM F. NORRIS,
Dr. HENRY D. NOYES,
Dr. J. F. NOYES,
Dr. CHARLES A. OLIVER,
Dr. HENRY S. OPPENHEIMER,
Dr. O. D. POMEROY,
Dr. J. S. PROUT,
Dr. B. ALEXANDER RANDALL,
Dr. STEPHEN O. RICHEY,
Dr. SAMUEL D. RISLEY,
Dr. JOHN D. RUSHMORE,
Dr. W. W. SEELEY,
Dr. MYLES STANDISH,
Dr. SAMUEL B. ST. JOHN,
Dr. T. Y. SUTPHEN,
Dr. J. OSCROFT TANSLEY,
Dr. LEWIS H. TAYLOR,
Dr. SAMUEL THEOBALD,
Dr. J. J. B. VERMYNE,
Dr. O. F. WADSWORTH,
Dr. DAVID WEBSTER,
Dr. HENRY W. WILLIAMS,
Dr. F. M. WILSON.

Present by invitation:

Dr. J. B. SHAPLEIGH,
Dr. C. M. CULVER,
Dr. A. FRIEDENBERG.

S. B. ST. JOHN,
SECRETARY.

Yours as ever:
E. H. Williams

F. GUTEKUNST PHILADA.

DR. E. WILLIAMS.

By Dr. R. SATTLER.

The year 1888 evoked much sorrowful interest among the members of this Society, on account of the death of three of its members. In the fall of the year (Oct. 6th, 1888) another name was added — that of Dr. E. Williams of Cincinnati.

The name erased from the membership roll has been associated with the American Ophthalmological Society from its earliest beginning. Dr. Williams was one of its most zealous promoters: he witnessed and was instrumental in its birth; he watched with eager solicitude and unflagging interest its early growth, and from the first and throughout the intervening period of its progressive advance, he upheld for it an exalted standard of the highest possible scientific and practical realization.

If his energies were untiringly and willingly devoted to the interests of this Society, his name must be mentioned, as well as that of his friend Dr. Agnew, for having been foremost among that limited number of exclusive specialists of thirty or more years ago, who were constantly directing their efforts to elevate the standard and assist the progress of Ophthalmology in America, but recently so brilliantly and successfully ushered in, in Europe by the combined labors of Von Baer, Von Jaeger, Von Graefe, Arlt, Helmholtz, in Germany; Donders in Holland; Sichel, Desmarres, in France, and Mackenzie, Crichett, and Bowman in England.

As a pupil, and later as a representative of this school of classical ophthalmology, he was again among the first to kindle the spark of enthusiasm among the profession in this country, and particularly in the Western States. His indefatigable labors secured a general recognition for ophthalmology as a distinct and important department of medical knowledge at a comparatively early period.

Dr. Williams went abroad in the fall of 1852 with the avowed intention of devoting special attention to surgery, though with a decided inclination to take up the study of ophthalmology. His own inclination and the advice of Prof. J. D. Gross, his personal friend, and at the time professor in Louisville, markedly influenced this determination.

Commencing his studies in France, the reports from Germany of the brilliant invention of Helmholtz, the crowning achievements of Von Graefe, together with the general enthu-

siasm in medical affairs, so impressed him that he left France and went to Germany, having finally determined to take up ophthalmology as his specialty. He with many others foresaw the far-reaching scope of ophthalmology. How speedily it was elevated to one of the most exact and scientific departments of the medical sciences is well known.

Dr. Williams enjoyed another rare advantage: he had a natural taste and aptitude for languages, both ancient and modern. In a comparatively brief period he mastered both French and German, and gained unexceptionably complete control of both languages.

The knowledge of these languages, particularly German, gave him an inestimable advantage over his fellow-students. It brought him in familiar personal contact with A. Von Graefe in Berlin, Von Arlt in Prague, Desmarres and Sichel in Paris, and other distinguished clinicians.

He spent two years and a half abroad, availing himself of every advantage which could be procured from private and university instruction. He traveled extensively. He had ample means and was enthusiastic and determined in the pursuit of his one object, to qualify himself in the most thorough manner for his life's work on his return to America.

Dr. E. Williams, at the time of his death, had almost completed his sixty-sixth year. He was born Dec. 19, 1822, in Lawrence County, Ind. In 1886 ill health obliged him to abandon active professional work, his career as a specialist having embraced full thirty-one years.

He was one of a family of ten children. His parents were among the first settlers in Lawrence County, Ind. His brothers, seven in number, all followed the example of their father and engaged in agricultural pursuits. Dr. Williams, who was regarded as the most frolicsome and lighthearted of the family, was the only one who manifested a desire for study, and eagerness for literary pursuits. The bent of self-culture asserted itself in early life, and every available opportunity was utilized.

After receiving his preliminary education in the schools of Bedford, Ind., he entered Ashbury University, and after a four years' course, received his degree in 1847.

For a short time he taught school, but soon finding favorable opportunities to carry out the cherished idea of his life, and devote himself to the study of medicine, he entered the University of Louisville, Ky., attended two full courses of lectures, and received his degree of M.D. in 1850.

He engaged in the general practice of his profession for about eighteen months, and again returned to Louisville to attend a post-graduate course. In 1852 he went to Cincinnati,

desirous of establishing himself in a place offering a larger scope for professional activity. He left Cincinnati in 1852 to pursue his studies abroad, returning in May, 1855.

Upon his return to America he determined to limit himself to the practice of ophthalmology, and he did not resume general practice after this period, engaging at once in the practice of his chosen specialty in Cincinnati. He must therefore at the time of his death be regarded as among the oldest of exclusive American oculists. West of the Alleghany Mountains and over the extensive Western Territory, he was the pioneer ophthalmologist. There the fruits of his labors first gave evidence of their practical worth, and the claim to priority can not be disputed.

The extent and importance of his early labors will remain unwritten. In the beginning of his career as a specialist, he met with opposition and many disappointments both from the profession and laity. It was, however, to be foreseen with reasonable certainty that success, eminence, and fame must sooner or later come to a man of his superior endowments and perfect moral equipoise, who in addition to an excellent preliminary training had also profited by a thorough medical education in one of the best equipped medical schools of that time, under the special tutelage of Prof. J. D. Gross and Dr. Richardson of New Orleans, two men who even at that time had risen to more than local eminence. His European experiences, his linguistic achievements, his studious habits, and ungovernable spirit of progress foretold this as a certainty.

Before his return to America he had contributed a paper of exceptional interest, in which he gave a practical demonstration in London, England, in July, 1854, on the use of the ophthalmoscope. Mention of this is made in the *Medical Times Gazette*, page 7, linking his name with a praiseworthy effort, for which he also received the appreciation of the English ophthalmologists.

After his return to America he established a charity eye-clinic on the plan of the European institutions. Through his efforts mainly, and as a merited tribute to his zeal, the first professorship of ophthalmology in America was created in the Miami Medical College. He held this position until he was disabled by ill-health.

He contributed numerous articles to American and foreign journals, and for many years was one of the associate editors of the Cincinnati *Lancet and Observer*. During his editorship he presented to the readers of this journal, in almost every issue, articles relating to the diseases of the eye, of diagnostic or therapeutic interest to the general practitioner; he also kept prom-

inently before the medical profession the advances made in the various departments of ophthalmology in Germany, France, and England.

He was the author of the article on "Injuries of the Eye" in Ashurst's System of Surgery, which, written in a concise and terse style, reflected the results of his large experience.

He revisited Europe several times, attending the Ophthalmological Congress in Paris in 1861. In 1866 and 1872 he returned for shorter visits.

His attachments for Profs. Von Graefe and Von Arlt bordered upon veneration. His friendship for his European confreres and his early associations were among the cherished recollections of his later years, and were constantly referred to with renewed pleasure and satisfaction.

Tall and broad-shouldered, with a merry facial expression which mirrored his genial character, eyes which by their soft and penetrating gaze fascinated the attention and invited discussion, associated with this a frank and earnest address, uniformly courteous manners, devoid of all studied or acquired polish, one could but be impressed that with him the art of being and appearing agreeable was a natural or spontaneous attribute or gift. Endowed with a disposition broad, generous, and affectionate, an even and jolly temperament, he attracted many people, and in his social as well as his professional relation he was always a conspicuous man, in particular because his ready conversational power, adaptive ability, and diverse funds of information rendered easy an approach with strangers.

His fund for story telling was, among his friends, almost proverbial, and this, as well as his knack for their favorable introduction, must also be considered one of his characteristics; certain it is that it afforded him as much pleasure as it often did his listener.

As a didactic and clinical lecturer he excelled. His delivery was not alone attractive, but his style so inimitable and fascinating, his information so extensive, that he was regarded by students as one of the most entertaining and instructive lecturers. He held for many years the position of ophthalmic surgeon to the Commercial Hospital, and during the War of the Rebellion his services were freely and constantly bestowed upon the wounded in the various hospitals of Cincinnati.

He was the recipient of many honors: the Ophthalmological Society of Great Britain made him an honorary member in 1884, and a similar recognition was tendered him from the Athens Medical Society in 1880; besides these, he held many positions of honor and trust. A tribute justly bestowed was the honor extended to him by this society, tendering him the

presidency in 1876. To his dignity, justice, and progressive tendencies as a presiding officer at the International Congress in New York, those who were present can bear ample testimony.

In his judgment of men and their actions, he was as charitable as he was liberal and just; firm in his own convictions pertaining to religious and secular affairs, he accorded the most respectful recognition to the views of others. He was an upright Christian, and his conduct in religious matters was exemplary. To his own cherished religious views, and to the simple creed of his church, he was zealously devoted.

Dr. Williams was twice married. His first wife died in 1851, and left him a daughter, his only child. With his second wife he lived during a period of uninterrupted happiness, celebrating only a few years before his death his silver wedding, enjoying and giving in return the most unselfish affection of a husband and father.

His family life reflects only to a more beautiful degree the many noble characteristics which his public and professional career so constantly evidenced and brought out.

The history of Dr. Williams' life illustrates one of the most brilliant and useful professional careers, crowned by an exceptional eminence in his specialty among the profession, and a reputation among the laity remarkable for its extensive, and at one time almost general scope.

It may indeed be said of him that his was in the fullest sense of the word a useful, painstaking, and unselfish life, overflowing with humanity, charity, and good will.

Appended is a list of his contributions to ophthalmology:—

January, 1856. (Cincinnati Lancet and Observer.)
Cases of Keratoconus, or Conical Cornea.

January, 1857. (Cincinnati Lancet and Observer.)
Kyklitis or Inflammation of the Corpus Ciliare.

August, 1857. (Cincinnati Lancet and Observer.)
Cases of Trachoma with Pannus, treated by Inoculation with Gonorrheal Matter.

October, 1857. (Cincinnati Lancet and Observer.)
On the Treatment of Pannus by Inoculation.

March, 1858. (Cincinnati Lancet and Observer.)
Excision of a Cicatrix in the Cornea, for the Relief of Neuralgia of the Eye and Face.

May, 1858. (Cincinnati Lancet and Observer.)
Cases of Parasites in the Human Eye.

March, 1859. (Cincinnati Lancet and Observer.)
Cataract operated on by Linear Extraction.

May, 1859. (Cincinnati Lancet and Observer.)
Injuries of the Eye. With report of Cases.

July, 1859. (Cincinnati Lancet and Observer.)
Obliteration of the Lachrymal Sac by Actual Cautery.

December, 1859. (Cincinnati Lancet and Observer.)
Diseases of the Lachrymal Sac.

December, 1859. (Cincinnati Lancet and Observer.)
Iridectomy in Glaucoma.

February, 1860. (Cincinnati Lancet and Observer.)
Exophthalmus with Goitre and Functional Derangement of the Heart.

April, 1861. (Cincinnati Lancet and Observer.)
Fluid Cataract.

August, 1862. (Cincinnati Lancet and Observer.)
Vesicles on the Cornea.
Separation of the Retina.

November, 1863. (Cincinnati Lancet and Observer.)
Trachoma. Causes and Mode of Propagation.
A Paper read before the Cincinnati Academy of Medicine.

February, 1864. (Cincinnati Lancet and Observer.)
Treatment of Trachoma.

August, 1864. (Cincinnati Lancet and Observer.)
Phlyctenular Ophthalmia.

December, 1864. (Cincinnati Lancet and Observer.)
Hypopium-Keratitis.

March, 1865. (Cincinnati Lancet and Observer.)
Aqua Chlori as a Collyrium.
Diseases of the Eye. (Cincinnati Lancet and Observer.)
The Ophthalmoscope, Construction of the Instrument and the Method of using it. (Cincinnati Lancet and Observer.)
Reute's Ophthalmotrope. (Cincinnati Lancet and Observer.)

Clinical Statistics and Observations drawn from my Private Practice for the year 1864. (Cincinnati Lancet and Observer):
Caries of the Orbit.
Cysts of the Orbit.
Exophthalmos from Phlegmon of the Orbit.
Ectropium.
Inoculation and Syndectomy.
Discharge of the Vitreous Humor in Flap Extractions.
Modified Linear Extraction.
Extraction of Cataract without opening the Capsule.
Hemeralopia, or Night Blindness. (With Report of the Case.)
Retinal Detachment. Operation and Result.
Sarcoma of the Choroid.
Thread Operation to relieve Secondary Divergent Strabismus.

Rare Cases with Practical Remarks:
Basedow's Disease.
Anæsthesia Retinæ.
Binocular Temporal Hemiopia.
Strabismus with Rigidity of the Muscle.

From the Transactions of the American Medical Association, 1865:
Stricture of the Nasal Duct.
Paracentesis Corneæ.
The Unguentum Citrinum Rubrum, or Brown Citrine Ointment.

March, 1869. (Cincinnati Lancet and Observer.)
Tumor of the Brain with Optic Neuritis.

September, 1876. (Transactions of the International Medical Congress, Philadelphia, Pa.)
Orbital Aneurismal Disease and Pulsating Exophthalmia; their Diagnosis and Treatment.

November, 1879. (Tri-State Medical Association, Evansville, Ind.)
Symptomatology of Optic Neuritis.

AN ANALYSIS OF NINETY CASES OF SIMPLE CHRONIC GLAUCOMA, WITH SPECIAL REFERENCE TO THE EFFECTS OF IRIDECTOMY ON THE ACUITY OF VISION AND THE VISUAL FIELD.

BY CHARLES STEDMAN BULL, M.D.

NEW YORK.

The remarks embodied in this paper are based upon a careful analysis of ninety cases of simple chronic glaucoma, which the writer was enabled to follow out for a varying length of time subsequent to operation. They embrace all the facts in regard to each case which have any bearing upon the subject of the effects of iridectomy upon the acuity of vision and the state of the visual field. The cases extend over a period of about seventeen years, were all examined and treated by the reporter, and the conclusions drawn are therefore derived merely from his own personal experience.

Of the ninety cases under consideration, forty-four (44) were males and forty-six (46) were females, the cases being nearly equally divided between the sexes. The age of the patients varied between twenty-four (24) and eighty-six (86) years.

In the decade	between	20	and	30	there	were	two	cases.
"	"	"	38	"	40	"	seven	"
"	"	"	40	"	50	"	sixteen	"
"	"	"	50	"	60	"	twenty-four	"
"	"	"	60	"	70	"	thirty-three	"
"	"	"	70	"	80	"	four	"
"	"	"	80	"	90	"	four	"

Of the ninety (90) cases, seventy-seven (77) were Christians and only thirteen (13) were Hebrews. This is contrary to the usually accepted belief, that the Hebrew race is peculiarly prone to this disease.

The *refraction* of the one hundred and eighty (180) eyes of these ninety (90) patients varied as follows: Simple hyper-

metropia existed in one hundred and five (105) eyes; simple myopia was found in ten (10) eyes; and emmetropia existed in six (6) eyes. Simple hypermetropic astigmatism was found in ten (10) eyes; and simple myopic astigmatism in three (3) eyes. Compound hypermetropic astigmatism was met with in twenty-four (24) eyes, and compound myopic astigmatism in two (2) eyes. In two (2) eyes a condition of phthisis bulbi prevented any measure of the refractive condition, and in eighteen (18) eyes the advanced state of the cataract present was an obstacle to the same end.

The *cornea* was more or less cloudy in the right eye in five (5) cases, and in the left eye in five (5) cases.

The *anterior chamber* was shallow in one eye in thirty-four (34) cases, and in both eyes in forty-one (41) cases. It was of normal depth in twenty-five (25) eyes and was entirely abolished in twenty-eight (28) eyes.

The *iris* was more or less movable in all the cases, except in those eyes in which the condition was that of absolute glaucoma.

The *lenses* were entirely clear in one hundred and twenty-two (122) eyes; sixty-three (63) on the right side and fifty-nine (59) on the left side.

There were slight peripheral opacities in the lens in thirty-five (35) eyes, nineteen (19) on the right side and sixteen (16) on the left side.

There was cataract in an advanced stage in eighteen (18) eyes; in six (6) cases in the right eye, and in twelve (12) cases in the left eye.

Phthisis bulbi existed in one eye in two cases. In one of these cases the eye had been lost in childhood from purulent conjunctivitis, and in the other case the loss of the eye was due to traumatism, and occurred in childhood or early youth.

The *glaucomatous excavation* of the optic disc was very deep in one hundred and six (106) eyes; moderate in depth in forty-eight (48) eyes; and in seven (7) eyes there was no excavation demonstrable, though there was both diminution of vision and narrowing of the field of vision.

The condition of the *field of vision* varied greatly, and is

worthy of close and attentive study. In five (5) cases it was contracted in one eye and normal in the other. In eighteen (18) cases it was contracted in one eye and either telescopic or entirely absent in the other. In thirty-nine (39) cases it was contracted in both eyes. In seven (7) cases there was no measurable field in one eye, and in the other there was absolute glaucoma. In twelve (12) cases it was contracted in one eye moderately, and there was absolute glaucoma in the other. In six (6) cases there was no measurable field in either eye. In three (3) cases there was no limitation in the field of either eye. In one case there was absolute glaucoma in one eye and a perfectly normal field in the other.

Among the ninety cases, or one hundred and eighty (180) eyes, there were twenty-two (22) eyes afflicted with *absolute glaucoma*, nine (9) on the right side and thirteen (13) on the left side. In each of these cases, the other eye was the seat of simple chronic glaucoma.

The *intraocular tension* was increased in both eyes in seventy-five (75) cases. It was increased in the right eye alone in eight (8) cases, and in the left eye alone in six (6) cases. The tension was normal in both eyes in three (3) cases; in the right eye alone in four (4) cases, and in the left eye alone in eight (8) cases. The tension was diminished in the right eye in two (2) cases.

One of the most doubtful points in the history of the development of simple chronic glaucoma is in the determination of the *interval* between the outbreak of the disease in the two eyes. In the majority of the cases the patients are unable to determine how long an interval existed between the beginning of the attack in the two eyes, and in many instances the statement of a simultaneous attack in both eyes is of very doubtful value. Among the ninety patients under consideration, sixty-four (64) were unable to give any opinion as to the length of interval between the attacks in the two eyes, and many of these stated vaguely that the disease began simultaneously in both eyes. In twenty-six (26) cases the interval was known with tolerable accuracy, and varied between two months and twelve years. In twenty-eight (28) cases, the right eye was the first

attacked, and in twenty-two (22) cases the disease began in the left eye.

In all the ninety (90) cases, the only operation done was an *iridectomy*, always broad and usually upwards, and in the majority of cases the instrument used was the ordinary lance-knife. In no case was the operation followed by any extraordinary amount of hemorrhage, nor by any symptom pointing to malignant complication.

In forty-five (45) cases a *simultaneous* iridectomy was done on both eyes. In seventeen (17) cases an iridectomy was done on one eye, and was followed at a varying interval by an iridectomy upon the fellow eye. In eight (8) cases an iridectomy was done on one eye only, the other eye remaining normal as long as the patient was under observation, which in many instances extended over a period of years. In two cases, two iridectomies were done upon one eye, with an interval between them. In one case an immature cataract was extracted at the time of the operation of iridectomy. In one case a sensitive atrophied stump was enucleated, preliminary to an iridectomy on the other eye. In twenty (20) cases an iridectomy was done on one eye, the other eye being blind from absolute glaucoma. In all these cases of simple chronic glaucoma the chief interest centers in the state of the *acuity of vision* and the *prognosis* as to the results of an operation. To this end an accurate history was kept of each case, with special reference to vision and the visual field, before and after the operation for a varying length of time, which in some cases extended over a period of years, and the result is very far from encouraging, as the cases show a condition of the vision and visual field rather worse than had been anticipated.

One hundred and fifty-four (154) operations were done on the one hundred and eighty (180) eyes under consideration. Vision was temporarily improved by the iridectomy in both eyes in two cases, and in one eye in six cases; but in all eight cases, after a few months, a steady loss of vision and narrowing of the field set in, and continued progressively as long as the patients were under observation.

Vision remained unchanged, neither better nor worse, after

the operation for a period of one year or longer in both eyes in eight (8) cases, and in one eye in twenty (20) cases.

Vision grew slowly and steadily worse after the operation in both eyes in forty-one (41) cases, and in one eye in twenty-nine (29) cases.

Vision grew rapidly worse after the operation in both eyes in two (2) cases, and in one eye in eight (8) cases.

One point in connection with the effect of the operation upon the resultant vision is of some importance, and sufficient attention does not seem to have hitherto been called to it. In those cases in which the lens shows peripheral opacities, whether due to the natural senile change or directly to the interference with the nutrition of the lens induced by the glaucoma, the question would naturally arise: "What effect has the iridectomy upon the lenticular opacities?" Peripheral opacities of the lens existed in thirty-five (35) of the one hundred and eighty (180) eyes considered, and repeated examinations showed that the operation had materially hastened the growth of the cataract in twenty (20) eyes, or more than fifty per cent.

Another point elucidated by a study of these cases is that the effect of the operation varies as to vision according to the stage of the disease at the time of operation. If we limit arbitrarily the early stage of the disease to the first six months, and regard everything beyond this as belonging to the later stages of the disease, it will be seen that the earlier the operation is done the more likely are we to obtain a good result, but to this there are not a few marked exceptions. It will be well in this comparison to regard every case, where the existing vision has been maintained after the operation, as a good result. A comparison of the results of operation in these cases shows that an early operation gave a good result in both eyes in four (4) cases and in one eye in eight (8) cases. But the reverse of this is somewhat significant, viz.: An early operation gave a bad result in both eyes in four (4) cases and in one eye in twelve (12) cases. Now, when we come to consider the later stages of the disease, we find that a late operation gave bad results in both eyes in thirty-four (34) cases and in one eye in twenty-six (26) cases. The reverse of this is, however, sig-

nificant, viz.: A late operation gave a good result in both eyes in three (3) cases and in one eye in eleven (11) cases.

In analyzing the histories of these cases, both individually and collectively, it will be found a difficult matter to draw any satisfactory conclusions as to prognosis after operation. Many of the cases of simple chronic glaucoma are of long duration, even when left entirely untreated. Experience has taught most operators that a large iridectomy often causes serious optical inconvenience, even when the vision is fairly good, and that in many instances when the field is much contracted, an iridectomy causes a still further diminution in the size of the field. Furthermore, the state of tension is no reliable guide in forming a prognosis, and bears no constant relation to the condition of the iris or anterior chamber, or to the acuity of vision and state of the visual field. The depth of the excavation in the optic disc bears a very inconstant relation to both the degree of vision and the state of the field, and is almost equally at variance with the condition of intraocular tension. It is no uncommon experience to find an almost typical glaucomatous excavation in an eye with perfectly normal vision and visual field, and without another symptom of glaucoma. Yet in these cases Nettleship hints that such an excavation may be of importance as tending to prove that chronic glaucoma may begin rather in the optic nerve than in the ciliary region, and argues that such suspicious appearances may precede the outbreak of rapid glaucoma (see Royal London Ophthalmic Hospital Reports, xii. 2).

There are several known causes for the failure of the operation to stay the progress of the disease. One of these is some unfavorable process going on in the vicinity of the wound, especially in aged patients, or in those in a bad state of health. Another is a more or less marked displacement of the lens by the operation, owing to undue violence, or to a weak suspensory ligament, which, in its turn, leads to the development of cataract, especially in eyes with peripheral opacities already existing in the lens. Another cause, not infrequently seen after an iridectomy done simply for optical purposes, is a slowly progressive haziness of the cornea, extending usually from the

location of the wound. This I have not myself met with in any case of glaucoma. Another not infrequent cause, resulting directly from the operation, is the continued contraction of the field of vision.

The opinion is held by some authors that when glaucoma occurs in a myopic eye, it does so early in the patient's life. This has not been my experience. Among the 180 eyes under consideration, myopia, or myopic astigmatism, or both, was met with in fifteen eyes, occurring among nine (9) patients, and of these nine patients only two were under sixty years of age. This result is directly at variance with the latest statistics published by Nettleship. With regard to the opinion that the prognosis in such cases is especially bad, my experience is not sufficient to justify any conclusion.

The prognosis, after operation, is also influenced by the condition of the patient's health, and probably also by the location and size of the wound. The farther back from the corneal margin the wound is made, the larger will be the segment of iris removed, and the less the likelihood of the formation of anterior synechiæ. There are certain opinions held by most ophthalmologists in regard to the so-called cystoid or "filtering" cicatrix, namely, that in desperate cases it is a favorable condition, by allowing free percolation of fluid through the lips of the wound and beneath the conjunctiva, and thus aiding in keeping the tension low. This is undoubtedly true in so far as the maintenance of normal tension has a direct influence upon the maintenance of the existing vision. But this is only one of the factors interested in the maintenance of the existing vision, and not a few cases of simple chronic glaucoma show a diminished tension from start to finish, and these cases, in the reporter's experience, all end unfavorably.

CONCLUSIONS.

In endeavoring to draw some rational conclusions from the study of ninety cases, it seems wise to begin with a quotation from Priestley Smith, to whom ophthalmologists owe so much of their knowledge of the pathogeny and pathology of glaucoma.

1. In considering the expediency of an operation in simple

chronic glaucoma, he says: "In every case of chronic glaucoma, the responsibility of advising an operation is a heavy one, and should on no account be undertaken without a full explanation to the patient or his friends of the almost positive certainty of blindness on the one hand, and of the uncertainties which beset the operation on the other. Having regard to the age of the patient, the impossibility of great benefit, and the possibility of a painful and accelerated progress, a prudent surgeon will only operate on the express desire of the patient to receive the only possible chance of benefit, however small it may be." Armed with the preceding precaution, it seems to be our duty to operate in cases of chronic progressive glaucoma, and the earlier the better.

2. If the disease in a given case seems to be stationary, and is still in the primary stage, and if it be possible to test the vision and the visual field at short intervals, delay in operating is permissible, but a weak solution of eserine or pilocarpine should be used daily, merely as an aid in controlling the course of the disease. The examination of these patients should be at short intervals, and should invariably include the test for visual acuity, and the careful examination of the visual field.

3. If the disease exist in both eyes, but with useful vision in both eyes, the eye in which the disease is the more advanced should be operated upon without delay; and the surgeon will be guided in his treatment of the fellow eye by the result of the operation on the first eye.

4. To insure the best result, the incision should be made well in the sclerotic, with a narrow cataract knife, or a broad lance knife, and the entire iris, from one end of the incision to the other, should be carefully torn or excised from its insertion.

5. The most carefully performed iridectomy by skillful hands is sometimes followed by the rapid loss of what sight still remains, sometimes partial, but unfortunately sometimes also total.

6. A successful result is, in the majority of cases, more likely to follow the operation if it is performed early in the course of the disease, but the maintenance of the existing degree of vision, even in these cases, is not invariable.

7. As regards the question of *symmetry*, it is probable that in the large majority of cases, probably as much as eighty per cent., the disease is sooner or later present in both eyes, and a careful study of the cases seems to establish the fact that there can be no specified interval of time which insures the second eye against an attack.

8. If the patient is old and feeble, and one eye is still free from the disease for a year or more after the other eye has become affected, it may be considered prudent to avoid an operation on the affected eye; as it is probable that the unaffected eye may remain free during the remainder of the patient's life.

9. The condition of the field of vision is no constant guide, either in forming a prognosis as to the progress of the disease, or in deciding as to the time of operation.

10. The acuity of vision bears no constant relation to either the success or the failure of the operation.

11. The anterior chamber is usually shallow, is occasionally entirely absent, but is often apparently normal in depth. The condition of the chamber gives no reliable hint as to the state of the vision or the visual field, nor any indication as to prognosis.

12. The appearance and mobility of the iris appear to have some bearing upon the prognosis, though not perhaps to the extent believed by Nettleship. The latter states that in the cases in which the iris reacted rapidly to eserine, the operation proved successful. This has not always been the experience of the reporter. But in the majority of the cases in which eserine caused rapid contraction of the pupil, the visual acuity was fairly good and the field was not seriously limited.

13. The depth of the excavation in and the color of the optic disc seem to have no close connection with the defect in vision or with the limitation of the visual field, nor do they offer any constant guide as to prognosis or to the effect of an operation upon the progress of the disease.

14. The condition of the intraocular tension is a very uncertain guide in deciding the time for operating. It may be normal, or increased, or even diminished. It does not even seem to bear any constant relation to the degree of visual

acuity or to the state of the visual field. The steady maintenance of an increased tension, however, without any diminution, almost invariably indicates the necessity for an immediate operation, and this necessity is especially indicated if the tension is continually on the increase.

15. The health and age of the patient exert a decided influence upon the effect of the operation, and any marked evidence of senility is distinctly unfavorable to operation.

HISTORIES IN DETAIL OF NINETY CASES OF SIMPLE CHRONIC GLAUCOMA.

CASE 1. — James G., aged 52, May 4, 1872. Has had failing vision for several years, beginning in right eye. No pain, other than a dull ache, at any time. Vision at times worse than at others. Has had "rainbow" rings around lights for more than a year. Is subject to chronic muscular rheumatism.

R. E. $\frac{20}{200}$, unimproved; shallow anterior chamber; sluggish iris. T + 1. Deep overhung excavation. Pulsating veins. Field characteristically limited. Refraction hypermetropic. Media clear.

L. E. $\frac{20}{70}$, unimproved. Shallow anterior chamber. Iris about normal. T + 1. Moderate glaucomatous excavation. Field characteristically limited, but less so than in R. E. Refraction compound hypermetropic astigmatism. Media clear.

May 7th, broad iridectomy upwards in both eyes. No incarceration of pillars of coloboma in wound. Free hemorrhage. May 21st, R. E. $\frac{10}{200}$; L. E. $\frac{20}{100}$. All blood absorbed. June 17th, R. E. $\frac{10}{200}$; L. E. $\frac{20}{100}$. No apparent change in fundus. November 20th, R. E. $\frac{6}{200}$; L. E. $\frac{20}{200}$. Field of L. E. more limited. March 3, 1873, R. E. $\frac{4}{200}$; field markedly narrower. L. E. $\frac{20}{200}$, but field more limited. March 17, 1874, R. E. $\frac{1}{200}$; field almost telescopic. L. E. $\frac{10}{200}$, and field decidedly contracted.

CASE 2. — Sarah A. B., aged 49, June 18, 1872. Has had failing vision in both eyes for more than a year, but does not remember which eye became defective first. Has had occasional attacks of pain in both eyes, with rather marked photopsic symptoms. Has never had rheumatism.

R. E. $\frac{20}{200}$, unimproved. Ht. D 1.50. Shallow anterior chamber. T + 1. Glaucomatous excavation with pulsating veins. Field characteristically limited. Media clear.

L. E. $\frac{20}{200}$, unimproved. Ht. D 1.50. Same appearances as in the R. E., and field almost identical. Media clear.

June 20th, iridectomy with lance-knife upwards in both eyes. Very slight hemorrhage in either eye. July 12th, vision same in both eyes as before operation. October 4th, R. E. $\frac{15}{200}$; L. E. $\frac{12}{200}$; field unchanged. April 11, 1873, R. E. $\frac{10}{200}$; L. E. $\frac{10}{200}$; field in both eyes narrowed since operation. March 2, 1874, R. E. $\frac{5}{200}$; L. E. $\frac{5}{200}$; field very small in both eyes.

CASE 3. — Francis L., aged 60, April 16, 1874. Has had failing vision in L. E. for four months, without any pain. Is in good health, and an engineer by profession.

R. E. $\frac{20}{50}$, unimproved. Refraction hypermetropic. Tn. Iris apparently normal. Optic disc red and outlines obscured. No excavation. Very slight concentric limitation of field. Media clear.

L. E. $\frac{20}{200}$, unimproved. T. perhaps slightly increased. Anterior chamber shallow. Iris dilated and immovable. Marked narrowing of field. Deep glaucomatous excavation. Compound hypermetropic astigmatism. Media clear.

April 17th, iridectomy upwards on L. E. with lance-knife, and eserine in R. E. April 29th, iridectomy upwards in R. E. May 20th, R. E. $\frac{20}{50}$; L. E. $\frac{15}{200}$; no apparent change in field. October 11th, R. E. $\frac{20}{50}$; L. E. $\frac{12}{200}$; left field narrowed. May 2, 1875, R. E. $\frac{20}{70}$; L. E. $\frac{6}{200}$; field of both eyes decidedly reduced.

CASE 4. — Ascher A., aged 83, August 24, 1874. Does not know when his sight began to fail. Is feeble and very anæmic.

R. E. perception of light. Large arcus senilis. Iris dilated, atrophied, and immovable. Peripheral opacities in lens. Large annular posterior staphyloma. Patches of choroidal atrophy all over fundus. Refraction myopic D 3. Deep glaucomatous excavation. T + 1.

L. E., V = 0 — T + 2. Glaucoma absolutum with all the symptoms marked.

August 24th, broad iridectomy upwards in R. E. September 20th, R. E. perception of light. December 27th, R. E. percep-

tion of light; cataract much farther advanced. March 5, 1875, R. E. very faint quantitative perception of light. Lens nearly entirely opaque.

CASE 5. — Elizabeth B., aged 65, October 22, 1874. Does not know when her sight began to fail. Is almost a cripple from chronic rheumatic arthritis. Has been blind in the left eye for some months. At times severe pains.

R. E. perception of light. Shallow anterior chamber. Iris dilated and immovable. Engorged and tortuous episcleral veins. Deep glaucomatous excavation with arterial pulsation. Lens cloudy at periphery. Refraction hypermetropic. T + 2.

L. E., V = 0 — T + 2. Lens opaque. Glaucoma absolutum.

October 24th, iridectomy upwards with lance-knife in R. E. November 18th, L. E. perception of light; lens becoming rapidly opaque. February 3, 1875, R. E. no perception of light.

CASE 6. — Conrad W., aged 60, November 9, 1874. Has had failing vision for several years in L. E., and for several months in R. E. Has been totally blind for about six weeks in L. E.

R. E. $\frac{20}{200}$, unimproved. Shallow anterior chamber. Iris dilated and immovable. Lens cloudy at periphery. Refraction hypermetropic. T + 1. Field characteristically limited. Deep excavation.

L. E., V=0. T + 2. Glaucoma absolutum.

November 9th, iridectomy upwards with lance-knife in R. E. November 26th, R. E. $\frac{20}{200}$. December 23d, R. E. $\frac{20}{200}$. February 3d, R. E. $\frac{15}{200}$; limitation of field more marked. May 7th, R. E. $\frac{10}{200}$; limitation of field more marked. October 3d, R. E. movements of hand; field practically unmeasurable.

CASE 7. — Dennis M., aged 52, November 30, 1874. Vision began to fail in R. E. more than two years ago, and recently also in L. E. Has had some pain.

R. E. perception of light. Shallow anterior chamber. Iris dilated and immovable. Lens clear. Refraction compound hypermetropic astigmatism. T + 1. Deep excavation.

L. E. $\frac{20}{50}$, unimproved. T + 1. Refraction hypermetropic. Field concentrically limited. Lens clear. Glaucomatous excavation. Iris movable.

December 2d, broad iridectomy upwards in both eyes with a

lance-knife. January 3d, 1875, R. E. $\frac{5}{70}$; L. E. $\frac{20}{70}$; field in both eyes about the same. May 1st, R. E. $\frac{1}{200}$; L. E. $\frac{20}{100}$; left field narrowed. July 2d, R. E. perception of light; L. E. $\frac{20}{100}$. November 3d, R. E. perception of light; L. E. fingers at 3 feet; field telescopic.

CASE 8. Lavinia V., aged 69, December 10, 1874. Has had failing vision in both eyes for several years, with some pain, and "colored rings" round the lights.

R. E. $\frac{20}{100}$ +; with sph. $+\frac{1}{20} = \frac{20}{40}$ —. Shallow anterior chamber. Peripheral opacities in lens. Movable iris. T + 1. Glaucomatous excavation and limitation of field. Refraction hypermetropic.

L. E. $\frac{20}{70}$, and with sph. $+\frac{1}{24} = \frac{20}{40}$ +. Shallow anterior chamber. Movable iris. Peripheral opacities in lens. Glaucomatous excavation of disc, and limitation of field. T + 1. Refraction hypermetropic.

December 12th, iridectomy upwards in R. E., and eserine sulphate (1 gr. solution) in L. E. December 20th, iridectomy upwards in L. E. February 4, 1875, R. E. $\frac{10}{200}$; L. E. $\frac{20}{100}$; fields unchanged. June 11th, R. E. fingers at 2 feet; L. E. $\frac{10}{200}$; both fields markedly narrowed. March 1, 1876, R. E. perception of light; L. E. movements of hands. Well marked cataract in both eyes.

CASE 9. — Sarah D. H., aged 67, May 28, 1875. Has had failing vision for about two years, especially in L. E. Occasional attacks of pain. Is hypermetropic, and has worn distance glasses for thirty years. Is subject to chronic rheumatic arthritis, and has enlargement of the heart and mitral stenosis.

R. E. $\frac{20}{40}$, unimproved. Sluggish iris. Shallow anterior chamber. Arcus senilis. Cataract (peripheral). No change in disc and no limitation of field. Tn.

L. E. $\frac{20}{70}$, unimproved. Arcus senilis. Sluggish iris. Shallow anterior chamber. Cataract more advanced. No excavation in disc. No limitation of field. Tn.

February 16, 1879, rather persistent pain; limitation of field of vision; V = $\frac{20}{200}$ in both eyes; T +; lens opacities about the same; double iridectomy upwards with lance-knife. February 3, 1884, B. E., V = perception of light (quantitative); no projection; lenses opaque; T + 2; engorged episcleral veins.

CASE 10. — Martha N., aged 56, June 7, 1875. Failing vision in both eyes for nearly three years. No pain at any time. At times sees "colored rings," and everything looks smoky. Refraction hypermetropic. Hebrew.

B. E. $\frac{10}{200}$, unimproved. Shallow anterior chambers. Immovable and dilated iris. Lenses clear. Deep glaucomatous excavation of discs. Marked irregular concentric limitation of the fields. T + 1.

June 12th, iridectomy upwards in both eyes with a lance-knife. September 15th, V = $\frac{5}{200}$ in both eyes; fields telescopic; cataracts well advanced towards maturity in both eyes. February 9, 1876, V = perception of light in both eyes. Mature cataracts.

CASE 11. — Albert G. A., aged 67, September 24, 1875. Has had misty vision for several months. No pain, no photopsia, but all objects have a penumbra.

R. E. $\frac{20}{30}$, unimproved. T + 1. Glaucomatous excavation, and slight narrowing of field. Co. hyp. astigmatism.

L. E. $\frac{25}{50}$, unimproved. T + 1. Deep glaucomatous excavation, and irregular narrowing of field of vision. Co. hyp. astigmatism. Media clear in both eyes.

September 26th, eserine in R. E., and broad iridectomy upwards in L. E. with a lance-knife. October 1st, iridectomy upwards in R. E. November 12th, R. E. $\frac{20}{40}$; L. E. $\frac{20}{70}$. February 1, 1876, R. E. $\frac{20}{50}$; L. E. $\frac{20}{100}$; fields more narrowed. June 3d, R. E. $\frac{20}{100}$; L. E. $\frac{20}{200}$; fields still more narrowed. October 14th, R. E. $\frac{10}{200}$; L. E. $\frac{10}{200}$; fields very narrow.

CASE 12. — Mrs. C. D. W., aged 50, January 25, 1876. Seven years ago had slight right hemiplegia, from which she soon recovered. Shortly after this vision in L. E. began to fail, with occasional dull pain and colored photopsiæ. Eleven months ago had a second attack of total right hemiplegia, with loss of consciousness. From this she slowly recovered, though the loss of sensation has remained. After this the L. E. failed very rapidly, and the R. E. also began to grow dim. Refraction hypermetropic.

R. E. $\frac{20}{40}$, unimproved. Media clear. Movable iris. Slight glaucomatous excavation of disc, and slight limitation of field. T + 1.

L. E. perception of light. Media clear. Deep glaucomatous excavation of disc. Iris dilated and very sluggish. T + 2.

January 28th, eserine in R. E., and broad iridectomy upwards in L. E. with lance knife. February 20th, iridectomy upwards in R. E. March 30th, R. E. $\frac{20}{70}$ +: L. E. perception of light. November 16th, R. E. $\frac{20}{100}$ — L. E. perception of light. Right field decidedly more narrowed.

CASE 13. — Mrs. D. B., aged 49, May 24, 1876. For five months has suffered from severe headache at vertex, and frontal, cervical, and brachial neuralgia. Has had failing vision in R. E. without pain, but with flashes of light and colored rings.

R. E. $\frac{20}{50}$. Movable iris. Media clear. Deep glaucomatous excavation of disc. Hypermetropic, T + 1. Irregular limitation of field of vision.

L. E. $\frac{20}{20}$, apparently normal in every respect. Hypermetropic.

May 27th, eserine solution in L. E., and broad iridectomy upwards in R. E. with lance knife. June 28th, R. E. $\frac{20}{50}$; L. E. $\frac{20}{20}$. November 3d, R. E. $\frac{20}{50}$; L. E. $\frac{20}{20}$. February 12th, 1877, R. E. $\frac{20}{50}$; L. E. $\frac{20}{20}$. June 4th, R. E. $\frac{20}{50}$; L. E. $\frac{20}{20}$. Field of vision somewhat narrower than at time of operation one year ago.

CASE 14. — Mary F., aged 60, August 14, 1876. Has always been very myopic, but has never worn any glasses. Vision began to fail in both eyes about eight months ago, without any pain or any photopsic manifestations.

R. E. $\frac{20}{70}$, with sph. — $\frac{1}{8}$. Large conus of choroidal atrophy on temporal side of disc. Media clear. Deep glaucomatous excavation. T + 2. Paresis of right superior rectus. Concentric limitation of field.

L. E. $\frac{20}{100}$, with sph. — $\frac{1}{16}$. Large posterior staphyloma. Media clear. Deep glaucomatous excavation. Concentric limitation of field. T + 2.

August 26th, broad iridectomy upward in both eyes. Steady failure of vision in both eyes after the second month, and gradual continuous narrowing of the field of vision.

CASE 15. — Hannah U., aged 63, October 2, 1876. Does not know when her vision began to fail, but thinks she has been blind in L. E. for about six months.

R. E. $\frac{20}{200}$. Old corneal macula. Shallow anterior chamber. Dilated iris. T + 1. Glaucomatous excavation of optic disc and marked limitation of field of vision.

L. E. V = 0 — T + 2. Dilated and immovable iris. Glaucomatous atrophy of disc. Absolute glaucoma. Refraction in B. E. Compound hypermetropic astigmatism.

October 2d, broad iridectomy upwards in R. E. Very rapid failure of vision in R. E., so that three weeks after the operation it was reduced to counting fingers close in front of the eye and the reduction of the field to a small telescopic central spot.

CASE 16. Joanna C., aged 60, December 7, 1876. Has no knowledge of when her vision began to fail. A very ignorant and unobservant person.

R. E. $\frac{20}{70}$ + improved. Hypermetropic. Shallow anterior chamber. Movable iris. Clear media. Glaucomatous excavation. T + 1. Limitation of field of vision on nasal side.

L. E. V = 0. Central corneal macula. Iris dilated, immovable and atrophic. T + 2. Deep excavation. Glaucoma absolutum.

December 7th, iridectomy upwards in R. E. Slow, steady failure of vision in spite of the operation, so that in May, 1877, it was reduced to $\frac{10}{200}$, with a corresponding diminution in the diameter of the field.

CASE 17. — Charles D., aged 64, June 6, 1877. Vision began to fail in R. E. three years ago, with occasional slight pain.

R. E. $\frac{20}{100}$ +: Iris movable; media clear. Glaucomatous excavation. Field limited on nasal side. T + 1. Emmetropic.

L. E. $\frac{20}{70}$, with sph. — $\frac{1}{20}$ = $\frac{20}{80}$ +. Media clear. T + 1. Beginning glaucomatous excavation. Field slightly limited. Emmetropic.

June 6th, eserine in L. E., and broad iridectomy upwards in R. E. Vision remained as it was before the operation for three months, and then again began to fail, with sudden flashes of light and attacks of pain. November 3, 1877, R. E. perception of light. T + 2. Very deep glaucomatous excavation and beginning cataract.

L. E. $\frac{20}{200}$, with sph —. $\frac{1}{20}$ = $\frac{20}{50}$. — Media still clear. T + 1. Same day did simultaneous broad iridectomy downwards in R. E.

and upwards in L. E. Arrest of the disease apparently in the L. E. for a period of ten months, with maintenance of limits of the field at the time of operation. Then a slow, steady failure of vision in the L. E.

CASE 18. Sigmund S., aged 50, July 12, 1877. Lost his R. E. from purulent conjunctivitis, probably about 20 years ago. In 1860 or 1861 the L. E. began to fail, and he was told he had glaucoma. An iridectomy was done inwards on L. E. by Von Graefe at that time, and he said that for more than a year afterwards the vision was almost as good as ever. When I saw him in July, 1877, sixteen years afterwards, the condition was as follows: R. E. phthisis bulbi. L. E. $\frac{10}{200}$; clear media. Broad coloboma iridis inwards. Very deep glaucomatous excavation of the disc, with arterial pulsation. Very irregular concentric limitation of field of vision. Hypermetropic. T + 1.

July 14th, iridectomy outwards in L. E. No improvement of vision, but a gradual narrowing of the field and failure of vision, dating from the second operation.

CASE 19. — Thomas B., aged 58, February 28, 1878. Has had failing V. in R. E. for about eight months, without any pain or photopsiae. Center of cornea has the appearance of ground glass. Iris sluggish. Lens clear. T + 1. Glaucomatous excavation of disc. Marked limitation of field of vision. $V = \frac{10}{200}$. Hypermetropic.

L. E. $\frac{20}{20}$ — apparently normal.

March 2d, eserine in L. E., and broad iridectomy upwards with lance knife in R. E. Steady failure of vision in R. E. in spite of the operation. Six months later he could see to count fingers. The L. E. remained intact for 15 months after the operation on the R. E., since which time the patient has not been seen.

CASE 20. — Matilda H., aged 44, May 10, 1878. Symptoms of accommodative asthenopia and hazy vision for about 13 months, with steadily failing vision in both eyes, with slight attacks of pain, flashes of light, and colored rings. Refraction hypermetropic.

R. E. $\frac{20}{100}$ with sph. $+ \frac{1}{20} = \frac{20}{40}$.

L. E. $\frac{10}{200}$: with sph. $+ \frac{1}{61} = \frac{20}{70}$.

T + 1. Shallow anterior chambers, sluggish irides, lenses clear. Deep glaucomatous excavation in both discs, and irregular limitation of field on nasal sides.

May 10th, broad iridectomy upwards in both eyes. Gradual failure of vision and progressive narrowing of the field in both eyes for a period of seven months. Since the last of December, 1878, there was no change in the vision for more than a year. R. E. $\frac{5}{200}$. L. E. counting fingers immediately in front of the eye.

CASE 21. — Herman E., aged 38, May 20, 1878. Three years ago had an attack of total left hemiplegia, with right facial paralysis, from which, however, he entirely recovered. Vision began to fail four months ago in the L. E., and for the last three weeks he has had no perception of light. During the last month the sight of the R. E. has begun to fail.

R. E. $\frac{20}{50}$, unimproved. Shallow anterior chamber. Iris immovable, with dilated and horizontally oval pupil. Media clear. Refraction hypermetropic. Field concentrically narrowed, mainly on nasal side. T + 1. Deep glaucomatous excavation.

L. E. V = 0. Media clear. Iris dilated ad maximum and immovable. Deep glaucomatous excavation and atrophied disc. T + 2. Compound hypermetropic astigmatism.

May 20th, broad iridectomy upwards in both eyes. June 18th, R. E. $\frac{20}{50}$; L. E. 0. July 30th, R. E. $\frac{20}{70}$; L. E. 0. November 2d, R. E. $\frac{20}{200}$. February 4th, 1879, R. E. $\frac{5}{200}$. Very narrow field.

CASE 22.— Henry L. B., aged 33, July 8, 1878. Six years ago he had syphilitic iritis in both eyes, of the ordinary plastic type, from which he recovered completely, with no adhesions. Two years ago vision began to fail in both eyes, and has steadily grown worse.

R. E., fingers at 8 feet. Narrow anterior chamber. Iris dilated and immovable. Media clear. Refraction hypermetropic. Glaucomatous excavation of disc. Field narrowed downwards and inwards mainly. T + 1.

L. E., fingers at 2 feet. Shallow anterior chamber. Iris dilated and immovable. Media clear. Very deep glaucomatous

excavation. Refraction hypermetropic. Very irregular concentric limitation of the field. T + 1.

July 11th, iridectomy upwards in both eyes with a lance-knife. August 7th, R. E. $\frac{5}{100}$; L. E. fingers at 1 foot. October 3d, B. E. movements of hand.

CASE 23.— Mrs. R. L., aged 35, September 10, 1878. Is of a very nervous temperament. Vision began to fail in R. E. about four months ago, with no pain, but with occasional attacks of complete obscuration of vision of transient duration. Has had "flashes of light" and "colored rings" almost from the beginning.

R. E. $\frac{10}{70}$. Shallow anterior chamber. Iris sluggish. Media clear. Refraction hypermetropic. Glaucomatous excavation of disc. Field narrowed downwards and inwards. T + 1.

L. E. $\frac{20}{20}$, apparently normal. September 12th, eserine in L. E., and broad iridectomy upwards in R. E. October 24th, R. E. $\frac{10}{70}$; L. E. $\frac{20}{20}$. November 27th, R. E. $\frac{10}{70}$; L. E. $\frac{20}{20}$. December 28th, R. E. $\frac{10}{100}$; L. E. $\frac{20}{20}$. February 11th, 1879, R. E. $\frac{10}{200}$; L. E. $\frac{20}{20}$.

CASE 24.— Henry K., aged 50, October 14, 1878. Has had failing vision in both eyes for several months, more marked in R. E. Refraction hypermetropic. R. E. $\frac{15}{100}$; with sph. $+ \frac{1}{8} = \frac{20}{50} +$.

L. E. $\frac{20}{100}$; with sph. $+ \frac{1}{9} = \frac{20}{70}$. Shallow anterior chambers. Irides very sluggish. Lenses cloudy at periphery. Glaucomatous cupping of discs. Concentric limitation of fields. T + 1. Declines operation.

December 3, 1878, R. E. about same as at last visit.

L. E. distinguishes movements of hand eccentrically with nasal half of retina. Very deep excavation. T + 2. December 3, 1878, broad iridectomy upwards in both eyes. December 31, 1878, R. E. $\frac{20}{50} +$ with sph. $+ \frac{1}{15}$. L. E. movements of hand.

February 6, 1879, vision same. February 3, 1880, vision same. April 2d, R. E. $\frac{20}{100}$ with $+ \frac{1}{15}$; L. E. movements of hand. May 30th, R. E. $\frac{20}{200}$ with $+ \frac{1}{15}$; L. E. light.

CASE 25.— David H., age 45, October 24, 1878. Has had

failing vision in both eyes for more than a year. No pain, but much troubled with flashes of light. Three days ago the vision suddenly became much worse, so that he could not see to move about. Refraction hypermetropic.

R. E. fingers at 6 inches; hazy cornea. Very shallow chamber. Iris dilated and immovable. Deep cupping of disc. T + 2. Field telescopic. No enlarged episcleral veins. Lens clear.

L. E. fingers at 2 inches. Condition rather worse than in the fellow eye, but no enlarged episcleral vessels. Lens clear.

October 24th, iridectomy upwards in both eyes. November 30th, R. E. $\frac{15}{200}$; L. E. $\frac{5}{200}$. But no change in visual fields. Vision remained slightly improved until February, 1879, when it began again to diminish, and steadily failed as long as he was under observation, a period of more than a year. There was never any change in the telescopic field, either for better or worse. The case ended in slow atrophy of the optic nerve fibers.

CASE 26.— John F., aged 72, Nov. 10, 1879. Vision began to fail one year ago in both eyes. No pain nor any signs of inflammation at any time.

B. E. perception of light. Irides dilated and immovable. Cornea clear, but lenses cloudy at periphery. Refraction emmetropic. Deep cupping of both discs. T + 2.

November 12th, iridectomy upwards in both eyes. No improvement in either eye, and steady increase in the lenticular opacity.

CASE 27.— Theresa R., aged 64, March 1, 1880. Has had defective vision in the L. E. for an indefinite period, but it has become much worse of late. Vision began to fail in the R. E. about three weeks ago.

R. E. $\frac{20}{70}$ + unimproved. Shallow anterior chamber. Iris dilated and very sluggish. Media clear. Refraction hypermetropic. Cupping of disc. T + 1. Field narrowed on nasal side.

L. E. $\frac{20}{200}$, unimproved. Iris dilated and sluggish. Media clear. Refraction hypermetropic. Glaucomatous excavation. Concentric limitation of field. T + 1.

March 3d, iridectomy upwards in both eyes. Vision in R. E. was somewhat improved at first, but within a month again sank to $\frac{20}{70}$ +, where it remained for a long time. This patient was seen as late as the spring of 1884, and the R. E. then saw $\frac{20}{70}$. Vision in the L. E. steadily grew worse after the operation, and at the date of the last visit there was merely perception of light. The field of R. E. became slightly narrower immediately after the operation, and then remained unchanged.

CASE 28.— Mrs. Eliza A. S., aged 70, March 15, 1880. Vision began to fail about a year ago in R. E., and shortly afterwards in L. E. Has had considerable pain at intervals in both eyes.

R. E. perception of light. Shallow anterior chamber. Iris dilated and immovable. Media clear, except at periphery of lens. Refraction hypermetropic. Deep excavation of disc. T + 1.

L. E. $\frac{10}{200}$, same conditions as in R. E. Marked narrowing of field. T + 1.

March 15th, iridectomy upwards in both eyes. Steady failure of vision in both eyes in spite of the operation. Within three months there was no perception of light in the R. E., and vision in the L. E. had sunk to $\frac{5}{200}$, with a telescopic field.

CASE 29.— Mrs. Sarah W., aged 59, August 9, 1880. Vision began to fail in R. E. two years ago, and in three months she became totally blind. Four months ago R. E. became inflamed and very painful. The L. E. began to fail about one month ago.

R. E. V. = 0. No anterior chamber. Cataract. Injected episcleral vessels. Great pain. T + 3.

L. E. $\frac{20}{40}$ —. Shallow chamber. Iris very sluggish. Slight opacities at periphery of lens. Refraction hypermetropic. Glaucomatous excavation of disc. Concentric limitation of field. T + 1.

August 16th, iridectomy upwards in both eyes, and extraction of cataract in the R. E.

October 28th, R. E. V. = 0. All signs of inflammation have subsided. Wound ectatic. L. E. $\frac{20}{30}$ —. January 5, 1881, L. E. $\frac{20}{40}$ —. Field slightly narrower on nasal side.

The patient was seen last in October, 1882, when the L. E. had vision of $\frac{20}{50}$ +, and the field was practically unchanged from its condition two years before.

CASE 30.—Miss Laura T., aged 24, Sept. 20, 1880. Has always been myopic, but has never worn glasses. When a child had a severe inflammation of the L. E. of an ulcerative character, which practically rendered the eye useless. About four months ago the vision began to fail in R. E. and has slowly grown worse, with no pain unless after reading.

R. E. $\frac{10}{200}$; with sph. $-\frac{1}{8}$ ($-$ D 6.50) $= \frac{20}{40}$. Iris dilated. Media clear. Glaucomatous cupping of disc. Field concentrically and irregularly limited. T + 1.

L. E. movements of the hand. Broad leucoma adhaerens. Tn. No signs of irritation.

September 25th, broad iridectomy upwards in both eyes. October 11th, R. E. with sph. $-\frac{1}{8} = \frac{20}{30}$. Field somewhat increased in diameter. February 3, 1881, R. E. with sph. $-\frac{1}{8}$ $= \frac{20}{30}$ —.

This patient was last seen in the autumn of 1883, and the R. E. then had vision of $\frac{20}{40}$, with a field in about the same condition as it was when first examined.

CASE 31.—Mrs. S., aged 33, Hebrew, first seen Oct. 14, 1880. She has had symptoms of asthenopia for four years, with pain, blurred vision, nausea, vertigo, and headache, on any attempt to use her eyes. She saw Liebreich in London, who prescribed prisms, which intensified the symptoms.

R. E. $\frac{20}{15}$ —; rejects all glasses. Reads Jaeger 1 from 6″ to 24″.

L. E. $\frac{20}{15}$ —, same result. After atropia in both eyes. B. E. $\frac{20}{40}$ +, and with cyl. + D 1 axis 90° $= \frac{20}{20}$ +. In the autumn of 1887, there were occasional attacks of blurred vision, "colored rings," some pain, and marked diminution of accommodation, with concentric narrowing of the field in B. E., and an operation was urged as the only safeguard. Eserine had been used for several months, but without much benefit.

December 16, 1887, iridectomy upwards in R. E. February 13, 1888, iridectomy upwards in L. E. Since the last operation

all unpleasant symptoms have vanished. February 14, 1889, R. E. $\frac{20}{20}$ + with cyl. + Do — 50 axis 30°. L. E. $\frac{20}{20}$ with cyl. + Do 75 axis 150°. Field of vision in each eye nearly normal.

CASE 32.— Mr. G. W., aged 62, November 22, 1880. Vision began to fail in L. E. four years ago, and in the R. E. one year ago. No pain at any time. L. E. has been blind for a year.

R. E. $\frac{20}{40}$ —, unimproved. Chamber and iris about normal. Media clear. Refraction hypermetropic. Field narrowed on nasal side. Slight overhung cupping of disc. T + 1.

L. E. V. = 0, cornea hazy. Iris atrophied, dilated, and immovable. Deep glaucomatous cupping of disc. T + 2.

November 24th, broad iridectomy upwards in R. E.

This patient has been seen at intervals of three or four months ever since, the last time in March, 1889. For more than five years the vision in the R. E. remained at $\frac{20}{40}$ +. Since then vision has slowly failed owing to the development of a cataract, which has been very slow in its growth, and is not yet mature enough to warrant its removal.

CASE 33.— Michael D., aged 60, February 7, 1881. Does not know when his vision began to fail. No pain or discomfort at any time, except sudden flashes of light which always came on at night.

R. E. $\frac{20}{200}$; with sph. + D 3 = $\frac{20}{40}$. Shallow chamber. Iris dilated and sluggish. Media clear. Cupping of disc. Irregular narrowing of field. T + 1.

L. E. perception of light. Very shallow chamber. Lens cloudy at periphery. Deep glaucomatous excavation. Atrophic disc. T + 2.

February 9th, iridectomy upwards in both eyes. March 3d, R. E. $\frac{20}{50}$, with + D 3. L. E. light. There was a slow but steady diminution of vision in R. E. after the operation until November, at which time V = $\frac{4}{200}$. This was accompanied by a continuous narrowing of the field.

CASE 34.—James S., aged 60, May 20, 1881. Vision began to fail in L. E. seven years ago, and in R. E. one year ago. Has had no pain of any account at any time. Has always been myopic.

R. E. $\frac{20}{200}$; with sph. — D 4 = $\frac{20}{70}$. Media clear, except at periphery of lens. Iris dilated and immovable. Deep glaucomatous excavation of disc. Field markedly narrowed. T + 1.

L. E. perception of light. Almost no anterior chamber. Cataract. T + 1.

May 26th, iridectomy upwards in both eyes. There was a steady failure of vision in the R. E. following the operation, though the process was slow. As late as the last of April, 1882, he could still see $\frac{10}{200}$, but the field became narrow, and the lens became more opaque.

CASE 35. — Mr. David U., aged 80, February 2, 1882. Has had failing vision in both eyes for six years, but during the last three months the loss has been very rapid. Occasional slight pain. Has chronic bronchitis and paralysis agitans.

R. E. $\frac{6}{200}$; L. E. $\frac{12}{200}$. Some engorgement of episcleral vessels. Irides dilated and immovable. Lenses cloudy at periphery. Deep glaucomatous excavation of both discs. Very marked narrowing of the fields. T + 1. Hypermetropic.

February 11th, broad iridectomy upwards in both eyes. Rapid failure of vision following the operation in both eyes, especially in the R. E., so that on May 2d there was only perception of light in both eyes.

CASE 36. — Mr. Frederick S., aged 58, April 10, 1882. Failing vision in R. E. for more than a year, and in L. E. for two months. No pain at any time. Is hypermetropic and astigmatic, and has worn distance glasses for nearly 30 years.

R. E. perception of light. No anterior chamber. Iris dilated and immovable. Media clear. Deep cupping of disc. T + 1.

L. E. $\frac{20}{50}$. Shallow anterior chamber. Media clear. Iris sluggish. Cupping of disc. Concentric limitation of field. T + 1. April 12th, broad iridectomy upwards in both eyes. May 30th, R. E. fingers eccentrically at 8 inches; L. E. $\frac{20}{80}$. October 7th, R. E. perception of light; L. E. $\frac{20}{70}$. January 15, 1883, R. E. light; L. E. $\frac{20}{100}$.

CASE 37. — Mrs. A. V., aged 58, May 8, 1882. No definite history of when the vision began to fail. Is a great sufferer from chronic rheumatic arthritis, and has both hypertrophy and

valvular disease of the heart. Refraction hypermetropic. Has had some dull pain in the eyes at times.

R. E. $\frac{20}{70}$. Ht. D 1.50. Shallow chamber. Media clear. Excavation of disc. Limitation of field on nasal side. T + 1.

L. E. $\frac{20}{70}$. Much the same condition.

May 14th, iridectomy upwards in both eyes. June 15th, R. E. $\frac{20}{30}$; with sph. + D 1: L. E. $\frac{20}{30}$; with sph. + D 1. November 8th, R. E. $\frac{20}{30}$; with sph. + D 1; L. E. $\frac{20}{30}$; with sph. + D 1. February 2, 1883, V. same as at last visit in both eyes. May 26th, V. same; fields remained unchanged.

CASE 38. — Patrick Q., aged 40, September 3, 1882. Failing vision for six months in both eyes. No pain at any time. Both eyes V = $\frac{5}{200}$. Shallow anterior chambers. Iris dilated and immovable. Slight haziness of cornea. Lenses clear. Deep excavations of both discs. Fields cannot be tested. T + 1. Hypermetropic.

October 2d, iridectomy upwards in both eyes. Slow but steady failure of vision in both eyes in spite of the operation. March 16th, V = perception of light in both eyes.

CASE 39. — Mrs. R., aged 43, September 6, 1882. When a child had an inflammation of the R. E. which destroyed the sight. Has had failing vision in L. E. for about three months, with occasional attacks of pain.

R. E. fingers at 6 inches. Central corneal leucoma. Iris dilated and immovable. T + 2, but no pain.

L. E. $\frac{20}{40}$ +. Refraction hypermetropic. Shallow chamber. Media clear Excavation of disc. Field slightly narrowed on nasal side. T + 1.

September 9th, iridectomy upwards in both eyes. Vision in R. E. became rapidly worse, so that within a month there was only perception of light. In the L. E. the vision remained at $\frac{20}{40}$ until November 14, 1883, since which time the patient has not been seen.

CASE 40. — Mr. C. C N., aged 27, September 29, 1882. Has had failing vision in L. E. for several years, with flashes of light, colored rings, and occasional attacks of pain.

Both eyes, V = $\frac{20}{200}$. Refraction hypermetropic. Media

clear. Irides dilated. Deep glaucomatous excavation of both discs, with arterial pulsation. Fields narrowed concentrically, especially below. T + 1.

October 4th, iridectomy upwards in both eyes. Slow but steady deterioration of vision in both eyes, as tested from month to month, until April, 1883, at which time it was $\frac{10}{200}$, since which time the patient has not been seen.

CASE 41.—Henry H., aged 54, October 2, 1882. Has had failing vision in both eyes for about eight months, with some dull pain.

R. E. $\frac{10}{200}$. L. E. $\frac{20}{200}$. Shallow anterior chambers. Dilated and sluggish irides. Media clear. Refraction hypermetropic. Deep glaucomatous excavation in both discs. Concentric but irregular narrowing of fields. T + 1. Symptoms all more marked in R. E.

October 4th, iridectomy upwards in both eyes. December 29th, R. E. $\frac{20}{200}$; L. E. $\frac{20}{70}$. Early in January, 1883, vision began again to fail in both eyes, and steadily grew worse until June, 1883, when it was R. E. $\frac{5}{200}$; L. E. $\frac{10}{200}$. Since then the patient has not presented himself. The limitation of the fields was also slowly progressive.

CASE 42.—Thomas F., aged 80, December 11, 1882. Vision began to fail in L. E. about five years ago, and for more than a year this eye has been entirely blind. R. E. began to fail about two years ago. No pain, but has had flashes of light and colored rings.

R. E. perception of light. No anterior chamber. Dilated and immovable iris. Lens cloudy at periphery. Refraction hypermetropic. Glaucomatous cupping of disc. T + 1.

L. E., V = 0. Glaucoma absolutum. Cataract. T + 2.

December 11th, broad iridectomy upwards in R. E. Vision rather rapidly diminished in R. E. following the operation, so that by the end of January there was no perception of light.

CASE 43.—Mrs. M. S., aged 62, April 2, 1883. Failing vision in both eyes for more than a year, with occasional sharp pain, transient in character, and occasional onsets of obscuration of entire field.

R. E. fingers at one foot. Very shallow anterior chamber. Iris dilated and sluggish. Media clear. Deep excavation of disc. Field telescopic. T + 1. Hypermetropic astigmatism.

L. E. perception of light. Very shallow anterior chamber. Dilated and immovable iris. Lens cloudy at periphery. Deep glaucomatous excavation. Projection faulty. T + 2. Hypermetropic astigmatism.

April 4th, broad iridectomy upwards in both eyes; considerable hemorrhage after iridectomy in L. E. April 20th, blood all absorbed from anterior chamber of L. E.; ophthalmoscope shows hemorrhages, linear and flame-like in retina and on disc. R. E. fingers; L. E. light. June 20th, V = 0.

CASE 44. — Mr. P. M., aged 56, October 1, 1883. Failing vision in both eyes for three months, beginning in R. E. No pain.

R. E. $\frac{10}{200}$. Shallow anterior chamber. Iris dilated and immovable. Media clear. Deep glaucomatous excavation. Very narrow field. Pulsating arteries. T + 2. Refraction hypermetropic.

L. E. $\frac{20}{30}$. Shallow chamber. Movable iris. Media clear. Shallow excavation. Field narrowed on nasal side. T + 1.

October 2d, eserine in L. E., and iridectomy upwards in R. E. October 21st, iridectomy upwards in L. E. Steady failure of vision in R. E. to faint perception of light within three months from the date of the operation. In the L. E., V. remained at $\frac{20}{40}$ for fourteen months, since which time I have not seen the patient.

CASE 45. — Mrs. D. B. W., aged 45, first seen May 19, 1882. Then had simple hypermetropic astigmatism, with normal vision. Transient obscurations of vision at menstrual epoch, with no change in fundus or field. In October, 1882, began to have marked prodromal symptoms in R. E., for which eserine was used, and an operation advised. Remained about the same till February 15, 1884, when field was found slightly limited. T+1. Some pain. Again declined an operation. October 29, 1884, had marked failure of vision and narrowing of field in R. E. Vision slowly failed, and the field became more and more contracted till January 18, 1886. The R. E. $\frac{10}{200}$, with marked

narrowing of field, and some loss of power in the L. E. January 18, 1886, eserine in L. E., and broad iridectomy upwards in R. E. The same night marked prodromal symptoms in L. E., controlled by eserine. Since then there has been a steady loss of vision and narrowing of field in R. E., and occasional prodromal symptoms in L. E. April 18, 1889, R. E. $\frac{2}{100}$ eccentrically, and a very narrow field. Disc atrophic. Excavation gone. L. E. $\frac{20}{30}+$ with cyl. + D 1 axis 150°, and a normal field. Changes in the choroid in equatorial region and floating particles in vitreous.

CASE 46. — Mr. J. M., aged 63, April 14, 1884. Failing vision in both eyes for six months. No pain. Refraction myopic.

R. E. $\frac{20}{70}-$; with sph. — D 0.75 = $\frac{20}{30}$. Media clear. Movable iris. Excavation of optic disc. Field very slightly contracted. T + 1.

L. E. $\frac{20}{70}-$; with sph. — D 1 = $\frac{20}{50}$. Media clear. Movable iris. Glaucomatous cupping of disc. Decided narrowing of field. T + 1.

April 20th, eserine in R. E., and iridectomy upwards in L. E. May 2d, iridectomy upwards in R. E. Slowly progressive failure of vision and narrowing of field until November 20th, since which time the patient has not been seen. Last examination showed R. E. $\frac{20}{100}$; L. E. $\frac{10}{200}$.

CASE 47. — Mrs. C. M., aged 64, May 5, 1884. Can give no accurate history of her trouble. Duration unknown. No pain. Patient very unobservant. Has been blind in L. E. for at least a year. Refraction hypermetropic.

R. E. movements of hand. No anterior chamber. Lens cloudy at periphery. Very deep excavation of disc. T + 1.

L. E. V = 0. No anterior chamber. Iris dilated and immovable. Cataract. T + 2.

May 5th, broad iridectomy upwards in R. E. October 4th, R. E. 0.

CASE 48. — Mrs. B. F., aged 55, October 13, 1884. Lost her L. E. by some inflammatory process about 10 years ago, proba-

bly a corneal ulcer, which perforated. Vision of R. E. began to fail four months ago.

R. E. perception of light. Shallow anterior chamber. Media clear. Iris dilated and immovable. Deep glaucomatous cupping of disc. T + 2. Hypermetropic.

L. E., V = 0. Large central leucoma adhærens. Capsulo-lenticular cataract. Tn.

October 13th, broad iridectomy upwards in R. E. March 6th, R. E. = 0.

CASE 49. — Mr. J. M., aged 52, October 24, 1884. Has had some failure in vision of both eyes for several months. For the past four weeks has been annoyed by flashes of light and "colored rings," and some pain. Is markedly gouty. Refraction hypermetropic.

R. E. $\frac{20}{200}$: with sph. + D 1.50 = $\frac{20}{50}$. Shallow anterior chamber. Sluggish iris. Media clear. Glaucomatous cupping. Very narrow field. T + 1. Arterial pulsation.

L. $\frac{20}{40}$: with sph. + D 1 = $\frac{20}{30}$. Sluggish iris. Media clear. Slight cupping of disc and slight narrowing of field. T + 1.

October 26th, broad iridectomy upwards in both eyes. Slow diminution of vision and narrowing of the field in both eyes as long as the patient was under observation, a period of seven months. R. E. $\frac{20}{200}$; L. E. $\frac{20}{100}$.

CASE 50. — Mrs. R. C., aged 44, December 1, 1884. Failing vision in R. E. for fourteen months, and in L. E. for five months. No pain.

R. E. perception of light; L. E. $\frac{20}{200}$. Refraction hypermetropic. Shallow anterior chamber. Sluggish irides. Media clear. Deep glaucomatous excavation in both discs, and right disc decidedly atrophic. Concentric limitation of field in L. E. T + 1.

December 3d, broad iridectomy upwards in both eyes. No change in vision of R. E. Slow deterioration of vision in L. E. with progressive narrowing of the field. May 11th, 1885. R. E. light; L. E. $\frac{5}{200}$.

CASE 51. — Miss S. L., aged 61, December 1, 1884. Failing vision in both eyes for two years. Is very gouty.

R. E. $\frac{3}{100}$; L. E. $\frac{15}{200}$. Refraction hypermetropic. Shallow anterior chamber. Irides dilated and immovable. Lenses cloudy at periphery. Deep cupping of both discs. Very narrow fields. T + 1.

December 3d, iridectomy upwards in R. E. December 12th, iridectomy upwards in L. E. December 26th, R. E. $\frac{10}{200}$. Iris adherent to lens. L. E. fingers at 1 foot. Iris adherent to lens. Opacity of latter more marked. March 28th, R. E. $\frac{5}{200}$. Cataract. L. E. movements of hand.

CASE 52 —M. F., aged 69, January 4, 1885. Failing vision in both eyes for more than a year, with occasional attacks of pain. Shallow anterior chambers; irides dilated and sluggish. Media clear. Deep excavation in both discs. Very narrow fields. T + 1. All symptoms more marked in L. E.

R. E. $\frac{20}{100}$; L. E. $\frac{1}{200}$. Refraction hypermetropic and astigmatic.

January 11th, iridectomy upwards in both eyes. Steady loss of vision in both eyes; rather rapid in L. E. May 6th, R. E. $\frac{10}{200}$; L. E. light.

CASE 53.—Mrs. C. K., aged 54, February 22, 1885. Failing vision in both eyes for several years, with occasional attacks of pain. Shallow anterior chambers. Irides very sluggish. Media clear. Refraction hypermetropic. Deep cupping of both discs. Very narrow fields. T + 1.

R. E. fingers at 8 feet. L. E. $\frac{3}{100}$.

February 24th, iridectomy upwards in both eyes. March 20th, R. E. movements of hand. L. E. $\frac{1}{200}$, eccentrically.

CASE 54.—Mr. F. E. W., aged 60, March 9, 1885. Failing vision in both eyes for two years. No pain. Marked photopsiæ.

R. E. $\frac{20}{200}$. All symptoms of glaucoma very marked. T + 2.

L. E. $\frac{20}{50}$. Very deep glaucomatous cupping of discs. Refraction. Compound hypermetropic astigmatism. T + 1.

March 9th, broad iridectomy upwards in both eyes. Very slow deterioration both of vision and field in both eyes. March 3, 1887, R. E. $\frac{8}{200}$; L. E. $\frac{20}{70}$ +. Cupping of discs has disappeared, but fields remain as they were before the operation.

CASE 55.—Mr. J. P., aged 69, March 31, 1885. Failing vision in L. E. for four years and in R. E. for a year. Refraction myopic. Patient is very gouty.

R. E. $\frac{8}{200}$: with sph.—D 2 = $\frac{20}{70}$. Media clear. Cupping of disc. Field narrowed. T + 1.

L. E. $\frac{4}{200}$: with sph.—D 2 = $\frac{20}{100}$. Media clear. Deep cupping of disc. Field very narrow. T + 1.

April 9th, iridectomy upwards in both eyes. June 9th, L. E. $\frac{20}{60}$ with sph.—D 2; R. E. $\frac{20}{70}$. October 4th, L. E. $\frac{20}{100}$ with sph.—D 2; R. E. $\frac{20}{100}$ +. December 6th, L. E. $\frac{20}{200}$ with sph.—D 2; R. E. $\frac{20}{100}$. April 4th, L. E. $\frac{20}{200}$; R. E. $\frac{20}{100}$.

CASE 56.—Mrs. H. R., aged 60, April 6, 1885. Failing vision in L. E. for five years, and in R. E. for a few months. Compound hypermetropic astigmatism.

R. E. $\frac{20}{70}$; shallow anterior chamber. Sluggish iris. Media clear. Disc excavated. Very narrow field. T + 1.

L. E., V = 0. Iris dilated and immovable. Media clear. Disc excavated and atrophic. T + 1.

April 8th, iridectomy upwards in R. E. May 1st, R. E. $\frac{20}{100}$. June 6th, R. E $\frac{20}{200}$. October 10th, R. E. $\frac{10}{200}$.

CASE 57.—Mr. W. M., aged 54, Hebrew, Sept. 12, 1885. Vision began to fail in L. E. seven years ago, and in R. E. one year ago. L. E. has been blind for five years. Refraction hypermetropic.

R. E. $\frac{20}{100}$. Deep cupping of disc, and very narrow field. T + 1.

L. E., V = 0. Glaucoma absolutum and cataract. T + 2.

September 12th, iridectomy upwards in R. E. October 11th, R. E. $\frac{20}{100}$—. November 8th, R. E. $\frac{20}{200}$. Jan. 13, 1886, R. E. $\frac{10}{200}$.

CASE 58.—Mr. J. B., aged 59, Hebrew, Oct. 5, 1885. Vision was lost in R. E. one year ago quite suddenly, within a few days, and since then the vision of the L. E. has also failed, notably within the last three weeks. Refraction hypermetropic. He had no pain in the L. E.

R. E., V = 0. Glaucoma absolutum. Cataract. T + 2. No pain.

L. E. fingers at 8 inches. Deep excavation. Arterial pulsation. T + 1. Media clear.

October 10th, iridectomy upwards in L. E. October 28th, L. E. $\frac{10}{200}$. December 2d, L. E. $\frac{1}{200}$. February 14, 1886, L. E. light.

CASE 59.—Miss M. N., aged 67, October 5, 1885. Vision began to fail in L. E. 14 years ago, and very recently in R. E. also. No pain at any time.

R. E. $\frac{20}{40}$. Refraction hypermetropic. Slight cupping of disc and narrowing of field. T + 1. Media clear.

L. E., V = 0. Glaucoma absolutum. Divergent squint. T + 2. Cataract.

October 11th, iridectomy upwards in R. E. November 4th, R. E. $\frac{20}{50}$. Jan. 31, 1886, R. E. $\frac{20}{100}$ +. May 9th, R. E. $\frac{20}{200}$. October 14th, R. E. $\frac{18}{200}$.

CASE 60.—Mrs. Pauline B., aged 60, Oct. 19, 1885. Failing vision in L. E. for four years. Occasional pain. Two weeks ago had very severe pain in L. E., and sudden and marked diminution of vision. R. E. has been failing for several months. Refraction hypermetropic.

R. E. $\frac{20}{50}$—. Glaucomatous cupping of disc. T + 1.

L. E. perception of light. Iris dilated and immovable. Media clear. Very deep excavation of disc and atrophy. T + 2.

October 21st, eserine in R. E., and broad iridectomy upwards in L. E. November 12th, iridectomy upwards in R. E.

No change in L. E, but steady failure of vision and narrowing of field in R. E. till February, 1886, when V. was reduced to $\frac{15}{200}$.

CASE 61.—Mrs. E. B., aged 48, Oct. 19, 1885. Has had failing vision for six years in both eyes. Occasional pain and sudden flashes of light. At times vision seems to remain at a standstill. Refraction hypermetropic.

R. E. $\frac{20}{70}$; L. E. $\frac{20}{200}$. All the usual signs of simple glaucoma, more marked in the left eye, with cloudy lens and very narrow field. T + 1.

October 21st, iridectomy upwards in L. E., and eserine in R. E. November 17th, iridectomy upwards in R. E.

Steady failure of vision in both eyes, and narrowing of the field during the whole time the patient was under observation, a period of somewhat more than a year. At the date of the last examination in November, 1886, R. E. $\frac{20}{200}$; L. E. $\frac{8}{200}$.

CASE 62 — Miss F. B., aged 34, October 19, 1885. Has had failing vision in both eyes for several years.

R. E. $\frac{20}{70}$; L. E $\frac{20}{70}$. Refraction hypermetropic. Usual signs of chronic glaucoma simplex. T + 1. Lenses clear.

October 23d, iridectomy upwards in R. E. and eserine in L. E. December 3d, R. E. $\frac{20}{70}$; L. E. $\frac{20}{70}$. March 15, 1886, R. E. $\frac{20}{70}$; L. E $\frac{20}{70}$. May 10th, R. E. $\frac{20}{70}$; L. E. $\frac{20}{100}$. May 12th, iridectomy upwards in L. E. October 7th, R. E. $\frac{20}{70}$; L. E. $\frac{20}{100}$. October 4, 1887, R. E. $\frac{20}{70}$; L. E. $\frac{20}{100}$.

CASE 63. — Mr. J. J., aged 62, Hebrew, November 20, 1885. Failing vision in R. E. for ten years, and in L. E. for about a year.

R. E., V = 0. Glaucoma absolutum. Cataract. T + 2.

L. E. perception of light. Very deep cupping of disc. Lens cloudy at periphery. Arterial pulsation. Hypermetropic astigmatism. T + 1.

November 20th, broad iridectomy upwards in L. E. December 3d, L. E. = 0.

CASE 64. — Mr. J. K., aged 33, Hebrew, December 7, 1885. Failing vision in R. E. for sixteen months, and in L. E. for four months. No pain.

R. E., V = 0. Glaucoma absolutum. Cataract. Posterior synechiae. Divergent squint. T + 2.

L. E. $\frac{5}{100}$. Clear media. Deep cupping of optic disc. Excessively narrow field. T + 1. Compound hypermetropic astigmatism.

December 11th, broad iridectomy upwards in L. E. Steady failure of vision in L. E. up to date of last visit, March 11, 1886, when L. E. = counting fingers at 6 inches.

CASE 65. — Mr. M. F., aged 62. First seen in November, 1882. Then had annoying asthenopia, with slight myopic astigmatism in both eyes, and vision slightly below normal. Deep physiological excavation in both discs. No narrowing of fields.

The eyes remained about the same till December 8, 1885, when both fields were slightly narrowed, T + 1, and a well marked glaucomatous excavation existed in both discs. R. E. $\frac{20}{30}$ with cyl. — D 1 ax. 90°. L. E. $\frac{20}{40}$ + with cyl. — D 1.50 ax. 90°.

December 9, 1885, broad iridectomy upwards in both eyes. Since the field of vision in each eye has slowly grown more limited, the left being the worse, but the vision has deteriorated but little since the operation.

December 19, 1888, three years after the operation, R. E. $\frac{20}{50}$ —; with cyl. — D 1 ax. 90° = $\frac{20}{30}$ —. L. E. $\frac{20}{50}$ —; with cyl. — D 1.50 ax. 90° = $\frac{20}{30}$ —.

CASE 66. — Miss C. S., aged 67, December 28, 1885. Failing vision in R. E. for five years, and in L. E. for nearly four years. No pain.

Both eyes, perception of light. Clear media. Very deep excavation in both discs. T + 1.

January 3, 1886, iridectomy upwards in both eyes. May 30th, V = 0 in both eyes.

CASE 67. — Mr. P. B., aged 73, April 3, 1886. Failing vision in both eyes for four months, probably longer. Most marked in L. E. No pain. Refraction hypermetropic.

R. E. $\frac{20}{100}$. Lens cloudy at periphery. Deep excavation of disc with arterial pulsation. Field decidedly narrowed. T + 1.

L. E. $\frac{5}{100}$. Lens cloudy. All the symptoms more marked. T + 2.

April 8th, iridectomy upwards in both eyes; since the operation steady failure of vision and progressive narrowing of field; profuse hemorrhage at time of operation. November 4th, R. E. $\frac{12}{200}$; L. E. $\frac{3}{100}$ eccentrically; cupping very much shallower. February 2, 1887, R. E. $\frac{1}{200}$; L. E. fingers at 6 inches.

CASE 68. — Mr. H. R., aged 45, Hebrew, November 8, 1886. Failing vision in L. E. for a year, and in the R. E. for several months. No pain. Refraction hypermetropic.

R. E. $\frac{20}{50}$. Media clear. Beginning glaucomatous cupping of disc. T + 1. Concentric narrowing of field.

L. E. fingers at 2 feet. Media clear. Deep glaucomatous cupping of disc. T + 2.

November 10th, broad iridectomy upwards in both eyes. The L. E. became rapidly worse after the operation, but the R. E. retained vision of $\frac{20}{50}$ till December of the year 1887, since which time the patient has not been seen.

CASE 69. — Mrs. J. H., aged 50, February 7, 1887. Failing vision in R. E. for several years, and total blindness for the past two weeks. Failing vision in L. E. for several months. Occasional attacks of pain.

R. E., V = 0. Glaucoma absolutum. Cataract. T + 2.

L. E. $\frac{20}{70}$. Deep cupping of disc. Media clear. T + 1. Decided irregular narrowing of field. Hypermetropic astigmatism.

February 16th, broad iridectomy upwards in L. E. Slow deterioration of vision and progressive narrowing of the field of L. E. Was last seen in April, 1888, when the examination showed in L. E. $\frac{10}{200}$.

CASE 70. — Mrs. J. H., aged 50, February 7, 1887. Failing vision in R. E. for several years, and has been entirely blind in this eye for two weeks. The L. E. has failed for nearly a year.

R. E., V = 0. T + 2. No anterior chamber. Lens cloudy at periphery. Very deep glaucomatous excavation and atrophic disc.

L. E. $\frac{20}{70}$. Refraction hypermetropic. Shallow anterior chamber. Media clear. Excavation of disc and narrowing of field. Tn.

February 16th, iridectomy upwards in both eyes. Iris rotten in both eyes. No improvement in R. E.; slight temporary improvement in L. E., lasting for nearly three months. This was followed, however, by a slow deterioration of vision, extending over a period of eight months (L. E $\frac{10}{200}$), since which time the patient has not been seen.

CASE 71. — Louis J. L., aged 65, Hebrew, March 14, 1887. Failing vision in R. E. for two years, and in L. E. for a year. Refraction hypermetropic.

R. E. perception of light. T + 1. Very shallow anterior chamber. Media clear. Deep excavation.

L. E. $\frac{20}{100}$; with sph. + D 2 = $\frac{20}{50}$. Usual signs of glaucoma

simplex, with concentric narrowing of field. T + 1. Lens clear.

March 14th, iridectomy upwards in both eyes. April 22d, R. E., V = 0; L. E with + D 2.50 = $\frac{20}{40}$ —. May 20th, same. October 3d, L. E. $\frac{20}{50}$; with + D 2.50. January 4, 1888, L. E. $\frac{20}{50}$; with + D 2.50. April 30th, L. E. $\frac{20}{50}$; no change of field.

CASE 72. — Michael H., aged 65, May 16, 1887. Failing vision in both eyes for several years. No pain. Refraction hypermetropic and astigmatic.

R. E. perception of light. Media clear. Deep cupping and atrophy of disc. T + 1.

L. E. fingers at one foot. Media clear. Deep cupping of disc. Field telescopic. T + 1.

May 18th, iridectomy upwards in both eyes; steady failure of vision in both eyes. October 3d, R. E. 0; L. E. perception of light.

CASE 73. — Mr. F. B., aged 47, May 23, 1887. Lost the sight of the R. E. by a pistol-shot wound twenty-three years ago. Has never had any trouble with it since. Vision in the L. E. has steadily failed during the past year, without any pain or signs of irritation.

R. E., V = 0. Phthisis bulbi.

L. E. $\frac{20}{200}$. Refraction hypermetropic. Media clear. Glaucomatous excavation of disc. Concentric narrowing of field. T + 1.

May 25th, enucleation of R. E. May 31st, iridectomy upwards in L. E. June 28th, L. E. $\frac{20}{70}$. October 11th, L. E. $\frac{20}{70}$; no change in field. March 7, 1888, L. E. $\frac{20}{70}$. June 10th, L. E. $\frac{20}{70}$.

CASE 74. — Mr. J. S., aged 56, Hebrew, September 26, 1887. Has had failing vision for two years in both eyes. No pain.

R. E. $\frac{20}{50}$. L. E. $\frac{20}{70}$ +. Refraction hypermetropic. Media clear. Both discs deeply cupped, and fields concentrically narrowed. T + 1.

September 28th, iridectomy upwards in both eyes. Slow but steady failure of vision in both eyes, with slight unfavorable changes in the fields, as long as the patient was under observa-

tion. At date of last examination, February 8th, 1888, R. E. $\frac{20}{100}$; L. E. $\frac{20}{200}$.

CASE 75. — Miss E. H., aged 54, Hebrew, October 3, 1887. Failing vision for three years in both eyes. No pain.

R. E. $\frac{20}{100}$ +. L. E. $\frac{20}{100}$ +. Refraction hypermetropic. Media clear. Glaucomatous excavation of both discs. Concentric narrowing of both fields. T + 1.

November 11th, iridectomy upwards in both eyes. Slow diminution of vision and progressive narrowing of the field in both eyes. This patient was seen with great regularity once a month until June, 1888. At the last examination, R. E. $\frac{10}{200}$; L. E. $\frac{8}{200}$.

CASE 76. — Mr. C. Y., aged 47, October 17, 1887. Lost the vision of the R. E. very suddenly in the course of a few minutes ten years ago, without any signs of inflammation or pain, and has never regained it. Vision in L. E. began to fail about a year ago.

R. E, V = 0. Clear Media. Atrophy of optic disc. T + 1.

L. E. $\frac{20}{100}$. Refraction hypermetropic. Media clear. Glaucomatous excavation of disc. Marked narrowing of field. T + 1.

October 21, iridectomy upwards in L. E. There was a rather profuse hemorrhage into the anterior chamber, which was not entirely absorbed for several weeks. Vision was not materially changed in this eye, and 14 months after the operation the L. E. has vision of $\frac{20}{100}$ —, but the field had become somewhat more narrow than before the operation.

CASE 77. — Mr. S. B. B, aged 76, November 2, 1887. Failing vision for three years in L. E., and for one year in R. E.

R. E. $\frac{20}{40}$ —. Refraction myopic. Media clear. Deep excavation of disc. Concentric narrowing of field. Tn.

L. E. $\frac{20}{100}$ eccentrically. Media clear. Refraction myopic. Field very narrow. Very deep excavation of disc. T + 1.

November 4th, iridectomy upwards in both eyes. Steady failure of vision and progressive narrowing of the field in both eyes, which still continues, so that now (April, 1889), the patient cannot see to go about alone.

CASE 78. — Mrs. B. H., aged 50, December 3, 1887. Has had photophobia, flashes of light, failing accommodation, and tran-

sient obscuration of vision in the L. E. for some months. Is rheumatic. Well marked arcus senilis in both eyes. Refraction hypermetropic.

R. E. $\frac{20}{20}$. Shallow anterior chamber. Deep overhung excavation. Media clear. Tn. No limitation of field. Arterial pulsation.

L. E. $\frac{20}{30}$ —. Compound hypermetropic astigmatism. Shallow anterior chamber. Media clear. Deep overhung excavation. No limitation of field. Tn.

December 11th, eserine in R. E., and iridectomy upwards in L. E. This patient retained vision of $\frac{20}{40}$ + in the L. E. up to the date of his last visit (March, 1889), and the R. E. has remained free from any attack of glaucoma.

CASE 79. — Mrs. E. Q., aged 60, February 24, 1888. Has had failing vision in R. E. for more than a year, and for nearly as long in the L. E. At times considerable pain.

R. E. $\frac{20}{200}$. Refraction hypermetropic. Shallow chamber. Lens cloudy at periphery. Deep irregular glaucomatous excavation. Marked narrowing of field. T + 1.

L. E. $\frac{20}{70}$ +. Hypermetropic. Media clear. Cupping of disc. Narrowing of field. T + 1.

March 21st, iridectomy upwards in R. E. April 4th, iridectomy upwards in L. E. Vision in R. E. has continued slowly to fail, and in November, 1888, it was $\frac{8}{200}$; in the L. E. it remained unchanged ($\frac{20}{70}$) up to the last examination in November, 1888, a period of about eight months.

CASE 80. — Miss K. S., aged 57, May 14, 1888. Failing vision in L. E. four years ago, and in R. E. one year ago. No pain.

Both eyes have perception of light, with clear media, deep glaucomatous excavation of discs, and T + 1. Refraction compound hypermetropic astigmatism.

May 20th, iridectomy upwards in both eyes. October 30th, V = 0 in both eyes.

CASE 81. — Mrs. S. A. B., aged 49, June 18, 1888. Failing vision in both eyes for about eight months. No pain or any

discomfort. Is very gouty. Hypermetropic. Her mother and brother had glaucoma.

Both eyes V = $\frac{20}{200}$. Media clear. Glaucomatous excavation of both discs. Concentric limitation of field of vision. T + 1.

June 20th, iridectomy upwards in R. E., and eserine in L. E. June 26th, iridectomy upwards in L. E. The vision in both eyes remained the same for a period of more than ten months, and then began to slowly diminish.

CASE 82. — Miss M. L., aged 59, June 25, 1888. Vision began to fail in R. E. one year ago and sank suddenly, so that she has been blind in this eye for nearly four months. No pain at any time. Of late she has noticed some pain in L. E., with occasional obscuration of vision and "colored rings" around the lamp-light.

R. E., V = 0. No anterior chamber. Lens cloudy at periphery. Deep glaucomatous cupping and atrophy of disc. T + 2.

L. E. $\frac{20}{20}$. Shallow chamber. Hypermetropic. Lens cloudy at periphery. No excavation of disc, and no limitation of field. Tn. Prodromal stage.

October 17th, iridectomy upwards in L. E. Vision sank in this eye to $\frac{20}{30}$ immediately after the operation, but subsequently rose to $\frac{20}{30}$ +, and in May, 1889, seven months after the operation, it still remained $\frac{20}{30}$ +.

CASE 83. — Mrs. M. D., aged 64, July 16, 1888. Three years ago had partial paraplegia lasting for a few days, and two weeks later an attack of left facial paralysis, with loss of consciousness, from which she entirely recovered. One year ago she had a sudden convulsion, followed by loss of consciousness and delirium, and since then vision has failed slowly in both eyes, with some dull pain. Is hypermetropic.

R. E. perception of light. Shallow chamber. Iris dilated and immovable. T + 1. Deep excavation. Media clear.

L. E. $\frac{20}{200}$: with + D 3 = $\frac{20}{30}$. Media clear. Shallow chamber. Slight overhung excavation. Slight limitation of field. Tn.

July 18th, iridectomy upwards in R. E., and eserine in L. E. July 21st, iridectomy upwards in L. E. Slow failure of vision in both eyes. In October R. E. = 0; L. E. $\frac{10}{200}$.

CASE 84.—Mrs. S., aged 37, December 14, 1888. Vision began to fail in R. E. about ten months ago, and recently also in L. E. Has myopic astigmatism in the L. E., and hypermetropia in R. E.

R. E. $\frac{20}{40}$ —. Shallow chamber. Media clear. Glaucomatous cupping of disc. Irregular concentric limitation of field. T + 1.

L. E. $\frac{20}{30}$ —. Media clear. Excavation of disc. Slight limitation of field. Tn.

December 16th, iridectomy upwards in R. E. Declined an operation on L. E. Vision in R. E. remained at $\frac{20}{40}$ till May 3, 1889, the date of her last visit.

CASE 85.—Mrs. E. T. H., aged 86, January 19, 1889. Ten years ago had an attack of glaucoma in R. E., for which an iridectomy upwards was done. Since then there has been a gradual failure of vision in both eyes. Three years ago had an attack of complete left hemiplegia, from which she has partially recovered. Since then vision has failed more rapidly.

R. E. fingers at 3 feet. Coloboma iridis upwards. Peripheral opacities of lens. Shallow excavation and atrophy of disc. No field. T + 1.

L. E. fingers at 10 feet. Shallow chamber. Faint opacities at periphery of lens. Deep excavation of disc. No field. T + 1.

January 26th, iridectomy upwards in L. E. April 6th, R. E. perception of light; L. E. movements of the hand.

CASE 86.—Mrs. V., aged 40, January 29, 1889. Has had failing vision in both eyes at times for several months. No pain, but transient obscuration of field, and flashes of light. Refraction hypermetropic.

R. E. $\frac{20}{20}$. Media clear. Shallow excavation. No limitation of field. Tn.

L. E. $\frac{20}{50}$. Media clear. Glaucomatous cupping of disc. Concentric narrowing of field. T + 1.

January 31st, eserine in R. E., and iridectomy upwards in L. E. At date of last examination, May 9, 1889, L. E. $\frac{20}{50}$. R. E. remained as at first, $\frac{20}{20}$, with no limitation of field.

CASE 87.—Mrs. E. W., aged 45, February 18, 1889. Has complained for some months of severe pain in occiput and nape of neck, with dull ache in the eyes, and transient obscuration of vision and flashes of light. Refraction hypermetropic. Gouty.

R. E. $\frac{20}{20}$. Media clear. Iris sluggish. Deep glaucomatous excavation. Field slightly limited. T + 1.

L. E. $\frac{20}{30}$. Media clear. Iris sluggish. Deep excavation. Arterial pulsation. Limitation of field. T + 1.

February 21st, eserine in R. E., and iridectomy upwards in L. E. February 26th, iridectomy upwards in R. E. In this patient the vision has but slightly altered since the operation. R. E. $\frac{20}{30}$ +; L. E. $\frac{20}{80}$.

CASE 88.—Mr. C. M., aged 63, March 6, 1889. Failure of vision, with photopsia and dull pain, began in L. E. ten months ago, and in R. E. about six months ago. Refraction hypermetropic.

R. E. $\frac{20}{30}$ —. Shallow chamber. Media clear. Glaucomatous cupping. Limitation of field. T + 1.

L. E. $\frac{20}{50}$ +: shallow chamber. Media clear. Deep excavation of disc. Marked limitation of field. T + 1.

March 7th, iridectomy upwards in L. E., and eserine in R. E. Slow failure of vision in the L. E. since the operation, May 10th. R. E. $\frac{20}{30}$ +; L. E. $\frac{20}{70}$ —.

CASE 89.—Rev. Mr. W., aged 66, March 8, 1889. Failing vision in R. E. for 18 months, and in L. E. for more than a year. R. E. has been entirely blind for about a year. Some pain and annoying photopsia. Refraction hypermetropic.

R. E., V = 0. No anterior chamber. Glaucoma absolutum. Cataract. T + 2

L. E. $\frac{20}{200}$. Shallow chamber. Iris dilated and immovable. Lens cloudy at periphery. Very deep glaucomatous excavation. Field markedly contracted. T + 1.

March 9th, broad iridectomy upwards in L. E. Very free hemorrhage, with tendency to recurrence in anterior chamber for several days. Very slow healing of wound. March 24th, L. E. $\frac{16}{200}$. This patient lived at a distance, and returned home

immediately after the last examination, and has not since been heard from.

CASE 90. — William H. S., aged 45, October 3, 1886. About a year ago he noticed that he could not see to read as well as usual, and was obliged to hold his book farther away from his eyes. Procured glasses, which gave him relief, but was obliged to increase their strength twice within a year. Is now wearing sph. + D 2.50. For more than a year has had more or less constant dull pain in the eyes, mainly in the R. E. Has sudden flashes of light, and at times sees colored rings around the lights. Media perfectly clear in both eyes. Irides sluggish. Accommodation limited in both eyes.

R. E. $\frac{18}{15}$ —. Shallow anterior chamber. Lens clear. Ash. D 0.50.

L. E. $\frac{18}{15}$ +. Lens clear. Emmetropic. Deep glaucomatous excavation in both eyes. T + 1. Concentric limitation of fields. Color-sense markedly blunted for all but blue. Arterial pulsation in R. E.

October 18th, iridectomy upwards in both eyes. June 3, 1889, R. E. $\frac{18}{15}$ —; L. E. $\frac{18}{15}$ —. Excavation in discs very shallow. Field about the same as at operation.

DISCUSSION.

DR. HERMAN KNAPP, New York. — This subject is one of the most important pathologically, especially as it includes so many uncertainties. On the occasion of a discussion on glaucoma before the Academy, I put together all of the cases on which I had operated during the past nineteen years. There were 670 cases, and I operated on 352, with 464 eyes. There were 226 cases of chronic glaucoma. With regard to nomenclature we ought to speak of simple glaucoma or inflammatory glaucoma. Simple acute glaucoma is not known. With regard to race, one-third of the patients on whom I operated were Jews, but I think that depends very much upon the institution. In my practice, the disproportion is in favor of the Hebrews, as it is in Europe. I think that on the whole, there is a greater prevalence of this affection among the Jews. I cannot say that they have more accommodative power than others. They are as capable as other people, and why this should be so I have not the slightest idea, but the fact is I think beyond dispute.

I shall not here speak of all the points to which the doctor has referred. I have made a complete list of the cases and have put them together in groups. In general, I can agree with Dr. Bull. I think that the prognosis may be a little more favorable than he has stated. I think that there are a certain number of cases which not only keep their vision, but also have it improved, and improved permanently. I mean in chronic glaucoma. On the other hand, I have had four malignant cases in the 226 of chronic glaucoma. There were unfortunately two cases in which I operated on both eyes, and of course, both patients reproached me very much. In one of the cases the glaucoma was not very marked. The patient was a lady about forty-five years of age. The glaucoma was well developed, and the contraction of the visual field and the excavation were distinct. Visual acuteness was good. Six months later, vision failed, and she consulted Dr. Loring, and he advised an operation. She came to me and I operated on both eyes. This was followed by great exacerbation of the symptoms. This was a case of simple glaucoma terminating in malignant glaucoma. There were inflammatory symptoms, pain, and abolition of the anterior chamber in both eyes. There was perception of light, but not much more, and gradually this became extinct.

Another case was that of an old lady whom I had watched for eight years. She had atheromatous arteries, and her condition was such that I dreaded the operation very much. I shrank from it as long as I could, until there was rapid diminution of sight. I then told her that she would have to take her chances, as she would be blind in from three to six months. Both eyes turned out in the same way. This was three or four years ago. Since then she has been greatly annoyed by inflammatory recurrences of glaucoma. Lately one of the wounds opened, and a good deal of the ciliary body came into the wound, which I had to remove. The eye then shrank. There were two more cases but these were one-sided. Vision was lost in the affected eye, but in both cases the other eye has remained good. Malignant glaucoma is much more apt to follow in young persons than in old.

Cystoid Scar. — In my observations with extraction without iridectomy, I find that there are a certain number of prolapses which heal with a cystoid scar. This occurs even in young persons, and still more in older ones. I think that this is due to a mechanical cause. The location of the incision will throw the iris and ciliary body into the wound, forming microscopic channels, and causing this condition. I very much fear that the difficulty is due to an impure wound from the presence of parts

forced under any title of our existing nomenclature. I found it convenient to arrange my cases of glaucoma under the following heads:

I. Acute inflammatory glaucoma.

II. Chronic inflammatory glaucoma without visible degenerative changes in the iris.

III. Chronic inflammatory glaucoma with degenerative changes in the iris.

IV. Simple glaucoma.

V. Intermittent glaucoma.

In the records of the Mt. Sinai Hospital, the German Hospital, and of those in my private practice, I found detailed statements of forty-eight iridectomies in acute glaucoma. These forty-eight operations were performed upon thirty-nine patients, and the results obtained by iridectomy were highly satisfactory. The object for which these operations were performed was attained in all but two cases, and in these two exceptions the untoward outcome of the operation was not due to any defect of the method. One eye was lost by suppurative panopthalmitis, because I had overlooked an existing blennorhea of the tear-sac. This case was particularly sad, as the patient had previously lost her other eye. In the second case, operated upon by candle-light, with insufficient assistance in a tenement house, I carried a broad, lance-shaped knife squarely into the lens. It was the left eye of the patient, with widely dilated pupil and no anterior chamber. The iridectomy was performed in the usual manner. The patient obtained prompt relief in spite of the injury of the lens. Four days later the lens having become swollen by imbibition, the glaucomatous symptoms reappeared. I opened and enlarged the wound, removed the lens, and the patient made a good recovery with a useful eye.

In acute glaucoma iridectomy as a method has given in my practice uniformly good results. Anterior sclerotomy was performed by me five times in acute glaucoma. Four times the operation was only temporarily successful and had to be followed by a curative iridectomy. The one case in which sclerotomy

proved successful was that of a gentleman seventy years of age, who had been operated upon for cataract five years before. In the operation for cataract a section had been made upward in the limbus of the cornea and a broad iridectomy practiced. Ten weeks ago this gentleman returned to me with acute glaucoma in the two eyes. I iridectomized the right eye and sclerotomized the left aphakial eye. The glaucomatous tension was relieved and vision improved in both eyes. The occurrence of glaucoma in an aphakial eye demonstrates that a diminished circumlental space is not the only factor in the production of glaucoma. The number of sclerotomies performed by me in acute glaucoma is too small to permit me to formulate conclusions for the guidance of others.

There are other matters of interest in connection with these cases of acute glaucoma that I may mention here. One patient suffered from diabetes mellitus. His right eye had become affected, and was operated upon. Four days later the glaucoma showed itself in the left eye, which was promptly iridectomized. Both eyes recovered and retain until now, four years after the operation, useful vision.

In one case the attack of acute glaucoma supervened in one eye during the course of facial erysipelas. I was obliged to delay the operation ten days until the subsidence of the erysipelas. By the use of eserine, I was able to bridge over the time of danger; but I learned in this case that repeated instillations of eserine in acute glaucoma may result in posterior synechiae which are not easily broken, inasmuch as the employment of a mydriatic is counter-indicated in these cases.

One man operated upon for acute glaucoma in both eyes, suffered from myxœdema. The hypertrophic changes characteristic of this affection had existed more than ten years. There was no deviation in the ordinary course of healing, except that copious retinal hemorrhage followed the operation. At the end of six weeks the hemorrhagic patches had disappeared and the sight was completely restored.

In the case of a woman of fifty years of age, the acute glaucoma supervened in the course of herpes zoster ophthalmicus. It was one of the rare cases of bilateral herpes, and I was

called to see the case when the second side of the face and the second eye had become affected. I found vision abolished in the right eye, reduced in the left. Immediate iridectomy upon both eyes cured the glaucoma in both, but restored vision in the left only.

In this series of operations it happened altogether three times, and always in women, that twenty-four hours after iridectomy upon one eye, the other previously healthy eye was attacked by acute glaucoma. In two of these cases immediate iridectomy was practiced with good result upon the secondarily affected eye. In the third case the patient refused to have a second operation performed, and I resorted to the instillation of eserine, which to my agreeable surprise, cut short the attack and, as it seems, cured the glaucoma permanently. This is the only instance in my experience of the cure of acute glaucoma by the use of a myotic. The last named observations were made before the publication of Arlt's book upon Glaucoma. He advises the instillation of eserine into the sound eye at the time of operation in order to prevent the occurrence of glaucoma.

We now pass to the second class of cases — chronic imflammatory glaucoma without degenerative changes in the iris. These cases were characterized by the following symptoms: the cornea was slightly hazy in the center, the anterior chamber shallow, the pupil moderately dilated, promptly contracting upon the use of eserine, the episcleral veins were tortuous, the pain in the eye and head was moderate, vision varying from $\frac{3}{200}$ to $\frac{20}{200}$, field contracted in supero-nasal quadrant only, tension varying between +1 and +2, the duration of the disease from four to six months.

I operated only upon three patients that came under this category. In two patients both eyes were iridectomized; in the third only one. The results in these five operations were most satisfactory. The symptoms of glaucoma disappeared and there were only such changes in the interior of the eye as were due to the long-continued tension, viz.: slight cupping and paleness of the disk. The good results in these cases seem to be permanent, the patients having been under observation three years, two years, and one and one-half years respectively.

I may summarize my experience in this class of cases by saying that in chronic glaucoma without degenerative changes in the iris, iridectomy yields satisfactory results.

We may now consider the third class of cases that come under the head of chronic inflammatory glaucoma with degenerative changes of the iris. In my books I find records of ten patients upon whom I performed various operations for this condition. The operations were iridectomy anterior sclerotomy, posterior sclerotomy, and enucleation. Altogether twelve eyes were thus treated. In all twelve I began with an iridectomy. In no case was the pain, due to high intraocular tension, relieved. The question of sight need not be considered in these patients, the operation being merely undertaken for the relief of pain.

Many cases of absolute glaucoma come under this head. In five of the cases mentioned, I performed anterior sclerotomy when I found that I had obtained nothing by iridectomy, but anterior sclerotomy proved equally unavailing. In two of these cases I then performed posterior sclerotomy, denuding the sclera in the region of the equator between the rectus externus and the rectus inferior, making an equatorial incision through all the membranes of the eye, allowing some vitreous to escape and covering the gaping and scloral wound with the conjunctiva. In one of the eyes thus operated upon all symptoms of irritation ceased, and enucleation of the eye-ball became unnecessary. In the other eye, after a short period of quiet, all the symptoms of tension reappeared, rendering enucleation imperative.

Several of the patients here mentioned withdrew from observation, but I was told by their friends that they were either still suffering or had had their eyes removed by other surgeons. I may then sum up as follows: In chronic glaucoma with degenerative changes, neither iridectomy nor anterior sclerotomy will give to the patient the desired relief; posterior sclerotomy may do it at times.

What is meant by glaucoma simplex we all understand. I mean those cases in which the anterior aspect of the eye presents no sign of disease; but where the cupping of the nerve, the limitation of the field of vision in the nasal half, the gradual

reduction of sight, with retention of the color perception and the light sense are the characteristic symptoms. It has been said that if iridectomy be performed in cases of this kind, a further contraction of the field of vision and a rapid reduction of sight, entirely disproportionate to the optical disturbance of an enlarged pupil, would ensue. Still, in twenty operations recorded in my books, such results never followed.

It is true that four of the twenty eyes thus operated upon became blind in the course of time, but not immediately after the operation, and not in consequence of it, but rather in spite of it and this after a very long time. In the majority of cases the status quo antea is maintained, and eyes that have been operated upon ten years ago by me have shown to this day neither a further reduction of sight nor a further contraction of field. I am therefore of the opinion that the operation of iridectomy should be performed in all cases of simple glaucoma.

I now turn to the cases of intermittent glaucoma that came under my observation. It is not usual to make a different class of these cases, but in doing so I am justified by the peculiarity of their clinical features and the distressing operative results obtained. Happily I can only report the observations made upon three patients. The first case is that of a gentleman 63 years of age, who consulted me in the beginning of 1887. He stated that the vision of his left eye had gradually diminished; that he had felt a sensation of discomfort and pressure in this eye, and that he had occasionally seen colored rings around the lights, and, furthermore, that of late he had experienced similar symptoms in the right eye, the vision of which was usually perfect. The examination of the eyes showed for the right eye vision $= \frac{20}{20}$, for the left eye vision $= \frac{20}{40}$, fields of normal extent, good color preception, with glasses connecting his presbyopia he read Jaeger 1 with either eye.

The optic nerve of the right eye was decidedly redder than normal, that of the left eye decidedly paler and the retinal vessels were smaller than normal; no cupping of either disk. The pupils were small, reacted well, the anterior chambers appeared of normal depth, the episcleral veins were slightly tortuous. I supposed that he was suffering from the so-called pre-

monitory attacks of glaucoma, and requested him to call when the symptoms of which he complained annoyed him. A few days later he came one morning with symptoms of a mild attack of glaucoma in both eyes well pronounced. I prescribed $\frac{1}{10}$ per cent. solution of eserine, to be instilled every three hours as long as the attack lasted. He presented himself next day, with his eyes improved, and stated that one instillation of eserine had sufficed to make him comfortable. These attacks occurred about fortnightly, and were always readily cut short by the eserine. He remained under my observation about nine months, at which time the vision of the right eye had been reduced to $\frac{20}{40}$, that of the left eye to $\frac{20}{70}$, the fields still remaining complete. In September, 1887, I proposed to him the operation of iridectomy, to which he consented.

The iridectomies practiced were large and every way lege-artis; but when I discharged the patient from the hospital on Oct. 11th, I was shocked to find that the vision of his right eye had been reduced from $\frac{20}{40}$ to $\frac{20}{70}$, and that of the left from $\frac{20}{70}$ to mere perception of light. Both optic nerves were white, the vessels reduced in size; there was no appreciable cupping of the disk. The glaucoma remained cured, but a further reduction of sight of the right eye ensued. At present, with sight $\frac{20}{100}$ in the right eye, a complete field, and good color perception, he reads ordinary print with difficulty. After the operation he was obliged to give up his position as accountant in a banking house.

The second case of intermittent glaucoma was that of a saloon-keeper of fifty years of age. The left eye only was affected. Before the operation the sight of this eye was $\frac{20}{30}$. In all respects the case resembled that of the preceding patient. Two weeks after the operation, which had been correctly performed, the optic nerve appeared white, the vessels were small, no cupping of the disk, sight reduced from $\frac{20}{30}$ to $\frac{20}{100}$. This patient did not return.

The third case of intermittent glaucoma was that of a woman, A—— S——, aged fifty-five. She presented herself on Dec. 6, 1888, complaining of seeing at times colored rings around the lights, a circle of green surrounded by one of red. At the

examination the vision was $\frac{20}{30}$ with $+\frac{1}{48}$ in either eye, fields complete, color perception good. From Dec. 6th to Jan. 3d she had a number of glaucomatous attacks in the left eye only. After the last attack the vision of that eye had been reduced from $\frac{20}{30}$ to $\frac{20}{70}$. On Jan. 3d of this year, I performed iridectomy. Twenty-four hours later I found the wound closed and the anterior chamber restored. Two days later, no anterior chamber, the eye hard, and only perception of light. I opened the wound and dressed the eye. The following day I found the lens in the dressing and a large mass of vitreous hanging from the wound. I snipped off the vitreous at the level of the wound. The case proceeded well from that time, the wound healed, the glaucoma was cured, but the vision was lost.

The patient begins to have symptoms of intermittent glaucoma in the other eye. With my painful experience of iridectomy in these cases, I shall not be willing to attempt iridectomy again. Something must be done! If the eye be left to itself blindness will certainly ensue. Here sclerotomy may give a better result.

I may summarize my experience as follows: —

(1) In acute inflammatory glaucoma, iridectomy yields brilliant results.

(2) In chronic inflammatory glaucoma without degenerative changes in the iris, iridectomy gives satisfactory results.

(3) In chronic inflammatory glaucoma with degenerative changes in the iris, neither iridectomy nor anterior sclerotomy gives to the patient the desired relief. Posterior sclerotomy may do it at times.

(4) In simple glaucoma, iridectomy generally maintains the status quo ante, and is therefore indicated.

(5) In intermittent glaucoma, the operation of iridectomy is often followed by reduction of sight.

DISCUSSION.

DR. S. O. RICHEY, Washington. — The uncertainties in the results which have been described have led me to look a little farther into the matter, especially in chronic simple glaucoma. I do not believe that the cause of chronic simple glaucoma is entirely local. We have in glaucoma, so called, the local

expression of a cause to be looked for in the nervous system. It is unquestionably a vascular trouble. It is a trophic disturbance.

Reference has been made to the use of eserine in the early stages. My experience with it has been satisfactory. But I support it with galvanism applied to the cervical ganglia. I think that I can better illustrate my usual experience by reporting from memory a case. A woman aged forty-five years, apparently well nourished, had frequent attacks of severe pain in the head, with at times a flushed and at other times an intensely pale face. There was intolerance of light. She complained frequently of a halo, and during these attacks there was always partial blindness. After each attack there was increased excavation of the disc, and during the attacks greatly increased tension. She had been troubled by exhaustive hemorrhages for years because of a uterine fibroid; a left carcinomatous mamma had been removed two years before; the menopause had begun. These were sufficient factors of a vascular commotion, of which her glaucoma was the reflex determination. The causation in this case was exceptionally clear. I began the use of eserine, not in strong solution, about half a grain to the ounce, three times a day, lessening the strength to $\frac{1}{8}$ grain to the ounce, which I gave into her own hands. The case was a recent one, having lasted eighteen months, and was evidently chronic in character. The eserine had some effect upon the pupil, and I afterwards advised her to use it only when there was some threat of an attack. I supported the eserine by the application of galvanism, the positive pole being placed on the nape of the neck and the negative pole over the region of the trigeminus. I gained complete control of the trouble in six months. In the first three weeks she had three attacks. She had been having about two each week. She then did not have an attack for three months, and then the intervals between the attacks gradually increased in length. She now occasionally has them about a year apart. This was five years ago. Vision has remained about 20/xxx. The last time I saw her she told me that so far as she knew she was entirely well, and had not had an attack for over a year. In cases of this kind, where we have time, we have the opportunity of avoiding an operation, especially as the operation appears to be so unsatisfactory and the results so uncertain.

DR. HERMAN KNAPP, New York. — In regard to the glaucoma that developes in the other eye after operation, I have seen that repeatedly, and only exceptionally have I been forced to make an iridectomy. These cases were almost altogether controlled

by eserine. I may add a case which occurred in the last two weeks, after the extraction of cataract, where a little piece of iris fell before the knife and I had to excise it. On the fifth day acute glaucoma developed. The anterior chamber had not been restored. There was excessive pain and lachrymation. The lids were swollen and there was œdema around the eye. When I touched the ball, it was as hard as stone. I dropped eserine into the eye a few times, and in a few days the attack was completely controlled.

DR. CHARLES STEADMAN BULL, New York. — In reference to the use of a myotic, I would say that in talking with different gentlemen I was astonished to learn that they used eserine in what I consider excessively strong solution. In my experience a solution as weak as half a grain to the ounce may cause iritis after one single instillation. I never use a solution stronger than half a grain to the ounce, and usually employ a solution of one-tenth of a grain to the ounce. In every one of the ninety cases recorded in my paper in which glaucoma existed in both eyes and demanded operation on both eyes, I used eserine in the second eye before operating on the first eye. Where the second eye has remained normal after the operation I have believed that it remained normal because I used a weak solution of eserine. I have used a half grain to the ounce solution for long periods, and I have never seen such a solution produce any irritation in simple chronic glaucoma, and I have yet to see a case in which it failed to produce its effect after months of use. I, however, do not consider it a means of treating glaucoma.

DR. SAMUEL THEOBALD, Baltimore. — Dr. Gruening referred to one case in which eserine apparently permanently cut short an acute glaucoma. I have met with one such case. The attack had come on within twenty-four or forty-eight hours and the symptoms were so marked that I considered it unwise to postpone iridectomy. At the time of the examination eserine was instilled. Later in the day I went to perform the operation, but found the tension reduced and all the acute symptoms gone. I, of course, postponed the iridectomy, and since then have had no occasion to perform it. I have not seen the patient for some months, but up to that time there had been no return of the symptoms. She uses the eserine from time to time.

DR. B. ALEXANDER RANDALL, Philadelphia. — I would confirm the statements with reference to the value of weak solutions of eserine. In one case of intensely severe absolute glaucoma, a solution of one-eighth of a grain to the ounce was entirely successful in relieving the pain. In this case it has been used steadily for three years with no recurrence of the

severe symptoms and without the supervention of any inflammatory trouble, merely a boric acid wash being simultaneously employed

I should like to refer here to a case which has interested me very much, and which the president saw with me. He advised iridectomy. This was done, with the result of leaving a good deal of blood in the anterior chamber which had to be watched for two or three months, as the absorption was slow. No eserine was used. I found later that there were three or four synechiæ which had not been present during the two months after the operation. There had been no history of pain. I had previously seen a number of cases in which there was a decided loss of vision after operation which seemed to be due to too careful efforts to get rid of the blood. Until the publication of the views of Foester on the artificial production of cataract I had not understood why vision was lessened. I have since not endeavored too persistently to get rid of blood in the anterior chamber.

DR. S. D. RISLEY, Philadelphia. — I do not wish to speak of glaucoma, but simply in this connection to call attention to some observations on the value of weak solutions of eserine. I am convinced that in my earlier experience I failed to secure the greatest benefit to my patients from this drug, by employing too strong solutions, being forced by the pain it occasioned to relinquish its use entirely when weaker solutions would have been well borne and useful. Observations upon my own eyes have shown that solutions of the sulphate or bromide of eserine, not stronger than 1/30 grains to the ounce, will contract the pupil and cause a creeping or twitching sensation in the healthy eye, and if instilled regularly, three times daily, for a few days, will keep the pupil contracted steadily, and cause periorbital pain. In eyes with slightly increased tension, solutions from 1/10 to 1/30 grains to the ounce may be steadily used, with great advantage, when stronger solutions would not be tolerated.

DR. O. F. WADSWORTH, Boston. — I was particularly interested in Dr. Gruening's results in simple glaucoma, in that class of cases in which the front of the eye presents no signs of disease, where the anterior chamber is of good depth, the iris reacts promptly to light and to accommodation, and there is no perceptible increase of tension, or at least only a very slight and temporary increase; but where there is distinct excavation of the disc, decrease of vision, and contraction of the field. My impression is that such cases, in my experience, are more common than all the other forms of primary glaucoma put together, and my own feeling has been that they are cases which had

better be let alone. This feeling has been so strong that I have never had occasion to operate except in the later stages, when sometimes acute symptoms appear, and then the results have not been good. I have always given such a doubtful prognosis as to the result of operation that the operation has not been accepted early, and I have not felt justified in urging it. I have known a number of such cases operated on by others, but I think that in none has there been improvement. The course is usually excessively slow. Within two or three months I have removed a cataract from one such case where the patient had been under the care of another physician who had kept him on eserine for several years. The patient became uneasy and wanted something more done. He consulted the late Dr. Agnew and iridectomy was advised. This was done by the gentleman who had him in charge. The result was that the eye which was the worse has failed at least as rapidly as before, and that in the other eye, in which the iridectomy seemed to be perfectly smooth, a cataract formed, which I removed. This was the better eye before the operation. The patient thinks that vision has not decreased in this eye, except so far as the cataract is concerned, but of course it is impossible to decide this exactly. Since the cataract operation his vision is 14/xl, and he reads five-tenths Snellen. I hoped to have heard more said of such cases.

DR. J. A. LIPPINCOTT, Pittsburgh. — The cases related by Dr. Gruening are very instructive. Any light thrown on the therapeutics of simple glaucoma must always be warmly welcomed. In connection with this subject I desire to refer to two cases which seem worthy of special mention. In one, although the incision, which was made with a Von Graefe knife, was perfectly smooth, and was accomplished without undue traction, on withdrawing the knife the iris slowly but steadily bulged into the wound, being pressed forward by the crystalline lens. The result was unfavorable. In the other, operated on about six years ago, I unintentionally left the sphincter pupillæ undivided, and then concluded not to disturb it. Whether *post* or *propter hoc*, the result in this case has proved satisfactory, the patient retaining up to recently the vision she had before the operation, viz: 20/xl.

DR. H. F. HANSELL, Philadelphia. — I had hoped to have heard an opinion expressed in regard to absolute glaucoma, whether it is advisable to do an iridectomy, a sclerotomy, or an enucleation. This question was brought to my attention in the last case on which I operated. I made the incision with the Graefe knife at the junction of the cornea and the sclera. In

withdrawing the knife the iris protruded and behind this the lens and a large part of the vitreous. Three days later, I was obliged to enucleate the stump on account of the pain. I am unable to decide, when in a case of absolute glaucoma some operation is called for to relieve the pain, and not with the object of restoring vision, what operation should be selected.

DR. EMIL GRUENING, New York. — There seems to be a discrepancy in the results of the operations done by Dr. Bull and those done by myself, especially as regards chronic glaucoma. Dr. Bull says that in simple chronic glaucoma the *status quo* is often maintained and that vision is often lost. I say that in chronic simple glaucoma the *status quo* is maintained. If I make one class of the two that I have here, that is, simple glaucoma and the intermittent glaucoma, then the results will tally with those of Dr. Bull. In simple glaucoma, we include those two classes. There is the simple glaucoma which Dr. Wadsworth has described. Then there is simple glaucoma with a narrow anterior chamber, with cloudy cornea, some large episcleral vessels, but no distinct cupping and perhaps redness of the disc. These are the dangerous cases. Perhaps those cases of Dr. Bull in which there was rapid reduction of sight after operation were of this class. It is important to make this distinction.

DR. C. S. BULL, New York. — I did not read the histories of my cases, but in every one there is a detailed account of the entire treatment. In all those cases to which Dr. Gruening refers there was distinct excavation of the disc. The intermittent cases I have never seen.

DR. HENRY D. NOYES, New York. — I think that the value of this discussion turns upon digested statistical results, and I hope that that feature will be carried as far as possible in order that we may reach some broad generalizations, which are so much more valuable than deductions from a single case.

There are a few points which appear to have escaped observation. While among the symptoms of glaucoma, impairment of function as regards central and peripheral vision is always emphasized, I beg leave to call attention to another circumstance: that is, the occurrence of scotoma in some cases which may approach very closely the center of vision and there may be little or no peripheral impairment. A case of that description came under my observation a long time ago, for which I did iridectomy. The patient was able to mark out the scotoma, and from time to time gave me a map showing the progress of the case. Such maps I have had during a period of ten or more years. While in one eye there has been some increase of

the scotoma, in the other there has been none. In one eye vision has materially declined, but in the other the decline has been so slight that the gentleman is able to continue his profession as a lawyer.

I should like to call attention to the extreme difficulty of detecting the symptoms of glaucoma in myopia. In the statistics of Dr. Bull, in which the valuation of myopia is given at a certain percentage, it would seem that we rarely meet with that condition. It has happened to me to be much puzzled in not a few instances where there was myopia with excavation of the nerve and other symptoms which I could not account for. Where conditions of general distension of the back of the eye exist, there will also be in some instances lesion of the optic disc, which may be considered a true glaucoma, and for which the only method of relief is operation. These are difficult cases to decide about.

Another matter to which attention was directed many years ago is that glaucoma is associated with a large amount of refractive error. It has seemed that the aggravation of the glaucomatous condition was dependent upon accommodative strain. I know one gentleman, himself an oculist and the subject of great astigmatism, and also at present of glaucoma, who has found that he controlled his symptoms by absolutely suspending accommodation by atropia and resorting to the necessary corrective glasses for all purposes.

I was interested to hear about intermittent glaucoma, and it seems to me that unless there should be some frequency of recurrence we are liable to fall into confusion. Intermission is a characteristic of simple glaucoma, and simple glaucoma may exist for twenty years. It may remain latent for a long period and then recur. So that I am unable to make the distinction between simple glaucoma of more or less protracted duration with more or less frequent recurrences, and so-called intermittent glaucoma.

I may also say that I have assumed the conservative attitude which Dr. Knapp has taken in regard to cases of glaucoma simplex, where there is little or no impairment of function either in central or peripheral vision, and have preferred to let these patients take their chances under prolonged observation rather than interfere and expose myself and them to serious disaster and acceleration of the disease. In some of these cases I have resorted to strychnia in high doses; and while I cannot speak of the ultimate results, there has in some cases been temporary improvement of vision. This is hardly a condition in which statements of much general value can be

obtained. I have classed these cases more closely with simple atrophy of the nerve than with the glaucomatous condition. These two things border on each other, and it is hard to draw the distinction exactly.

In the matter of operation, I have gradually withdrawn from the extremely peripheric place of incision. I do not favor going so far back into the sclera as is done by some. I prefer to come closer to the border of the cornea, which involves less risk and which appears to me to be essentially as satisfactory, and is certainly much more easy of performance. The special reason for doing this is not so much the avoidance of a cystoid scar as the avoidance of traumatic cataract. I am absolutely sure that I have never produced traumatic cataract with the point of the knife, but I do know that cataract has ensued in at least three instances. In one case, that of a young woman aged twenty years, I was obliged afterwards to extract the opaque lens to relieve the persistent glaucomatous irritation, which continued despite the iridectomy. The ultimate result was good.

The question has been asked, what can you do for absolute glaucoma, save enucleation, if the case is a bad one? That depends much upon the circumstances of the patient and the necessity for relief. If the person is poor and could not afford to lose time, I should not hesitate to enucleate, but where the delay is not objectionable and where the preservation of a suitable stump is of some importance, the operation of ciliary neurotomy may answer the purpose.

DR. W. W. SEELY, Cincinnati.—With regard to the size and place of the iridectomy, I was glad to hear from the last speaker that the position of the iridectomy was not of so much importance as we formerly had thought. It has struck me for a number of years that the extreme peripheral position was not necessary especially as we know that only the removal of a small portion of the pupillary margin of the iris has sufficed to a cure or cures. I do not employ as extremely peripheral incision as formerly. I have never had a cystoid cicatrix. It has seemed to me that the results of incision made further in the cornea were as good as those of incision made further back in the transitional tissue. In regard to the size of the iridectomy, it has seemed to me that the results were as good when it was small as when it was large.

I have laid a great deal of stress upon the point referred to by Dr. Knapp of freeing the wound of the iris. I think that with a little manipulation that can be accomplished and the results of the operation are much better.

There are some points in regard to eserine. This is a chronic subject and individual experiences differ very widely. I have tried weak solutions of eserine, but have never seemed to get any effect from them. For many years, the only solution that I have employed has been a four grain to the ounce solution once a day. I use this every day and I have never seen a case of iritis result from its use. I do not find cases in which I have to stop the use of eserine on account of the pain. I have not that fear of the results of eserine which some seem to have.

DR. H. KNAPP, New York. — I want to say one word in regard to posterior sclerotomy. I have seen good effects from this in the case of an oculist who had repeated attacks of chronic glaucoma and who had had several sclerotomies and one iridectomy. The attacks came on almost daily and distressed him so that he could scarcely do anything. Sclerotomy was done and relieved him completely. When vision is lost and the eye ball is of good shape, I think that this deserves a trial.

DR. SAMUEL THEOBALD, Baltimore. — The case reported of a distinguished oculist with astigmatism who found relief from glaucoma by the use of atropia is to me one of unusual interest. I read a paper at the meeting in Washington, bearing upon this subject. I there pointed out my experience that astigmatism, and particularly astigmatism against the rule, is a not infrequent cause of glaucoma. During the past twelve months I have had further experience which has confirmed me in this view. I feel more than ever that it is incumbent upon the oculist when he encounters a case of glaucoma to examine for astigmatism.

DR. ARTHUR MATHEWSON, Brooklyn. — I would say a word in regard to the use of strychnia. In one case where the eye had been lost in spite of iridectomy, I iridectomized the other eye without stopping the progress of the disease. One day the patient came to the hospital with vision so bad that she had to be led. I gave her a large injection of strychnia. The next time the patient returned she had considerable vision, which continued. I have used strychnia in many cases of glaucoma since, but never with such marked effect, although in many with good results. In many cases, however, no result was obtained.

DR. SAMUEL B. ST. JOHN, Hartford. — My limited experience leads me to endorse the views in regard to the non-necessity for the peripheric incision and the non-necessity for the removal of a broad portion of the iris. One successful case has been referred to where the margin of the iris was not included. Some years ago, I intentionally made an iridectomy of that kind in the extraction of a cataract. In this case I was pleased with the way in which the iris was retracted and drawn out of

the wound. Some months ago, being called upon to do an iridectomy for glaucoma, I did it in the same way with a similar result. The iris retracted very nicely, and there was no necessity for instrumental interference in stroking back the pillars of the iris. We may get the same results, as far as the iridectomy is concerned, and better cicatrization of the wound by doing the iridectomy in this way. The case referred to was one of acute glaucoma, and the result of the operation was all that could be desired.

DR. HENRY W. WILLIAMS, Boston. — This matter is of such importance that I venture to make a suggestion in regard to one point. I am one of the few members of this society who treated glaucoma before iridectomy was introduced. The surprising results gained by the application of this momentous discovery of von Graefe, naturally led us to extend the operation to all cases, acute and chronic; for, at first, we were unable to decide as to the relative effects in each. After a while we began to observe that the results in acute glaucoma were almost certain relief, while in chronic glaucoma they were very uncertain and often unsatisfactory. Taking this into account, although I have here no statistics that I could present to be compared with those given to-day, it seems to me that we can very properly consider another point, and that is, the question how the interests of ophthalmic surgery are to be affected, and thus the interests of patients. We know that if we do an unsuccessful operation, the result is unfavorable to a certain extent to ophthalmic surgery, and tends to deter patients who could be successfully operated upon from coming for advice. Chronic glaucoma often maintains the same condition for a long time, whether operated on or not, and taking into account my own experience, with the results given by Dr. Bull, I think we should be reserved as to operating in chronic glaucoma. If we do it where the chances are very slight, we rather do an injustice to the profession and to the community. Even when we state that we do not expect good results, and although the patient may be satisfied, those who hear of the operation and would be proper subjects for it, in acute glaucoma, are apt to be deterred by the insuccess in such cases. I would not say that iridectomy should never be resorted to in the chronic form of this disease, but it should be used with a good deal of reserve, as the results are not such as to justify us in doing it on a large scale.

DR. EMIL GRUENING, New York. — It seems to be supposed that I perform iridectomy in every case of chronic glaucoma. I have only reported those cases in which I did the operation. I

have many other cases in which I did not operate. I do not recommend the operation in every case of chronic glaucoma. I have a large series of cases in which the operation has not been performed.

DR. C. S. BULL, New York. — The ninety cases reported are only those which I have followed for a year or more. Many other cases are not included because I could not follow them out.

THE USE OF THE CURETTE IN THE TREATMENT OF INVETERATE PANNUS.

BY E. GRUENING, M.D.,

OF NEW YORK.

IN trachomatous pannus the cornea is rendered opaque by changes in its parenchyma and its epithelium. In the parenchyma chiefly by infiltration, in the epithelium by proliferation and abundant vascularization. The opacity resulting from these morbid alterations is at times very dense; it often survives the original disease, and persists after the granulations in the lids have been rooted out. The treatment of this pannous condition of the cornea has hitherto been unsatisfactory, and when both corneæ are affected, the patient is practically sightless, and in fact, is often consigned to the Blind Asylum.

For the relief of intractable pannus two modes of operation are mentioned in our accepted text-books. The first is peritomy, the excision of a narrow strip of conjunctiva around the whole cornea, with subsequent scarification of the sub-conjunctival and episcleral vessels. The second is punctiform actual cauterization of the conjunctival vessels at their points of entrance into the cornea. In my personal experience these surgical procedures have been inadequate. Of other therapeutic measures proposed and practiced, I may here mention the inoculation with blennorrhoic pus, and the instillation of the Jequirity infusion. Inoculation is repugnant and dangerous. Jequirity though often beneficial, at times disastrous.

During the past two years I resorted successfully to the operation of curetting the cornea in cases of inveterate pannus. I attacked the cornea itself by removing its thickened and proliferated epithelium and its large superficial vessels. Altogether I employed this method upon eleven eyes of six patients. Two of my patients had been inmates of the New York Asylum for the Blind, the one three years, the other five. The mode of procedure is as follows:

The eye is anæsthetized by the instillation of a 6% solution of cocaine, and the whole epithelium of the cornea and its superficial vessels are bodily scraped away by means of a gouge-shaped instrument, such as is used for the removal of foreign bodies from the cornea (sharp spud). Each individual vessel is followed well upon the conjunctiva. During the curetting process the eye is frequently inundated with warm saturated solution of boric acid, and after the operation, warm compresses are applied continuously four or five days. Scarcely any reaction ensues. Twenty-four hours after the operation the cornea is covered with a dense grayish membrane, which adheres but slightly to the underlying tissue, and can be lifted off easily or wiped away. If left in place it disappears spontaneously during the following two or three days. In the course of two or three weeks the normal and transparent epithelium of the cornea is restored. The vascularity, as a rule, does not return. In three corneæ of the eleven treated, new vessels formed, and were removed by a repetition of the operation. The final results in all these cases were highly satisfactory, and may be illustrated by the case of Maggie Little, aged fifteen, who as an inmate of the New York Blind Asylum, applied for admission to the eye-ward of the Mt. Sinai Hospital on February 27, 1888. The granulations in her lids had disappeared and the conjunctiva had been changed extensively into cicatricial tissue. A dense pannus had reduced the vision of either eye to mere perception of light. I curetted both corneæ in the manner described, and on the 10th of April, six weeks after admission, Maggie Little was discharged from the hospital with sight = $\frac{20}{70}$. She could read ordinary print, and did not return to the Blind Asylum.

In cases of old and intractable pannus the operation of curet-

ting the cornea may be commended for its directness, simplicity, safety, and efficacy.

DISCUSSION.

DR. SAMUEL B. ST. JOHN, Hartford. — Shortly after learning of the method employed by Dr. Gruening, I used it in one case with highly gratifying results. Vision, after a single curetting, rose from 4/cc to 16/cc within two weeks. Since then there has been further improvement. The rapid improvement, and the absence of reaction, was remarkable. The greyish membrane referred to appeared in my case. I did not remove it, and it disappeared in a few days.

A CONTRIBUTION TO THE MANAGEMENT OF INITIAL MYOPIA ACQUISITA.

BY S. O. RICHEY, M.D.,
OF WASHINGTON, D. C.

THE emmetropic, or the non-progressive slightly myopic, eye is best suited to the occupations of civilized life, because it has most endurance when taxed by objects within the limit of distance at which rays of light sensibly diverge. Hyperopia is the typical refraction; "the refraction of neonati is exclusively hyperopic." * That this condition persists, or changes but slightly, in the lower animals and in human beings who lead an outdoor life, away from occupations requiring precise ocular attention to objects within the length of the arm; that the refraction increases with the years of an individual up to twenty-five, and beyond, if he be engaged continuously with small objects near him, are points established by statistics.

The hyperopic eye, unlike the emmetropic or myopic eye, is to a greater degree a vital organ, rather than an optical machine arranged for a given class of work. It has more life and adaptability, adjusting itself for the *best* definition of images at different distances and of varying sizes. Objects appear more

* Kœnigstein, Wien. med. Journ., p. 47, 1881.

brilliant to it — because, it accommodates for *every* object at *whatever distance*, and the ciliary muscle is better developed by this constant exercise; and because, with this constant effort at accommodation are associated movements of the choroid and retina, the perceptive elements being thus kept in a constant state of healthful tension. Objects are smaller and brighter, and more clearly defined.

A hyperope can see farther and more accurately when the atmosphere contains more than the usual amount of moisture, or in a fog; myopic vision is increased by such conditions.

Nature did not build eyes for vision limited to twenty feet, though she adapts, or endeavors to adapt, them to the uses to which they are subjected. Hence, the increasing tendency to myopia in civilization, for the percentage of myopia in a given race is an approximate measure of its civilization. The myopic eye can work in a *lower* illumination on account of the *apparent* size of the objects, which it magnifies. Myopia and chronic nasal catarrh are *vestigia* of luxury. Houses exclude light, distance, and cold air; the handkerchief is limited to the civilized human being.

How does nature, in her effort to adapt the human eye to its environment, change hyperopia into myopia, or myopic astigmatism? This is the question with which this paper will attempt briefly to deal; for, with a clear conception of the *modus operandi* of structural changes, we have positive indications for the prevention of such processes.

In accommodation, the ciliary muscle, by its contraction, advances the choroid, and with it the retina. This action of the muscle has been observed through a sclero-corneal incision opposite the muscle, and also by the swaying of the heads of pins stuck perpendicularly into different parts of the choroid (Hensen and Voelckers). This movement of the choroid increases the pressure of the corpus vitreum on the lens: the lens is carried against the iris, which being contracted offers resistance to the lens, except in the pupillary space where the lens becomes most convex. Whether the lens becomes more convex by its own elasticity during the relaxation of the zonule, or, whether the circular fibres *press* by their ciliary processes on the equator of the

lens (Müller), it is unnecessary to the purpose of this discussion to decide. We are also to exclude that class of myopia into which inherited tendency enters as a factor, so far as this is indicated by its existence in some progenitor, and limit our consideration to the action of the most potent cause of myopia, *ab initio.*

Among civilized people the objects which engage their attention from earliest childhood are, for the most part, included within the four walls of a room; generally within reach of the hands. After having fixed the mode of production of myopia, it will be proper to decide if it be best to *prevent* it, that being possible; if it be best to prevent *entirely* our adaptation by nature to our changed environment, or to *limit* only this process of adaptation. This is a question to be studied and discussed in the interest of coming generations, with a view to its settlement by ourselves, or others.

A slightly myopic eye seems best suited to the needs of present training, and trained occupations, though it would not have been so effective in the pastoral and nomadic modes of life of the past. It is better suited to a race of students and to kindred employments. The danger lies in the too rapid enforcement of the structural changes necessary. If these could be limited in the individual, and reach proper development slowly, through several generations, each one bearing its own share of the adaptation, disease processes might be avoided, and, with this, the inherited tendency to certain affections of the eye. No one organ can be good for everything. The hyperopic eye was perfect for its uses in the past, but it has, in a measure, given way to the so-called emmetropic eye, which must in turn be superseded by the eye of still higher refraction, with the least damage from the process.

The hyperopic eye always exercises some accommodation to secure definition of image, even at infinite distance, and the demand upon accommodation increases in inverse ratio to the size and distance of the object. Such eyes are rarely at rest. The anatomical peculiarities of the region supplied by the trigeminus are not fixed until after the period of second dentition, during which the greatest exactions are made upon it by our

methods of education and preparation for the future duties of life. Tonic ciliary spasm simulating myopia, or myopic astigmatism, is not infrequent. Schweigger says myopia is often developed in children after measles, or scarlet fever; diseases which offer a legacy of muscular asthenia predisposing to muscular spasm of taxed muscles, of which the ciliary muscles are most prominent, as during convalescence they are most relied upon for amusement.

Constant and excessive action of the ciliary muscle causes disturbance in the uveal tract by the continuous motion of the choroid, with the alternate compression and relaxation of the blood vessels resulting from it. The advancement of the choroid and corpus vitreum means an increase in the antero-posterior diameter of the bulb. With this state of things persisting while this whole region is adapting itself during the period of second dentition and diminished general vigor, especially after the exanthemata, is it surprising that the eye should become fixed with an abnormally long antero-posterior diameter? This shape and position having been maintained for some months, the tissues lose their resiliency, and when the spasm is relaxed, the eye does not promptly, if ever, recur to its former condition. This mishap occurs, too, upon the threshold of the sexual life, when the slightest influences have an exaggerated and permanent effect. The myopic process begun at this time is with difficulty interrupted, though it may sometimes be limited by prompt and decided measures, unless in case of inherited tendency.

Irritation of *one* ciliary nerve may cause contraction of the ciliary muscle and the iris, and the advancement of the choroid and vitreous body in the *one* section to which it is distributed. Thus, astigmatism may be inaugurated. To object that astigmatism depends upon asymmetrical curvature of the cornea, is to lose sight of the fact that when the vitreous is advanced it is probably narrowed, that the shape of all the tissues is modified, the cornea as well as the rest.

If the, at this time, temporary malformation of the bulb, and the associated uveal excitement, are not restored to the previous conditions, the prospect of recovery grows less, and inflammatory disturbances of the fundus may supervene.

The means at our command for the accomplishment of this purpose are simple, based upon the rational indications, and have been found effective. If not all elasticity of the tissues is lost by delay, the persistent use of atropia in suspending accommodation will permit a recurrence to the earlier refractive power; and, by the rest it affords, relieve the choroido-retinal perturbation. A solution of atropia, 1:120 parts, should be used, one drop in each eye, every second, third, or fourth day, *pro re nata;* combine with this a London-smoke + lens as strong as is tolerated, to be worn, and for a necessary time all near-work must be suspended. Some months are required to gain the best effect, which is the chief impediment to success. The true American, the child as well as the adult, living in the same atmosphere of nervous excitement, and impressed with an exalted idea of the importance of what he is endeavoring to do and the short space of time in which it must be done, has no appreciation of the conservation of energy. He has a life to live, and wants to get through with the *business.* He looks upon physical integrity as an accomplishment, rather than important to the real purpose of life. He is very impatient of time *lost* in securing to himself the physical advantages already possessed, and will probably more than once infringe the rules given for his guidance, and risk the success of the effort made in his behalf.

After the *best* effect of the mydriatic has been secured it may be suspended, the length of time the eyes may be used is arranged, the strongest plus lens through which the individual can read at 36 cm. distance is prescribed, and he is to be forbidden to approach the object more nearly. He is to read nothing that cannot be easily seen at the given distance with the lens. This plan, repeated as necessary, will establish the improved condition, in a length of time varying with different individuals.

I hereto append a few cases in point:

CASE I.—June 19, 1882. Miss M., aged 32. Since 1876, has noticed that she could not recognize acquaintances across the street. Has had pain in her eyes for four months. Her vision is worse after concentration for a time upon some

near object; has decided photophobia and often congestion of the bulbar conjunctiva. V., each = 20/cc. Reads Jæger's No. 1, easily with either eye, at 12 in. With — 3 Ds., V., each = 20/xx. A solution of Atropia, 1 : 240, and a + .5 Ds. lens for reading were prescribed to relax A. (as has since been suggested by Landolt in his work on *Accommodation and Refraction of the Eye*).

August 1st. + 1 Ds. each was prescribed, and the atropia was continued.

August 10th V. each = 12/c.

Jan. 11, 1883. Under this treatment continued V., each = 20/c —.

November 12th. No farther improvement, and — 1.75 Ds. were prescribed for distance, giving V., each = 20/xx.

July 16, 1884. I examined the eyes again with the same result.

Six years is a long time for tonic spasm of the ciliary muscle to exist without some structural change, which had taken place in this case, probably. After 30, the tissues naturally have less elasticity than earlier in life. The patient was a government employé, and was compelled to continue desk-work during the treatment. These three facts may explain why success in this case was not better even than it was.

CASE II.—July 29, 1882. F. C. H., aged twenty, a student of civil engineering. Complains of nothing except indistinct vision for distant objects. V., each = 20/LXX; with — 2 Ds., each = 20/xx. Reads Jæger's No. 1 at 21 in., and at 5 in.

He was seen at intervals until Feb. 4, 1884, and under the treatment carried out as well as possible while the young man was attempting to keep up with his class, with — 1.25 Ds., V., each = 20/xx.

July 22, 1884. The same condition existed. His mother is a myope.

CASE III.—Feb. 3, 1886. F. L. H., a school boy of twelve years. He is small, and does not look strong, though ordinarily vigorous by report. He is very fond of books, and reads nearly all the time in bad light and in awkward positions. Distant objects "are blurred; not clear as they used to be." V., each

= 20/XX—. Prescribed —.75 Ds., for distance only, with instructions to maintain *always* a distance of fifteen inches from his book, to read in a good light, not lying down.

October, 1888. He returned with V. R. = 20/LXX —; V. L. = 20/LXX—.

V. R. =, with — 1.25 Ds., 20/XX.

V. L. =, with — 1 Ds., 20/XX.

Subjected to the course of treatment indicated, with cold water douche to the eyes, he has gradually improved as the following tests declare:

November 10th. V. R. = 20/L; 20th, = 20/XL; December 22d, = 20/XXX; January 19th, = 20/XX.

November 10th. V. L. = 20/L; 20th, = 20/XL—; December 22d, = 20/XXX; January 19th, = 20/XX.

February 1st.—The atropia was suspended, while the + .5 Ds. lenses were continued, but February 9th, having recovered from the influence of the mydriatic, V. was slightly blurred.

July 1, 1889. The result of the test, V., each, 20/XX.

CASE IV.—June 16, 1888. W. W., aged seventeen years, consulted me in great distress. He had been rejected, upon a physical examination for West Point, the examining board having reached the conclusion that there was myopic astigmatism of the right eye, and myopia of the left eye. Upon examination, V. R. = 20/LXX; V. L. = 20/XX—. Jæger's No. 1 could be read easily at 12 inches.

After the instillation of atropia he was again examined.

18th, V. R. = 20/LXX; 19th, 20/LXX; with — 1. Ds. = 20/XX; 26th, = 20/XXX.

18th, V. L. = 20/XXX; 19th, 20/20.

The last part of July, V. R. = 20/XX, under the continued treatment.

He was advised to abandon his intended plan of going to West Point, because the integrity of his eyes could not be preserved under the exactions to which they would be subjected there, and he would be rejected at the close of his term. This course was followed, and he has since been studying at home.

September. V., each = 20/XX. He used his eyes in a bad light, and in December, V., each = 20/XX—.

February 19, 1889. He has been using his eyes six or eight hours daily since early in December, in reading, maintaining a proper position, and with a good light, without manifest disadvantage. V. = 20/xx —, each.

The father had hyperopic astigmatism of both eyes. An elder brother, whom I examined in June, 1883, when near the end of his course at the naval academy, at Annapolis, had a compound myopic astigmatism of about 5 D., which I suspect has increased. Of two sisters, the elder at 18 years was myopic: R. E. = 2 D.; L. E. = 1.25 D. The younger, October, 1882, 8 years old, was hyperopic, 1.25 D., and during the more than six years that have elapsed, the refraction has not varied. She has been going to school during this time, and has been under my observation. She has worn a correcting glass, read in proper position, and maintained the proper distance between her eyes and her books. She has developed well, though she had grown so slowly until she put on lenses that her parents feared she would be dwarfed. The influence of the glasses was proven by the prompt growth of the child immediately upon their adaptation.

The relief, and the gain in general nutrition and strength, afforded by the timely use of proper convex lenses in hyperopia show the exhaustive effort required of the ciliary muscle by our civilized surroundings. Unless some rational and systematic mechanical method is adopted in anticipating and avoiding the evils which result, Nature will compensate for the continual demand upon the ciliary muscle, by modifying the eye to suit the altered conditions, in order to save the rest of the body from exhaustion, and from the arrest of development arising from overtaxing one set of muscles at the early age at which our children are subjected to our forcing educational methods.

Shall we interfere by artifice with Nature's process in adapting the eye of the Past to the needs of the Present, until what is best can be settled? Or, shall we permit the young to drift into danger from progressive myopia, and the evils it entails upon themselves and their posterity by inheritance?

A concave glass is only an attempted compensation for mischief accomplished in part, or in whole.

ENUCLEATION DURING PANOPHTHALMITIS SUPPURATIVA—WHAT IS THE DANGER TO LIFE, AND HOW TO OBVIATE IT.

BY HENRY D. NOYES, M.D.,

NEW YORK.

SINCE the proposal by Prof. Alfred Graefe, in 1884, to substitute exenteration for enucleation, in consequence, as he alleges, of the important danger to life attending the latter operation, various writers have contributed to our knowledge of how real this danger may be. There is a general belief that the greatest peril is incurred when enucleation is practiced during acute suppurative panophthalmitis attended by severe inflammation in the orbit, especially if the latter be suppurative. Dr. Bunge of Halle has reinforced the opinions of his chief, Prof. Graefe, by a paper, and Deutschman in 1885, Nettleship in 1886, D'Oench in 1887, and Andrews in 1888, have put together all the data up to that time which bear upon the subject. Statistics of fatal cases are not quite accurate, but the number reported is between 36 and 40. Almost all the deaths were by meningitis; a few were by general infection. Meningitis without fatal termination has been several times recorded. The fatal results took place in only about one-half the cases, because of suppurative panophthalmitis, and in the remainder there was neither suppuration in the eye nor in the orbit. Propagation to the brain occurs in various ways, there being so many channels of communication to the cranial cavity from the orbit. Naturally, the optic nerve and its sheath would be the track most frequently followed, but an infective process is certainly quite frequent.

In estimating the measure of risk to life from enucleation a mere statement of the number of recorded deaths has no logical value, unless we can tell how many operations have been done during the time when these deaths took place. This we cannot do, and must therefore fall back upon statistics giving the

number of deaths among a given number of operations. In the Vienna Ophthalmic Clinic, Arlt reported 1,000 enucleations done by himself and his assistants, with no death. In Dr. Knapp's Clinic, D'Oench and Andrews report 578 cases, with no death. Of these cases, 32 were suppurative. Gunn, discussing a fatal case reported by Nettleship, says that this was the first fatal occurrence among over a thousand enucleations done at Moorefield's Ophthalmic Hospital. To augment the material from which a judgment may be formed, I have examined the reports of the operations done during twenty years at the New York Eye and Ear Infirmary, viz.: from 1868 to 1888. There were 1,164; and of these, 161 had suppurative panophthalmitis. Add to these 17 cases of suppuration of the globe, for which evisceration was done. There has been no death in the whole series.

We may sum up, therefore, a total of 3,742 cases: Vienna Clinic, 1,000; Moorfield's Hospital, over 1,000; Knapp Clinic, 578; New York Eye and Ear Infirmary, 1,164; total, 3,742, which includes only one death. Even this total is far below a correct percentage, no doubt, if reports could be had from other large clinics. Dr. Andrews, who tabulates 36 deaths, (New York Medical Journal, Dec. 29, 1888,) includes 4 cases of cancerous disease of the eye. Webster reported a case of purulent panophthalmitis following extraction of cataract, and death without having done anything more to the globe.*

If, now, the risk of death after enucleation is put at 1 in 4,000, and a fatal result can follow as in Webster's case of traumatic panophthalmitis without enucleation, we are certainly justified in performing the operation, notwithstanding the warnings and alarming declarations of Prof. Alfred Graefe and Dr. Bunge.

My purpose in this paper is not fully attained without calling attention to the fact that symptoms of meningitis have appeared in not a few cases, and passed away; and I further wish to add an experience which seems to me to have an important bearing

* Transactions Med. Soc. State of New York, 1888, p. 365. Man æt. 76, one eye enucleated for glaucoma absolutum. In other eye, a year later, normal extraction of cataract. Panophthalmitis fully developed on eighth day, meningitis on twelfth day, death in coma on twentieth day. No autopsy.

upon the therapeutics of severe cases of purulent orbital cellulitis where danger from meningitis confronts us.

CASE. — Man, aged 57, captain of a canal boat loaded with coal, was struck on the left eye by a piece of coal, and came to the New York Eye and Ear Infirmary, March 15, 1889. There was a lacerated wound on the lower part of the cornea, through which iris protruded. The iris was excised, and the wound carefully syringed with a solution of corrosive sublimate, 1 to 3,000, all the dirt removed, and bandage applied. The man insisted on returning to his canal boat. The next day he reappeared, with acute panophthalmitis suppurativa. He was put to bed, freely purged by a cathartic, and hot fomentations applied. After two days longer, the reaction attained extreme severity, both in the globe and orbit. Under ether, enucleation was performed, and so great was the infiltration of the orbital tissues that the operation was very difficult. Temperature, 99° F.

On the next day, March 19th, the lids were more swollen than before, and the orbital tissues more infiltrated and very hard. Temperature 101.2° F., pulse 55. Sublimate solution, 1–3000, constantly applied. Bromide of sodium at night. The following day, temperature 101°, pulse 55, suffers severe pain, had a bad night, was a little delirious, has a haggard and anxious look. Lids and orbital tissues very tumid, skin dusky red, the parts very hard when pressed upon, slight puriform discharge. The swelling greater than before the eye was removed.

The general symptoms were manifestly cerebral, and their gravity demanded vigorous measures. The intense phlegmonous inflammation in the orbit must in some way be controlled. The patient was etherized; deep incisions were made vertically through the middle of both upper and lower lids, and after they were split in halves the knife was carried on the same plane deep into the orbit along the roof and the floor; with the same freedom a horizontal cut was made through outer and inner angles and deep into the orbit. No collapse of the tissues ensuing, cuts were made in diagonal directions, reaching down to the apex of the orbit. Very moderate bleeding and less pus

or other inflammatory effusion took place. The tissues were hard, brawny, and yellowish gray. Solution of bi-chloride, 1 to 1000, was freely syringed into the cavity, and it was packed with gauze soaked in the same solution. After the operation, temperature 101°, pulse 52.

The following night he was more comfortable. The next day, March 21, temperature 99°, pulse 68. Wound opened, washed out, and repacked with gauze saturated with Sol. Hyd. Bichlor, 1 to 1000. The same treatment continued daily, the wound being opened, cleansed, and repacked once in twenty-four hours. Tissues of the orbit became much softer, and the swelling declined. During four days, until the 25th, temperature 98.2° to 99 4°. Been free from pain. March 29th, able to sit up, temperature 100°, pulse 65. April 4th, swelling and infiltration of tissues almost disappeared, temperature 98.8°, pulse 70. April 6th, discharged and to attend as out patient. The sublimate solution was continuously kept up, and not until his discharge was its strength reduced to 1–3000.

There seems to me no doubt that the patient's life was saved by the vigorous, not to say heroic, incisions, giving vent to secretions, and the powerful antiseptic. The general treatment consisted in moderate stimulation and a little bromide. Anodynes were not needed. The parts were so mutilated as to preclude wearing an artificial eye.

If enucleation had not been done, the orbital inflammation was severe enough to compel deep incisions, and the eyeball would have been a hindrance to the escape of fluid. Only the deep incisions and the powerful antiseptics could have been effective, and to give opportunity for them, removal of the eye would have been necessary. Hence, I do not regard the enucleation as contributing to the risks of the disease, much less responsible for the cerebral symptoms.

Where evisceration has been done in similar cases, the effusion in the orbit usually grows greater, and it has more than once happened that I have been obliged to cut through the back of the opened globe to give vent to fluids behind.

It seems to me that timely resort to deep incisions, with or without enucleation, is the urgent indication when symptoms

of meningitis appear. It will be very rare that the eyelids must be divided in the vertical plane, but one may not shrink from this unpleasant proceeding when, as in the case of my patient, they are enormously swollen, the palpebral fissure closed, and the orbital tissues densely infiltrated and protruding.

It must not be inferred that I am in favor of enucleation of the eye in every case of purulent panophthalmitis. Some cases may be brought through a lingering process without doing it, yet for the large class to whom this misfortune happens, whose daily bread depends on daily wages, enucleation is the most humane and time-saving alternative.

DISCUSSION.

DR. CHARLES J. KIPP, Newark. — I have recently enucleated an eye for traumatic panophthalmitis, three days after the occurrence of the injury. The case was that of a boy whose cornea was perforated by a piece of rusty iron wire. I saw him six hours after he had received the injury, and found a small, lacerated wound, with yellowish edges, in the outer half of the cornea. The cornea around the wound was hazy. A knuckle of iris was in the wound, but did not protrude. The iris itself was swollen and discolored. There was a quantity of pus in the lower part of the anterior chamber, and a yellowish exudation closed the pupil. The eye had perception of light only. I washed out the eye with a 1–3000 solution of corrosive sublimate, instilled atropine, and applied a bandage. On the following day there was much swelling of the lids, abundant sero-purulent secretion from the conjunctival sac, great chemosis, increased haziness of cornea, and the anterior chamber was half filled with pus. The pain in and around the eye was almost unbearable. Next day there was, in addition to the symptoms mentioned, considerable protrusion and impaired mobility of the globe. As there was no longer any hope of saving the eye, and the pain could not be relieved by free doses of morphine, I enucleated the eye on the same day. On opening Tenons capsule, I found, to my great surprise, a considerable quantity of pus between it and the globe, and after the division of the optic nerve more pus escaped from the deeper parts of the orbit. It is needless to add that the sclerotic was not cut into, and that no opening could be found in it. I washed out the cavity with a 1–1000 solution of corrosive sublimate, applied corrosive sublimate gauze over the lids, and a bandage over this. No reaction followed the operation, and the patient was discharged from the hospital six days after the operation.

DR. HENRY W. WILLIAMS, Boston. — When I saw Snellen in Utrecht, five years ago, as he was about to enucleate an eye, he remarked to me that he was going to take out this eye, but that now he only took out one where he formerly removed six. When I soon after saw Horner in Zurich, he said that he now seldom took out an eye compared to the frequency with which he used to do so. I thought these two statements of great importance as coming from two of the best clinical teachers and most accurate observers that we know of; especially as they were in both cases made without my having given any indication of my own opinion as to enucleations.

On further conversation I found these confrères agreed with me that removal of the eyeball had been far too frequently practiced, because of an exaggerated fear of sympathetic inflammation of the opposite eye, in cases where oftentimes no operation was needed, or where partial excision, exenteration, or opticociliary neurotomy would have answered every purpose of protection, while retaining in the orbit the sclera with its attached motor muscles, to the great benefit of the patient.

DR. H. KNAPP, New York. — It would be important if Dr. Noyes could indicate the fatal cases of panophthalmitis without enucleation, if possible. I could never find reports of such cases. There have been a number of fatal cases of secondary panophthalmitis, but of ordinary, primary panopthalmitis after cataract operations only one fatal case has been reported.

CARIES AND NECROSIS OF THE WALLS OF THE ORBIT.

BY H. KNAPP, M.D.,
NEW YORK.

MANY cases of periosteal swelling, especially at the margins of the orbit, disappear by absorption in the course of some weeks or months, without any special treatment. In most instances they are probably the result of injury, but a cause cannot always be found. The periosteal intumescences in the later stages of syphilis are rare on the bones of the orbit, but they occur, and are sometimes quite extensive, producing considerable pain and exophthalmos. They may, as in the bones of the nose, lead to caries, but I remember no such example

from my personal experience. In a marked case of syphilis with protracted tertiary symptoms, repeated painful swellings of different bones, etc., I noticed also, rather acute diffuse swelling of the upper and inner walls of the orbit and considerable exophthalmos, but no disturbance of vision. It completely yielded to mercurial inunction, not to iodide of potassium, which the patient, a physician, had taken for a long time.

Caries and necrosis affect the different walls of the orbit with unequal frequency.

The *outer wall* is rarely affected, though exposed to traumatisms as much as any of the others.

The *upper wall* is, it seems, the most frequent seat of these processes, and where the consequences are most dangerous. We are all familiar with the picture of long ulceration and suppuration below the upper margin of the orbit, which ends in a retracted scar and eversion of the upper lid, sometimes with great swelling of the conjunctiva, necessitating plastic operations, especially when by exposure of the eye ulceration of the cornea ensues. The mere cutting out of the cicatricial cords in indrawn scars with more or less palpebral eversion has rarely given me satisfactory results, for commonly a new cord reëstablishes the *status quo ante.*

The caries of the upper wall of the orbit has been seen, by propagation of the suppuration, to lead to meningitis and death. In other cases the inflammation spreads to the orbital tissue, produces exophthalmos, neuro-retinitis, with more or less impairment of sight up to perfect blindness. Recovery may take place, but the sight remains impaired. The suppuration may also extend to the cranial cavity, causing death by meningitis or abscess. Very instructive examples of these conditions are reported by v. Graefe and Horner in the first volume of Zeh. Klin. Mon., 1863.

Treatment in these cases, even under very bad conditions, is frequently followed by excellent results. Allow me to illustrate this by an example from my practice of last winter:

A child, 3½ years old, was sent to me by a physician with the statement of the parents that he thought it necessary to have the eyeball removed. The disease had begun, a month pre-

viously, by swelling of the upper lid and gradual protrusion of the eyeball. I found the whole upper lid dark red, very much swollen, the supra-orbital margin tender to the touch, considerable exophthalmos, chemosis, and diminished mobility of the eyeball. In the lower half of the cornea, which by insufficient closure of the lids had been exposed, there was a deep ulcer, but as yet no perforation. On raising the upper lid, I could ascertain that the upper half of the cornea was clear and that iris and pupil were intact. Below the inner third of the upper margin of the orbit there was a greater prominence in the upper lid, with indistinct fluctuation. My diagnosis, caries of the upper wall of the orbit, was at once made, and I resolved to treat and cure it without sacrificing the eye. I sent the child to the hospital and lanced the prominent part of the upper lid, liberating a considerable quantity of pus. The explorations with a probe discovered extensive caries of the upper and part of the inner wall of the orbit, but no loose bone. No communication with the frontal sinus or with the nasal cavity could be detected, though in the unclean and scrofulous child either may have existed. After removing the pus as far as it was possible by external pressure, I inserted a perforated silver tube to keep the cavity drained, drew the upper lid forcibly down so as to cover the cornea, applied a patch of sublimate gauze to the lids, and covered it with absorbent cotton and a flannel roller. The eye was carefully cleansed and the drainage tube and dressing were changed two or three times daily. There was not much improvement in the first days, yet the corneal ulcer did not spread. On the fourth day I made another deep incision into the upper lid, this time in the outer third. Again I liberated considerable pus, and the probe showed extensive caries also in the outer half of the upper orbital wall; in fact, this wall felt rough in its whole extent, reaching almost to the apex of the orbital pyramid. This accounted for the exophthalmos. Another silver tube was inserted into this opening, and the dressing continued as before. The improvement was now very rapid and most gratifying. The eye gradually receded, the secretion disappeared, the swelling of lid and conjunctiva subsided, the corneal ulcer

cleansed itself and healed, leaving a macula which, being in the lower part of the cornea, did not interfere with sight. The child was discharged from the hospital in three weeks, the silver tubes being removed. Gradually the swelling disappeared entirely, the eye was in its natural position, its sight and movements were undisturbed, the upper lid could be raised and depressed as in the normal, and there was no indrawn scar. No relapse has occurred. I need not say that I was particular in the care for the child's general health and in the cleansing of its nasal cavities. No internal remedies were given.

Suppurative periostitis with caries and necrosis of the *lower wall* of the orbit are not infrequent, and I have seen marked examples of it. The greatest swelling is commonly near the inner angle, even when the lachrymal sac is not implicated. The morbid process may start from a carious tooth or from the malar antrum, and the abscess point either in the conjunctiva or on the outside of the lid, on the cheek. A number of such cases are reported in detail, especially in surgical literature. I will not take up your time with any from my own experience. Suffice it to say that caries and elimination of a portion of the infraorbital margin with indrawn scar and ectropium of the lower lid are the most prominent features of this variety. Apart from the treatment of the original seat of the disease, it is most important freely to lay bare the diseased bone, scrape roughnesses away, and remove loose portions. Drainage as above is indispensable.

Of very great importance are the affections of the *inner*, mesial, *wall* of the orbit. The lachrymal groove and its surroundings furnish the greatest number. Caries may spread from there to the lower orbital margin and the fossa canina. The inner wall of the lachrymal groove or its neighborhood is not infrequently corroded and perforated, which leads to the well-known fistula sacci lachrymalis interna. Carious processes in this region will render the ordinary treatment of swelling and fistula of the lachrymal sac inefficient; we must lay the cavity freely bare, either by splitting from the conjunctiva the external wall of the sac, including both canaliculi, or by opening it from the skin. The lips of the wound should be held apart, the

cavity cleansed by syringing, its walls inspected and probed. In rare cases, of which I have seen some examples, polypi, developed in the lachrymal sac, will then pop forth. Repeated formation of polypi in lachrymal fistulae is, in the majority of cases, probably caused by necrosis, just as in the ear. Allow me to illustrate this by a recent case, which seems very instructive.

A young man had a fistula in the upper lid, above the inner canthus. There was not much difficulty with the conduction of the tears, but the fistulous canal was filled with polypoid excrescences. He had had this condition for months, with occasional painful swellings of the upper lid and inner canthus. I at once said to the gentlemen present that these polypi in all probability proceeded from a piece of dead bone. I probed the canal and found my supposition confirmed. Attempts to extract the bone caused great pain, as it was still firmly attached to the soft parts. I therefore freed the fistula from the polypoid tissue, and inserted a silver tube, telling the patient to let me examine him every week until the dead bone had become loose enough to be drawn out without laceration of the soft parts. In three weeks this could be done. I show you the piece here: it is the whole inner plate of the lachrymal bone. After its removal the patient recovered in a week.

I have had similar cases under my care, though none so marked and demonstrative.

The posterior part of the inner wall of the orbit may also be the result of caries and necrosis. Empyema of the ethmoid cells projecting like a tumor, simulating exostosis, has been seen and reported also by the present speaker. It produces exophthalmos. The inflammatory products, pus, etc., are commonly discharged into the nose, whereupon the exophthalmos disappears. In some cases, however, the orbital wall yields, and the pus enters the orbit. Though I have known and appreciated these conditions for many years, I failed to make a correct diagnosis in an important case which I saw two years ago. It referred to a robust man, æt. 46, about, a member of the United States Senate. Being in good general health, he had lost, six months before he consulted me, the sight in one of

his eyes in the course of two days during the development of a considerable exophthalmos. There never had been any discharge from his eye, nor had any one of his physicians been able to detect a cause for the difficulty. The exophthalmos diminished gradually, but did not entirely disappear; the sight was lost. When I saw him, there was still some protrusion, but unimpeded mobility of the globe; vision abolished; the interior showed complete optic nerve atrophy; no other abnormity. The rapid decay of sight during the development of an exophthalmos made me think of embolism or thrombosis in the ophthalmic vessels, not the retinal alone. I could, on palpation, find no anomaly in the orbit or its walls. One of our colleagues in New York, a very self-assured and outspoken man, told the senator the difficulty was of syphilitic origin, however emphatically he denied it, and whatever other physicians thought and said. Our patient was sincere, and I could not detect a trace of lues in his system. I told him that in spite of the assurance of Dr. ——, I could not advise him to take specific remedies, and, in fact, owing to my inability to make a positive diagnosis, I could not advise him anything.

In May of last year the senator came again, and told me that he had been under the care of a specialist for nasal disease, in Washington, who, after some treatment and exploration of the deeper parts of his nose, ruptured a swelling on the side near his bad eye, and a great quantity of matter came out. The patient at once felt relieved, and in a few days his eye had resumed its natural position, though the sight remained lost. The case was now clear to me. The senator had suffered from ethmoiditis. The lateral wall of a cavity in which inflammatory products had been retained had become perforated, and the contents of the cavity had entered the orbit, probably burrowed under the periosteum, produced exophthalmos, optic neuritis, and blindness, as in the fatal case of Horner, where the autopsy revealed this condition.

If now I look at the *etiology* of this group of diseases, I am inclined to believe that the great majority of them originate in the neighboring cavities of the orbit; we only fail to find the connection, which may be a capillary fistula only. Pus is the

result of specific germs. A simple injury, even fracture of the orbital walls, if not communicating with a cavity containing such germs, will not cause suppuration. That all the neighboring cavities of the orbit, by extension of their morbid processes, cause caries and suppuration of the orbital walls is illustrated by numerous well-observed cases. I will not deny the existence of primary periostitis and caries of the orbit, just as little as I deny the existence of primary perimastoiditis, but its occurrence can only be exceptional.

From the foregoing considerations, I would deduce the practical rule that in every case of caries and necrosis of the orbit we should most carefully investigate the conditions of the neighboring cavities, especially those of the nose, which seem to be more frequently at fault than any of the others, and which, strange to say, have been most neglected.

The *treatment* also has to begin with these cavities, may we detect in them the cause of the orbital difficulty or not. Any disease of the nose and its neighboring pneumatic cavities has to receive our full attention.

The local treatment of the orbit has been exemplified in the history of the above cases. It consists in free opening of foci of suppuration, careful cleansing—in some cases with antiseptic injections—and thorough drainage. For this purpose, I cannot highly enough recommend to you the perforated silver tubes with a flange, in preference to all others. I keep a whole series of them on hand for various purposes, and have used and recommended them for many years. They have stood the test of time. Rough bone should be scraped with a sharp spoon, and necrosed portions should be removed as soon as they become loose or easily enough accessible to be detached without injuring important surrounding tissues. The eyeball should be protected, and if everted lids afford insufficient closure, plastic operations should not be delayed until the cornea has become ulcerated by exposure.

MULTIPLE CYSTS OF IRIS IN BOTH EYES.

BY HENRY W. WILLIAMS.

On June 22d I saw a girl, 9 years of age, from a distant city, whose eyes presented these appearances: In the right eye a large projection, slightly folded, having a resemblance to a large cyst, extended downwards from the upper margin of the pupil, and a similar growth from the temporal border. At the lower and inner parts of the field of the pupil were two small pedunculated growths of similar aspect. All these were of the color of the iris, which had a healthy fibrillated appearance. They were dark brown, smooth, appearing as if made up of sacs of distended iris tissue, rather than like ordinary cystic growths. In the left eye two somewhat convoluted cysts, of like aspect, filled the pupillary space from above and below. At the center of each pupil a somewhat square space separated a little these bulging projections, and through this area there was a little oblique vision, although I could not obtain through it any view, or even a reflex of the fundus, even after the use of atropia, which slightly increased the light perception, although no obvious dilatation of the pupils was obtained.

I advised a second inspection of the eyes after a short interval, as I could not get an intelligent history of the case, being unwilling to attempt active measures until after further observation.

HYSTERICAL BLINDNESS OF TEN YEARS' DURATION IN A HEALTHY MALE SUBJECT.

BY GEORGE C. HARLAN, M.D.,

PHILADELPHIA, PENN.

SIXTEEN years ago I reported several cases of hysterical amblyopia under the head of "Simulated Amaurosis" (Am. Jour. Med. Sciences, October, 1873), and since then have chanced to meet with a number of cases, some of which have been published from time to time. The subject has been discussed so frequently of late years in journals and lectures and works upon the nervous system that the excuse for reporting such cases, as a warning to be on the lookout for their possible occurrence in female patients, no longer exists. The same cannot yet be said where male subjects are concerned; and perhaps it is still in order to remind the profession that this strange psychical whim, or whatever it is, is not altogether confined to the more irresponsible nervous organization of the gentler sex. In one of my first cases the patient was a male, and the following is the report of his case:

"A rather delicate-looking boy, aged 11 years, was represented to have become blind in the right eye about eighteen months before. After the disease had resisted the skill of the family physician for some months, the patient's father was recommended to 'try electricity,' and took him to a 'professor' of that science. The result of one application was an entire restoration of vision. The cure lasted, however, only for a few weeks, when the remedy was resorted to again, with the same result as before. After this history had repeated itself a number of times, the father, as a measure of economy, invested in an apparatus of his own, and wound up his son's vision as often as it ran down.

"When brought to the Wills Eye Hospital, the boy asserted that the eye was not conscious of the ophthalmoscopic examination, which, however, revealed nothing to account for the loss of

sight. When a prism was placed before the left eye, he admitted seeing two images of the gas jet, which could easily be distinguished by a colored glass, or made to unite by a corrective squint when the base of the prism was held outwards. He was required to read with the prism still before the eye; and while he was disconcerted and thrown off his guard by being urged to read rapidly, a fold of paper was slipped in front of the left eye, and he continued to read with the right. The father was quite sure that there was no motive for the deception. The fact that the boy's mother was blind of the right eye was a singular coincidence, and perhaps may have had a psychological bearing on the case."

About the same time, I met with the report of a case, by Galezowski, of Paris, in which the patient was also a boy, eleven years of age. Galezowski considered it a plain case of malingering, and in my own report I spoke of the pretended blindness as a deception. What I have seen in other cases since convinces me that we both may have been wrong, and raises a strong doubt in my mind whether either of these patients could have seen by conscious effort with the eye supposed to be blind.

No other instances of this affection occurring in males have come to my knowledge until Dr. Wm. A. Moore reported three cases at the last meeting of this society, and Dr. Edward Jackson referred to one that had recently occurred in his practice. Another has since been reported (New York Med. Journal, Feb. 9, 1889) by Dr. Marlow.

The following case presents several points of interest besides the sex of the patient. A tall, well-developed young man, 22 years of age, a clerk in a railroad office, living some distance from Philadelphia, came to me in March last with the following history: Ten years ago while walking on the street he was struck on the right eye with a stone thrown by another boy. Considerable pain and inflammation followed the injury and the sight of the eye was lost. He was for several months under the care of a well-known ophthalmic surgeon, and finally discharged as incurable from supposed paralysis of the optic nerve. His eyes had since been a constant source of anxiety to his parents,

which at times had proved a serious interruption of his education. He had recently suffered considerable eye strain and frontal headache after work at his desk, which had occasioned him much uneasiness, particularly as his family physician had assured him that it would probably be necessary to have the blind eye removed to save the other one. Under these circumstances he came to Philadelphia for special treatment, quite ready to submit to enucleation if it should be advised.

In the left eye, V. = 20/20, and no manifest hypermetropia; ophthalmoscopic appearances normal. In the right eye, he stated that there was no light perception, that he was not conscious of the bright reflection from the ophthalmoscopic mirror; but the appearance of the eye was natural, the pupil responded to light, and the ophthalmoscope showed absolutely nothing abnormal but a low degree of hypermetropia. His appearance and manner were so utterly at variance with any suggestion of hysteria or any kind of nervous derangement that the suspicion of it did not at first occur to me. At the second visit, with both eyes freely under the effect of homatropine, ophthalmoscopic examination gave the same negative result as before. The mydriatic revealed a latent hypermetropia of 1.25 in the left eye, which had been the cause of the asthenopic symptoms. As a last resort, a prism with base down was held before the left eye, and, to my surprise, double images of a gas jet were at once admitted. This, of course, proved that both eyes saw. How well the right could see was easily shown by a simple test which has never yet failed me in similar cases. A +1.25 glass, which merely corrected the error of refraction, was placed before the right eye, and before the left a +4 glass, which excluded that eye from distant vision without the knowledge of the patient, and he was directed to read the test letters at twenty feet. He read No. 25 without hesitation, of course with the blind eye. I then closed the left eye, and called his attention to what he was doing. His surprise was equaled by his joy at the discovery, and both were evidently genuine. There was no suspicion in my mind of a conscious deception on his part — in fact, he had been ready to seal his good faith by the sacrifice of his eye.

Two interesting points in this case are the long-continuance of this imaginary disease, and the entire absence of any other symptoms of irregular nervous action. After remaining firm in the belief of his blindness for ten years, there is no reason why he might not have carried this suppositious burden through the remainder of his life. The patient himself considered his general health to be perfect; and his uncle, a well-known medical practitioner, assured me that he had not only always been free from any other suggestion of hysteria, but that he knew of no young man in whom he would be more surprised to find any symptom of nervous derangement.

The behavior of the pupil should have excited suspicion of simulation at once, as prompt pupillary reflex in a blind eye may be considered a physiological paradox. My excuse is the apparent absurdity of that view of the case, when the history and present condition of the patient were considered. That the converse does not always hold — that a perfectly immovable pupil is not positive proof of something more than hysteria — was shown by a typical case of hysteria that I reported to the society in 1884, in which a widely-dilated and fixed pupil was one of the symptoms promptly relieved by the application of a wooden imitation of a magnet.

DISCUSSION.

DR. SAMUEL B. ST. JOHN, Hartford. — In this connection, I wish to mention a case in which I made a conspicuous failure to detect the condition, although I was quite certain it existed. The patient was a boy, ten years of age, and, as I afterwards learned, his mother died in an insane asylum. The father had been under my care for a few months previously for steadily increasing atrophy of the optic nerve, which had been going on for a number of years. I mention this fact to show that the subject of eye trouble had been a prominent one in the family. Moreover, there were two neighbors affected with progressive eye troubles, which led to great impairment of vision. The boy had been surrounded by an atmosphere of conversation relating to diseased eyes and impending blindness. He was brought to me with the statement that one eye was blind. I was unable to see anything in the condition of the eye to account for it. I was unable to detect him with any of numerous tests. I then

suggested that he see Dr. Carmalt. Dr. Carmalt wrote me that he had been unable to detect the simulation by the usual tests, and he came to the conclusion that the boy had been shutting one eye without being seen; and at last he caught him doing this. The father was privately told of the trouble, and then the nature of the trouble and the rapidity of the cure were dwelt upon before the boy. He was then given something of an indifferent nature. As he went home, his father would ask him if he could see this or that. Gradually vision came back, and by the time he arrived at home, vision was as good as ever. The supposed blindness was of five weeks' duration. This case shows the importance of knowing the environment of cases in which this trouble is suspected.

FURTHER OBSERVATIONS ON MALARIAL KERATITIS.

BY CHARLES J. KIPP, M.D.,

NEWARK, N. J.

During the nine years that have passed since I first described this disease * I have had under my care one hundred and twenty additional cases, and a careful study of the same has brought out some facts not previously noted.

In all of the cases here referred to the onset of the corneal disease was preceded by several well-marked paroxysms of intermittent fever, for which quinine had been administered. In most cases the paroxysms ceased after the development of the keratitis, but in some they continued for days and weeks. Occasionally the keratitis did not manifest itself till five or six days after the last paroxysm. The disease was observed chiefly in persons between twenty and fifty years of age. Only five cases occurred in persons under five years old. One of these was an infant at the breast, whose mother had intermittent fever. The great majority of the patients belonged to the laboring class. About sixty-six per cent. occurred in males. Cases of this disease came under observation in every month of

* On Keratitis from Malarial Fever. Transactions of the American Opthalmological Society, Newport, 1880.

the year, but sixty-nine per cent. occurred during the months of June, July, August, September, October, and November. The smallest number of cases were seen during December, January, and February. In some years a much larger number came under observation than in others.

In all but five of the cases only one eye was affected.

In about twenty-five per cent. of the cases the patients had suffered previously, some four or five times, from a similar affection of the eyes, and nearly always in the same eye, in connection with chills and fever. The length of the interval between the attacks varied from one to six years. In a few of these cases the fever returned yearly and was regularly followed by the eye affection.

With regard to the character of the eye affection observed in connection with the fever, it should be stated that in only five of the cases the peculiar narrow, serpiginous, superficial ulcer, with lateral offshoots, which is usually found, was absent, and that instead a large abrasion of the epithelium was present, which was probably the result of the breaking of herpetic vessels. In all of the other cases the form of ulceration above described was developed and its onset was nearly always attended by photophobia, lachrymation, and the feeling as if a foreign body were under the upper lid and rubbing against the eyeball. Sometimes a severe supraorbital neuralgia ushered in the eye disease. In a few cases little or no irritation was present during the whole course of the keratitis. The eyelids were rarely red and swollen, and the palpebral conjunctiva was in only a few cases much injected and swollen. There was always more or less circumcorneal injection. If the eye was examined within a few hours after the appearance of the signs of irritation, there was found in some part of the cornea, usually not far from its margin, a number of small grayish opaque elevations arranged in a line, like a string of beads. On the following day these elevations had disappeared, and in their place was found a narrow furrow with a hazy floor and grayish, ragged edges. At the same time, or perhaps not till some days later, one or several short, grayish, perhaps slightly raised, were seen to shoot from one or both sides of the original furrow into the

healthy cornea. If examined with a loupe these offshoots were also seen to be made up of a line of minute grayish dots placed closely side by side. In the course of a day or two these offshoots were also changed into shallow furrows. Unless arrested at this stage by treatment, the main furrow and the branches continued to grow gradually in length, without, however, increasing much in depth or width. The epithelium between the branches, especially if they were placed closely together, was, however, often destroyed. In some cases several furrows were developed simultaneously in different parts of the cornea. The length attained by the furrows varied greatly; sometimes they measured only a few millimeters when the disease was arrested, while in other cases they extended across the entire cornea at the time the cases came under observation. They usually followed a crooked or zigzag course. The furrow always remained quite shallow, and probably seldom penetrated Bowman's layer. The width of the main furrow rarely exceeded one millimeter. The floor and the edges of the main furrow and the branches remained of a bluish-gray color throughout the course of the disease in the cases which were properly treated from the beginning; but in some cases in which poultices of bread and milk had been applied, the floor and edges had assumed a yellowish color, and in two of these cases a hypopion was observed. Perforation of the cornea did not occur in any case. Iritis was observed only in the cases with hypopion, and was only slight in degree. Severe pain in and around the eye was present in nearly all of the severer cases and usually continued till the progress of the ulceration was arrested. The sensibility of the cornea was frequently somewhat reduced in the vicinity of the ulceration, but in other parts it was unimpaired. The tension of the eye remained normal throughout the course of the disease.

The duration of the corneal disease in the milder cases was from two to four weeks, but in the cases which did not come under my care till the ulceration had made considerable progress, and especially if the fever did not yield to treatment, several months were often required for the cure of the case. With the subsidence of the ciliary pain, the photophobia, and

the lachrymation, a marked change was noticed in the appearance of the ulcer. The infiltration of the edges of the furrows disappeared, the edges became smoother, and the furrows began to fill up. Vessels appeared upon the cornea only in cases in which some part of the ulcer was situated close to the limbus conjunctivæ. After the process of repair had once begun the filling up of the furrows required usually but a comparatively short time. The opacities remaining, although not very dense, were, however, in most cases visible on examination, with oblique illumination for months and sometimes for years afterwards.

In a large proportion of the cases a marked disposition existed to a recurrence of the disease with every subsequent attack of malarial fever. Many of the patients have been under my care twice for precisely the same form of ulceration, and a few of them as many as four or five times at intervals varying from one to five years. In these cases the ulceration occurred usually in a different part of the cornea at each attack.

With regard to the five cases previously mentioned in which the form of ulceration here described was absent and in its stead was found a mere abrasion of the epithelium, it may be stated that no attempt at repair was observed for several weeks; that in several cases a shallow font was found some weeks later at the point of abrasion, and that this filled up only very slowly. In one of these cases an ulcer with a yellowish floor developed, which, after increasing considerably in depth, healed without leaving a dense opacity.

Diagnosis. In former years I was inclined to look upon the peculiar form of ulceration here described as characteristic of malarial poisoning, and Dr. Hotz of Chicago, who published a paper upon the subject in *The Chicago Medical Journal and Examiner* for December, 1881, did not hesitate to express the opinion that it was as pathogmonic for malaria as the mucous patches in the mouth are for syphilis. A larger experience has, however, convinced me that it is occasionally, though rarely, seen in persons in perfect health. Since I wrote my first paper on this subject, I have seen at least a dozen cases of this peculiar form of ulceration in persons who were either in the best of health and who lived in localities where malarial fevers

were almost unknown, or in persons suffering from some other disease than malarial poisoning. My own experience thus shows that malarial fever was the cause of the corneal disease in about ninety per cent. of all the cases in which the peculiar ulceration was present.

Within the last five years there have been published several papers by different authors describing a peculiar form of ulceration of the cornea, which resembles so closely the one observed by me in the great majority of the cases of corneal disease due to malarial poisoning that I have no doubt as to their identity. The first of the papers referred to is by Dr. Hansen-Grut of Copenhagen, and is published in *The Transactions of the International Medical Congress held at Copenhagen* in 1884. No mention is made of malarial fevers as the cause of the affection of the cornea. The second paper is by Dr. Emmert of Berne, and can be found in *Hirschberg's Centralblatt für Augenheilkunde*, October, 1885. Emmert calls the disease *keratitis dendritica exulcerans mycotica.* He saw six cases of this disease, all occurring in scrofulous or phthisical patients, and in two of the cases he found a peculiar bacillus in or on the epithelial cells which he had scraped from the infiltrated margin and from the floor of the furrows. Shortly after the publication of Emmert's article, Hock of Vienna, also described, in *Hirschberg's Centralblatt für Augenheilkunde*, December, 1885, a few cases of a similar affection of the cornea occurring in individuals in good health. In the following year Dr. Gillet de Grandmont published in the *Archives D'Ophtalmologie, tome sixieme*, p. 422, the history of a case of what he calls *kératite ulcéreuse en sillons étoilés*, which seems to have much in common with the cases described by the authors above mentioned. Malarial fever was not present in this case. The latest publication on this subject is by Dr. Van Millingen of Constantinople, and is contained in *Hirschberg's Centralblatt für Augenheilkunde* for January, 1888. In this paper Van Millingen states that in connection with intermittent fever he has seen an affection of the cornea which has a remarkable resemblance with the *keratitis dendritica* observed by Hock, Hansen-Grut, and Emmert. As in neither of the above cited papers the article written by

myself on this subject in 1880 is referred to, it seems fair to assume that it was unknown to the authors of the same.

As regards the bacillus found by Emmert, I may state that I have searched for it several times since his paper was published, but have thus far failed to find it in the epithelium scraped from the edges of the furrows. So far as I know, Emmert's discovery has not thus far been confirmed by any writer.

Treatment. Besides remedies for the general disease, which should be conquered with all possible speed, I have used locally warm fomentations, with two to four per cent. solution of boric acid, the pressure bandage, cocaine, atropine, and eserine; and in all cases with muco-purulent secretions of the conjunctiva have applied a one per cent. solution of silver nitrate to the palpebral conjunctiva. Encouraged by the apparently more rapid recovery of the cases treated by the application of silver nitrate to the conjunctiva, I was induced to apply at first a one per cent. solution and later a two per cent. solution of the same directly to the furrows in cases which had failed to yield to the warm fomentation and atropine. Previous to the application of the silver nitrate to the floor of the furrows, these were scraped with a delicate sharp spoon. Under this treatment I had at first very excellent results; but very soon I came across cases which were made worse rather than better by it. In such cases I tried thorough scraping alone for a while, and if this did not arrest the march of the ulcer, have applied the actual cautery to the advancing parts of the ulcer. In most cases where the actual cautery was applied, the pain was speedily relieved and the progress of the ulceration arrested by one application, but in others it had to be applied several times before the disease could be brought to a standstill. In a few cases none of the remedies here mentioned seemed to have the slightest effect on the corneal disease, and this more especially the case in patients suffering from chronic malarial poisoning. In these cases no improvement in the eye disease took place till the general health was much improved.

I append a few sketches taken from my case-book of seven cases of keratitis from malarial fever.

MALARIAL KERATITIS.



DISCUSSION.

DR. HENRY D. NOYES, New York. — This paper interested me very much, because it appears to me that while a great deal of merit attaches to some of the statements, there is a little confusion in classification with respect to the influence of malaria in producing inflammation of the cornea. My observation on this subject dates back some fifteen or twenty years, and I am in print since 1881 as to the existence of the disease. In the cases which I have seen the process was simply a superficial keratitis. It was rare to find the deeper tissues affected. If that occurs, it is due to some complication.

I have been led to consider malaria the cause of the inflammation chiefly by two symptoms: first, exaggerated tenderness over the supra-orbital nerve, which is invariably found; and second, notable anæsthesia of the surface of the cornea. This has attracted my attention to the history, and I have then found a malarial history. In addition to the ordinary treatment of superficial keratitis, I have used strong doses of quinine. As regards the existence of a form of keratitis due to malaria, I am entirely convinced.

The second point which I wish to make is in regard to this peculiar type of keratitis of which the Doctor has given us this interesting sketch. I recognize that keratitis at once. I remember very well all the papers to which he has referred. The first case published was by Hansen-Grut in *Transactions of the International Congress at Copenhagen*, 1884. The title given to this condition by Emmert was *keratitis exulcerans dendritica mycotica.* That kind of a case is in my opinion not essentially malarial. It may co-exist with malarial poisoning, but that it is essentially a mycotic disease I fully believe. The observations of Emmert give strong testimony in this direction. I have a case in mind which is sufficiently convincing. During the time of the blizzard in March, 1888, a number of men who for four days were exposed to these severe atmospheric conditions in digging out the Long Island Railroad were taken with what is called snow blindness. Two of them were brought to the eye infirmary. One had intense photophobia and suffered intense pain. By instilling cocaine freely into his eyes, I was able to examine the cornea. On both sides there were present the signs of dentritic mycotic keratitis. The so-called snow blindness was nothing but mycotic keratitis. Assuming that to be the correct diagnosis, my reasoning was: Let me destroy the cocci and I shall cure the trouble. I secured sufficient anæsthesia by cocaine and scraped out every line of infiltration. The following day the man was comfortable and in a few days

was well. I think that it is unnecessary to resort to the actual cautery. That involves healthy tissue. Simply scraping out these lines of infiltration removes the intrinsic cause, and then simple treatment is all that is necessary.

DR. T. Y. SUTPHEN, Newark. — Since Dr. Kipp called my attention to these peculiar cases fifteen or sixteen years ago, I have taken a great interest in them. They are always associated with malaria. Where there has not been a distinct chill, the patients have been living in malarial districts. I have seen one case of hypopyon with iritis follow this ulceration, and it was necessary to perform paracentesis once or twice before recovery. These cases relapse, but each relapse is less severe than the former, taking the character of softened corneal scar.

In those cases where quinine has not acted as rapidly as I thought it should, I have had great benefit from the use of Fowler's solution continued for a long time. Many of these cases will yield to arsenic which do not heal under quinine and local treatment.

I think that Dr. Kipp is right in considering this disease as quite unique.

DR. JOHN GREEN, St. Louis. — Keratitis complicating malarial fever is quite common in the vicinity of St. Louis. The patients give a history of an attack of intermittent fever followed within a few days by inflammation of one eye or of both eyes. When such cases have come under my care they have presented the usual characteristics of acute or sub-acute keratitis, generally superficial and not infrequently aggravated by neglect or by irritating applications. As a rule the patients have already undergone a course of constitutional treatment by quinine, etc.; the corneal affection commonly yields to simple local treatment.

DR. EMIL GRUENING, New York. — I am well acquainted with this form of keratitis (keratitis dendritica), but I have been in the habit of associating this disease with the condition of the teeth. In every case of this form of keratitis I find the teeth covered with so-called tartar, and all of these patients were in the habit of applying saliva to the eyes in some manner. I think that the mycotic origin seems to be well-established, and I think that the source of the infection is in the mouth. I have also resorted to the treatment mentioned by Dr. Noyes, and removed the gray masses. I find that in some cases the furrows do not heal; they are clear and clean, but remain open, the epithelium not re-forming for as long as six months.

DR. SAMUEL THEOBALD, Baltimore. — I have also for a num-

ber of years recognized these cases of keratitis following malarial attacks. It is not uncommon for me to meet with cases such as have been described, but I have not observed the typical form of ulceration. These cases do not always show ulceration of the cornea. There is sometimes a little raised spot of inflammation. I have been impressed with the fact that anæsthesia of the cornea is so frequently present. I have regarded this variety of keratitis as belonging to the general order of herpes zoster. I have once or twice seen iritis associated with keratitis following malaria. In one case where the malarial history was clear, there was the usual form of superficial keratitis and also typical herpes zoster upon the temple. I have therefore re garded these cases not as of mycotic origin but as being of the herpes zoster variety, and due to changes in the ganglionic matter connected with the fifth nerve.

DR. HENRY W. WILLIAMS, Boston. — I wish to add my testimony to the harmlessness of cocaine in corneal affections. I do not think that any one who has seen the constringing effect of cocaine upon the corneal and conjunctival vessels would consider the use of this agent irrational. If it constricts the vessels we should suppose that it would be useful, and experience proves this. I have seen no harm from a two per cent. solution. I have no doubt that a four per cent. solution may cause abrasion of the cornea and be mischievous. A two per cent. solution does not cause the mischievous dilatation of the pupil that atropia does and increase the photophobia, and it does not cause the painful brow sensations that eserine does. It appears to have a soothing influence, not merely for the time being, and by its action upon the corneal and conjunctival circulation it seems to be one of the most effective agents that we have. In ulcerations of the cornea, especially in children, it is especially serviceable when combined with pilocarpine, which does not cause pain in the supra-orbital nerve, but contracts the pupil and shuts off the light, thus lessening the photophobia and the consequent spasmodic friction of the upper lid upon the ulcerated corneal surface.

DR. H. KNAPP, New York. — I only want to say that superficial ulceration of the cornea is in a number of cases a symptom of acquired syphilis. There is a very superficial loss of tissue, and it heals only under anti-syphilitic treatment.

DR. H. G. MILLER, Providence. — I am inclined to agree with Dr. Kipp as to the malarial origin of the form of keratitis which he describes. Up to seven or eight years ago, we in our part of New England were exempt from malaria. At that time a form

of intermittent fever appeared and spread from the southwest to the northeast, crossing this part (Rhode Island and Connecticut) of New England. Within a few months of the occurrence of the intermittent fever, this form of keratitis began to show itself. I had not seen it before. Since then it has been exceedingly common. I have observed it take this dendritic form in many cases and develop in the way that Dr. Kipp describes.

DR. CHARLES J. KIPP, Newark. — I have no doubt of the mycotic nature of the disease. I have sought for the bacillus, but have not found it. This I have attributed to my incompetence. In ninety per cent. of these cases the inflammation has followed immediately upon a paroxysm of intermittent fever. The attack usually begins as a series of small dots like minute phlyctenulæ. The next day the epithelium is thrown off and the furrow is open. These furrows rarely increase in width, but extend in a serpiginous manner. In the treatment of the affection I have used scraping, but this is not more effective than the application of nitrate of silver. In my first paper I referred to the use of Fowler's solution.

DR. T. Y. SUTPHEN, Newark. — Of all the cases of herpes of the cornea which I have observed, none had the peculiar appearances which so distinguish this form of keratitis.

IRRIGATION OF THE ANTERIOR CHAMBER—A NEW SYRINGE FOR EFFECTING IT.

BY J. A. LIPPINCOTT, M.D.,

PITTSBURGH, PENN.

SINCE McKeown five years ago introduced the procedure of syringing out the anterior chamber in operating for cataract, this method of removing cortical remains has been adopted by distinguished operators in different parts of the world. But the number of those who use the intraocular syringe is up to the present time quite limited, and the value of this recent addition to our armamentarium is still regarded by many as doubtful. My own experience is not extensive enough to form a basis on which to formulate very positive opinions. Nevertheless, I beg to present it as so much evidence on the general question as to whether syringing out the anterior chamber is a justifiable or useful measure.

During the past seven months I have used the syringe in fifteen cataract extractions. Of these cases five were hypermature, eight were mature, one was glaucomatous, and one traumatic. In two of the cases the cortical had become so softened that when the nucleus escaped, the great mass of the lens remained behind, filling up the pupillary area, and practically leaving the vision as bad as before touching the eye. In the mature cases more or less cortical matter remained. As to visual results:

In 2 cases, S. (corrected) = 20/XX. In 2 cases, S. (corrected) = 20/XX—. In 3 cases, S. (corrected) = 20/XXX. In 3 cases, S. (corrected) = 20/XL. In 2 cases, S. (corrected) = 20/LX. In 1 case, S. (corrected) = 20/LXXX. In 1 case, S. (corrected) = 8/C.

In the remaining case the extraction was made a week ago, at a distance, and the corrected vision cannot be given; but the operation was absolutely smooth, and the immediate visual result was all that could be desired.

Of the two instances in which Vn. = 20/LX one was a case of

traumatic cataract with a broad anterior synechia requiring an extensive iridotomy before washing out the lens-matter. The other was a case of glaucoma the progress of which had been previously checked by an iridectomy. In adjusting the glasses the media were found perfectly clear, the impairment of vision being accounted for by well marked glaucomatous changes in the disc. In the worst two cases, with vision respectively 20/LXXX and 8/C, the media were also clear, and the imperfect vision found to be due to atrophy of the optic nerves. In but one case was it necessary to do a second operation. In this case the posterior capsule was so thick and tough that puncturing it effected no material benefit, and the dense membrane was removed with the forceps.

The above facts and statistics are not presented as particularly brilliant evidence of the value of the intraocular syringe in cataract extraction, but they may be regarded as tending to show at least that the employment of this instrument is attended with no radical disadvantages. As a matter of fact, I think we are guided in deciding on the relative merits of different methods not so much by masses of statistics, as by close observation of particular cases and circumstances. Looking at the matter from this point of view, whoever uses the intraocular syringe must be convinced that we have in it a means of removing lenticular debris from the anterior chamber *tuto, cito et jucunde.* Especially is its usefulness apparent in those cases in which the cortical has degenerated into a more or less liquid state. In these cases, and even in extracting cataracts whose peripheral layers are not specially soft, a certain amount of cortical frequently remains after as long and thorough stroking of the cornea as may be considered safe. The residual debris may indeed not be abundant enough to very seriously obstruct vision, and the pupil may look fairly black in good daylight, but the fierce light from the electric lamp reveals a grey film which, on the introduction of the syringe, at once disappears, leaving an unobstructed pupil.

Beside cataractous debris, clotted or liquid blood may be removed in the manner we are considering, more easily and perfectly than in any other way. Every one knows how innocuous and how readily absorbed is even a notable quantity of blood in

the anterior chamber if the lens capsule is unbroken. But my experience leads me to believe that blood remaining in the eye after removal of the lens is not so readily disposed of, but leads to irritation and inflammation of the iris, and consequent lessening of the visual acuity.

The intraocular syringe has been employed not only in cataract extraction, but also in removing collections of pus from within the eye. The two following cases illustrate its advantages in this regard.

CASE I.—J. B., aet. 12, presented himself at my office on the afternoon of February 4, 1889, with his right eyeball intensely red, and a hypopyon five mm. wide at its center, while the aqueous was decidedly turbid. There was a broad posterior synechia in the lower outer region. A small scar was seen on the cornea opposite the adhesion. The boy had been struck in the eye with a flying splinter eight days before, while chopping wood. The patient was sent to the Allegheny General Hospital; and the same evening an incision was made under ether at the corneal margin opposite the synechia. With the exit of the aqueous a small quantity of the pus also escaped. The adherent portion of the iris was now seized, torn from its attachment, and snipped off, whereupon some soft opaque lens-matter appeared in the wound. The removal of the segment of iris also disclosed the fact that a considerable quantity of pus lay in the posterior chamber. Up to this time I had never seen or made use of McKeown's method, and I was not prepared with a suitable instrument. An ordinary eye-dropper with a very slender nozzle was however quickly cleansed, and charged with a 1 per cent. solution of boric acid and its contents expressed into the anterior chamber. This was repeatedly done—the nozzle helping to break up the lens tissue and render it viable. Presently, the pus and much of the lens having been removed, the penetrating electric light revealed a small dark object which was grasped with a pair of smooth iris-forceps and removed. It proved to be a piece of wood 1½ mm. long. The washing out process was kept up until the eye looked perfectly clean, when atropine was instilled and a bandage applied. No reaction followed. The wound healed in a few days, and the boy was

discharged in a week with the eye entirely free from irritation, but with a rather dense capsule through which however he could dimly count fingers.

CASE 2.—W. E., a glassworker, aet. 40, consulted me May 4, 1889. On his left cornea was a very small ulcer surrounded by a faint nebulous area. The cornea was surrounded by a broad livid-red zone. The pupil was dilated (presumably by atropine). Learning that the man was exceedingly intemperate, he was urged to go into the hospital, but without avail. Three weeks later he again presented himself, having been since his last visit on one continuous debauch. The whole globe was intensely injected and somewhat œdematous. The anterior chamber was four-fifths full of pus. The cornea pointed near the lower margin. The eye appeared to be doomed. The patient was sent to the Allegheny Hospital, and soon afterward etherized. During the administration of the anæsthetic the cornea, without any violence on the part of the patient, burst at its prominent point, but no pus escaped. The opening was enlarged with a Graefe knife whereupon a small drop of pus came out. It was now evident that the purulent collection was largely made up of cheesy masses of considerable size, which gentle manipulation failed to dislodge. The nozzle of the intraocular syringe was introduced, and a quantity of 1 per cent. boric acid solution was run into the eye and out again, driving easily and rapidly before it all pus, solid and liquid, and cleansing the eye in a surprising manner. The pupil, which was 5 mm. in diameter round, and apparently free, was nevertheless irresponsive—probably from inflammatory changes in the texture of the iris. Besides, the surface of the iris had a pasty look. A continuous heat apparatus was applied over a light pressure bandage, and, on account of the condition of the iris, a solution of atropine and boric acid was directed to be instilled every two hours. Twenty-four hours later the globe was less congested and the iris looked decidedly cleaner, but there was a small collection of fresh creamy pus at the bottom of the anterior chamber. After a moment's deliberation as to whether the wound should be re-opened and the irrigation renewed, it was decided to trust to the therapeutic efficacy (already many times

demonstrated in my experience) of the continuous dry heat. The treatment already instituted was therefore continued. During the next twenty-four hours the fresh accumulation of pus entirely disappeared. The corneal wound was well closed and the corneal curvature restored. The anterior chamber was filled with perfectly transparent aqueous. The pupil was more dilated and the tissue of the iris looked well. The vision was not seriously impaired. The congestion of the globe was markedly lessened. Two days later the condition of the eye had still further improved, and the patient was on the high road to complete recovery, when, by an unhappy mistake, he was permitted to leave the hospital. He did not re-appear until three weeks had elapsed, when the eye was found to be in a hopeless condition.

Of course this case had an unfortunate termination, but that does not militate against the fact of the brilliant, if temporary, result of the irrigation in a very unpromising case.

I think it will be readily granted that a syringe for washing out the anterior chamber ought to stand the following tests: 1st. It should be easily made and kept aseptic. 2d. It should always be ready for use, or capable of being quickly made so. 3d. It should be easily handled, and its movements readily and absolutely controlled with one hand alone, the other being free for other purposes. 4th. Its ejecting force ought to be capable of being accurately estimated and regulated. 5th. It should not throw bubbles of air into the eye.

Among the latest intraocular syringes described are those of McKeown, Panas, and Wecker. McKeown's * is a piston syringe with flat curved nozzles. The instrument used by Panas is described by himself † as virtually a compte-gouttes armed with a hard rubber tube. Wecker's ‡ syringe is shaped like an ear speculum with a thin India rubber membrane stretched across the large end and furnished with a silver tube at the other. Now, it appears to me that no piston syringe will fulfill any of

* Ann. d Oculistique, Mars-Avril, 1888, p. 144.

† Quoted by McKeown, ibid, p. 145. Before the publication of McKeown's article, however, Panas had abandoned the instrument above referred to and substituted for it a piston syringe. Arch d'Ophthalmologie, Vol. VI, p. 471.

‡ Described by McKeown, Ann. d'Oculistique, Mars-Avril 1888, p. 145.

the conditions stated above except the last; and that any instrument constructed on the principle of Wecker's or Panas' first syringe, while it may stand the first and second, or even perhaps the third test, cannot fulfill the last two conditions. The first cataract case in which I irrigated the interior of the eye was that of the glaucomatous cataract mentioned above. Suspecting that a good deal of cortical matter might remain after the expulsion of the nucleus, I had carefully cleansed the instrument which I have for years used for syringing the nasal duct, and which consists of the rubber portion of an eye-dropper attached to a fine curved silver nozzle — being thus practically the same as the original Panas syringe. I found that it required great care and constant watching of the point of the instrument to prevent the entrance of air into the nozzle and thence into the anterior chamber. A small bubble did in fact get into the eye, but I was able to wash it out, and no injury resulted.



ANTERIOR CHAMBER SYRINGE.
(Natural Size.)

The syringe which I have the honor to present to-day is simple in principle, and can be briefly described.

It consists essentially of a bit of black rubber tubing with a curved flat gold nozzle at one end, and a small metal reservoir * at the other. To control the movements of the nozzle, the latter is fitted into a hollow, hard rubber handle through

* Since this paper was read I have used the syringe with the upper end of the rubber tube attached to a Graefe's "undine" instead of to the metallic reservoir and found the former to answer very well.

which the rubber tubing passes. To the handle is attached a short metal piston which can be pressed by the index finger down upon the tubing and thus stop or retard the current.

Let us see how this syringe responds to the tests. 1st. As there is no backward flow, it has no tendency to become septic in use except at the point of the nozzle, and the latter can be readily pulled off and thrown into boiling water or alcohol. If the purity of the other parts of the apparatus is suspected, it is easy to place the reservoir in boiling water, and to replace the old rubber tubing with a new piece. 2d. This instrument can always be depended upon to work smoothly. 3d. It is held like a penholder, and is as easily and securely handled. 4th. As the ejecting force is proportional to the height of the column of liquid, it is of course under absolute control. I have found as a matter of practice that when the reservoir is at a height of eight inches above the eye, the stream is as strong as required; and this height should not be much exceeded. It may be added that should a *per saltum* movement be desired, this can be effected by rapid up and down movements of the reservoir, which is held by an assistant, or by intermittent pressure on the short piston. 5th. It goes without saying that in using this syringe there is no possibility of the entrance of air into the eye.

As to the fluid injected, the chief desideratum, in my judgment, is that it be clean in all senses of the word. Distilled water, filtered and boiled shortly before using, should be employed. No chemical is needed, as the object is not to *disinfect* the anterior chamber,—an effectual disinfectant would be too irritating to be used safely—but there is no objection to the employment of non-irritating substances such as boric acid or common salt in very weak solution.

Finally, the fluid as it enters the eye ought to be about blood heat. If much higher than this, the sensation is not pleasant, and if much lower, decided pain is experienced, and, what is more important, a spasmodic contraction of the pupil is apt to take place. The reservoir is fitted with a receptacle for a thermometer by which to regulate the temperature.

This syringe is made by Feick Bros. of Pittsburgh, and Reynders of New York.

DISCUSSION.

DR. EMIL GRUENING, New York.—I agree with the reader as to the *cito et jucunde*, but I disagree as to the *tuto*. I think that the instrument does not fulfill all the indications which Dr. Lippincott requires. It is not easy to keep it absolutely clean. It is not impossible that air may enter. I have of late used a very simple instrument for this purpose which is a glass flask, the undine devised by Alfred Graefe. The flask has a spout, and is filled with the solution desired. I have used a one-half per cent. solution of salt. The injecting force may be graduated by raising or lowering the flask. When the eye is irrigated there seems to be a suction exerted. Water thrown from a certain distance enters the chamber. I have used this instrument in hypopyon with brilliant results. I have brought out thick pus which could not otherwise be removed.

TWO CASES OF EXTRACTION FROM THE VITREOUS OF STEEL WHICH HAD PASSED THROUGH THE LENS.

O. F. WADSWORTH, M.D.,

BOSTON, MASS.

APRIL 27, 1886, a boy of thirteen, while watching a man at work with hammer and drill, felt something strike his right eye. He was seen not long afterward by a doctor, who discovered no wound. There was moderate pain and photophobia at first, soon relieved; but on the evening of the following day he complained that he could not see with the injured eye. I saw him on the morning of April 29th, less than forty-eight hours after the injury. There was scarcely any congestion; a linear cicatrix near the center of the cornea, 2 mm. long; a scar in the anterior capsule, and sufficient opacity in the lens, chiefly posterior cortical, to hide, with moderately dilated pupil, the parts behind it. A few hours later, when the pupil was fully dilated, careful examination revealed a grayish body behind the lens, nearly in the course of the wound, and slightly movable. He counted fingers at 2′—3′.

The next day the lens was a trifle clearer, and through its lower and inner part the body behind it was made out to have a sharp outline. Fingers at 5′.

After another twenty-four hours the lens was still clearer, and fingers were counted at 6′—7′. The foreign body could be made out pretty well with a + 7. behind the mirror. It had very little motion, only swung gently with movement of the eye, had a defined angular outline, and on one surface presented the appearance of a fresh fracture of steel. Operation for removal was advised and agreed to.

The following day, May 2d, cocaine was applied, the lids washed and the conjunctiva sluiced with solution of bichloride, 1-6000. The eye was rolled upward and inward with forceps; a fold of conjunctiva between the external and inferior rectus

line; this area was bounded by a narrow strip of (apparently) choroid uncovered by epithelium, and then came the normal fundus of a nearly uniform darkish red; the whole quite regular and sharply defined.

Nine days after the operation he began to see occasional flashes of light before the eye, perhaps a dozen in the course of the day, appearing without special cause; in a few days these became fewer, and were seen mostly in the evening about six o'clock. There was no other symptom of irritation.

Feb. 15th. The thickening over the wound has disappeared. V., R. $\frac{14}{12}$: L. with + .75 cyl. axis 90° $\frac{14}{12}$—. Two dots of blackish pigment have appeared on the disc, near its lower and outer edge; otherwise fundus and media as before.

Feb. 25th. Flashes only on rising in the morning, and occasionally in the evening. R. $\frac{14}{12}$ +; L. with +. 50 cyl. $\frac{14}{12}$—. Vitreous unchanged. On the posterior capsule of the lens, near the end of the band of opacity, a cluster of very fine dots is seen with a strong convex lens behind the mirror. The dots of pigment on the disc noted on the 15th are (at least one of them is) larger, and there are several other black spots, as shown in figure. (Some of these are represented too large, some are quite fine.) A few dark dots are seen moving in the posterior vitreous. Sclera visible at position of wound, but the lead-colored line seen on the 4th is not made out.

April 2d. Examined by members of the New England Ophthalmological Society. Condition about the same. V. not tested. The flashes less. Some of the pigment spots on the disc larger.

May 22d. He says that now the "fine" flashes, which "are bright like a lamp," have diminished in number,— that they are seen only about once a week, then generally in the evening; but a few days after the examination in April (from which he felt no inconvenience) he began to see on first rising in the morning, or in the evening, a grayish light moving with moderate speed round the upper and outer side of the eye, and oc-

casionally passing more than half way round the eye. The light usually moves from the upper and inner angle of orbit, outward and then downward, sometimes in the reverse direction, rarely it "divides and shoots off." At first this appearance became more frequent, but latterly rather less so; he now sees it from three or four to a dozen times in the morning in the course of ten to fifteen minutes, rather oftener in the evening. He has been doing light work the last two weeks. Lately he has occasionally, on looking to the right, seen something come over the left eye from its outer side, and then go back again. V. $\frac{14}{12}$—. An extensive defect in the outer and lower quadrant of the F., encroaching slightly on the adjacent quadrants; in other directions F. of normal extent. Lens as before. In the vitreous the fine threads are not more numerous, but there is, nearly in the antero-posterior diameter, a small globular grayish body with a tail. There is more pigment on the disc, and the spots previously seen have changed; the larger one, depicted on Feb. 25th, is now much broken, while another, as large as it was, has formed a little below it, and there are more spots over and near the larger vessels. There are also in various directions on or just in front of the retina small black rounded spots, not all sharply defined, perhaps a dozen in a radius of two diameters from the disc. The bare sclera is seen at position of wound of operation, wedge-shaped, something resembling a choroidal vein crossing its apex, a small blackish mass which seems to project slightly into the vitreous over its (apparent) lower edge near the apex, and a short black band near this running nearly perpendicular to the edge. Upward and inward, directly opposite to the wound, the retina is separated and comes nearly straight forward, looking gray and opaque, the fold cutting off the fundus to within half a diameter of the disc, and the separation extending upward and outward a little beyond the vertical meridian, downward and inward a little below the horizontal.

June 1st. The separation of the retina is much more extensive, it reaches much further outward above, and almost straight downward from a little to the inner side of the disc, but the parts which looked gray on May 22d now generally transmit a

red reflex and are irregularly wavy. Black spots are visible on the separated as on the non-separated retina, often overlying vessels, and where they lie on the profile of a fold they are seen to be close to, but a little in front of the retinal surface. The appearance of the disc is the same, as is that of the parts about the wound. V. $\frac{14}{20}$—. Defect of F. corresponding to the separation.

June 27th. The flashes have become less numerous, and none have been seen the last two or three days. The separation has extended rather farther outward above. Apparently the black spots on the retina are rather more numerous, and there is a little more pigment on the disc. The vitreous shows somewhat more fine opacities.

July 1st. Separation of retina appears total, but there is no part so opaque as when first seen. The disc, seen rather indistinctly, much the same. The field in which he can see the finger at 18″ is apparently only about an inch wide and three inches long. Flashes are still seen.

The interest in these two cases centers mainly in the second. It is unusual, although by no means unknown, for a foreign body to pass through the lens, cause an opacity only along the wound and leave the curvature, of the central parts at least, practically unchanged.

A more favorable case of the sort for operation could hardly be imagined, and the result of the operation seemed at first all that could be desired. But the appearance of the flashes nine days after the operation, and their persistence, and still more, later, the presence and variation of the pigment spots on the disc and in the posterior vitreous excited doubt as to the final result, a doubt which the end only too well justified. With these exceptions, for more than two months the condition was highly satisfactory.

Considering the pigment changes observed later about the wound of operation, it is probable that an irritative proliferative process was going on there, the results of which became visible at a distance, on the disc and in the most posterior parts of the vitreous, some time before they could be seen in the neighborhood of the wound itself. It is not easy to explain the mechan-

ism of the separation of the retina, starting, as it did, at a point almost the farthest possible from the wound. The vitreous was repeatedly and carefully examined, and the threads visible in it were perhaps not too fine, but certainly too lax, to have exerted any efficient drag.

AN ANALYSIS OF SOME OF THE OCULAR SYMPTOMS OBSERVED IN SO-CALLED GENERAL PARESIS.

BY CHARLES A. OLIVER, M.D.,
OF PHILADELPHIA.

THESE observations were made upon twenty well marked cases of general paralysis of the insane seen at the State Hospital for the Insane at Norristown, Penn., in private practice, and in several private asylums.

The study has been limited to subjects in the so-called second stage of the disease, where the psychical symptoms had become of such a character as to necessitate control, and where motor and sensory degeneration had become more or less manifest.

Care was taken that each subject was seemingly free from any extraneous general disease or local disorder, and that competent and authoritative medical opinion had been given as to the type of the general complaint; besides, the entire study has been limited to the male sex, so as to escape any conflicting and complicating changes that might appear in connection with the many diseases peculiar to the female sex.

OBSERVATIONS.*

First. Direct vision for form, as a rule, slightly reduced from normal.

Second. Direct vision for color, as a rule, slightly subnormal.

Third. Accommodative action, though impossible to obtain any reliable results by various subjective methods, yet objectively (retinoscopy), range and consequent power of accommo-

* A portion of these observations formed a part of the Third Annual Report of the Ophthalmological Department of the State Hospital for the Insane at Norristown, Penn.

dation apparently about normal, or slightly less so in a few instances, for age and refractive error.

Fourth. Visual fields: nothing could be obtained, though seemingly reduced in area, especially in the vertical meridians.

Fifth. Pupils frequently unequal in size; in several instances having a difference of one or two millimeters in their horizontal meridians.

Sixth. Pupils ofttimes ovoid and oval in shape, their long axes being generally opposed to one another. (It must be remembered that if careful examination be made of many pupils in ordinary clinical work amongst the mentally healthy, there will be found a large proportion exhibiting this condition.)

Seventh. In one instance, repeated examinations at two week intervals, revealed a changeable condition of the pupillary form.

Eighth. One iris quite irregular in its pupillary outline, without any evidence of localized change.

Ninth. Irides generally sluggish to light stimulus, and in a few instances, though fairly responsive to accommodation and convergence, yet absolutely immobile to light.

Tenth. With seemingly similar degrees of refractive error, and apparent identical amounts of objective nerve change, the two irides in the same subject frequently unequally mobile to light stimulus, accommodation, and convergence.

Eleventh. In several instances, irides were feebly responsive to efforts for accommodation and convergence only.

Twelfth. In nearly every instance, where light stimulus produced a reflex act, the secondary movement of the iris of the exposed eye was much less marked than is found in the normal eye.

Thirteenth. Irides utterly devoid of any gross peculiarities in comparative tint.

Fourteenth. Insufficiency of the interni present in more than one-half of the cases. Quantitative measurement of the extra ocular muscle enervation impossible to obtain on account of deficient mentality of the subject.

Fifteenth. In a few instances, a peculiar nystagmic action at the release of utmost muscle tension; this being more particularly noticed with the external, internal, and inferior muscles of the globe.

Sixteenth. Optic discs decidedly and unequally grayed in tint, especially in their deepest layers and to their temporal sides; but not more marked, as has been elsewhere noticed, in the left eye.

Seventeenth. Capillarity of nerve substance seemingly lessened, the greatest amount of blood supply being recognized in a rather broad crescentic area to the nasal side of the disc.

Eighteenth. Physiological excavation frequent; usually seen to the outer side of the disc, and extending to the lamina.

Nineteenth. Scleral ring sharply cut, and as a rule, broad; this being more pronounced to the outer side of the nerve.

Twentieth. Broad black pigment crescents, broken and partially absorbed, beyond the scleral ring, frequent to the temporal side of the disc.

Twenty-first. Narrow pigment lines of varying width and different degrees of absorption, beyond scleral ring to the nasal side of the disc.

Twenty-second. Fibre-layer of retina seemingly diminished in thickness, the greatest amount of coarsest striation being seen at the upper and lower borders of the optic nerve.

Twenty-third. Retinal arteries undersized and sometimes slightly tortuous.

Twenty-fourth. Retinal veins (which in the majority of cases were quite tortuous) normal in size, though in several instances somewhat contracted and tapering as they pass into the optic nerve.

Twenty-fifth. Retinal vessels carrying apparently properly colored blood-currents.

Twenty-sixth. Very few lymph reflexes, these being limited to the walls of the main retinal stems.

Twenty-seventh. In one case a deposit of minute yellowish bodies in the retina between the disc and the macula.*

Twenty-eighth. No other gross changes in the retina.

Twenty-ninth. Granular and disturbed condition of the choroid marked in the majority of cases.

---

* Very much like the hyaline bodies noted by Loring and the "pin-point specks" spoken of by Noyes. Urine was carefully examined, giving negative results.

Thirtieth. Refraction generally hypermetropic, with marked degrees of astigmatism.*

The average age was forty years; weight, one hundred and forty-seven pounds; height, five feet and seven inches; complexion, nine blondes, six brunettes, and five medium; nativity, fourteen born in the United States, one in Germany, one in the East Indies, and four unknown; intra-pupillary space, fifty-five millimeters: corneæ, eleven millimeters in horizontal diameter; pupillary diameter, two and a half millimeters in horizontal meridian.

SUMMARY.

1. The sensory changes herein described, which have been limited to unequal optic-nerve degeneration, decrease of retinal circulation, with subnormal direct and eccentric vision for both form and color, distinctly show lowered sensory-nerve response.

2. The motor symptoms consisting in unequal and feeble movement of the irides, causing inequality and irregularity of pupillary areas, the peculiar form of ataxic nystagmus, the slight loss of ciliary tone, all express want of proper muscle action — true paresis.

3. The peculiarly local conditions shown in the fundus, such as the pigment massings, the crescents of absorption, the disturbed and granular condition of the choroid, etc., all indicate wear and tear of an abused and irritated organ.

4. Therefore, these observations upon the ocular apparatus, which were most probably made during the second stage of the disease known as general paralysis of the insane, show not only local changes, but distinctly demonstrate that the series of sensory-motor disturbances found, are but the peripheral expressions of one of the many indices of gradual loss of neural strength and power in this disease.

* It should be distinctly understood that these conditions were not present in every case, each patient presenting different ratios of the several observations given.

CASE OF HEMIANOPSIA WITH PECULIAR CEREBRAL SYMPTOMS.

BY S. B. ST. JOHN, M.D.,

HARTFORD, CONN.

Mr. Y., aged 39, conductor. First seen June 28, 1883; said that two weeks ago he found a sudden slight dimness of vision, without pain. Had had malaria badly. V. R. = $\frac{15}{20}$, L. = $\frac{15}{15}$. Ophthalmoscope showed very slight haziness of retina — no other change. Reading slightly difficult. Put on course hydrarg. and potassium iodide.

There was gradual improvement up to September 15th, when he found that a distinct blur suddenly came over R. E. This passed off in six weeks (there being no ophthalmoscopic change), under use of ac. phosp. and strych., and Nov. 4, V. R. = $\frac{15}{15}$, L. = $\frac{15}{15}$—. Though the vision responded to tests, there was a sluggishness of the retina in responding, and a feeling of discomfort that was ominous.

June 2, 1884. Return of dimness, and November 19th, V. R. = $\frac{15}{25}$, L. = $\frac{15}{40}$. Has now blurring in nasal half of each field. I suspected intra-cranial pressure at the decussation, and put him again on potassium iodide and hydrarg. About this time I asked him to see Dr. Loring, which he did, and this is Dr. Loring's letter at that time.

128 MADISON AVENUE,
NEW YORK, Dec. 16th.

Mr. Y's case is certainly, in many respects, a peculiar one, and one which I should like to study at leisure. The first thing to determine, it seems to me, is whether there are any ophthalmoscopic signs of the presence of disease within the eye itself, and it would seem to me that there are such signs, although I must confess they are not well marked. It seems to me that there are signs of commencing atrophy of the gray type. Now, whether these are due to primary disease of the fibers or to some morbific influence of a

malarial type, it is hard to say. It may, of course, be due to some intra-cranial trouble, such as you suggest, but I am more inclined to think it is not, from the fact that in the left eye the peripheral vision is relatively so good, and the central so much impaired. If pressure at the commissure was the cause, I should expect a more decided loss of vision in the parts affected, whereas it is a diminution and not an absolute loss. I am therefore inclined to think it an atrophic process affecting symmetrical parts of the retina of each eye, the exact nature of which I am, as yet, in doubt about. I have seen some cases like this of a specific origin, and I should be inclined to try anti-specific treatment rather vigorously, especially mercury. In regard to the prognosis, I am in doubt also; one thing is certain, the left eye has got steadily worse, and the vision is worse to-day than it ever has been. I am sorry I cannot throw more light on the case, but it is a difficult one, and one which needs much more study than a single visit can give. I have seen a remarkable improvement in such cases sometimes, and I would not discourage him too much.

Ever yours, E. G. LORING.

He was put upon a vigorous anti-syphilitic treatment, and this was kept up for a few weeks with absolutely no improvement.

In April, 1885, the dullness of the retina had increased so markedly that he had to look an appreciable time at each word in order to comprehend it, but V. R. = $\frac{15}{15}$, L. = $\frac{15}{40}$. The hydrarg. treatment was resumed, and pushed to slight ptyalism. From time to time cinchonidiæ sulphas had been used to meet malarial symptoms. He then saw Dr. Loring again, who wrote as follows:

128 MADISON AVENUE,
NEW YORK, May 27, 1885.

I do not know that I can throw any light upon Mr. Y's case other than what I said in my former note. His central vision seems to be as good as at my former examination. I do not think there is any growth pressing on the nerves at the chiasma, but what the true cause of his trouble is I do not know, unless it be a sort of multiple degeneration of the nerve fibers in spots. It may possibly be due to his malarial diathesis or habit. I am sorry, but this is all I can say of the case.

Very truly yours,
EDW. G. LORING.

He was then given cinchonidia in increasing doses.

September 6th. Pressure in head marked. Fl. ext. ergot given gtt xx. every 6 hrs. In two weeks he was better of the pressure, and also of the pain he had complained of after slight jarring, as in stepping from sidewalk to street. Internal rectus weak, not overcoming 10°. In walking needs *both* eyes; if either one is shut he becomes confused. Add. = 8°, abd. = 8. Prism gives no relief for reading. (Not seen for long interval.)

July 20, 1887. V. R. = $\frac{15}{20}$, L. = $\frac{15}{100}$, at right side field. At times finds words lengthen and contract while he looks steadily at them. Is not confused now in walking if one eye is shut, as formerly. Pressure in head and back of neck less. Put on course of strychnia.

July 5, 1888. Reading gradually more difficult. V. R. = $\frac{15}{25}$, L $\frac{15}{64}$ in right field.

June 15, 1889. V. R. = $\frac{15}{25}$, L. = $\frac{15}{64}$ in R. F.

With R. E. can hardly read at all, but with both reads No. 1 Jaeger, but retina becomes easily fatigued. Has frequent feeling of pressure in the head aggravated greatly by bending over so that he has to be bolstered up in bed at times to relieve it. In the right eye the hemianopsia is complete. In the left eye the right half is much brighter than the left, and the line of demarcation is exactly mesial. There are no marked ophthalmoscopic changes.

SIMPLE TESTS OF THE OCULAR MUSCLES.

BY B. ALEX. RANDALL, M.D.,
PHILADELPHIA.

SINCE the time when Donders and other pioneers first gave us a full picture of the matters of refraction, accommodation, and convergence, the questions as to muscular insufficiencies have occupied a considerable share of attention. Seizing these subjects with his usual vigor, v. Graefe handled them in a manner which has made them in great measure his own; and later discussion has shown that in many respects we can hardly do better than to return to him for solid teaching on this very important matter. Partial tenotomy, and other forms of "graduated tenotomy," rediscovered in this later day, were thoroughly tested by him; and the rules of procedure which he left us were the results of thorough winnowing of the useless from the valuable.

He gave us three practical tests, intended more especially for the study of insufficiencies of the interni, but two of them well calculated to serve in other cases. The first of these was as to the ability of the patient to fix with both eyes an object such as the finger-tip, as it was approached in the middle line to within a few inches of the eyes — a test that is often of value in determining which of the interni is the weaker — but a confessedly rough test, which, even with Landolt's "ophthalmodynamometer," rarely fails to show 16–20 metre angles of converging power in even very weak muscles.

The second test consists in causing the patient to fix upon an object held in the middle line a little below the horizontal at a convenient near point, and watching for any wandering of one eye, in front of which a card is held. Modify his procedure by substituting a *fine* fixation object, such as a pen-point, for the "moderate-sized" penholder which he suggested, and we have an admirable test — ready, simple, and accurate. The *rationale* of this and of the third test, more generally called by v. Graefe's

name, is clearly set forth in his paper; but his tests as there given are rather crude for the certain attainment of the end in view. We are to make trial of the *balance* which subsists between accommodation and convergence—"ein Gleichgewichtsversuch"—and the prime essential to any constant result is that the fixation object shall be such as to hold the accommodation fixed and unvarying. It is a delicately-formed forefinger which needs any accurate accommodation to see it with fair clearness; yet how often we see the test applied in this way! It is small wonder that we hear little as to the value of results thus gained. But try the test in the other form—use a fine pen-point as the fixation-object, insist that the patient fix it so as to see the tip sharply, and make quick movements of the covering card from one eye to the other, and you will obtain results of great practical value and reliability. I do not remember that I have ever discovered by any other test a muscular insufficiency which this test had failed to reveal. Further, it is a test which is *quantitative* as well as qualitative; and in hundreds of cases the *degree* of insufficiency thus estimated and recorded, has proven at most only 1° away from the result as measured by prisms. Roughly speaking, each millimetre of movement of the deviating eye corresponds to 2° of insufficiency as measured by the prisms; but so far as the interni are concerned, each jerk with which the fixation is accomplished is to be multiplied into the foregoing result. Thus, if the covered eye move in some 3 mms. to fix, but do so with three distinct impulses, our estimate of the degree of deviation would be, not 6°, but 18°. Of course, no such rough rule-of-thumb will enable every one at the first trial accurately to estimate degrees of deviation; but a very moderate amount of practice in the comparative use of this and other tests will prove to any one that it is as accurate as it is easy.

No one who has had any experience in testing muscular insufficiencies will need to be told that he must repeat his tests several times and average his results—the first few trials may show a relation of accommodation and convergence that is wholly fictitious and unnatural. Neither this nor any other test will give at all times equal or infallible results; but I ask

for the method — always easy of application, without any spirit-levels or other paraphernalia — a reasonable and conscientious trial at your hands; and do not believe that you will often fail to discover and approximately measure even minute deviations, whether vertical or lateral. To the possible objection that long practice has made me especially expert in correctly estimating, I may reply that I was as accurate as now, when, after a year's practice, I demonstrated the method in v. Arlt's clinic in 1883. On the other hand, some one may object that this is all "as old as the hills," and utilized by every one. It ought to be; but I distinctly doubt if it is. I have never found any one who had habitually employed it.

Let us pass now to the third test of v. Graefe — that with vertical diplopia and prisms. It is, perhaps, in fashion to scoff at this test — never, surely, among those who know how to use it. It furnishes us with just what we want to know — the *habitual* relation between accommodation and convergence. Of course, this relation is not a fixed one; within the limits of the region of relative accommodation and convergence it may by effort be greatly altered; but the habit for each individual is fairly fixed, as we often realize to our cost, if we try to secure abruptly too marked a change in ordering spherical glasses.

Let the underlying principles be clearly realized in practice, and the test will give results that can be relied upon. First, the fixation object must be such as to hold the accommodation fixed — it must not, therefore, be a huge dot and line that could be seen many yards away, but a fine object, such as an asterisk, or a few letters of Jaeger No. 1, or still finer type. Second, the vertical diplopia must be absolute — no long vertical must be afforded which may be common to both images. In this matter too many have followed v. Graefe's original paper, where this was not fully realized, and too large a test object was there given — to be grossly exaggerated by some of his followers. I have seen titanic "dot and line" figures that occupied the greater part of an octavo page. No eye with a self-respecting accommodation could focus for such an object.

Given a suitable fixation object and a vertically placed prism (one of 6° or 8° is quite strong enough) and there will be found

few cases of lacking balance which will not reveal themselves to this test. In the measurement in degrees of the discovered deviation the revolving prisms of Crêtes will prove a great saver of time and trouble. Using this and a fixation object which allows of no overlapping of the images, we will rarely be troubled by any question of "latent insufficiency." Perhaps I am confessing to great incapacity as an observer when I state that I have never seen a case of what Dr. E. G. Loring described as latent insufficiency, and of which Dr. H. D. Noyes spoke last year in the Washington meeting. I have met suggestions of it, which promptly yielded to more careful testing. There may be no question as to the possibility of its occurrence, so long as a patient has any region of relative accommodation and convergence; but, as a clinical fact, I have found it in no single case among hundreds carefully tested as to the muscular condition.

A device of extreme utility in using this vertical diplopia test for far or near was suggested some three years ago by E. E. Maddox (*Journal of Anatomy and Physiology*, xxi), and it has been a surprise to me that so few seem to have noticed it in his abstract in the *Ophthalmic Review* of December, 1886. I have used it with the greatest satisfaction since seeing his paper. It consists of an obtuse-angled prism — or, as it may be otherwise stated — of a double prism base to base. It is held with the junction line of its two inclined surfaces bisecting the pupil, and gives, of course, two false images equidistant from the true position of the object.* In practical testing for distance the observer can cover one eye with the hand which holds the red glass, while he brings the prism into position with the other. A double point of light near the pole of the cornea tells when this is accomplished, and the patient can at once see two lights, and tell whether they stand in a vertical line. The red glass is then brought in front of the other eye, and a third light is seen tinged red. If midway between the two white lights, and in the same vertical line, every form of heterophoria is excluded at a single blow. On the other hand, the slightest vertical or

* Is not this an easy way of obtaining the double images in ophthalmometers like that of Javal and Schiötz? I have not yet put into execution my intention of testing it.

lateral deviation is at once manifest; the red image may approach or blend with one of the white ones, or may wander to the side. If the strength of the prism is such as to give 1.5° of actual deviation in each direction — say 3° of angle in the older notation — no normal muscles are able to blend the real image with one of those vertically displaced; at 6 m. the apparent displacement is about 15 cm. above and below the actual level. Only an eye with weakness of inferior or superior recti will see the red image at any notable distance from the proper level, and the deviation may be at once measured with the prisms as usual. Of course, it is well to check the results by changing the double prism to the other eye. The test is as readily applied near by, the fixation object being an asterisk, or something of the sort, instead of a point of light. The prism is small, and may be conveniently carried in the pocket-book, as mine has been for years, always ready for tests at the bedside as well as elsewhere.

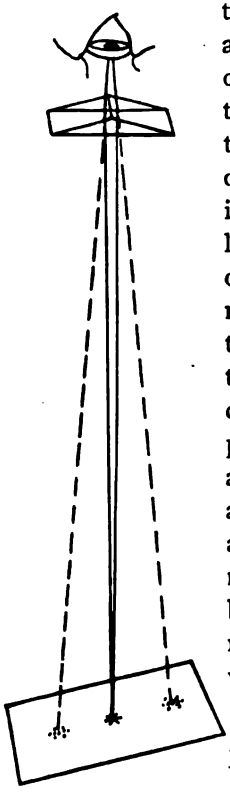

One point, as to the results of my testing, I would like to put upon record here; it has been previously set forth, but not with sufficient clearness; insufficiency of convergence for the near is met in a very large proportion of the eyes tested. Among 81 medical students it was noted (in degrees varying from 2°–12°) in 42 cases, or 52 per cent. Among the last 200 patients on my private case-book (excluding strabismus and presbyopia), there were 154 cases of insufficiency of convergence, 61 of no deviation, 21 of excessive convergence, and 4 of vertical deviation. All of those with inward tendency of the axes were hypermetropes, as were also most of those with deficient convergence.

The tests of the power of the muscles to overcome prisms for distance have not often been of practical value in my hands. Abduction in nineteen cases out of twenty has been from 6°–8°;

adduction almost anything which the patient persistence of the examiner chose to make it. I find that most intelligent patients can overcome from 16°–60° abducent prisms, and those who have by the balance-test an unmistakable lack of convergence are sometimes the best at adduction experiments. For myself, with 3° of outward deviation for distance, and 8° at 25 cm., the abduction is 7° and the adduction from 50°–70°; and this not strictly as the result of practice, although I have always been able to converge my eyes enormously at will, for when first tested by Dr. Risley, ten years ago, the results were almost identical. My refraction is low H., and my accommodation normal.

The point on which I wish to lay stress is, that insufficiency of convergence for the near is the rule among hypermetropes. The reason seems not far to seek. The hypermetrope can avoid excessive convergence only by utilizing and developing the negative part of his range of relative convergence; and, like many of nature's compensations, the correction is overdone. Excessive convergence gives place to deficient convergence. Of course I am speaking of uncorrected hypermetropia — the convex correcting glasses will give relative divergence in all but the actual squint cases; but these are the cases where the demand for excessive accommodation is still present.

As for the other side of the scale — the inward tendency of the visual axes — I have met hardly a case which could be considered one of insufficiency of the externi. A few cases of actual paresis and a number of the concomitant converging strabismus of hypermetropes are the only apparent instances of the condition which have presented themselves.

CONTRIBUTIONS TO THE SUBJECT OF TUMORS OF THE ORBIT AND NEIGHBORING CAVITIES.

BY CHARLES STEDMAN BULL, M.D.,

OF NEW YORK.

CASE I. — *Adeno-Sarcoma of the Lachrymal Gland.* The patient, George G., aged 35, presented himself to me for the first time on May 30, 1887, with the following history. A little more than a year before he had noticed a swelling or tumor, as he thought, of the outer angle of the left upper lid, but after a while he discovered that the swelling was not in the lid, but was a tumor beneath the lid and on the outer aspect of the left eye. There was at first no interference with the movements either of the lid or globe, and no sense of discomfort, but the tumor gradually increased in size and began to cause the patient some annoyance. It had never been painful nor specially sensitive on pressure, nor was there any interference with the vision. When I saw him the outer end of the left upper lid was somewhat bulging, and the growth was seen to be applied closely to the eyeball on the upper, outer, and lower quadrants, and presented in the interpalpebral opening. On everting both lids, and making the patient look toward the extreme right, the growth was seen to extend backwards and upwards into the orbit, and to be connected with a glandular tumor at the site of the lachrymal gland. The tumor was distinctly lobular, reddish in color, somewhat firm in character, and perfectly movable beneath the ocular conjunctiva and upon the globe. The mobility of the eye was slightly interfered with upwards and outwards. The media and fundus were normal, and vision was $\frac{20}{20}+$. The ocular and palpebral conjunctiva was somewhat injected, but there was no secretion of any kind. A diagnosis was made of tumor of the lachrymal gland, and it was decided to attempt its removal. The patient was etherized, and the upper lids pulled downwards as far as possible over the lower lid. The eyebrow was then

closely shaved, and an incision was made from the middle of the eyebrow outwards, following the line of the supra-orbital margin for the distance of an inch and a half, through the skin and subcutaneous tissue. The tarso-orbital fascia was then divided, care being taken not to wound the tendon of the levator palpebræ muscle. As soon as the orbital cavity was opened, and some of the orbital fat pushed aside, the tumor was seen to involve the lachrymal gland. By the aid of the handle of the scalpel and a pair of blunt-pointed scissors, the adhesions between the growth and the upper and outer walls of the orbit were carefully divided, no very firm points of adhesion being found. The attachments of the tumor to the eyeball were then easily separated, care being taken to dissect off as much of the ocular conjunctiva from the external face of the tumor as was possible, and the enlarged gland was then removed entire. There was considerable hemorrhage from the divided vessels, which, however, soon ceased, and the cavity was then carefully washed out with a solution of mercuric corrosive chloride (1–1000). Six deep sutures were then introduced through the entire thickness of the lips of the wound, including the tarso-orbital fascia, and as many more through the external lips of the wound as were necessary to bring the edges into thorough coaptation. Sublimate dressings and a bandage were then applied. The wound healed by first intention, and there was no suppuration, and in three weeks all signs of tumor or operation had disappeared. The tumor was hardened in Müller's fluid and alcohol, and numerous sections were made and carefully stained for future study. These showed that the degeneration had begun near the center of the gland, for here nearly all traces of the normal glandular structure were absent. It was impossible, however, to determine whether the abnormal growth began in the ependyma of the glandular tubules or in the connective tissue around them. If it be true, as Berlin thinks, that all adenoid tumors belong to the common type of cylindroma, then the tumor in question was a cylindroma. Away from the center and near the periphery of the gland there were found many tubules in a healthy state; but even in the midst of these normal tubules were others in a distinct condition of hypertrophy, with numerous small round

cells interspersed. In all parts of the growth the connective tissue framework was crowded with small round cells, and as the section neared the center of the gland these cells became more and more numerous until all the glandular elements were crowded out and disappeared, and nothing was visible but a closely-pressed mass of small round cells, in place of glandular tissue. After a careful examination had been made of the various sections, the patient was told that the growth would in all probability return, and that he must report at intervals for examination. The tumor was removed in June, 1887, and the patient has been seen at intervals of two or three months ever since, — the last time in March of this year, at which visit nothing abnormal was discovered in the orbit or eyelids. I have termed the growth an adeno-sarcoma of the lachrymal gland, as being most in consonance with the results of the microscopic examination.

CASE II. — *Abscess of the Ethmoid Cells, Frontal Sinus, and Orbit.* The patient, a gentleman aged 46, consulted me April 16, 1888, with the following history: He had been long subject to naso-pharyngeal catarrh, with frequent acute exacerbations and profuse discharge, and he had been under treatment of one kind or another for many years. About Christmas of 1887 he had first noticed a swelling at the upper and inner angle of the right orbit, though he had had a constant dull pain in this vicinity for more than a year. The swelling continued to slowly increase without much change in the subjective symptoms until March, when he began to see double. At this time his headache was constant, and being alarmed he consulted his family physician, who made an examination and discovered that with either eye alone his vision was perfect, but that the diplopia and consequent disturbance of vision returned when both eyes were open. Tincture of iodine was painted over the swelling of the lid, and potassium iodide was given internally, but without producing any beneficial effect, and he was finally advised to consult me, which he did on April 16, 1888. I found a rather marked protrusion of the inner half of the right upper lid, and a dislocation of the right eye outwards and downwards and a little forward. The motility of the eye inwards and up-

wards was somewhat limited. The lids were normal in action. Vision was $\frac{20}{20}$+ and the media and fundus and field of vision were perfectly normal in every respect. The tumor or swelling was smooth, elastic, irregularly ovoid in shape, and extended backwards some distance into the orbit. It occupied the supero-internal angle and inner wall of the orbit. It was painless on pressure and showed no signs of any inflammatory process. There was a profuse, almost purulent discharge from the right nostril. A hypodermic needle was introduced through the skin of the lid and pus was withdrawn from the cavity. A diagnosis was then made of abscess of the frontal sinus, which had probably broken through the bony roof of the orbit, and involved the latter cavity. The patient was told that nothing but operative interference would be of any use, and he consented at once to have the operation done. On April 18th the right eyebrow was shaved, and a long incision was made through all the tissues down to the bone, beginning at a point at the junction of the middle and outer thirds of the eyebrow and running parallel to and just above the supra-orbital margin, across the root of the nose to the inner end of the eyebrow on the opposite side. As soon as the knife penetrated the region of the swelling, it was followed by a flow of pus amounting to about half an ounce, as nearly as could be calculated. As soon as the incision was completed, the knife was withdrawn and the finger introduced. A large irregular hole was felt just at the inner end of the supra-orbital margin, extending into the frontal sinus, and involving part of the lachrymal bone. Pressure on the closed lids backwards caused pus to run from the incision, and the finger pushed into the orbital cavity discovered that the abscess extended backwards into the orbit and that there was an opening in the orbital plate of the ethmoid bone, large enough to admit the end of the middle finger. The walls of the frontal sinus were distended in all directions, and were rough and covered with numerous osteophyte; but the bony wall between the frontal sinuses did not appear to be perforated. The frontal sinus was first washed out with a sublimate solution (1–500), bringing away much pus and small particles of bone, and after a brief period the fluid was observed to drop

from the right nostril, showing that a communication existed between the frontal sinus and the superior nasal meatus on this side. The same solution was then used to wash out the cavity of the abscess in the orbit and also the ethmoid cells, and this also brought away a large quantity of pus. After the entire cavity had been thoroughly cleansed, a rubber drainage tube was introduced into the frontal sinus, and the rest of the external wound kept open by pledgets of sublimated cotton, and the patient was made to lie on his right side. The lids were kept closed and covered by a piece of gold-beater's skin, in order to prevent as far as possible any entrance of the purulent discharge into the conjunctival cul-de-sac. The cavity was washed out twice a day with the sublimate solution until the discharge of pus grew very scanty, and then the irrigation was practiced once a day until all purulent discharge had ceased. The drainage tube was finally removed at the end of the third week, at which time all external swelling of the surrounding parts had disappeared, the flow of pus was reduced to a few drops, the eyeball had returned to its normal position, and the diplopia had vanished. At the end of the third month the cavity in the orbit had closed, and shortly afterwards the external wound along the orbital margin filled up with granulations, which first appeared from the edges of the opening into the frontal sinus, and gradually the external wound healed under a scab. At the end of the fourth month, close observation was needed to discover that an operation had been performed. For about two months previously systematic treatment of the nasal cavities had been carried out, with the result of checking all discharge from the nostrils and converting the patient from the condition of a mouth-breather to a condition of normal respiration. The patient has not been troubled since. This is one of quite a number of cases operated upon in a similar manner, which have all recovered in a comparatively short time, and without any bad results.

CASE III. — *Tumor of the Maxillary Antrum, Nasal Fossæ, Ethmoid Cells, Orbit, and Cranial Cavity.* The patient, James McK., aged 51, first consulted me on November 11, 1887, and gave the following history: He had always been subject to pro-

fuse naso-pharyngeal catarrh, which had been treated in an intermittent and spasmodic manner for a number of years. In February, 1887, he began to suffer from shooting pains in the left side of the nose, and along the course of the left supra-orbital and infra-orbital nerves, and as the weeks elapsed this pain increased in severity and began to be localized in the left orbit. In April there appeared a profuse purulent discharge from the left nostril and from the pharynx. The pain continued to increase in severity, and early in August the left eye began to protrude from the orbit. The ocular conjunctiva gradually became injected, and the eyelids, particularly the lower lid, became swollen. He at this time consulted Dr. E. G. Janeway of New York, who, after a careful examination, told him that he had a tumor in the left orbit. The symptoms gradually grew worse, and early in October the exophthalmus was so marked that he could scarcely close the lids over the eyeball, and his vision began to be impaired. On November 11th, when I first saw him, his condition was as follows: the left eye protruded forwards, outwards, and downwards, and the lids could not be closed over it. The cornea was clear, the lower lid was everted and partially concealed beneath the protruding globe; the ocular conjunctiva was markedly congested, and the chemosis very extensive. The eye was absolutely immovable. The pupil was widely dilated and immovable. Vision was $\frac{20}{100}$, that of the other eye being normal. The ophthalmoscope showed a well-marked condition of "choked disc" with hemorrhages. A protrusion of the growth could be seen at the inner wall of the orbit anteriorly, and an examination with the finger demonstrated that the tumor could be felt at the inner canthus and backwards along the inner wall and floor of the orbit. A careful examination of the anterior and posterior nares showed that the left inferior nasal meatus was entirely occluded by a growth, and it was thought that the latter also extended into the middle nasal meatus. The occlusion of the inferior meatus was caused by the bones being pushed down from above by the growth, this being the opinion of both Drs. Lefferts and Asch, who kindly examined the case with me. The patient was then sent for a further examination to Dr. Wm. T. Bull, who diagnosed a tumor

of the antrum, nasal meatus, and orbit, and advised non-interference, by reason of the probability that the growth involved the deep bones of the face.

The pain was now so severe that the patient had to be kept under the influence of opiates. By December 3d the eye had become entirely blind, and the protrusion forward of the growth was very marked. It was decided to attempt the partial removal of the tumor, as a means of affording the patient some relief from his suffering. On December 5th the eye was enucleated under ether and with considerable difficulty, and then complete exenteration of the contents of the orbit was begun. The conjunctiva was divided along the margins of the lids, and the entire contents of the orbit were removed by knife and scissors. The bony floor of the orbit was entirely absent as far back as the apex of the orbit, except a narrow rim along the anterior margin. The maxillary antrum was filled with the growth, and was entirely cleaned out with forceps and curette. The opening from the antrum into the nasal meatus was found enormously enlarged, and the left side of the nose was filled with the growth. Part of the lachrymal bone and the entire orbital plate of the ethmoid were gone, and the ethmoid cells were filled with the growth. There was a large, ragged opening through the roof of the orbit into the anterior fossa of the skull, and through this the growth also protruded. All operative procedures were then stopped, the cavities of the orbit, maxillary sinus, and nasal meatus carefully washed out with a solution of mercuric bichloride (1–2000), and antiseptic dressings applied. There was no unusual amount of blood lost during the operation. On recovering from the effects of the anæsthetic, the patient complained of great pain in the head, which was relieved by morphia. He remained fairly comfortable until about 9.30 P. M. of December 6th, when his breathing suddenly became stertorous, and he was found comatose. In a few minutes the respiration became Cheyne-Stokes in character, but this yielded to hypodermic injections of strychnia. The patient died quietly in a comatose state at 7 A. M., December 7th, with regular respiration. Unfortunately no autopsy was allowed.

The tumor was carefully hardened in Müller's fluid for about

two months, and numerous sections were then made through various parts of the growth, special care being devoted to the growth removed from the maxillary sinus. At first there was considerable difficulty experienced in classifying the tumor, as the sections seemed to be made up of nothing but cells. Of these there were all kinds, round, ovoid, stellate, and fusiform, the small round cells largely predominating. There was a very scanty fibrillar, intercellular substance, and the general consistency of the growth at the time of its removal was decidedly soft or medullary. This was particularly true of the mass removed from the maxillary antrum. The growth in the orbit and ethmoid cells was decidedly myxo-sarcomatous in character, and a careful study of sections from all parts of the tumor finally led me to class it as a myxo-sarcoma. In some places in both the orbital and maxillary growths there were small cavities, filled in the fresh state with a yellowish fluid, which gave to the part the character of a cysto-sarcoma.

In all probability the disease started in the maxillary antrum, possibly as the result of long-continued irritation and inflammation extending from the chronic naso-pharyngitis, and thence growing in every direction inwards to the middle and superior nasal meatus, and thence into the cavity of the ethmoid bone, and upwards through the orbital plate of the maxillary bone into the orbit. The absorption of a part of the roof of the orbit, and the extension of the growth into the anterior fossa of the skull, was probably the latest stage of the disease. The direction of the growth inwards would of course make the extension outwards through the opening of the orbit a slow and protracted process, as was proved in this case, the exophthalmos having been one of the later symptoms. Still it is the general opinion among surgeons that growths originating in cavities near the orbit, and involving the latter secondarily, are generally of very rapid growth. In the case in question, all the subjective symptoms occurred within ten months of the death of the patient.

DISCUSSION.

DR. H. KNAPP, New York.—These tumors, especially the last, are among the most frightful. I remember one case of the same kind in which the growth had evidently originated in the nasal fossa as a polypoid growth, and the man had been operated on sixteen times before he consulted me. The growth afterwards penetrated almost all of the cavities, and breathing was interfered with. I operated and removed immense quantities of the growth, but it extended into the sphenoid cells and the frontal sinuses and dipped into the cranial cavity, where I stopped. The patient was rendered comfortable, and died six months later. I remember several other cases on which I operated. It is difficult to know what to advise. In another fatal case I found polypoid tumors which became sarcomatous in all of these cavities.

Another group of cases of which the doctor had an example is that of empyema, especially of the ethmoid cells. One of these cases came to me last winter for operation. There was exophthalmos and diplopia, and the trouble had lasted for a number of years. The patient was a young lady with some nasal obstruction. A tumor protruded into the orbit about the inner canthus. It was doubtful whether it was an osteoma or an empyema. I made a diagnosis of probable empyema. I did not make an exploratory puncture, because I did not think that would change the method of operation. It proved to be an empyema involving the ethmoid cells and protruding anteriorly. I made a free opening in the anterior wall, put in a spoon, and evacuated what was in the cavity. The cavity was singularly free from caries and from polypoid and other growths. I carefully syringed it, and united the edges of the wound with silk sutures, and put in a silver drain. This healed by first intention, and in about a week the patient was discharged from the hospital. It is now over a year since the operation. I saw her a short time ago and there has been no relapse. This is the only case that I have had in which such a condition healed without further treatment. In other cases, I have been compelled to continue the treatment for months. I think that this depends upon the quality of the cavity. If the case is a chronic one with marked caries, it will last until all the particles have been discharged. These tumors in or near the orbit should be attacked as soon as we make the diagnosis. This is especially true of osteoma of the frontal sinus.

DR. W. F. MITTENDORF, New York.—I cannot too strongly emphasize the importance of early interference in abscess of the frontal sinus. I remember distinctly a gentleman who came

with intense exophthalmos. The process had been allowed to go on until the cornea had been entirely destroyed. Early interference might have saved the eye. In this case I succeeded in relieving the patient entirely of his unpleasant symptoms in four or five weeks.

DR. B ALEXANDER RANDALL, Philadelphia — I have been much interested in the paper, and I should like to obtain some information in regard to a case, possibly of kindred nature, which has greatly interested me. The patient is a young man whose first symptom was pain which was supposed to be due to catarrhal trouble. He then developed ptosis, with paralysis of the superior rectus, marked protophthalmos, chemosis of the conjunctiva, and swollen veins. There apparently was trouble at the base of the orbit. He was put on mercurial inunctions with the use of mercury internally. The mydriasis which had been present yielded within a week and gave place to paresis of the external rectus. This, too, gradually passed away. There was paresis, but never total, of the internal rectus of the left eye at the same time that the paresis of the externus of the right eye came on. This then yielded, the left first and the right soon after. The inferior rectus then became paralyzed and so remains. There is a dense brawny swelling of the lids as though in the first stage of a large stye. This has gradually increased until his right lid, without any paralysis of the levator, is down over the eye and he cannot raise it.

I have searched for nasal trouble, for frontal sinus trouble, and evidence of anything more than syphilitic periostitis at the base of both orbits. He denies all possibility of syphilitic infection, but that has not great weight. I may also mention that he has aphonia, due, not to paralysis of the vocal cords, but to this same brawny swelling of both vocal cords and ventricular cords, as is seen in the lids. The condition has persisted for five or six weeks. There is a little renal trouble; no albumen, but casts. There are no other general lesions. This case has interested and bothered me a great deal. It is a curious one, which might perhaps not inappropriately be mentioned in this connection.

DR. R. A. REEVE, Toronto.— Two years ago, in a paper referring to twelve cases of inflammation of the frontal sinus on which I had operated, attention was called to a point of some importance in the etiology and prophylaxis In four of them nasal catarrh was the apparent cause. And in two additional cases there was marked hypertrophy of the tissues on the middle turbinate.

CASE OF DOUBLE CHOKED DISC, DUE TO INTRACRANIAL TUMOR, WITH AUTOPSY.

BY CHARLES STEDMAN BULL, M.D.,
NEW YORK.

A YOUNG married lady, aged 23, was brought to me on June 30, 1888, with the following history: In August, 1887, ten months before, she had been delivered at full term of a healthy female child. There was nothing abnormal in the confinement, and she recovered rapidly. She was apparently in her usual health until February, 1888, when she had a miscarriage at the sixth week, and was seriously ill for a couple of weeks, complaining of a dull headache at the vertex. In the latter part of March or first of April, the headaches became somewhat more severe and more frequent, being located always at the vertex, but there were days when she did not complain of any pain in the head. During April there were occasional attacks of diplopia, of what nature it is impossible to say. During the last of May she complained at times of failing vision, and the headaches became more severe, but the diplopia disappeared, and did not again return. I first saw her on June 30th, and a careful examination gave the following results: V. $= \frac{18}{20}$ — in each eye, with normal accommodation, and an ability to read Jaeger No. 1 at five inches. For 18 inches, Adduction, 26°, Abduction, 6°. For 18 feet, Adduction of 18°, Abduction of 4°. The media were perfectly clear. There was no peripheral limitation of the field of vision either for form or color in either eye, but there was an irregular negative central scotoma for all colors, within the limits of which the color sense for all colors was blunted, though there was no positive color-blindness. The refraction of both eyes towards the periphery was slightly hypermetropic. The ophthalmoscope showed a very marked exudative neuro-retinitis with hemorrhages in both eyes, perhaps the most pronounced type of "choked disc" which I have ever seen. The papillae were enormously swollen, and the infiltra-

tion extended into the retinae in all directions, as far as and involving the region of the macula. The refraction of the head of the disc was + D 12. The hemorrhages were of the most varied character; punctate, linear, flame-shaped, and serrated, and were scattered not only on the discs, but all over the fundus. The urine on examination proved normal in every respect, both chemically and microscopically. At this time the only symptoms pointing to the presence of intracranial disease were the lesion of the optic nerve and the headache at the vertex. There was no loss of power in upper or lower extremities and no loss of sensation anywhere in the body. The functions of the body were all properly performed, though the appetite was somewhat impaired. A diagnosis was made of intracranial tumor, probably sarcoma or gliosarcoma, at the base of the brain, and probably involving the region of the infundibulum, and possibly extending forward to the region of the optic chiasm. This the autopsy subsequently proved to be partly right and partly wrong. The patient was kept under constant observation, and was seen in consultation by several eminent gentlemen of New York and other cities during the next few months. All agreed in regarding the case as one of cerebral tumor, and all located the growth in very nearly the same position. One of the gentlemen consulted advanced the opinion that the growth was either tuberculous or a gummatous infiltration, but it seemed to me that the existence of a syphilitic growth might be entirely excluded. Vision remained practically unchanged until the latter part of July, when it began to diminish somewhat rapidly, and by September 25th there was no perception of light, and from this time till her death on May 5, 1889, there was total blindness. During the month of July a loss of memory began to manifest itself, and a partial loss of the sense of smell. By the latter part of August the mental faculties had become so impaired that her memory was practically gone, and she became incapable of any continued conversation. Early in July right hemianæsthesia appeared, beginning in the hand and arm and subsequently extending to the foot and leg, so that she was unable to walk without assistance. The anosmia became complete during the early autumn. The exudation into the optic nerves

and retinae became more and more marked at each examination, and the hemorrhages into the retinae recurred again and again. The patches of yellow exudation in the region of the macula strongly resembled those met with in retinitis albuminurica, though without the stellate arrangement. The urine was carefully examined every week, but never showed a trace of either albumen or casts. The headaches were at no time very severe and gradually ceased towards the end of September, 1888. The evidences of dementia, however, gradually increased, and for a period of about three months previous to her death the dementia was practically complete.

Autopsy, May 6, 1889. The calvarium was not adherent, and the diploë was normal. The dura mater was normal and not especially tense. The convolutions on top were flattened and dry, the flattening being more marked in the frontal lobes. When the infundibulum was cut, a strong stream of cerebrospinal fluid escaped with force, like a stream of blood from a divided artery. On the basal aspect of the brain, the olfactory bulbs were entirely gone, and the olfactory nerves were thin, flattened, and reduced to the neurilemma. The frontal edge and basal surface of the optic chiasm were apparently normal. The chiasm was bounded caudad by the enlarged and fluctuating infundibulum or base of the third ventricle. The third nerves were normal. The left fifth nerve was torn off. The right fifth nerve was unusually far back, and at a very abnormal distance from the median line. The sixth nerves were normal. The pyramids were flattened. The pons was normal. The arteries at the base of the brain were normal. In the intrapeduncular space there was a bladder-like distension of arachnoid, 20 × 10 millimetres, filled with fluid coming from the ventricle. The convolutions at the base of the hemispheres and in the cerebellum were normal. The fissure of Sylvius was normal. The foramen of Munro was enormous. On lifting the corpus callosum and fornix, and exposing the third ventricle and basal ganglia, a tumor was revealed, involving the corpora quadrigemina, extending caudad to the anterior crura of the cerebellum; the larger part, nodulated, 30 millimeters across in both directions, and extending into the left hemisphere, and involving

the thalamus and internal capsule. The prolongation of the growth extended caudad from the thalamus towards the left occipital gyri for a distance of 15 millimeters. The anterior corpora quadrigemina were like bulbous projections dislocated forwards. The ventricles were enormously distended. The corpora striata were normal. There was no evidence of growth in the right thalamus. The tumor appeared to be a gliosarcoma involving the region of the pineal gland, and invading the left thalamus and posterior division of the left internal capsule.

SPASTIC TORTICOLLIS, APPARENTLY DUE TO FAULTY POSITION OF THE EYES, AND CURED BY TENOTOMY.

BY DR. O. F. WADSWORTH,
BOSTON.

CARL F., a bright, intelligent boy, nearly 14 years old, of good size, and with well-shaped head, was brought to me June 5, 1887, because of a deformity which was said to have commenced in infancy and to have been becoming more pronounced up to that time. On the supposition that he had wry-neck and lateral spinal curvature he had been first taken to Dr. E. H. Bradford. Dr. Bradford found no permanent contraction of the muscles of the neck, and that, while there was a well-marked convexity of the spine toward the left, the vertebræ were apparently normal. He also observed that the eyes were not directed properly, and advised that the boy be taken to me.

The brief history of the case, obtained mainly from the boy's father, was as follows: In early infancy it was noticed that the boy's eyes were "wild," and that the left eye rolled up; at least as early as when he began to walk the head was held tipped to the right, and as he grew older the right shoulder dropped. Of late years the eyes had not been so "wild," but appeared more so when he was excited. He had never had double vision. The tipping of the head and dropping of the shoulder had grad-

ually grown worse, and of late the remarks of his schoolmates on his figure had caused him much annoyance.

The boy was well grown, his muscular system well developed. He sat or stood with his head tipped to the right, his face turned a little to the right and inclined considerably forward, his right shoulder considerably lower than the left, the spine laterally curved with convexity to the left. (Fig. I.) In walking the left shoulder was carried a little in front. The excursion of each eye was good in all directions. In ordinary positions, with fixation for near or distance the left eye stood about 1''' higher than the other. Only when the eyes were turned strongly down and to the left, while at the same time the head was inclined forward and to the right, and rotated a little to the right, did he apparently get binocular fixation; even in this position the left eye rolled up when it was covered, and on being uncovered again did not instantly come back to fixation. In this position it was impossible to use the stereoscope; in other positions he could see the two images at once (L and F, for instance,) but could not unite them; the images were homonymous, the right always higher. He also apparently fixed binocularly with his head nearly in the normal position when prisms amounting together to 20°–25° were placed before the eyes, base down L, base up R. V., R. or L. $\frac{14}{12}$. Fundus normal in both eyes.

On June 10th, further attempts were made to obtain stereoscopic vision, without avail; L. and F. could be brought to a level with vertical prisms amounting to 18°, but not united. V. under homatropine, R. or L. with +.75, $\frac{14}{12}$+.

July 14th, with cocaine, the superior rectus tendon of the left eye was partially divided, but the boy became very restless, and the operation could not be completed. Although I thought a fairly wide division had been made, there was no perceptible effect on the position of the eye.

August 12th, another attempt at division of the same tendon was made with cocaine, the boy being unwilling to take ether and assuring me that he would be quiet. This time he became unruly still earlier, and the operation was again abandoned.

October 22d, the boy's condition was the same as in June. Under ether, the left superior rectus tendon, which was large and broad, was fully divided.

November 17th. The boy and his father report that he has been much straighter ever since the last operation, and is still improving. Both his head and trunk have a very greatly better position. The left eye now turns down as far as the right, not quite so far up. The eyes usually appear straight, but when the left is covered, in most positions at least, the right seems to move downward a little to fix, and *vice versa.* He cannot unite in the stereoscope.

December 9, 1888. He has grown much during the past year. His figure is now almost normal, but the right shoulder is still slightly lower than the left, and the head is very slightly

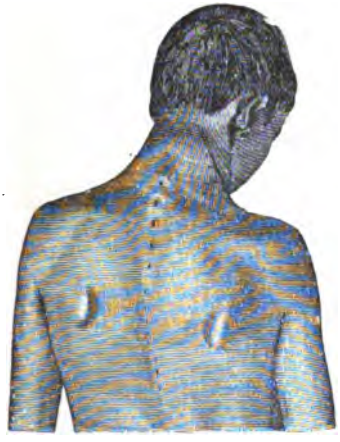

FIG. 1.

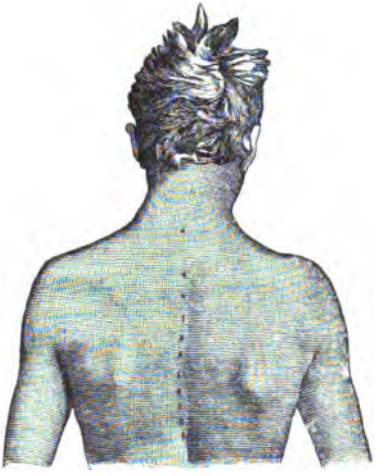

FIG. 2.

tipped. (Fig. 2.) He has never had double vision or asthenopia. V., R. with +.50 cyl. $\frac{14}{12}$; L. with +50 $\frac{14}{12}$. When he fixes in the median line, in or a little below the horizontal plane, on covering the right eye it appears to turn upward a very little, and when the left eye is afterward covered in turn to turn downward again to fix; if the left eye is covered first, the right does not appear to change. Double images of a flame at 14′ are not perceived even with the help of red glass and prism. In the stereoscope L. and F. are united with difficulty.

It would seem *prima facie* an almost incredible supposition that with never a sign of double vision or asthenopia a faulty

position of the eyes should cause so pronounced and persistent a distortion as in this case, particularly when the distortion did not enable the individual to obtain binocular fixation for the vastly greater part of the time. Yet the fact that the distortion did to all appearance render binocular fixation possible in one position of the object led me, in the absence of other discoverable cause, to think this supposition probable. It is within the bounds of possibility also that in earlier life the twisted posture gave binocular fixation over a wider area, and therefore for a larger part of the time, and that the posture once become habitual, occasional binocular fixation only was needed to maintain it in permanency. The rapid improvement that took place after tenotomy appears to sufficiently confirm the correctness of the theory.

It has been suggested to me that the vigorous growth of the boy during the year after the tenotomy was one, perhaps the most, active factor in the change that occurred. I should be far from denying that the growth had been a helpful influence. To suppose it more than a subsidiary one, however, is to neglect the consideration that during the four and a half months that elapsed between the time the boy was first seen and the tenotomy there was no discoverable improvement, while during the first month after tenotomy the improvement was very marked.

The objection might also be made that it was not the actual changed relation of the eyes, but the moral effect of the operation that produced the desired result. But certainly the incomplete operations under cocaine, which did not alter the position of the eyes, should have had even greater moral effect than the operation under ether, and yet they left the condition absolutely unchanged.

DISCUSSION.

Dr. S. D. RISLEY, Philadelphia. — I have been much interested in this report, since I have had the opportunity of studying three similar cases, and do not know of any recorded case. The first was seen in 1880, age 15, a stalwart lad, the son of a physician. The head was carried strongly to the left side, both in reading and walking, but could be readily and voluntarily brought to the upright position. Notwithstanding this fact, a

general surgeon had advised a tenotomy of the muscles of the neck. The boy volunteered the statement that when he held his head erect his vision was impaired. His father therefore brought him for advice about the eye trouble. In the habitual position the lad enjoyed binocular vision-sharpness 20/xx, while in the erect posture the letters were confused by vertical diplopia, which was, however, corrected at twenty feet by a three degrees prism, placed with its base down over the right eye, and V. = 20/xx. The refraction was for O. D. H = 1 D., O. S. H. As. = + .50 ⌒ + .50 cy. ax. 90°. A tenotomy — complete — of the right superior rectus was done under ether, assisted by Dr. Randall and the boy's father. The result was to relieve the faulty position in which the head was habitually carried for several years. He was placed as accountant in a badly-lighted counting room, in 1887, and soon developed asthenopia and a return of the faulty posture, but allowed a year or more to pass without seeking advice. I then found not only a return of the former conditions, but a marked lateral curvature of the spine. A complete tenotomy of the left inferior rectus was done, and subsequently a second division of the right superior rectus, which, together with a correcting glass, relieved the asthenopia, but did not affect the ungraceful carriage which was now produced by the permanent deviation of the spine.

In the other cases, one was relieved by prismatic glasses without operation both from the faulty posture and the asthenopia, the other by a double tenotomy and the subsequent use of weak prisms. It had not occurred to me, however, to place these cases in the category of torticollis.

Dr. O. F. WADSWORTH, Boston. — I do not know that I was distinctly understood. One point of importance in my case is that there were at no time any asthenopic symptoms. The boy was at school and had experienced no trouble in doing his work. It was his physical appearance that took him to a physician.

PARTIAL TENOTOMIES IN CASES OF NEURASTHENIA, WITH INSUFFICIENCIES OF THE OCULAR MUSCLES.

BY MYLES STANDISH, M.D.

BOSTON, MASS.

THE ordinary symptoms of an error of refraction are well known, and are grouped under the descriptive title of Asthenopia; they consist of blurring of print, smarting of the lids, pain in the eyes and orbits, a heavy, dull pain in the temples or over the brows, and are often accompanied by occasional prostrating sick-headaches. All of these symptoms are aggravated upon any attempt to do near work, and some are relieved by the cessation of such work. There is no mistaking the cause of such a group of symptoms. The act of accommodation is evidently the source of the difficulty.

In an ordinary case of asthenopia, with all the symptoms present, the diagnosis, as I have said, is easy; but when the headache becomes very prominent, and the other symptoms are very slightly felt, or are not present at all, and especially when the headache does not appear until some hours after the use of the eyes, which has originated the nervous disturbance, then the diagnosis is not so apparent. To this class belong the large majority of school-children who have violent sick-headaches at frequent intervals; the many professional men who find it necessary to drop all work, and go off on short vacations every few months, and who return from such short trips with an improvement in mental and physical conditions which seems out of all proportion to the length of the vacation. To this class also belongs the business-man who spends his Sundays reading books and newspapers, and who invariably has a headache Monday morning. Herein lies the value of the change of scene, so advantageously prescribed by physicians in cases of physical depression of obscure origin. I believe that mere change of scene never improved a man who habitually led an out-of-door life.

As I have implied above, refractive headaches bring in their train great impairment of mental and physical vigor. The dull, heavy pain in the head, accompanied as it generally is by a constant sense of fullness, is, in itself, very depressing; and when to this is added the occasional sick-headache, the result is a feeling of lassitude which is never absent so long as the use of the eyes is continually adding to that load already too great for the nervous system to carry.

Headaches and neurasthenic conditions are often much mitigated by the correction of errors of refraction when the starting-point of the reflex process is not in the eyes, but in the digestive or reproductive tract. In these cases the relief from the additional nervous irritation, caused by the strain upon the ciliary muscle and its auxiliaries, will reduce the severity of an habitually prostrating sick-headache to a so much milder form of cephalalgia that the patient can go about and attend to his duties. The relief from the physical depression consequent upon such repeated prostrations may go far toward making successful the treatment of the original cause possible.

The treatment of an error of refraction is, of course, to place before the eye such a lens as will enable it to do its work with no more labor than would be required by a normal eye. The effect of such a lens is often marvelous. As soon as the eyes become accustomed to the new conditions, the headaches disappear entirely, together with irritability, choreic-like movements of the hands or head, and many obscure sensations and pains, previously referred to various causes. The patient, from being very nearly an invalid, is transformed into a well man, and is enabled to do his daily task with but a tithe of the accustomed fatigue. He is enabled to go to the theater without paying the penalty of a headache the following morning, although the headache had always been attributed to the bad air of the theater. He finds that he can do with impunity many other things which before always exhausted him, such as traveling on the railroad, visiting picture-galleries, etc. In short, he finds his general vigor and health much improved. In order to do away with the refractive strain in these neurasthenic cases, it is absolutely necessary that the correction of the error should be

perfect, and that the lenses should be set in the frames with mathematical accuracy. If an incorrect lens is prescribed, or a cylindrical lens is set so that the axis is not correct, we have created an artificial astigmatism which is, when the glasses are worn for any length of time, as disastrous as the original error; although I have seen an incorrect lens give relief, apparently through doing away with the accustomed form of irritation, and to continue to so give relief until the cumulative effect of the fatigue from the new source of error was sufficient to develop the whole train of symptoms anew.

There is a certain class of cases in which the use of the eyes seems to stand as the direct cause of extraordinarily severe headaches, frequently accompanied by a condition of nervous prostration which utterly unfits its victims for the duties of life, yet when the errors of refraction are corrected only partial relief is obtained, and that not enough to be of material benefit. The direct relationship between the use of the eyes for near work and the most tremendous outbreaks of cephalalgia and general nervous disturbance would seem to point to the eyes as in some way the direct precipitating cause, yet, as I have said, correction of refraction in the most careful manner utterly fails to give the relief we expect.

This class of cases is explained of late by attributing the cause to eye strain arising from an insufficiency of one or more of the recti muscles. This explanation has, *a priori*, many arguments in its favor. It is but natural to suppose that in the case of any abnormality in the strength of the recti muscles there should be as much difficulty and fatigue experienced in maintaining binocular vision as there is in keeping the eyes constantly accommodated for distant vision in an error of refraction. The ciliary muscle and the recti muscles have to a great extent the same nerve supply, and it would seem that a reflex irritation would be as easily obtained from one source as the other. The confusing effect of slight diplopia associated as it is with ocular vertigo is well known.

Although this source of reflex irritation would seem so probable, but very little has been done by ophthalmologists for the treatment of these difficiencies of the ocular muscles. An oc-

casional pair of prisms has been ordered and their continual use has generally proved unsatisfactory, or at rare intervals a tenotomy of the overbalancing muscle has been performed. As a rule, however, no treatment for the inequality of the muscular balance has been attempted. Within a few years Dr. G. T. Stevens has proposed that as prisms did not accomplish the hoped-for result in these cases, it was logical and proper to adopt operative interference, and proposed an operation similar in character and method to a strabismus operation, with the exception that the tendon of the overbalancing muscle was only partially severed from the globe, and the portion cut was only the central portion of the insertion, leaving the outer edges of the tendon intact.

The results obtained by this operation have been loudly extolled by Dr. Stevens and a few enthusiastic followers. It has been claimed by them that the eye strain in cases of illy balanced ocular muscles was responsible to a very large extent for all varieties of functional nervous disturbance. Not only were severe headaches and neurasthenia cured by this operation, but also neuralgia, chorea, epilepsy, and insanity. One writer in a recently published work on nervous diseases goes so far as to credit this operation with the cure of a case of chronic dyspepsia. The extravagance of these claims has undoubtedly prejudiced many gentlemen against the operation, and as a result, this method of treatment has not been generally accepted. Many have urged theoretical reasons why this particular form of operation should not accomplish the mechanical result desired, but as yet very few have actually tried the operation and reported the results.

In this state of affairs the question can only be settled by the public record of the experiences of different operators, and that is my reason for reporting this short series of cases.

With cases of chorea, epilepsy, insanity, dyspepsia, etc., I have had no experience. My patients have all been persons invalided by constant and severe headache, accompanied by a more or less neurasthenic condition which has utterly incapacitated them for their duties in life. The condition of such patients is truly deplorable, the victims of a constant dragging

headache which increases to intolerable torture if they stir abroad or use their eyes for reading or any near work at home. They retire at night greatly fatigued, and arise in the morning with an aching head and burning eyes. This condition of affairs goes on for years, and the patient becomes a petulant, peevish, suffering invalid. Every practitioner of medicine has sooner or later found himself utterly helpless in the face of such a situation, and if it is possible by the relief of the strain caused by unbalanced ocular muscles to so lighten the load of nervous irritation, under which the patient is struggling, as to give him a practical cure of his asthenopia and neurasthenia, it is a possibility that should be thoroughly investigated.

It is true that very many such cases are entirely cured by the proper correction of errors of refraction, but a certain proportion of cases are relieved only for a short time by the lenses, and if tested will be found to have marked ocular insufficiencies.

The methods of examination as yet devised for the examination of the recti muscles are rather crude and inaccurate. The methods are two: —

First. In examining for the condition of the internal and external recti, for instance, a vertical diplopia is artificially produced by placing a prism before one eye with its base up. A lighted candle is placed at twenty feet in a darkened room. Then if one image of the candle flame is directly over the other the muscles are said to balance, but if there is a lateral displacement there is said to be an insufficiency. A similar test with a prism base in gives the balance of the superior and inferior recti. The measure of the amount of the insufficiency is obtained by placing prisms with their bases at right angles to that of the prism producing the diplopia, and recording the number of degrees required to place one image over the other. The variation at successive examinations in the number of degrees required to make the diplopia vertical in this test is sometimes very great. This is no doubt partly due to inherent difficulties in the method of examination which produce faulty observations, but I am sure that it is to a greater extent due to the physical condition of the patient at the time of the examination. If fatigued and exhausted a greater amount of insufficiency will be

manifested than if the head is clear and the physical condition good.

Second. The practical strength of the muscles to fuse diplopic images into one, when such images are artificially produced, by placing a prism before the eyes with the base up or down, or in or out.

Theoretically one would suppose that these two tests would supplement and confirm each other, but practically I have often found this not to be the case at any single sitting. In fact, the results of these examinations of the ocular muscles are often exceedingly confusing, and vary greatly from day to day. It is customary to explain this variation by saying that the patient acquires the trick, after a while, of using his muscles under these new conditions, and so the different results are simply a record of the proficiency acquired in this new form of gymnastics. This explanation is to a certain extent true, and accounts, no doubt, for the much higher result obtained by the second method of examination after it had been repeated several times. It fails, however, to explain all the variations obtained, especially the results obtained by the first method of examination.

Recognizing the difficulties of accurate diagnosis by these methods of examination, it has been my practice to order prisms with the base in the proper direction, to alleviate any strain that might be present from the supposed insufficiency as shown by these tests; to have them worn continuously for a longer or shorter period and see if any alleviation of the symptoms followed. I have a number of times confirmed myself in my opinion by reversing the prisms, and finding that with this change the symptoms were aggravated.

With these introductory remarks I will now report five cases which I have abstracted from my records, and which constitute the entire number of such cases upon which I have operated.

CASE I. — First seen by me August 11, 1887. B. H. R., clergyman, thirty-one years of age. A man of healthy appearance and robust stature. Has had asthenopia for six or seven years and has been treated by several gentlemen distinguished in the profession. Glasses, Dyer's method of progressive use of eyes, etc., have been prescribed without relief. The last two

years the headache from the use of eyes has increased so that he has been obliged to give up all reading, and now the least excitement prostrates him with a headache. He cannot go down town, ride in the horse cars, or make a social call, except in the dark, without precipitating a violent headache. Has been obliged to give up his duties on account of his infirmity, and for eighteen months has been almost an invalid. Cannot read over two pages without being obliged to stop on account of the pain. V. o. u. 12/x. Ophthalmoscopic examination entirely negative. Overcame prisms to-day when looking at a lighted candle at a distance of twenty feet, four degrees with the base up or down, eight degrees with the base in, and twenty-five degrees with the base out.

Græfe's vertical diplopia test, with same object and distance, showed a state of muscular equilibrium. In a state of accommodation, when one or the other of the eyes is covered, it apparently converges a little. On August 22d, after a week's use of a solution of atropine and cocaine in each eye, there appeared a hypermetropia of 0.50 Diopters in each eye; but the muscles overcame prisms only to the following extent when tested as before: Three degrees base up or down, six degrees base in, twelve degrees base out. Vertical diplopia test, as before, requires three degrees, base out, to place one image over the other. The inconsistency of this examination is obvious. If the ability of the muscle to overcome prisms is of any value as measuring the strength of the muscles, the above examination shows an insufficiency of the internal recti. If, on the contrary, the Græfe vertical diplopia test is of any value when applied as above, then there is an insufficiency of the external recti.

These examinations were repeated at intervals of four or five days until October 3d. The results, with regard to the ability to overcome prisms, was not found to vary much as to the vertical muscles, but the lateral muscles varied very considerably. When the base of the prism was placed toward the nose, the eye could fuse the images some days with eight degrees before one eye, another day three degrees would give permanent diplopia. With the base turned outward, the variation ran from twelve degrees to twenty-one degrees.

The vertical diplopia test, however, remained pretty nearly constant, requiring four degrees to five degrees base out, to place one image over the other. On October 3d, prisms were ordered two degrees base out, before each eye for constant use. October 22d, the patient reports that his eyes feel much better. Has left off his blue glasses which he had worn for eighteen months, and wears only the prisms without experiencing any photophobia. Has read an hour at a time. Has considerable headache still. I then reversed the prisms, placing their bases in, and on November 14th he reports that his eyes have been extremely painful. Has not been able to read any; headaches have returned with redoubled violence, and is obliged to lie down in a darkened room most of the time. The ability of the muscles to overcome prisms, when tested under these conditions, did not seem to stand in any relationship to the manner in which the prisms were worn, as for instance when the prisms had been worn base in, on one occasion the eyes overcame twenty-one degrees base out, and on another twelve degrees, exactly as happened when the prisms were worn with their bases out. On the other hand, during this period if tested by the vertical diplopia test the equilibrium was found to be perfect, which would seem to show that the added muscular exertion required to overcome the prisms worn (four degrees bases in), continued after they were removed, and exactly counteracted the natural insufficiency of the externi. The prisms were replaced with their bases out for distant use; and I ordered +0.50 D. combined with prism one degree base out, o. u. for near use.

With these glasses his headaches were much relieved. He was able to read to a limited extent, and could go about without the great fatigue or the neurasthenic symptoms which of late had attended all exertion. The eyes were examined from time to time after the prisms had been replaced with their bases out with somewhat varying results as to ability to overcome prisms, but with an average about as follows: Three degrees up or down, eight degrees base in, and twenty-one degrees base out. Such a condition of the muscles as the above average would indicate is about the normal standard I believe, except, perhaps,

that twenty-one degrees is rather low for the limit of power of the internal rectus. The Græfe test required five degrees base out for vertical images. This latter test, together with the fact that if he omitted wearing his glasses for several hours, he invariably had a headache, determined me in my diagnosis of an insufficiency of the external recti. A partial tenotomy of the tendon of the internal rectus of one eye was proposed with the idea of restoring the muscular equilibrium.

The operation was promptly accepted, and on May 21, 1888, Dr. W. D. Hall being present, I cut about three millimeters of the center of the tendon of the left internal rectus at its point of insertion. Two days later the patient reported that he had omitted the prisms since the operation, and that his head had not felt so well for six or seven years. Has walked two miles to my office without fatigue. Felt like a new man. Had tried to read with his prisms, but found that they made his eyes water and that he could read quite well without them. Overcame prisms four degrees base up or down, nine degrees base in, and nineteen degrees base out. Vertical diplopia test showed an equilibrium.

On July 6th, reports that several weeks ago he resumed his clerical duties and could do them without fatigue. Has resumed the use of prisms for reading, otherwise goes without them. Can read two or three newspapers through without fatigue. Reads several hours daily. On December 11th, I found that one degree base out was necessary for equilibrium with the vertical diplopia test at a distance of twenty feet. This condition has remained up to the present time, and on May 8, 1889, the gentleman says that he never has headaches, that while his eyes do not admit of constant near work without fatigue, he is able to do all his work and some collateral reading. This report only lacks a few days of a year from the date of the operation, during which period he has had absolutely no treatment.

I have reported this case somewhat fully, in order to illustrate the difficulties of an accurate diagnosis, but the remaining four cases I will report in a somewhat briefer form.

CASE II. — M. M., female, aged forty-two, teacher by occupation. She was first seen by me in June, 1887, complaining of

asthenopia. Manifest hypermetropia found of 0.75 D. For reading, found that 2 00. D. was necessary to give comfort. I ordered these glasses. The patient returned to me in May and June, 1888, complaining that she could only do her work with the greatest difficulty, on account of the pain in the head and eyes, and that the smarting of the lids was something extreme; and as there was a distinct conjunctivitis, treatment by astringents was instituted, but this failed to give relief. The eyes were examined under homatropine, and hypermetropia of 2.00 D. O. U. found. The muscles overcame prisms two degrees base up or down, three degrees base in, and twenty-one degrees base out. Vertical diplopia test, at twenty feet, required two degrees base out. Ordered more persistent use of glasses and continued treatment of lids.

Although not teaching at this time, the patient's condition became gradually worse. Head ached most of the time. Pain in the eyes always present. Complained greatly of many rather fugitive pains. Was always greatly fatigued, and incapacitated from doing even her household duties. At my suggestion she was examined by her physician, who reported that the only cause he could find for her condition was overwork.

Her eyes were examined from time to time, and the ability to overcome prisms was found to be as follows: two degrees base up or down, three degrees base in, and twenty-five degrees base out. This condition remained pretty constant during the four months from June to November. The amount required to place one image over the other in the vertical diplopia test varied from two degrees to five degrees base out.

As the patient was now unable to attend to her duties, and seemed to be rapidly descending into a condition of nervous prostration, a partial tenotomy was advised and accepted. The operation was done November 13, 1888.

The operation was partial tenotomy of the internal rectus of the right eye. The insertion of the tendon was severed, so that the merest shred was left. When the operation was finished the divergence was quite marked, and diplopia was present. Eight hours after the operation, the visible divergence still persisting, and as the patient said all objects "looked

funny," I thought best to approximate the edges of the cut in the tendon by a suture that was drawn up until I could see no divergence.

The operation was followed by considerable relief of the general fatigue; could work about the house. Headaches much relieved. There was still some pain in the eyes, however.

Examinations for the two weeks after the operation showed an ability to overcome prisms of two degrees base up or down, five degrees base in, and twenty-one degrees base out. Græfe test for distance required a prism of three degrees base out.

This patient has been able to do her work since the operation without fatigue, and her general condition is much improved. There is still considerable complaint of the eyes. It seems to me probable that we should have had a better result if I had drawn my corrective stitch less tightly.

CASE III.—Mrs. R. W. B., fifty-one years of age, was referred to me by Dr. E. H. Bigelow, of Framingham. She gave the following history at her first visit on August 3, 1888: "Four years ago had an illness which was marked by pain in the region of the heart and hyperæsthesia. Said to have been accompanied by marked dimness of vision. During the attack light and sounds were extremely annoying." Has never been well since. Has headache pretty much all the time. Headache severe enough to incapacitate her from doing anything, and much worse upon any attempt to do near work. There is a constant sense of fullness in the head, accompanied by a feeling of extreme lassitude. The eyes are sore and painful, and patient dreads to move them about. Has worn dark glasses for two years. Patient kept the eyes closed most of the time when talking, and when asked why she did this, said it relieved the distressed feeling. Sensation of fatigue in eyes present upon first awakening in the morning. The slightest excitement or the shortest railroad journey brings on a violent headache that confines the patient to her room for several days.

Upon examination, the condition of the eyes was found to be as follows: V. O. U. = 14/x not improved by any lens. The muscles overcame prisms of two degrees base up or down, seven degrees base in, and eight degrees base out. Graefe vertical

diplopia test, with a candle at twelve feet in a darkened room, showed muscular equilibrium; at twelve inches the same test required five degrees base in to bring the images vertical.

I advised, for experiment, a prism of two degrees base in before each eye for constant use. On August 27th, the patient reported that the prisms had given much relief to the ocular symptoms, but that otherwise she was about the same. Muscle test at this visit showed a power to overcome prisms of two degrees base up or down, eleven degrees base in, and eight degrees base out. The vertical diplopia test required, at twelve feet, three degrees base in; and at twelve inches, seven degrees base in.

The bases of the prisms were then reversed, and upon September 14th, the patient reported that all her symptoms were much worse, as indeed her excitable manner during her visit plainly showed. This excitable condition produced a somewhat startling change in the tests with the prisms; for that day she overcame three degeees base down, four degrees base up, seven degrees base in, and *twenty-eight* degrees base out. The vertical diplopia test at twelve feet, as before, required six degrees base *out*. Nevertheless, a partial tenotomy of the external rectus of the left eye was proposed, which was subsequently accepted, and on October 13th I operated on the external rectus of the left eye. Cocaine was used. I cut the central third of the insertion of the tendon, which was rather broad. An hour subsequently to the operation the vertical diplopia test showed equilibrium of the muscles for distance.

On November 14th, the patient reported that for two weeks following the operation she had felt perfectly well. Could not remember feeling so well since a child. Had attended some private theatricals and gone about very considerably. Since then the use of the eyes for near work had given some discomfort, and if long continued was followed by severe headache. She considers herself well by comparison. Has no sense of fullness in the head. The weariness had disappeared. Does not dread to look at people or to move the eyes as formerly. The eyes are now rested in the morning. Has no headaches except upon long-continued near work.

Prism tests of the muscles showed ability to overcome three degrees base up or down, nine degrees base in, and twenty-eight degrees base out. The vertical diplopia test at twenty feet required three degrees base in. I prescribed prisms one degree base in, before each eye, for near work.

December 19th, patient reported as follows: Has been very well, much better than ever before. Does not feel absolutely strong, and has a feeling as if it would be possible to overwork herself, if she was not somewhat cautious.

In February I wrote to Dr. Bigelow a letter of inquiry, and received the following reply: "Mrs. B. is very much improved in her general health since your treatment of her eyes. She seems like another person now, as I meet her. She certainly appreciates highly the help you have given her."

CASE IV. — Mr. W. B. N., twenty-seven years, student, married. Was first seen by me on September 22, 1888. Patient was a large, athletic-looking man, and in flesh and color appeared to be a well man. The history was, that ten years or more ago patient "broke down" during his college course; at this time he was troubled with occasional diplopia. Dr. Agnew was consulted in New York, and said that there was insufficiency of the interni; prescribed prisms, and hinted at a possible operation on the eye muscles. The prisms were worn a short time with relief, and were finally omitted on the advice of another eminent ophthalmologist. Within a few years his eyes had been examined under atropine, and Cyl. + 1, 00. D., axis vertical O. U., ordered for reading. Patient has had four years of nervous prostration. Has been better the last six months. Has used eyes more than usual of late. Still has many nervous symptoms, and is obliged to rest much, and to devote much time to sleep, if he would feel at all well. Two weeks ago he began to walk unsteadily. Saw double when he arose in the morning. Has been nauseated by this diplopia. Diplopia has continued of late for three-quarters of an hour after arising. Can ordinarily have diplopia or not at will. Of the false images in the morning, one was above the other, and some distance to one side. Diplopia crossed.

The power of the muscles to overcome prisms was as follows:

one degree base down, four degrees base up, six degrees base in, and fifty degrees base out. This latter result was accomplished by blurring the image, and it is probable that the accommodation was exerted to its fullest extent in the attempt to overcome the prism. Graefe vertical diplopia test twelve feet, showed equilibrium of muscles.

After two days of complete rest the muscle tests were as follows: Overcame prisms, two degrees base up, two degrees base down, seven degrees base in, fifty-nine degrees base out. Graefe vertical diplopia test required five degrees base in, for equilibrium. Ordered prisms two degrees bases out for trial.

September 29th, patient reported that the glasses had nauseated him, and aggravated all his symptoms. The prisms were reversed, and on October 6th the report was that the glasses had given relief to the eyes, but that other symptoms were the same.

After this, many variations of the prisms were tried, with bases up, down, etc., with rather indecisive results as to the vertical recti, but a pretty constant evidence of insufficiency of the internal recti, and on November 17th I did a partial tenotomy of the external rectus of the left eye. The central transverse incision of the tendon was not over two millimeters. On November 28th the patient's statement of his condition was, "Have had to go back to the two degree prisms bases in, but with them am much better off than before with three degrees or four degrees."

On December 1st I did a partial tenotomy on the external rectus of the right eye. This operation still left, when entirely well, an insufficiency of the internal recti; and although at first it apparently gave considerable relief, the patient has gradually fallen back into his previous condition.

An operation on one of the vertical muscles was not accepted; and on April 12th he wrote me in response to an inquiry: "I am somewhat dependent upon the cylindro-prismatic glasses; I still seem to have about six degrees of lateral insufficiency; health has been about as wretched as usual."

CASE V. — G. P. H., forty-four years, clergyman, married. Seen by me on November 17, 1888, and gave the following his-

tory: First broke down five years ago. Is said to have had nervous prostration. His condition has varied from time to time, but of late has steadily grown worse. Cannot attend to his duties, cannot read, sleeps very poorly. Is troubled much by pain in the forehead and back of the neck. Has sensations of weakness. If he attempts any work, has a nervous feeling or thrilling, which alarms him and incapacitates him for proceeding. Has a constant feeling of fatigue in the head. Has had two attacks of vertigo, after straining his eyes, which entirely disappeared upon closing the eyes. When he first began to preach, stammered, and overcame the fault with difficulty.

V. O. U. = 20/XV + Vertical diplopia test, at twenty feet, required prism one degree base out, to place images vertical. Muscles overcame prisms of four degrees base up, three degrees base down, four degrees base in, twenty degrees base out. Ophthalmoscopic examination revealed nothing abnormal.

Has worn, by advice, + 60 inch lens O. U. for reading, for the last few months. Advised prisms two degrees base out for constant use, for diagnostic purposes.

The gentleman returned to me on December 1st, and said that he had been very much relieved by the glasses. Had used his eyes freely. Headaches and other pains very considerably diminished.

Graefe vertical diplopia test showed an insufficiency of six degrees of the externi; and the muscles overcame a prism of four degrees base up, three degrees base down, eight degrees base in, and sixteen degrees base out, showing once more the inconsistency of these two tests, which are supposed to prove the same thing.

The glasses were then reversed; and four days later the patient reported that he could read very well with the prisms placed bases in, but that all his nervous symptoms, such as fatigue and distress in the head, had returned with their accustomed sequelæ.

The prisms were again placed bases out, and gave immediate relief. He was enabled to do some literary work, and did not become so exhausted upon slight effort. He was kept under observation for nearly eight weeks, and tested frequently. The

relief afforded by the prisms, which was so marked at first, gradually diminished until, in the latter part of January, the eyes ached at night very considerably, and the patient was obliged to relinquish all work on account of the general symptoms. During this period the muscle tests ran pretty uniformly, as follows: Prisms overcome, at a distance of twenty feet, two degrees base up or down, six degrees base in, twenty-two degrees base out. Vertical diplopia test required five degrees base out, to place images vertical.

On February 2, 1889, I did a partial tenotomy of the internal rectus of the left eye. About four to five millimeters of a very broad insertion were cut. Operated under cocaine. An immediate trial with candle and red glass showed a crossed diplopia. In five minutes, however, it had disappeared. The operation was not immediately followed by any gain, except that dizzy sensations in the head, to which he had before been subject, had entirely disappeared. Twelve days after the operation the Graefe vertical diplopia test showed muscular equilibrium.

On March 2d, patient reported that he felt distinctly better. His eyes were comfortable; his neuralgias had disappeared; he had no dizzy spells or trembling attacks; and, to judge by his face and general appearance, one would say that he was evidently much better.

In response to a letter of inquiry, the gentleman writes me, under date of April 16th: "I began preaching after I saw you, and have been able to keep it up every Sunday, once a day; but I have felt rather exhausted some of the time. On the whole, there has been a gradual improvement, — I ought to say, a very decided improvement in some respects, — and I am still gaining. . . . The ability to do some professional work must be attributable largely, if not entirely, to the operation; and this is a gain of incalculable value."

I have reported these cases more at length than I should otherwise have done, but for the desire on my part to emphasize the utter unreliability of the results of any single examination for proving the existence of insufficiencies of the ocular muscles.

If the cases are studied in detail, it will be found that the

condition that was ultimately proved to be the cause of all the disturbance was rarely discovered at the first examination, and that it was only when the muscles had been relieved of their extra load, by the use of prisms, that the true state of affairs was revealed. Again, what is to be especially noticed in these cases is the fact that the von Graefe test for insufficiency and the ability to overcome prisms, which are supposed to be only different methods for arriving at the same facts, should so frequently show exactly opposite results. From my experience in these five cases I should say that, while I would not discard the trial of the ability of the muscles to overcome prisms, I should rely much more upon the results of the von Graefe test. I desire also to call attention to the fact that the constant use of prisms for a few days was a much more satisfactory method of trial. It is evident from the results obtained in these cases that when the weak muscle had an additional burden laid upon it by the prisms, that the disagreeable symptoms were aggravated, and *vice versa* when the burdens of the weak muscles were relieved and the severity of the symptoms abated.

With regard to the ultimate results in the cases reported, it would seem that if the incision had been a trifle freer, so as to have weakened the muscle a trifle more, that the results might have been better in the first, second, and third cases. In the fourth case the result, although so far a failure, is so, apparently, because there is still a large amount of lateral insufficiency left, and also, probably, because there is a certain amount of vertical insufficiency which has never been corrected.

The results obtained in the first, second, third, and fifth cases are highly satisfactory to the patients and encouraging to the operator, and have been accomplished after all other means had been tried and failed.

A word as to the number of such cases, and then I am done. From an ophthalmologist's point of view I should say that they were not numerous. The vast majority of cases of headache and neurasthenia, which have the eye for their starting point, are completely relieved by properly correcting glasses, and this too, when an insufficiency exists, according to the von Graefe test.

The correction of errors of refraction in neurasthenic cases should be done with the utmost care. An error of half a diopter in a spherical lens, or of ten degrees in placing the axis of a cylindrical lens, is sufficient to continue nervous disturbance.

A number of times, when I thought I had gotten another case to add to the number reported here to-day, I have found that I was mistaken, and that all that was needed was a more careful examination for errors of refraction than the patient had hitherto received, and a very slight alteration in the formula.

I say that these cases are probably rare, for the reason that I have been industriously looking for them for three years among all the clinical material at my command, and I have only found three cases in addition to those reported. These three cases all refused operation. It is probable that such cases may be more numerous in neurological than ophthalmological clinics.

In conclusion, while I am not in a position to judge as to the efficacy of partial tenotomies for the treatment of epilepsy, insanity, etc., I do believe that it is of great advantage in a certain class of neurasthenics.

DISCUSSION.

Dr. GEORGE C. HARLAN, Philadelphia. — I have used the Crete prism for a number of years, and find that the results obtained by it are different from those obtained from successive prisms. In my own case, comparing the Crete prism with successive prisms, I can overcome three times as many degrees with the former as with the latter. It has seemed to me that the difference is the same as that experienced between lifting a weight gradually and carrying it, and lifting it and dropping it successively a number of times. I have found this same difference in results in a number of patients, and have often wondered, in reading reports, which method the observer had used.

Dr. SAMUEL THEOBALD, Baltimore. — In one respect, I reached a number of years ago the same conclusion as Dr. Standish, and that is, that the vertical diplopia test is much more trustworthy in giving the relative strength of the external and internal recti muscles than seeing how strong a prism the patient can overcome. I found in my own eyes that while with the vertical diplopia test I apparently had insufficiency of the internal recti, I could take all the prisms in my Nachet case, put them together, and overcome them with the internal recti. I

came to the conclusion that the method was extremely untrustworthy; that it was a matter of mere knack, some patients being able to put the muscles in a state of tension and overcome a marked prismatic effect. The test for vertical diplopia at twenty feet, and then at the reading distance, I think gives pretty fairly the relative strength of the internal and external recti.

I do not attach much importance to slight degrees of insufficiency of the internal recti muscles (2° or 3°) at twenty feet. Insufficiency of the external recti at twenty feet of even this slight amount I regard as of more significance.

Dr. S. D. RISLEY, Philadelphia. — The subject of the anomalies of the ocular muscles, their detection and measurement, is one of much importance in the routine of office work, but around which much confusion still seems to exist. I was interested in the reporter's experience in the endeavor to arrive at the state of muscular balance by measuring at twenty feet or more the relative strength of the muscles, as indicated in their power to overcome prisms. The time consumed; the steadily increasing ability of the internal recti, especially, to resist diplopia; and withal the varying results from day to day, or even on the same day, long since led me to abandon it as not only tedious, but unreliable. The principles and methods so carefully and clearly laid down in Dr. Randall's paper, yesterday, are not only more trustworthy, but consume less time, and remove much of the confusion which clusters around this subject. I desire to urge the importance of calling into action the power of accommodation at the same time that the muscular balance is sought for, and that as nearly as possible under the ordinary conditions of use. Where ametropia is present the test must be made through the correcting glasses, and in presbyopia, or high myopia, through the required reading correction. The test object should be something requiring accurate focusing in order to be seen distinctly at the usual reading distance, as pointed out by Dr. Randall. My own preference is for a short word from Jaeger No. 1, — placed in the center of a white card. This is placed firmly at thirty centimeters from the eyes and vertical diplopia produced by a six or eight degrees prism placed base down over one eye, where the lateral balance is sought for, or a sufficiently strong prism base in to cause lateral diplopia if the state of vertical balance is under investigation. If lateral or vertical deviation of the images is manifested the correcting prism will be found to be quite uniform under frequent repetitions of the test, whether made at the same sitting or on successive days, provided the patient has

been careful to keep the images clearly in focus. In measuring the deviation I very much prefer the Crete prism to the placing of successively stronger or weaker prisms before the eye. Not only is much time saved by using it, but much fatigue to the patient. In its usual form, as found in the market, it is cumbersome and unwieldy. To overcome this objection, I have devised a more convenient form of rotary prism, which I present at this meeting of the society. It is made to fit into the ordinary trial frame, so that zero can be placed at any desired part of the graduated frame. The prisms are rotated by means of a milled-head screw, increasing in strength from zero to thirty degrees. It has been in use for about two months, and I present it for the inspection of the members of the society, feeling sure they will find it not only a convenient instrument, but one which will save much time, and will also enable them to arrive at more accurate results than in the placing of prisms of different strength in slow succession before the eyes.

Dr. EDWARD JACKSON, Philadelphia. — Instead of the single dot, I use as the object for the near test a little group of fine dots, such as can be made with a fine pen upon a white card; and require the patient to count these dots. In this way I make sure that the patient is accommodating for the point fixed. Dr. Randall yesterday said of the Graefe test that the line should be left out, using simply the dot. I use it that way altogether. The line was originally introduced to enable the patient to say whether the images were exactly vertical or not. But you can tell this by turning the base of the prism a little to either side. If the patient still states that the dots are vertical, after the prism has been turned 10° or 20°, they were probably not exactly vertical to start with; but if turning the prism 5° causes him to notice their displacement, you can accept his answers as correct.

Dr. Standish spoke of the condition of the eye muscles as the cause of the symptoms. In a good many cases, perhaps in the large proportion, I am not satisfied that the muscular anomaly is the cause. We have a chain of morbid phenomena with faulty muscular action at the one end and pain at the other; but I think that in the majority of cases this morbid train is due no more to the one than the other; the cause is central. The movements of the eye muscles are complex and the adjustments required are complicated and of comparatively recent evolution. Binocular vision seems to be confined to man. While the muscles are found low down in the animal kingdom, the co-ordinating mechanism is of recent development, and I think on that account we should look for it to be more liable to defective

development. I think that these cases are not faults of the physical properties of the muscles, or of the situation of their insertions, so much as they are faults of the control of these muscles by the co-ordinating centers.

Dr. O. F. WADSWORTH, Boston. — I wish to say a word as to the adduction test. This is described by many writers as though it were a distance test. The point that I wish to make is, that as it is made, it is not a distance test; that the higher prisms are only overcome by an effort of the accommodation, and as soon as accommodation comes in, the test is no longer a distance test. The abduction test does not call for any effort of the accommodation, and is a distance test.

I agree with Dr. Risley that in the lateral prism test, i. e., the adduction and abduction test, we may get quicker and more regular results with the revolving prism than with successive prisms. For the Graefe test, for the lateral deviation with vertical diplopia, I think that the revolving prism has no special value. Dr. Risley spoke of the rapidity with which the result is obtained as an advantage. I think that in this test rapidity is an objection. It is my experience that in a considerable number of cases where there is lateral deviation, the lateral deviation only appears, or appears in greater degree, after the prism has been held before the eye some appreciable time. I have in mind one case, operated on within two months, in which the first measurement gave lateral deviation as low as 2° or 3°, but on holding the prisms in place for a while it went up to 23°. Full tenotomy of the internal rectus still left a deviation of 10°, but relieved the asthenopia.

With regard to the fourth case reported by Dr. Standish: I saw that patient several times. I do not think that further tenotomies in that case would be of advantage. This patient presented marked hysterical symptoms. He came to me finally complaining of hemi-anæsthesia, and desired to be sent to a neurologist, because oculists had done all they could for him. His vertical deviation varied constantly, apparently. At one period he had the habit of testing his muscles the first thing on getting out of bed in the morning, and he brought me tables of vertical deviation which he had observed in the course of a week, testing three or four times a day. I think that case was one in which the muscles might have been cut indefinitely without result.

Dr. GEORGE C. HARLAN, Philadelphia. — Did Dr. Wadsworth, in his test for adduction, employ atropia? That would seem to overcome the objection which he has raised. I have been surprised in several instances of the adduction test at the

absence of any difference between the results obtained before and after the use of atropia.

There is one other point, and that is the very great disturbing effect of a low degree of vertical insufficiency. This has been strongly brought to my attention by a patient whom I treated five or six years ago. He was a great sufferer from the symptoms described. He had been under the care of a member of this society, who had treated him with prisms and by operation. I afterward had him under my care for some time. There was considerable insufficiency of the internal recti, for which I did a section, with partial and temporary relief. The tests at different times, however, were so contradictory, and the final results so unsatisfactory, that we eventually became very tired of each other, and he disappeared. The other day he returned. In the mean time my attention had been called to the disturbing effect of slight vertical deviation. I found a vertical deviation of 2° or 3°, and prescribed that prism; at the same time also correcting the insufficiency of the interni. He returned in a few days, stating that this had given him more relief than anything which had been done before. The result was still good a month later.

Dr. MYLES STANDISH, Boston. — When I started this series of cases I distrusted the Crete prism very much. All these cases were examined by the other method. Since then I have used the prism more, but I do not feel quite sure of it. Of course a great many people have errors of refraction, and many have insufficiency of the muscles, with no nervous symptoms. The reason is, I think, that they have no neurotic tendency. In order that this condition should produce such symptoms there must be some inherited neurotic tendency. I did not say that insufficiency of the muscles produced these headaches. Many have insufficiency without headaches. I stated that it was the precipitating cause. I am willing to modify it further to please the gentleman, and say that it is the use of the muscles which is the precipitating cause.

In regard to the fourth case: I think that it is true that the man had hysterical symptoms. So had the others. I do not think that we know enough to say because a case is hysterical that the hysteria may not be precipitated by some reflex cause.

MYDRIASIS OF ONE EYE WITH INTACT ACCOMMODATION LASTING FOUR MONTHS AFTER APPLICATION OF HOMATROPINE TO BOTH EYES.

By O. F. WADSWORTH, M.D.,
BOSTON, MASS.

Mrs. A., 33 years of age, in very good general health, consulted me on May 30, 1887, on account of a slight blur lately noticed in reading. The blur seemed to her to spread over the book from the left, was not enough to interfere with reading, and did not become worse. Except for a slight congestion of the lid conjunctiva, the eyes were externally normal in appearance. V., R. or L. with $+.50\ \frac{14}{10}$: together with $+\ 1.\ \frac{14}{10}$. She read .5 Sn. 28″ to 7″. Fundus normal in both eyes. A mild collyrium was prescribed.

June 6th, and again June 14th, the condition was the same in all respects.

June 15th, homatropine hydrobromate, 1%, was dropped into each eye some eight times at intervals of a few minutes. Dilatation of pupils equal. V., R. with $+.75\ \frac{14}{12}+$, L. with $+\ 1.25\ \frac{14}{12}+$; together $\frac{14}{10}$. With a strong + lens behind the mirror a faint thread was made out in the vitreous of the left eye, running across a little above the horizontal meridian, and moderately movable. In other respects examination negative. On the same day she went to the country for the summer.

July 7th, Mrs. A. wrote that, while the right pupil had become of natural size within a day or two after the application of homatropine, the left had remained large; that the blur on reading was unchanged.

As this condition continued, she came to see me on Aug. 10th. R. pupil natural; L. pupil presented an appearance as in paralysis of the sphincter iridis and showed very little reaction.

T. and F. normal. V. with + .75 $\frac{14}{10}$—. Read .5 Sn. up to 7″ with L., up to 6″ with R. Media and fundus as before. A small crystal of pilocarpine nitrate in L. contracted the pupil strongly and brought the far point to 6″ – 8″.

Pilocarpine nitrate 2% to be applied once each day.

Aug. 29th, she reported that the pupil did not dilate again so quickly after the pilocarpine as at first. It was then some sixteen hours since the last application of pilocarpine, and the left pupil was somewhat larger than the right, but reacted fairly well.

Except for one interval of about a week pilocarpine was used daily for the next six weeks.

Oct. 12th. No pilocarpine for two days. L. pupil as in paralysis of sphincter, reaction slight, but not wholly absent. Blur as at first visit is observed in reading, but otherwise no discomfort. Reads fine print (the New York *Tribune* reduced so that the width of the printed page is a little less than four inches) up to 6¾″ with R. or L. equally well, without a glass. Fine thread in vitreous L. as in June, and fundus normal.

Oct. 18th. Consultation with Dr. Hay. Pupil and A. as on 12th. Pot. iod., gr. v. 3 t.d., was ordered, and on the suggestion of Dr. Hay she was directed to massage the eye gently daily.

Oct. 26th, she reported that she had forgotten the massage. The L. pupil was now usually rather smaller than on the 18th. It was 5.5 mm. diameter when looking at the distance with the R. covered, but generally less than this, and contracted from 5 to 3.5 mm. with accommodation.

Nov. 8th. L. pupil 5.5 mm. when R. is 5 mm—. When R. is contracted to 2 mm. with light and accommodation L. is about 2.5 mm. By gaslight the difference between the pupils seems rather greater than by daylight, and when with distant fixation light from the mirror is thrown into the L. eye its pupil reacts much less than does that of the R. eye under like circumstances. Pot. iod. gr. vii.

A week later the condition was unchanged, and the iodide was increased to gr. x.

Nov. 28th. Condition the same. As no inconvenience was

experienced except from the slight blur in reading, treatment was now abandoned.

I saw Mrs. A. casually afterward at irregular intervals, and the difference in size of the pupils was always quite apparent. In Jan., 1889, I again examined her eyes. They were in all respects the same as in Nov., 1887, excepting that the blur in reading was no longer perceived.

The case stands alone in my experience. The character, circumstances, and surroundings of the patient were such as to make hysteria improbable, and the surreptitious use of a mydriatic still more so. The only other disturbance that could be discovered was a slight constipation, which was habitual. Against the use of a mydriatic is the fact that accommodation was perfectly preserved at a time when there was but the slightest reaction of the pupil to strong light and accommodative effort. Against both hysteria and the use of mydriatics is the circumstance that the pupil, while reacting well, has for fourteen months remained very perceptibly larger than the other. Had this inequality of the pupils existed before the homatropine was applied, three careful examinations at different times, to discover the cause of the slight blur complained of, could not have failed to reveal it.

DISCUSSION.

Dr. SAMUEL THEOBALD, Baltimore. — It would be important to know whether or not this patient had a solution of homatropine at home. I have had cases where the mydriatic was being used by the patient when it was supposed that it was not. It might be said that the fact that the accommodative power was fairly good would disprove this, but a very weak solution would dilate the pupil without producing an appreciable effect upon the accommodation. This is a point that should always be excluded in these cases.

Dr. SAMUEL D. RISLEY, Philadelphia.— There is another practical explanation of these cases. I have had pupils kept dilated by the use of an eye-wash free from any mydriatic by the use of a pipette which had formerly been used for a mydriatic, the pipette apparently contaminating the solution.

Dr. W. W. SEELY, Cincinnati.— I have seen a case, that of a student, in which a one-grain solution in one eye produced free

dilatation of the pupil. This continued until the end of the session. In the fall he returned with the dilatation still present. Again the next spring the pupil was in the same condition. I then used eserine once or twice, but with no permanent effect. Six months later he began the use of a weak solution of eserine rather persistently, and finally overcame the mydriasis. That is the only case where I have seen what might be called permanent mydriasis from a mydriatic. The solution was used only once.

Dr. SAMUEL B. ST. JOHN, Hartford.— I have a patient whose pupil has been permanently dilated for ten years, and this condition is said to have followed the instillation of atropia. I do not know how strong the solution was. As the dilatation gives no trouble he has not requested that anything should be done for it. The accommodation is about the same as that of the fellow eye.

Dr. E. E. HOLT, Portland.— I had a case where after the use of atropine the pupils remained dilated and the accommodation paralyzed. This condition has continued five or six years. The woman was in fair health but of a nervous temperament.

Dr. O. F. WADSWORTH, Boston.— The question of simulation is always to be considered in these cases. There was no reason to suspect it in this instance, and I think it is hardly possible that a mydriatic could be used to dilate the pupil so that there was practically no reaction to strong light and accommodation, and yet the patient be able to read small type as near that eye as the other.

A NEW ROTARY PRISM.*

BY S. D. RISLEY, M.D.,

PHILADELPHIA.

I PRESENT herewith, for the consideration of the society, a new, and I think a more convenient, form of revolving prisms than those heretofore in use.† Adopting the principle first put in practice by Volkmann, and later by Cretes, two prisms of fifteen degrees each are superimposed, with their bases in opposite directions.‡ They are mounted in a delicately milled-edge cell, with a diameter the same as those employed in the Nachet trial glasses, which therefore fits readily into the ordinary trial-

frame. The milled-edge permits its convenient turning in the frame, so that the base or apex of the prism can be readily placed in any desired direction. The prisms are caused to rotate in opposite directions by means of a milled-head screw projecting from the front of the cell. The strength of the successive prisms, resulting from the rotation, is read off on the graduated scale engraved on the front plate of the containing cell, extending from zero to thirty degrees, the combined value of the composing prisms. As constructed it will usually be found most convenient to place the instrument before the left eye, when the rotating screw, with the zero mark vertical, will

* See discussion, page 405.
† It is manufactured by Borsch & Rommel, Walnut and Juniper Streets, Philadelphia.
‡ The strength of these prisms has since been increased, their total value being forty-five degrees.

stand at the upper and outer quadrant and can be readily manipulated without the hand of the operator obstructing the patient's vision. In this position, turning the screw to the right or left will cause the base of the resulting prisms to be inward or outward, that is to say, toward the nose or temple as may be desired, when the strength of the adducting or abducting muscles is to be determined. If the vertical muscles are to be examined, the zero points may in like manner be placed horizontally, by simply turning the containing cell in the trial-frame. The main features of the instrument are well shown in the accompanying cut.

THE INEFFICIENCY OF HYDROBROMATE OF HOMATROPINE IN CONTROLLING THE ACCOMMODATION OF THE EYE FOR THE PURPOSE OF FITTING GLASSES.

BY E. E. HOLT, M.D,

PORTLAND, MAINE.

WHEN hydrobromate of homatropine was introduced, a few years since, it was thought to possess valuable properties as a mydriatic, inasmuch as its effects upon the accommodation of the eye passed off very much quicker than that of sulphate of atropine. While it is not denied that homatropine possesses great value in ophthalmology, it is the purpose of this article to draw attention to the fact that it cannot be relied upon for controlling the accommodation of the eye in certain cases of refraction for the purpose of fitting glasses. The following case may be selected as one among several in my practice to illustrate this point.

C. P. K., aged 21 years, consulted me Dec. 26, 1888. Asthenopia came on while in college, and he was obliged to give up study. Test without a mydriatic: —

V. D. 1. 0 +; c — 0. 5 d. c. axis 135° = 1. 0 +

V. s. 1. 0 +; c — 0. 5 d. c. axis 45° = 1. 0 +

Ordered hydrobromate of homatropine 3 per cent. solution. December 27th, used solution nine times in sixteen hours; hourly for four hours previous to test.

V. D. 0. 4; c + 0. 5 d. s. ⌣ + 0. 5 d. c. axis 45° = 1. 0 +
V. s. 0. 4; c + 0. 75 d. s. ⌣ + 0. 5 d. c. axis 90° = 1. 0 +

P. M., five hours later. Solution used four times, as often as a patient was seen, probably every twenty minutes previous to test.

V. D. 0. 4; c + 0. 5 d. s. ⌣ + 0. 5 d. c. axis 45° = 1. 0 +
V. s. 0. 4; c + 0. 5 d. s. ⌣ + 0. 75 d. c. axis 90° = 1. 0 +

There was a muscular error in this case, but no more than is often observed in asthenopia. Glasses for the correction of astigmatism were ordered, and he was given a chart to practice and record Dyerizing. He made little or no progress, having gained but ten minutes in a month, and glasses were ordered to correct all the ametropia revealed by the homatropine. After due trial the progress towards recovery was unsatisfactory, and he was advised to come and have the eyes tested again.

On March 7th, ten weeks later, the following condition was found. Test without a mydriatic:

V. D. 0. 7; c + 0. 5 d. c. axis 45° = 1. 0 −
V. s. 0. 7; c + 0. 75 d. c. axis 90° = 1. 0 −

A *one* per cent. solution of sulphate of atropine was ordered. March 8th, the next day, the one per cent. solution of atropine was used six times in the last twenty-four hours.

V. D. 0. 3; c + 1 d. s. ⌣ + 0. 5 d. c. axis 90° = 1. 0.
V. s. 0. 4; c + 1 d. s. ⌣ + 0. 75 d. c. axis 90° = 1. 0.

March 9th, second day. The one per cent. solution of atropine has been instilled five times in each eye since the last test.

V. D. 0. 3; c + 1 d. s. ⌣ + 0. 5 d. c. axis 90° = 1. 0.
V. s. 0. 3; c + 1 d. s. ⌣ + 0. 75 d. c. axis 90° = 1. 0.

It will be observed that the latent hypermetropia revealed by the use of the *three* per cent. solution of hydrobromate of homatropine was just one-half of that revealed by the use of the one per cent. solution of the sulphate of atropine, and that the axis of the cylinder of the right eye was also changed from 45° to 90°.

Glasses which corrected all the ametropia revealed by the use of the one per cent. solution of the sulphate of atropine were ordered, and by wearing them he made progress towards recovery. This progress was not satisfactory, however, and a prism of a half a degree was combined with one of these glasses

to correct a slight deviation of the axis of the right above that of the left eye. With these glasses the patient has made satisfactory progress towards recovery.

According to the conclusions reached by Dr. Oliver in his experiments with hydrobromate of homatropine complete ciliary paralysis can be obtained by a single instillation of the $\frac{1}{60}$ of a grain of hydrobromate of homatropine at the time of the utmost action of a single instillation of the $\frac{1}{20}$ of a grain of hydrobromate of homatropine. It was found that the utmost loss of accommodation occasioned by a single instillation of the $\frac{1}{20}$ of a grain of homatropine was thirty-two minutes, and that this action was only maintained for about two to four minutes. The instillation of the three per cent. solution, which would be about $\frac{1}{30}$ of a grain, as in the case cited, the test following the last application in a few minutes, must be considered thoroughly done, and leave no room for doubt as to the inefficiency of hydrobromate of homatropine to control spasms of the accommodation, in certain cases, for the purpose of fitting glasses.

Since finishing this paper, Dr. Oliver kindly writes me that his experiments were made upon emmetropic or ametropic non-irritable eyes. He refers me to Dr. Stewart's paper in the *Medical News* for March, 1889, and cites the following portion as embodying what he holds to be true of the clinical value of homatropine in ophthalmology. "The fact of the constant irritant action of repeated instillations of homatropine hydrobromate on the deeper tunics of the eye, the choroid, and probably to a certain extent the retina, gives answer in great measure why ametropia cannot be properly estimated; hence the drug should be avoided in the correction of refractive errors."

DISCUSSION.

DR. EDWARD JACKSON, Philadelphia. — Those who use homatropine and find it unsatisfactory use it in a different way from those who find it satisfactory. Those who have come to rely upon it to produce full paralysis of the accommodation use it by repeated instillation at short intervals. I have found, and elsewhere state, that a single instillation of a saturated solution can not be relied upon to produce complete paralysis of accommodation. Instillations made at intervals of an hour, no matter what

the strength of the solution is, are unreliable. The instillations must be made a few minutes apart, so that the dose is introduced as rapidly as possible. When used in this way, I believe that homatropine is as reliable as any mydriatic. I have used it in probably eight hundred cases, and I use it in all cases for purposes of diagnosis alone. Two years ago I published my conclusions in the *Medical News*, and gave a table of the cases in which I had then used homatropine, and followed it immediately by a stronger mydriatic, and the second mydriatic showed no decided pre-eminence over the homatropine. In some cases the second mydriatic would give a slightly higher hyperopia, while in other cases the homatropine gave the higher degree, but in no case did the difference exceed .5 D.

I make not less than three, and usually more, instillations, at intervals from five to fifteen minutes, and have the refraction tested in from one to two hours after the instillations. Recovery will sometimes be found commencing within three hours.

DR. B. ALEXANDER RANDALL, Philadelphia. — In some observations made by Dr. Risley, and reported to this Society in 1881, in which I assisted, homatropine, used within its proper limits, was shown to be perfectly comparable to the stronger mydriatics in the success with which it was employed in uncovering the full amount of refractive error. Later experience confirms this.

THE DECENTERING OF LENSES FOR ACCURATE PRISMATIC EFFECTS: WITH TABLES FOR DECENTERING, AND OF REFRACTING ANGLES.

BY EDWARD JACKSON, M.D.,

OF PHILADELPHIA.

PROBABLY inaccuracies that now occur in the filling of prescriptions for prisms would not be tolerated by either prescribers or opticians, if they were recognized. Such inaccuracies escape notice because prisms are prescribed in combination with spherical and sphero-cylindrical lenses. The effect of a prism in such a combination is simply to change the position of the optical center. Hence an error as to the amount of prismatic effect introduced amounts only to an imperfect centering of the lens, and as such is very readily overlooked.

To test practically the strength of a prism in such a combination, it is necessary, first, to establish the point at which the glass when in use will be pierced by the visual axis. Then we may either ascertain by trial what prism is required to bring the optical center of the combination to that point, or we may simply measure the distance from that point to the optical center, and from this distance and the strength of the lens in the combination calculate the strength of the prism. Or, on the other hand, where the lens in the combination is sufficiently strong, as compared with the strength of the desired prism, the prescription to decenter the lens to a definite distance, in a definite direction, is an excellent way to indicate the desired prismatic effect, and one that avoids all risk of error from inaccuracy in the maker's standard prisms.

To avoid the need of repeated calculations in ordering or testing prisms thus, I two years ago prepared a table like the one here given, and have since commonly ordered prisms in this way. The formula by which such a table is calculated for

spherical lenses, and prisms numbered by deviation, is perfectly simple. *The distance a lens must be decentered to produce a certain prismatic deviation is the tangent of that angle of deviation, with the focal distance of the lens for a radius.* Thus, for a one-diopter lens, radius being one meter, the decimal to be read from a table of natural tangents is the required distance, in meters, or, moving the decimal point three places to the right, in millimeters.

In Table I, the first column gives in diopters the strength of the lens to be used. At the head of each of the other columns is given the prism (in degrees of deviation) to be combined with it; while below, the column gives the respective distances in millimeters that the optical center must be removed from the visual axis to produce such an effect.

TABLE I.—DECENTERING REQUIRED TO PRODUCE A GIVEN DEVIATION.

Lens.	0.5° d.	1° d.	1.5° d.	2° d.	2.5° d.	3° d.	4° d.	5° d.
1 D.,	8.7	17.5	26 2	34.9	43.6	52.4	69.9	87.5
2	4.3	8.7	13.1	17.5	21.8	26.2	34.9	43.7
3	2.9	5.8	8.7	11.6	14.5	17.5	23.3	29.2
4	2.2	4.4	6.5	8.7	10.9	13.1	17 5	21.9
5	1.7	3.5	5.2	7.	8.7	10.5	14.	17.5
6	1.5	2.9	4.4	5.8	7.3	8.7	11.6	14.6
7	1.3	2.5	3.7	5.	6.2	7.5	10.	12.5
8	1.1	2 2	3.3	4 4	5.4	6.5	8.7	10.9
9	.9	1.9	2.9	3.9	4.8	5.8	7.8	9.7
10	.9	1.7	2.6	3.5	4.4	5.2	7.	8.7
11	.8	1.6	2.4	3.2	4.	4.8	6.4	8.
12	.7	1.5	2.2	2.9	3 6	4.4	5.8	7.3
13	.7	1.3	2.	2.7	3.3	4.	5.4	6 7
14	.6	1.2	1.9	2.5	3 1	3.7	5.	6.2
15	.6	1.2	1.6	2.3	2.9	3.5	4.7	5.8
16	.5	1.1	1.6	2.2	2.7	3.3	4.4	5.5
17	.5	1.	1.5	2.	2.6	3.1	4.1	5.1
18	.5	1.	1.5	1.9	2.4	2.9	3.9	4.9
19	.5	.9	1.4	1.8	2.3	2.8	3.7	4.6
20	.4	.9	1.3	1.7	2.2	2.6	3 5	4.4

In Table II, the first column gives, as before, the strength of the lens, the head of each of the other columns shows the refracting angle of the prism equivalent to the amount of decentering indicated by the figures beneath, which indicate in mm. the distance the optical center is to be removed from the visual axis.

TABLE II — DECENTERING EQUIVALENT TO A GIVEN REFRACTING ANGLE (INDEX OF REFRACTION, 1.54).

Lens.	1°	2°	3°	4°	5°	6°	8°	10°
1 D.,	9.4	18.8	28.3	37.7	47.2	56.5	75.8	95.2
2	4.7	9.4	14.1	18.8	23.6	28.2	37.9	47.6
3	3.1	6.3	9.4	12.6	15.7	18.8	25.3	31.7
4	2.3	4.7	7.1	9.4	11.8	14.1	18.9	23.8
5	1.9	3.8	5.7	7.5	9.4	11.3	15.2	19.
6	1.6	3.1	4.7	6.3	7.9	9.4	12.6	15.9
7	1.3	2.7	4.	5.4	6.7	8.1	10.8	13.5
8	1.2	2.3	3.5	4.7	5.9	7.1	9.5	11.9
9	1.	2.1	3.1	4.2	5.2	6.3	8.4	10.5
10	.9	1.9	2.8	3.8	4.7	5.6	7.6	9.5
11	.9	1.7	2.6	3.5	4.3	5.1	6.9	8.7
12	.8	1.6	2.4	3.1	3.9	4.7	6.3	7.9
13	.7	1.4	2.2	2.9	3.6	4.3	5.8	7.3
14	.7	1.3	2.	2.7	3.4	4.	5.4	6.8
15	.6	1.3	1.9	2.5	3.1	3.8	5.1	6.3
16	.6	1.2	1.8	2.4	3.	3.5	4.7	6.
17	.6	1.1	1.7	2.2	2.8	3.4	4.5	5.6
18	.5	1.	1.6	2.1	2.6	3.1	4.2	5.3
19	.5	1.	1.5	2.	2.5	3.	4.	5.
20	.5	.9	1.4	1.9	2.4	2.8	3.8	4.8

To use one of these tables, for the combination of a prism with a spherical lens it is only necessary to find in the first column the strength of the lens in question, and go across, on a level with this, to the column which has at its head the strength of the desired prism, and the figures given tell the number of mm. the lens must be decentred. For quarter or half diopters the value may be interpolated. With cylindrical and spherocylindrical lenses, however, it is necessary to take into account the angle between the direction in which the lens is to be decentered and the axis. The strength of the cylindrical is to be multiplied by the sine of this angle, and the resulting product added to the strength of the spherical (subtracted when the signs are opposite), and the sum to be regarded as the total strength of the lens to be looked for in the first column of Table I or II. When, however, a cylindrical lens is decentered in a direction oblique to its axis, it not only gives a prismatic effect in the direction in which it is decentered, but gives also a prismatic effect, proportioned to the cosine of the same angle, perpendicular to this direction. This latter undesired effect is to be met either by a similar decentering of the lens before the other eye, if they are of the same strength and have symmetrical axes, or by an additional decentering for this especial purpose.

So that the securing of prismatic effect oblique to the axis of a cylinder is quite a complicated problem. But when the decentering is required in the direction of the axis of the cylinder, the angle between axis and direction of decentering being zero (and its sine zero), the cylindrical has no prismatic effect, and may be disregarded. And again, when the direction of the decentering is perpendicular to the axis of the cylinder, and the sine of 90 degrees equal radius or one, the strength of the cylindrical is simply added to the spherical and the sum used as though it were a simple spherical lens.

These tables may also be used in testing simple prisms, as those of the trial-case. For this purpose mark on a spherical lens of convenient strength the situation of the optical center; superimpose the prism to be tested, and note the apparent change in the position of the optical center. This distance in mm. found opposite the number of the lens, will be in the column having at its head the real strength of the prism. It is hoped this use of the tables will draw attention to the inaccuracies of the prisms furnished in trial-sets.

Though not bearing on the subject of decentering lenses, I wish to introduce here, so that it may be generally accessible, a table giving the refracting angles of prisms numbered according to the angle of deviation. Such a table will facilitate the making of such prisms, and also serve for comparisons of the two systems of numbering.

To prepare such a table, we have: *Given the index of refraction of the glass to find the refracting angle of a prism that will have a certain angle of minimum deviation.* In the accompanying figure, suppose the solid lines to represent a section of a prism, perpendicular to its edge, and the course of a ray passing through it with the minimum deviation, and the broken lines to be: a line bisecting the refracting angle of the prism, a line perpendicular to the surface of the prism at the point of incidence, and the extended direction of the incident ray; let i represent the angle of incidence, d one-half of the angle of minimum deviation, r one-half of the refracting angle of the prism, and n the given index of refraction.

By the law of sines,

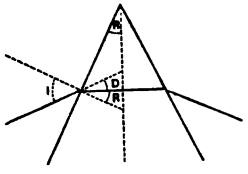

$$\text{sine } i = n \times \text{sine } r.$$

$$\text{But } i = r + d.$$

$$\text{Hence sine } i = \text{sine } r \times \text{cosine } d + \text{cosine } r \times \text{sine } d,$$

$$\text{or } n \times \text{sine } r = \text{sine } r \times \text{cosine } d + \text{cosine } r \times \text{sine } d,$$

From this, by transposition, reduction, and substitution, we get

$$\text{cotangent } r = \frac{n - \text{cosine } d}{\text{sine } d}.$$

Stating this as a rule: *From the given index of refraction subtract the cosine of half the angle of deviation to be produced; divide the remainder by the sine of half the angle of deviation, and the quotient will be the cotangent of half the required refracting angle.*

TABLE III.—REFRACTING ANGLES OF PRISMS NUMBERED BY THE ANGULAR DEVIATION THEY PRODUCE.

For glass with an index of refraction equal 1.54.

Angle of deviation.	Refracting angle.	Angle of deviation.	Refracting angle.
0.25°	0.46°	8°	14.63°
0.50	0.93	9	16.40
0.75	1.39	10	18.18
1.	1.85	11	19.93
1.50	2.78	12	21.67
2.	3.70	13	23.38
2.50	4.63	14	25.07
3.	5.55	15	26.74
3.50	6.48	16	28.37
4.	7.40	18	31.36
4.50	8.32	20	34.70
5.	9.23	25	41.97
6.	11.05	30	48.47
7.	12.85	40	58.30
		81	81.

This table very well illustrates the fact that the strength of a prism, that is, its power to cause deviation in the rays that pass through it, does not increase proportionally with the refracting angle of the prism. Thus, to cause a deviation of nine degrees, a prism is required to have a refracting angle of 16.4 degrees; but a prism to have nine times this deviating power needs to have not quite five times this refracting angle. This, of course, is the extreme case, and for weak prisms, less than 10°, the discrepancy is slight and of no importance in practice; but the scientific objection to such a system of numbering is very great.

A NEW METHOD OF NUMBERING PRISMS.

BY WILLIAM S. DENNETT, M.D.,
NEW YORK.

A FEW years ago ophthalmologists from all parts of the world, feeling the need of some common language to be used in reference to the eye as an optical instrument and to the lenses that are ordinarily used to correct its errors, agreed upon the diopter as a convenient unit of measurement for spherical and cylindrical lenses, and recommended its use.

Though the metric system is not without its faults and inconveniences, we have on the whole much reason to congratulate ourselves that this suggestion has been generally adopted.

Unfortunately, no attention was given at the time to the very faulty method of numbering our prisms, and now that muscular anomalies are claiming so much attention, we are likely before long to be called upon to adopt a common unit for prismatic glasses. This matter was discussed briefly at the ophthalmological section of the recent congress in Washington, and suggestions were called for.

The very general endorsement that modern writers on physics have given to the system of units and constants recommended by the London Philosophical Society, and now known the world over as the "C. G. S. System," is certainly well-deserved. Our method of numbering spherical and cylindrical glasses is in harmony with that system, and it is highly appropriate that the prismatic lenses which are so constantly used should be correspondingly named.

No better argument for a new nomenclature is needed than that given by Dr. Jackson in the paper just read, which shows that the working power of each prism is a transcendental function of the number by which it is known, and is not related to that number in such a way that it can be easily calculated. In fact, one needs to consult a table to find out the relative strength of the glasses with which he is constantly working.

Prisms as used clinically are of value on account of the change

in direction which they allow or produce in the visual axis, and hence the numbers of prisms should be so chosen that they will give a clear and definite idea of their relative angles of deviation so our unit prism should be our unit of angular measurement.

The C. G. S. System recognizes two units of angular measurement — the degree and the radian. The degree has much to recommend it, and though an arbitrary quantity and of no particular mathematical significance, our familiarity with its use, as well as the facility of computation with numbers that belong to a sexagesimal system, are points that ought not to be overlooked. On the other hand, the radian is a unit that has appeared in answer to the demands of modern geometry. It is much used in analytical science, and, other things being equal, should take precedence over any purely arbitrary quantity.

We shall have one very striking advantage in the choice of the radian as our unit on account of the seemingly accidental relation of the number which expresses its value in degrees to that which forms the decimal part of the index of refraction of some of the glass in common use. This makes it possible for us to have the working unit in the new system, based upon the value of the angle of deviation absolutely identical with the unit now in use, which is based on the value of the refracting angle, and so the change can be made with neither inconvenience nor confusion, and, as will be seen below, we shall simply write "Cr." instead of "Pr." in our prescriptions, and those who are inclined to use prisms so carelessly as to be satisfied with the old system will never know except by the name which system is being used, while those who appreciate and aim at something like scientific accuracy in the use of methods and instruments will find that the new system leaves nothing to be desired.

The radian, as is well known, is the angle which is measured by that part of the circumference of the circle that is exactly equal in length to the radius. Its value in degrees is 57.295 +. Fifty-seven degrees is of course too large an angle to be used as a working unit by ophthalmologists, but one one-hundredth part of it, or .57295°+ is the exact* deviation produced by a

* The calculation is accurate to within a few seconds. The prisms of the shops are liable to vary from five to twenty minutes.

one-degree prism made of light flint-glass, the refraction being estimated in air for the line D (Fraunhofer), which is the center and most luminous part of the normal spectrum.*

The calculation by which this result was obtained is here given by means of the formula which has just been used in the paper read by Dr. Jackson, except that D is taken to represent the angle of deviation, instead of half that angle. This modification is made on account of the fact that prisms as ordinarily used in test cases and trial-frames are not placed before the eye in the position of minimum deviation, but in a position such that one only of the refracting surfaces contributes to the displacement of the image. Whenever it is desirable that prisms should be prescribed to be worn in the position of minimum deviation, one can order the prism of double the refracting angle of half the number of centrads desired.

According to the formulæ referred to and the figure here given

$$\cot. r \sin. d = n - \cos. d,$$

in which,

d = angle of deviation;
r = refracting angle;
n = index of refraction sought;

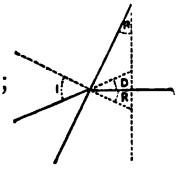

then

$$\cot. r = 57.295;$$
$$\sin. 34' 22'' = .00999;$$
$$\cos. 34' 22'' = .99995.$$

Substituting and transposing

$$n = .99995 + 57.925 \times .00999$$

reducing

$$n = 1.57233,$$

the index of refraction which we require to make the one degree prism equal to the centrad.

The index of refraction given by Everett for D (Fraunhofer), for light flint-glass, is 1.57403, and the error caused by assuming these two numbers, which are the same up to the third decimal to be identical, is less than two seconds.

In recapitulation, then, the writer desires to recommend that we adopt, for our absolute unit of angular measurement, the

* See Everett's "Units and Physical Constants."

"radian," and for our working unit, the "centrad," and that we define the ideal centrad as an achromatic prism that produces in light passing through it in a direction perpendicular to one of its faces, a deviation of one one-hundredth of a radian, or .57295°+, equal to 34′ and 22.62″, that for ordinary working prisms of small refracting angle, where achromatism is of no particular importance, we use a prism of light flint-glass whose index of refraction for D (Fraunhofer), is 1.57233, and whose refracting angle is 1°; that multiples and submultiples of this unit be designated by numbers that vary directly as the angle of deviation produced; that we distinguish between the new system and the old by writing "Cr." in the place of "Pr." when we are speaking of prisms which are numbered by this system; that we use in our clinical work prisms made as above described, or if made of glass differing from the standard in its refractive power, this difference shall be compensated for by a variation in the refracting angle.

In the table below will be found the proper refracting angle for prisms made in accordance with the above suggestions.

Table showing the refracting angle in degrees necessary to produce a given amount of deviation in centrads.

Index of refraction, 1.57233.

Centrads.	Degrees.	Centrads.	Degrees.
1	1.	11	10.52
2	1.58	12	11.39
3	3.3	13	12.18
4	3.59	14	13.59
5	4.59	15	14.23
6	5.58	16	15.11
7	6.55	17	16.28
8	7.54	18	17.9
9	8.50	19	17.42
10	9.30	20	18.41

DISCUSSION.

DR. EDWARD JACKSON, Philadelphia. — Dr. Dennett's suggestion is a radical one, but I see no objections to it from a scientific standpoint. The only change that would be required,

to make a prism of one centrad correspond to one degree of refracting angle, would be to use a flint-glass having a higher index of refraction. This is possible. The tendency has been to raise the index of refraction of crown glass. It is now about 1.54. Many years ago it was nearer 1.52. The only objection would be that the glass would be a little softer, and probably cost more.

DR. W. S. DENNETT, New York — The index of refraction that I quoted is from the book of J. D. Everett, published with the approval of the Physical Society of London. We could use flint-glass as well as any kind. The material is at our service.

EXTENSIVE VASCULAR GROWTH IN VITREOUS.

GEORGE C. HARLAN, M.D.,

PHILADELPHIA.

Mrs. S. D. R., æt. 50, came to the Pennsylvania Hospital on Nov. 22, 1887. She stated that she had always had good sight until June, 1886, when the left eye was attacked with what was pronounced iritis. It was violently inflamed, and became nearly blind. There was gradual improvement until the following September, when she resumed her occupation as seamstress (the right eye remaining unaffected), and continued to work until June, '87. Then, after sewing until late one afternoon, the right eye felt tired and the sight became dim, and the next day she could not see to work. Since then vision had been variable, but never good. This rather vague history was all that could be obtained. With correction of a low degree of astigmatism V = $\frac{20}{40}$ in the right eye, and $\frac{20}{50}$ in the left.

The right eye presented a very peculiar ophthalmoscopic appearance. The fundus was slightly hazy, but could be seen pretty distinctly, as if through a thin veil, by accurate focusing. There were several dull yellowish-white spots about the macula, the remains of old hemorrhages, but no recent extravasations. The vitreous was quite transparent and free from shreds. The disc was obscured by a congeries of contorted vessels, and by following these forward with convex lenses a beautiful vascular

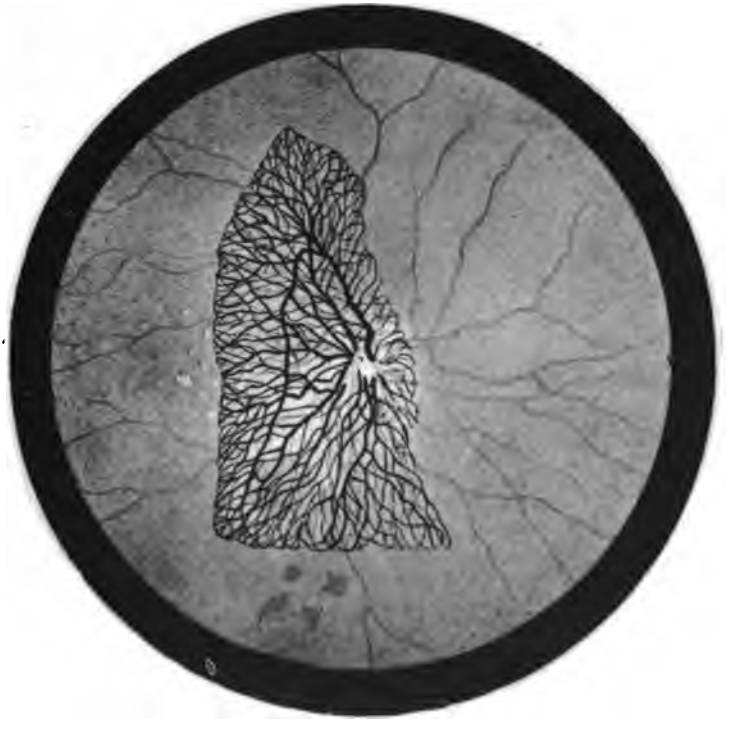

P. N. K. SCHWENCK, M.D., DEL. F. GUTEKUNST, PHOTO.

net-work could be seen, forming a delicate veil-like membrane stretching forward and outward at an angle of about 45°. Its anterior margin, which was extremely delicate but sharply defined, and was formed by anastomosing capillaries, could be best seen with + 4 D. The vessels which, by rapid subdivision and inosculation, formed this net-work, came directly from the disc and seemed to have no connection with the retinal vessels, which could be readily seen through the veil in their normal position. There was nothing like a stroma — not even an opacity — nothing but vessels which offered but little obstruction to a view of the parts beneath them.

In the left eye there were also inosculating vessels stretching forward into the vitreous from the disc, but not nearly so numerous as in the right. The vitreous was slightly nebulous, and there were a few small uveal spots on the lens and the remains of a hemorrhage at the macula. The urine contained a trace of albumen, but no casts.

On the 13th of December, four patches of recent retinal hemorrhage were seen on the lower anterior part of the field in the right eye. On the 2d of March, there were several more quite large extravasations above and to the nasal side, and one just below the disc, and vision was reduced to $\frac{20}{70}$, but there had been no change in the vascular membrane, and no disturbance of the vitreous.

It is hardly possible to represent this condition accurately on paper, but the accompanying drawing by Dr. Schwenk gives a very fair idea of it, except that the lines are rather heavy and give the impression of a denser membrane. The patient was seen by Drs. Norris and Jackson, who confirmed the results of my examination in all respects.

This case presents so many points in common with those reported by Dr. Theobald and Dr. Carmalt (Trans. Am. Oph. Soc'y, 1887,) that we may suppose that the vessels had their origin in the same way from vitreous hemorrhages. It differs from them, however, in the fact that the vitreous was clear and free from shreds, and even the spaces in the meshes of the membrane remained unclouded. It is so difficult to understand how sufficient hemorrhage to give rise to such an extensive

development of vessels could occur without leaving any other mark upon the vitreous, that without the record of these cases before me, I might be inclined to suspect an anastomotic aneurism.

Since writing the above, I have had an opportunity (July 24, 1889) of examining this case again, and decided changes noted in the ophthalmoscopic picture confirm the view of a comparatively recent and inflammatory origin of the vascular membrane. In the right eye, the vitreous was somewhat hazy, though there were no floating shreds. This and a slight keratitis punctata made the fundus much less distinct than at former examinations, but the details could be made out without much difficulty. There were no fresh hemorrhages, and the marks of the old ones could not be distinguished except at the macula, which presented much the same appearance as at the first examination. In the vascular membrane, most of the smaller vessels had disappeared, and the greater part of those remaining seemed empty — reduced to dark lines scarcely recognizable as vessels. The sharp outlines of the membrane were destroyed, and a ragged appearance substituted. V., with $+50 + 50$ cyl. $90 = \frac{20}{50}$. The left eye showed very little change since first seen, and V., with $+25 + 1$ cyl. ax. $90 = \frac{20}{30}$. Examination of urine gave a negative result. The history of the patient since she came under observation shows that the vascular growth interfered remarkably little with vision, which varied directly with the condition of the retina and the transparency of the media.

SOME VAGARIES OF ACCOMMODATION.

BY D. COGGIN, M.D.

I.

A CASE OF APPARENT AH. WHICH GRADUALLY PASSED INTO MYOPIA.

April 24, 1880, L. F. G., a boy of nine years, sought advice because of pain in his eyes (more in the left) on reading music when playing on the violin. V. = $-\frac{4}{5}$ *o. d.* and $-\frac{4}{6}$ *o. s.* A. = 10, and V. = $\frac{40}{50}$ *o. u.* Preferred + 1 D. cylinder axis horizontal *o. s.* and + .75 cylinder axis horizontal *o. d.* and V. = $\frac{4}{4}$ or $\frac{50}{50}$ *o. u.*

It being desirable not to take the boy from school, his accommodation was not paralyzed — at that time atropine being the available mydriatic — but the cylinder glasses referred to were ordered, and they gave relief. Both parents are am.

Over two years later (August 28, 1882) he was seen again. Recently, pain on using his eyes. Atropine (0.03 — 4.0) for four days. V. = $-\frac{4}{4}$ *o. u.* + .50 D. c. ax. horizontal = $\frac{4}{4}$. Sept. 7th, V. = $\frac{4}{4}$. A. = 10 and V. = $\frac{55}{50}$. Horizontal line in Green's Dial perhaps the clearest; —.50 c. axis vertical corruts. To omit use of his + c. glasses as they tire. Eyes feel better.

April 22, 1883. Letters indistinct and lids twitch of late. V. = $\frac{4}{6}$ *o. u.* After four days of atropine instillations, V. = $\frac{4}{4}$. To discontinue.

May 8th, V. = $\frac{4}{4}$ *o. u.* A. = 12 and V. — $\frac{55}{50}$. 40° *out* lines in dial the blackest, but — .75 s. clears and is preferred to a cylinder. A zinc and boric acid lotion ordered for the relief of a conjunctivitis.

June 22d, V. — $\frac{4}{5}$ — .75 D = $\frac{4}{4}$ and dial clear, so gave — .75 glasses to use at will.

Jan. 16, 1886. For a month some dizziness, and letters waver on reading. V. = $\frac{4}{8}$. A = 12 and V. = $\frac{40}{50}$. — 1.5 = $\frac{4}{4}$, and prescribed for music and for distance. Is taking tonics and the like.

March 20, 1887. Eyes still trouble him. Dyer's exercise, the use of prisms, etc., were all declined, so he was given a lotion containing cocaine and pilocarpine.

June 2, 1889. The old story, if he uses his eyes. At present there is less accommodative strain, as the patient is out of school. V. = $\frac{5}{24}$ *o. u.* − 1.5 = $\frac{5}{5}$. No corneal As. by shadow-test — my. only. It will be noticed that, unlike the cases of H. passing into M. that were reported before this society by Dr. Risley two years ago, this one first presented symptoms of Ah., which are, however, no longer present. It would seem as if, in this instance, there had been a partial contraction of both ciliary muscles (according to Javal and other observers), which produced a lenticular As. The frequency with which ordinary spasm of the accommodation is encountered — especially among school-children — and the rarity of cases like the one referred to in these notes, are somewhat remarkable.

(Since writing the above, a woman of twenty years sought treatment because of pain in her eyes when doing trying work in a woolen mill. V. $\frac{5}{6}$ *o. u.* − 75 c. ax. vertical = $\frac{5}{4}$ and dial clear. After the use of homatropine V. = $\frac{5}{6}$ *o. d.* $\frac{5}{12}$ *o. s.* + .75 *o. d.* and + 1.25 *o. s.* = $\frac{5}{5}$. No As. Here, then, was an example of seeming Am., but which, on paralyzing the accommodation, was found to be H.)

II.

RECURRENT SPASM OF THE ACCOMMODATION. (H. *o. d.*, MY. *o. s.*)

Sept. 8, 1887, G. R. N., aged 14 years, a Phillips Academy student, first came to me because of asthenopic symptoms. V. $\frac{5}{12}$ *o. d.* $\frac{5}{24}$ *o. s.*

Two years before, − 1 D. glasses had been prescribed for distance, with which his V. = $\frac{5}{5}$ *o. u.* A. = 12, and V. = $\frac{50}{50}$ *o. u.* Nose broad above — almost amounting to epicanthus. H. by shadow-test. No As.

Homatropine hydrobromate (1-60) failing to remove the spasm, atropine sulphate (0.03-8.) was ordered to be used morning and night.

Oct. 11th, atropine instillation for three days and spasm less. V. = $\frac{5}{8}$ *o. d.* $\frac{5}{18}$ *o. s.* To continue its use.

Oct. 27th, noon, V. = $\frac{5}{5}$ *o. d.* — $\frac{5}{5}$ *o. s.* Overcomes 8° prisms, base out. To relieve muscular fatigue, advised + .75 glasses to wear when studying evenings.

July 2, 1888. The + spherical glasses less restful of late. Is again unable to see off. V. = $\frac{5}{18}$ *o. u.* With — 1. *o. d.* and — 1.25 *o. s.* V. = $\frac{5}{5}$.

Sept. 8th, eyes have been atropinized for two weeks. V. $\frac{5}{5}$ *o. d.* $\frac{5}{8}$ *o. s.* — .50 = $\frac{5}{5}$ *o. s.* No pain on studying since he began to wear the + .75 glasses. The refraction of the left eye being clearly myopic it was suggested that the + glass should be removed from the left side of the spectacle frame that he wore when studying.

Oct. 6th, reported that he was doing well and that he preferred to study with, rather than without, the + .75 S. in front of his right eye.

March 9, 1889. Return of spasm, but unaccompanied by pain unless he goes without his somewhat unique monocular when studying. V. $\frac{5}{8}$ *o. d.* $\frac{5}{18}$ *o. s.* A. = 12, and V. $\frac{60}{50}$ *o. d.* A. = 16, and V. = $\frac{55}{50}$ *o. s.* — .50 = $\frac{5}{5}$ *o. d.* — 1 = $\frac{5}{5}$ *o. s.*

Ophthalmoscopic image is still H. of the right eye and My. of the left. The spasm of the right eye is less — though the use of the + glass has not prevented its return — as shown by the increased acuteness of vision and also by the weak negative glass that is required to neutralize it. Whether the refraction of the right eye will, like that of the left, eventually become My. is a question that can best be answered later.

III.

TEMPORARY ANOMALY OF SIGHT OCCURRING DAILY.

Feb. 12, 1884, Miss S., aged 43, a private school teacher, presented symptoms of Pr. V. $\frac{4}{4}$ *o. u.* No H. A. = 3, and V. = $\frac{55}{50}$. + .75 D. = $\frac{24}{50}$, and this number of glasses was ordered and afforded relief.

Sept. 18, 1888. For over two months, on closing her school at one o'clock, she had every day been unable to recognize people across the street, although she could see as well as ever before beginning her daily school work.

She was in health, and was not feeling tired. V. = $\frac{5}{18}$ *o. u.* No glasses help. Perforated disc = $\frac{5}{5}$. No opacity in lenses. A zinc lotion ordered, there being a conjunctivitis.

Oct. 4th, continues to see well only in the morning. Vertical lines in dial the brightest. No c. or s. glass improves vision.

Dec. 3d, noon, V. $\frac{5}{18}$. Of late, when tired, has seen double with either eye covered or with both together, as in incipient cataract. Sees spectrum colors nights, occasionally. T. and field of vision normal.

Dec. 4th, morning, V. $\frac{5}{5}$ — after a night's rest.

Jan. 5, 1889. V. = $\frac{5}{18}$.

May 29th, V. $\frac{5}{24}$. Gave + 1.5 glasses for evening use — her old ones (+.75) being insufficient for newspaper type.

June 26th. When last seen, Miss S. had V. of $\frac{5}{5}$ in the morning, and only of $\frac{5}{8}$ about four hours later — no glass improving it. At five metres from Snellen's test-type she saw a second row of letters below, but in contact with, the true one, singly or with both eyes. A. = 4, being greater, apparently, than at any time when it was observed during five years.

Though no ischæmia of the retinal vessels was detected, it is possible that prolonged use of the eyes may have occasioned what has been called anæsthesia of the retina. Still, it is to be noticed that, after correcting the Pr., the sight for near was not affected, nor was that for distance, on using the perforated disc. As before stated, the patient is in health and has not presented any symptoms of mental perversion.

The double vision was not wholly unlike that seen in scotoma scintillans, but this lasted longer, and it was not followed by headache.

Believing the trouble to be accommodative (due to exhaustion of the ciliary muscles), no special treatment was prescribed, and as the daily disturbance in sight is diminishing it is reasonable to expect that it will ultimately pass away. (In fact, on the 6th instant, when Miss S. had enjoyed a week's rest, her sight, at noon, was $\frac{5}{4}$ with both eyes.)

PERISCOPIC CYLINDRICAL AND SPHERO-CYLINDRICAL GLASSES.

BY GEORGE C. HARLAN, M.D.,

PHILADELPHIA.

AT the meeting of the Society in 1885, I gave a description of "Börsch's sphero-cylindrical combination lens, ground on one surface only," and explained the method of its manufacture. I had then no experience in the use of this glass, which was quite new, and referred only incidentally to what I have since found to be its chief advantage.

The superiority of the "periscopic" form of lens, or meniscus, when high powers are required, is, I believe, universally admitted, and its use is quite general in the case of spherical glasses. This has not been the case, however, with cylindrical and sphero-cylindrical glasses, as opticians generally have not undertaken to grind them in this form. The lens to which I wish again to call the attention of the Society consists of crossed cylinders ground on one surface of the glass, the other side being left for any desired spherical curve. In this way a meniscus may be produced. Here, for instance, is a combination lens giving the effect of $+4 \frown +2$ cyl. To produce this effect crossed cylinders of 4 and 6 are required, supposing the other surface of the glass to be left plain. If we wish to give the periscopic form to this glass, it can be done by making the cylinders 6 and 8, and grinding a -2 sph. on the other side. If a simple cylinder is needed, the spherical curve must equal that of the weaker cylinder.

My experience with these glasses has been very satisfactory, but I have been particularly encouraged to bring the subject again before the members of the Society by the advice of Dr. Javal, of Paris, who has himself worn a pair for several years. He has derived great comfort from their periscopic effect, and assures me that he considers them very valuable glasses, and not so well known as they should be.

NOTE. — Since the meeting of the Society I learn from a recent publication by Dr. Geo. J. Bull, of Paris, entitled, "Lunettes et Pince-nez," that glasses similar to these have been made, with more or less success, before, but that they have never been in general use. Dr. Bull describes them under the head of "verres toriques." "The tore (Latin *torus*) is the surface engendered by a circle which turns about an axis situated on the plane of the circle." A familiar example of the torus is the circular convex moulding at the base of an architectural column. A glass ground upon a wheel having this form will present two cylindrical curves, at right angles to each other, one depending on the radius of the wheel, and the other upon the radius of the convexity of its rim. The effect of such a wheel is practically the same as that of Börsch's apparatus with the pendulum movement, and it might be used in the manufacture of glasses of high power but would not be adapted to grinding lenses of long curvature. A one dioptric curve for instance, would require a wheel six feet in diameter. Dr. B. gives the history of two attempts to make these glasses.

M. Cassas, a painter, was greatly annoyed by his inability to see horizontal lines distinctly, and applied to all the physicists and opticians he could find for some means to correct his defect. After a search of more than twenty years, Guscipi, an optician of Rome, finally, in about 1840, made him a pair of glasses which "passablement" corrected his astigmatism. The anterior surface of these glasses was a convex spherical, and the surface toward the eyes a concave tore. (Annals d'oculistique, 1866, v. LV, p. 107.)

There seem to have been no further attempts in this direction until M. Georges Poullain corrected a compound hypermetropic astigmatism in his own eye with such a glass, and described his apparatus for manufacturing it to the French Association for the Advancement of Science, in February, 1877. The effect of this glass was $+3.50 \frown +2$ cyl. As the radius of its spherical curvature was an inch and a half, it must have been excessively heavy, and M. Poullain also experienced inconvenience from spherical aberration.

It would seem that "toric lenses" is the proper designation of these glasses.

THE ABSOLUTE STATIC REFRACTION OF THE EYE.

BY EDWARD JACKSON, M.D.,

PHILADELPHIA.

THIS paper is based on the study of the refraction in 4,000 eyes, determined with complete paralysis of the accommodation obtained by the use of one of the mydriatics in all cases under fifty years of age, and in some up to the age of fifty-five. All cases presenting during the time covered, in which for any reason the refraction of the eyes was thus accurately determined, are included. In most cases the measurements were made by myself, and in all others under my immediate supervision. Of these eyes 2,031 were those of private patients, and 1,969 were of patients presenting themselves at the Dispensary of the Philadelphia Polyclinic. For the tabulation of the latter I am indebted to Dr. T. B. Schneideman, Instructor in Refraction and Ophthalmoscopy in that institution. The two sets of cases having been tabulated independently, the greatest difference they presented in the relative proportions of the different forms of ametropia was four per cent. in the proportions of hyperopia, there being 32.8 per cent. of hyperopia among the dispensary patients, and but 28.5 per cent. among the private patients. To balance this the private patients showed slightly higher percentages of simple hyperopic and mixed astigmatisms, and of emmetropia.

The proportions of the different forms of ametropia were as follows:

Compound Hyperopic Astigmatism,	1610	eyes, or	40.2	per cent.
Hyperopia,	1225	"	30.6	"
Compound Myopic Astigmatism,	361	"	9.	"
Mixed Astigmatism,	267	"	6.7	"
Simple Hyperopic Astigmatism,	249	"	6.2	"
Myopia,	158	"	4.	"
Simple Myopic Astigmatism,	79	"	2.	"
Emmetropia,	51	"	1.3	"

Among the many statistical studies of the refraction of the eye there are but very few that deal with the relative frequency of the various forms and degrees of ametropia as they occur in practice. However, in a paper read here last year, and published in our transactions, p. 48, Dr. S. M. Burnett has given the refraction of 576 eyes, upon the study of which his paper was based. Of these, he says: "They can, in no way, be regarded as selected cases, since they are taken as they were recorded in my case-book, and represent very fairly, I think, the eyes that are brought to the oculist for examination." It is interesting to compare these statistics, (which agree substantially with the statistics of 806 astigmatic eyes given in Dr. Burnett's "Treatise on Astigmatism,") with the figures given above, thus:

	Burnett.					Jackson.	
Comp. H. Astigmatism, .	55	eyes,	or 9.5	per cent.,	against	40.2	per cent.
Hyperopia, . . .	59	"	10.2	"	"	30.6	"
Comp. M. Astigmatism, .	63	"	10.8	"	"	9.	"
Mixed Astigmatism, .	8	"	1.3	"	"	6.7	"
Simple H. Astigmatism, .	96	"	16.6	"	"	6.2	"
Myopia, . . .	55	"	9.5	"	"	4.	"
Simple M. Astigmatism, .	140	"	24.3	"	"	2.	"
Emmetropia, . .	151	"	17.8	"	"	1.3	"

The disagreement shown by this comparison of statistics is very serious. Indeed, the order of relative frequency is almost reversed.

How is this to be accounted for? Of my own statistics I can only affirm my full confidence in their substantial accuracy. In every case the state of refraction was determined by the refraction ophthalmoscope, and also by test-lenses, and in a majority it was also measured by the shadow-test. Again, I do not entertain a doubt of the general carefulness and competence and high scientific fidelity of Dr. Burnett's investigations. Nor can it be that the number of eyes taken as the basis of his statistics is so small as to permit any great departure from the general average relative frequency of the different forms of ametropia. No consecutive five hundred eyes in my series shows any such variation from the standard of all. Then, too, the agreement with Dr. Burnett's other statistics precludes such an explanation. Finally, there seems to be no adequate reason

to suppose that the eyes presented for examination in Washington are in this respect radically different from those presented for examination in Philadelphia. There is but one thing that I can find to account for the difference in question, and that is that Dr. Burnett made over 89 per cent. of his determinations of refraction without the use of any mydriatic. The character of the discrepancy accords perfectly with this explanation. The relative scarcity of compound as compared to simple hyperopic astigmatism, of hyperopia as compared with emmetropia, the relative excess of myopia, and myopic astigmatism of all forms, indicate that Dr. Burnett's statistics are vitiated by the presence in the eyes tested of unrelaxed accommodation.

The frequency of the different degrees of refractive error among the 2031 eyes seen in private practice are given in the next table. The first column gives the different degrees, with intervals of 0. 25 D. up to 2 D., and above that with intervals of one diopter as far as the different refractive errors go. The second column gives the number of eyes presenting each degree of hyperopia. It includes not only simple hyperopia, but the hyperopic astigmatisms,* and the cases of mixed astigmatism in which hyperopia was predominant; in short, all cases in which the antero-posterior axis of the eye-ball was too short. In the same way the third column gives all the eyes having too long an antero-posterior axis, the myopias, myopic astigmatisms, and mixed astigmatisms with predominant myopia. The fourth column gives the different degrees of astigmatism of all kinds, the fifth the hyperopic astigmatisms, including the mixed with predominant hyperopia; and the sixth gives the myopic astigmatisms including the mixed with predominant myopia.

On the first line the number 58, opposite zero, represents not only the cases of emmetropia, but includes twenty cases of mixed astigmatism in which the hyperopic and myopic meridians, being just equally ametropic, balanced, the antero-posterior axis being really of the proper relative length. The 696 on the same line is the sum of the emmetropias, hyperopias, and myopias, that is, all eyes having less than a quarter diopter of astigmatism. It will be found that the sum of the hyperopic

* The degree of hyperopia in astigmatisms being taken as the mean of H. in the meridians of greatest refraction and least refraction.

astigmatisms and the myopic astigmatisms do not equal the sum of the fourth column, giving all the astigmatisms, by twenty, the number of mixed astigmatisms in which neither hyperopia or myopia predominated, and which, therefore, could not be included in either of the other columns. The degree of astigmatism in these cases can be ascertained from the table by comparing the figures on the same line in the fourth, fifth, and sixth columns, and noticing the discrepancies between the number in the fourth and the sum of the numbers in the fifth and sixth, wherever such discrepancies occur.

Of course, where the change is made between an interval of one-fourth diopter and an interval of a whole diopter, a noticeable break occurs in the diminution of the figures to be observed in reading down any column. It is also worth while to mention that higher degrees of myopia, and rather a larger number of the very high degrees of it, were met with in dispensary practice, than among the cases from private practice here tabulated. The hyperopias include no cases of aphakia.

The totals at the bottom of the table do not include the figures on the first line.

Degree in D.	Hyperopia.	Myopia.	Astigmatism.	H. Astig.	M. Astig.
0.	59	..	696	..	..
0.25	160	43	370	328	42
0.50	229	43	343	293	42
0.75	210	27	180	152	28
1.	252	21	92	68	21
1.25	179	18	65	51	14
1.50	111	21	58	35	22
1.75	88	13	25	16	9
2.	68	13	29	17	12
2.25 to 3.	167	36	81	40	37
to 4.	85	30	49	28	18
5.	29	19	30	17	13
6.	20	26	11	6	5
7.	7	8	1	..	1
8.	3	8	..	..	..
9.	3	4	..	..	..
10.	2	1	..	..	..
11.	1	7	1	..	1
12.	1	2	..	..	..
13.	1	4	..	..	..
14.	..	4	..	..	..
15.	..	2	..	..	..
16.	..	1	..	..	..
20.	..	3	..	..	..
23.	..	1	..	..	..
	1,616	356	1,335	1,050	265

Of course, such statistics are not to be regarded as indicating accurately the relative frequency of different states of refraction in the community at large. They doubtless underrate the frequency of emmetropia and hyperopia, and of the very low degrees of myopia, and, to a less extent, of astigmatism; causing relatively high percentages of myopia, and astigmatism above the lowest degrees. Still, making allowance for such tendencies, they probably come nearer to representing the true relative frequency of the different forms and degrees of ametropia throughout the whole community than any statistics obtained by other methods. At least, it is worth while to consider them briefly from this point of view.

First, with reference to the relative length of the antero-posterior axis: 80 per cent. of all eyes are hyperopic; one-half have hyperopia of 1.25 D., or less. The maximum of frequency extends from 0.50 to 1 D., including over 34 per cent. of all. Doubtless, this state of affairs comes down to us from uncivilized ancestors. Not that, under any circumstances, the hyperopic eye is better fitted for the service of its possessor than the emmetropic; but that, with uncivilized men, myopia was almost as serious a disability as blindness, and therefore to be certainly escaped, even if it were necessary, in most cases, to overstep the desired mean, and encounter the minor inconveniences of hyperopia. In a state of society in which a low degree of myopia is not *per se* much more dangerous than a corresponding degree of hyperopia, we can expect the tendency of evolution to gradually shift the maximum closer to the emmetropic standard. A very small part of the existing myopias may be regarded as due to such a movement, but the majority are certainly pathological.

When we consider the perfection of the developmental processes that such symmetry of refraction presupposes, it seems wonderful that more than one-third of all eyes are free from appreciable regular astigmatism, and that in less than one-third does the astigmatism amount to more than 0.5 of one diopter. It seems pretty certain that complete freedom from astigmatism is the standard toward which evolution has been directed all along.

Series of cases of hyperopia diminishing or passing over into myopia while under observation have been reported by Dr. S. D. Risley [Transactions for 1884, p. 751, and 1887, p. 520] and Dr. Wm. F. Norris [Transactions for 1886, p. 369]; and both these writers regard astigmatism as an important factor in the causation of such changes of refraction. If there be a connection between astigmatism and myopia, statistics like these should give some evidence of it Let us examine them with reference to this point. The total number of hyperopic eyes was 1,616, and the cases of hyperopic astigmatism number 1,050. That is, 65 per cent. of all hyperopic eyes are astigmatic. Of the 356 myopic eyes, 262, or 73.6 per cent., are astigmatic. Here is a slight preponderance of astigmatism among myopic eyes.

It must be remembered, however, that the larger number of cases of astigmatism are of quite low degrees, and if there be a connection between myopia and astigmatism, we should find more definite evidence of it on studying the higher degrees of the latter. Taking now only the eyes presenting one diopter, or over, of astigmatism, we find that there were 278 among the hyperopic, and 149 among the myopic. That is, the proportion of eyes having one diopter or over of astigmatism is among the hyperopic 17.2 per cent., and among the myopic 41.8 per cent.

These figures indicate pretty clearly a connection between astigmatism and myopia. This connection may be either that astigmatism causes myopia, as Risley and Norris suppose, or that both astigmatism and myopia are effects of the same process, one of not entirely uniform distension of the globe — a not improbable explanation. In the former case, we would expect the astigmatism to be present before the myopia; in the latter we would expect them to appear or progress together. Cases of both kinds have been published. But among the published cases, as among cases of my own, unpublished, those in which a very considerable degree of astigmatism ante-dated the myopia, or tendency toward myopia, are decidedly in the majority.

With reference to the direction of the principal meridians of refraction in astigmatism, it was found that in these 2,566 astigmatic eyes, the direction of the meridian of greatest refraction —

that is, the direction of the axis of the convex cylinder, or perpendicular to the axis of the concave cylinder that would correct the astigmatism, was situated as follows:

Vertical, 38 per cent.

Twenty degeees either side of the vertical, from 70° to 110°, 32.7 per cent.

Horizontal, 7.4 per cent.

Twenty degrees either way from the horizontal, from 160° to 20°, 7.4 per cent.

Oblique, from 25° to 65°, and from 115° to 155° inclusive, 14.5 per cent.

These figures do not materially differ from those obtained by other observers. No noticeable difference was found between the number of eyes in which this meridian inclined upward and toward the median line, and the number in which it inclined upward and from the median line.

DISCUSSION.

DR. W. S. DENNETT, New York.—The cases given by Dr. Burnett were those in which he had used the instrument for examining the corneal curvature, and it would not be quite fair to compare them in some other way in which the ciliary muscle could have taken part.

DR. PETER A. CALLAN, New York.—These statistics are interesting, but we must not put too much weight on them. This reminds me of a little story in a German periodical. A horse-dealer called his son to come and ride a horse. "How shall I ride him," the son inquired, "to buy or to sell?" This covers the case. A patient comes, and we can find astigmatism or not, as we wish. I believe that very little value can be attached to statistics, for emmetropia exists only as an accident.

DR. H. KNAPP, New York—Where did you put the limit of astigmatism?

DR. EDWARD JACKSON, Philadelphia.—The limit of astigmatism was put at 0.25 D. More than one-third of the eyes fell below it. Dr. Burnett's paper was in reference to the curvature of the cornea in different kinds of ametropia. The figures which I have quoted are those of the number of cases of the different forms of ametropia. He assumes that these figures represent actual cases of myopia, hyperopia, etc., and on them bases his paper, stating that in a certain form of ametropia, the curvature was so and so.

THE EMPLOYMENT OF OLEATE OF VERATRIA TO FACILITATE THE DETERMINATION OF ERRORS OF REFRACTION.

BY SAMUEL THEOBALD, M.D.,
BALTIMORE.

IF THE use of a mydriatic eliminated all the difficulties and uncertainties which frequently attend the determination of the more complicated forms of ametropia, we would unquestionably be justified in paralyzing the accommodation in every such case, notwithstanding the temporary inconvenience which the patient experiences from this procedure; but, I apprehend, few persons of considerable experience will claim that it really does this. In simple H. it enables us, as a rule, without much difficulty to determine the total error of refraction, and in simple M., by eliminating ciliary spasm, it usually gives us a much more trustworthy result than can be otherwise obtained; but, in the measurement of astigmatism, the help which we derive from the employment of a mydriatic is, unfortunately, by no means so efficient. The total refractive error of the eye, apart from the astigmatism, can, undoubtedly, be more exactly determined, but the actual amount of astigmatism, in many cases, is as difficult, or as impossible, of ascertainment with the eye under the influence of a mydriatic as with the accommodation in its ordinary state of activity. In a word, *while symmetrical ciliary spasm is usually suppressed and latent hypermetropia rendered manifest by the application of a mydriatic, asymmetrical ciliary spasm and latent astigmatism are but little, if at all, influenced by it.* Indeed, it has seemed to me, not infrequently, that *the capacity of the eye for what may be termed asymmetrical accommodation is actually greater when it is under the influence of a mydriatic than when it is not.* And this has disposed me to believe *that as in the iris, so in the ciliary muscle, only the circular fibres are paralyzed by the mydriatics that are commonly employed, while the radiating fibres, which we may safely assume have most to do*

with asymmetrical accommodation, like the radiating fibres of the iris, are actually stimulated by them. However this may be, there can be no doubt that in many cases the wearing of cylindrical glasses renders manifest, after a time, a great deal more astigmatism than can at first be discovered even by the liberal use of a mydriatic. That the true direction of the meridians of greatest and least refraction can be more accurately ascertained with the accommodation paralyzed than without is, to say the least, problematical; while, on the other hand, it cannot be denied that a widely dilated pupil is an obstacle, and in some instances a serious obstacle, to the exact determination of the refractive condition of the eye as it exists in ordinary vision.

Influenced by these several considerations, I have found myself of late less frequently resorting to mydriatics in my refractive work — especially in the examination of astigmatism — than I formerly did. My usual course of procedure is, first, to ascertain as accurately as I can the total ametropia by means of the ophthalmoscope; then, to measure carefully, by the vertical diplopia test, the relative strength of the external and internal recti muscles at 13″ and at 20′; and, finally, to determine the manifest error of refraction with glasses. If the knowledge of the true refractive state of the eye which I obtain with the ophthalmoscope is less exact than that which can be gained by the use of a mydriatic, it is at least, in many cases, sufficiently exact, when supplemented by the information derived from the muscle test and the trial with glasses, to indicate the character and strength of the *spherical* glass with which the cylinder should be combined; and this, I believe, is as much as, and sometimes more than, the mydriatic does for us. For example, if in a case of compound hypermetropic astigmatism we find, with the error of refraction uncorrected, 2° or 3° of insufficiency of the internal recti muscles at 20′ and 6° or 7° at 13″, it matters very little to us, in most cases, what the *total* hypermetropia may be, since the state of the muscular balance would contra-indicate the correction of any part of that which was latent. So, also, in astigmatism apparently mixed, the discovery of insufficiency of the external recti muscles of appreciable amount would lead us to suspect that the myopic element was

not real, but the result of ciliary spasm, and having confirmed this by careful *binocular* testing, as we very often can, we should be kept from the error of prescribing, in such a case, a concave spherical or cylindrical glass, just as would have happened had we employed a mydriatic. Again, in compound myopic astigmatism, with the myopia at all considerable in degree, the absence of relative divergence at 13″, with the vertical diplopia test, would, in the first place, make us suspect that the real myopia was less than the apparent, and, in the second place, would prevent our correcting, for near vision, as large a portion of the myopia as we otherwise would have done.

On the other hand, the cases in which it would be unwise to prescribe glasses without first using a mydriatic are usually fairly well indicated by the tests which I have described. For example, if in a case of compound hypermetropic astigmatism, in which there was but little manifest hypermetropia, we should find well-marked insufficiency of the external recti muscles at 20′, we would without hesitation resort to the use of a mydriatic, because we should be warranted in suspecting the existence of a considerable amount of latent hypermetropia, and because, in order to restore the normal muscular balance, we should wish to neutralize a large part of this.

The great difficulty, however, which I experience in dealing with cases of astigmatism — and this difficulty is the same, as has been said, whether a mydriatic be employed or not — is in determining the exact strength of the *cylindrical* glass, not in deciding upon the spherical glass which is to be combined with it. Is the astigmatism discoverable in a given case the total astigmatism of the eye, or is it only that which is manifest, and is there an additional portion rendered latent through the action of the ciliary muscle? or, on the other hand, is the apparent astigmatism greater (as sometimes happens) than the real? Shall I give the weakest of several cylinders which, according to the line and letter tests, seem to correct the astigmatism equally well, or shall I not? These are the questions which are constantly presenting themselves to my mind. And it is in the endeavor to solve these questions that I believe I have derived some help from the action which I find veratria exerts upon the accommodative apparatus of the eye. I may add

here, also, that my experience has led me to formulate a rule which, though it is doubtless subject to many exceptions, has been of practical value to me in this same direction. It is as follows: In astigmatism *according to the rule* we need correct only that which is readily made manifest, first, because in this form of ametropia latent astigmatism is less often met with; second, because, even if the whole defect be not fully corrected, the asthenopic symptoms will probably be entirely relieved for an indefinite period; third, because the slightest over-correction of the astigmatism will certainly give rise to serious annoyance. On the other hand, in astigmatism *against the rule* we are warranted in correcting fully every particle of the defect which we can render manifest, first, because here latent astigmatism is, perhaps, more commonly present than not; second, because, unless the defect be fully corrected, the relief which the glasses afford will in all probability be of but short duration; and, third, because a slight over-correction of the astigmatism is scarcely more likely to prove unacceptable to the eye than an appreciable under-correction.

For some time I have been in the habit of employing oleate of veratria as an application to the forehead and temples for the relief of asthenopia and the headaches which result from accommodative strain,* and having found it efficacious in many cases, I was led to prescribe its use in astigmatism, especially, as a preliminary to testing for glasses. It is needless to say that its action is entirely unlike that of belladonna, and that it neither dilates the pupil nor paralyzes the accommodation. What it does appear to do, however, besides rendering the eye less irritable and asthenopic, is to exert a quieting effect upon the ciliary muscle, influencing especially, it seems to me, the radiating fibres, and thus lessening the tendency to asymmetrical accommodation. It is true that not infrequently the influence which it exerts upon the muscle is inappreciable; but, as a rule, after several daily applications of the veratria the irrita-

* It is hardly necessary to say that the use of veratria for the relief of asthenopia, supra-orbital neuralgia, etc., is not novel. Although it seems to have been but seldom employed for this purpose of late years, it was a favorite remedy with surgeons, and with the older school of oculists, twenty-five or thirty years ago. Dr. Delafield held it in high esteem (see these Transactions for 1865, p. 38), and my grandfather, Prof. N. R. Smith, from whom I learned of its usefulness, prescribed it constantly, and regarded it as a valuable remedy.

bility of the muscle is found to be unmistakably lessened, and the determination of the refractive error is accomplished with greater ease to the patient as well as to the examiner. All who have had experience in testing cases of astigmatism know what an immense difference there is in the behavior of different eyes under examination — how in one eye the measurements are made with the greatest facility, and the selection of the proper cylinder is attended by no difficulty whatever; while, in another, the skill and patience of the examiner are exhausted in an effort to reach even an approximation to a definite conclusion. It would be too much to claim for the veratria that it makes the latter class like the former; but its action will be understood at once when I say that the effect which it produces is, at least, an approach to this.

The veratria is most conveniently used in the form of an oleate, which I have always prescribed in the strength of 10%. It need be applied but once a day (in the morning, after washing, is the best time), and but a small quantity (as much as can be gotten upon the finger-tip by twice touching it to the mouth of the tilted vial) should be rubbed upon the forehead and temples. It is necessary to caution patients to wash their hands after making the application, and to be careful not to transfer the veratria, with their hands, handkerchief, or towel, from the forehead to the eyes, as it causes very persistent irritation if it finds its way into the conjunctival sac. It is also well, in applying it to the temples, not to put it near the outer angle of the lids, as it seems to spread over the skin, and may find its way in this manner into the eye. As a rule, the burning and tingling sensation which it produces upon the forehead and temples is not unpleasantly severe, but in some cases complaint is made of it. After its use has been continued for a while the skin becomes very much less sensitive to its action, and to increase the effect it may be necessary to rub the forehead with a rough towel before applying it. When time permits, the veratria should be applied every morning for three or four days before the test of the refraction is undertaken; and, after the glasses have been prescribed, its use from time to time will be found decidedly efficacious in relieving any lingering traces of asthenopia.

DISCUSSION.

DR. W. F. MITTENDORF, New York.—Veratria is a very dangerous agent, and great care is required that it does not reach the conjunctiva or the mouth. I should prefer cocaine on account of its soothing effect and because it is easier to apply and very prompt in its action.

DR. W. H. CARMALT, New Haven.—Mr. President: I do not see anyone present who was also present with me at the second meeting of this Society held in New York in 1865; I therefore beg to refer the *younger* members to the remarks of Dr. Edward Delafield, the then president, upon the paper of Dr. Dyer, in which the latter first enunciated the plan of treating asthenopia which we are now accustomed to associate with his name, *i. e.*, *Dyerging*. If my memory serves me Dr. Delafield stated that he didn't believe much could be accomplished by glasses in asthenopia, but that he always cured his patients by the application of veratria to the forehead and temples, producing with it severe pain, and he regarded the strong counter irritation as the therapeutic factor. I recall this bit of ancient history now in connection with Dr. Theobald's paper, surmising that it might be that the success Dr. Delafield obtained by the use of the same drug was by reason of its effect upon the accommodation rather than as he regarded from its counter-irritant effect.

DR. B. ALEXANDER RANDALL, Philadelphia.—I have found that upwards of fifty per cent. of hypermetropic cases have insufficiency of the internal recti, of from 2° to 12°. This was in persons presumably normal, who did not come on account of their eyes. Among eye patients, the proportion is higher still.

As to the matter of astigmatism, I would ask Dr. Theobald if by his manifest test he can come as near to the proper cylinder as he can by the use of a mydriatic under these circumstances.

DR. MYLES STANDISH, Boston.—While I firmly believe that the ciliary muscle can produce or correct astigmatism, I do not believe that this is due to the action of the circular fibres. I believe that the circular fibres of the ciliary muscle are myths like the radiate fibres of the iris. Several years ago I spent considerable time searching for circular fibres in the ciliary muscle. I found that circular fibres could always be found if they were skillfully cut for. I think that they are the product of the microscopist. I think that all the fibres are radiate. These decussate like the muscular fibres of the heart, and decussate more closely near the point of insertion than farther out, and because these fibres are cut in a certain way we get the appearance of circular fibres. I have a series of slides in which I attempted to follow a circular fibre in revolving the eye. I

think that I proved that what was a circular fibre in one section became a radiate fibre in another.

DR. SAMUEL THEOBALD, Baltimore.— I have always avoided the use of cocaine for the purpose for which I employ veratria. If it is used in an appreciable strength, two to four per cent., the probability is that the effect which it produces in the corneal epithelium will alter the refractive condition of the eye. I have spoken and written against the use of cocaine in the determination of refractive errors because I think it brings in an element of uncertainty which we should avoid. Furthermore, the effect of cocaine upon the ciliary muscle is entirely different from that of veratria. I therefore think that it could not be substituted for it.

Veratria was a favorite remedy with my grandfather, Dr. N. R. Smith. He used it in cases of supra-orbital neuralgia and in asthenopic cases, with temporary benefit.

With regard to Dr. Randall's point with reference to the coexistence of hypermetropia and insufficiency of the internal recti muscles, the question at once suggests itself as to what, in his opinion, constitutes insufficiency of the internal recti. If he considers a slight amount of relative divergence at 13″ with the vertical diplopia test, say 2° to 4°, as insufficiency of the internal recti, then his views in regard to that condition differ from my own. I believe that with normal muscular balance such a relative divergence is the rule.

What I said was that if in compound hypermetropic astigmatism we found the error of refraction associated with 2° or 3° of insufficiency of the internal recti at twenty feet and 6° or 7° at thirteen inches, it would make little difference what the total hypermetropia might be, as the condition of muscular balance would contra-indicate the correction of any part of that which was latent. Doing away with the accommodation, effort would exaggerate the weakness of the internal recti.

ON CERTAIN STEREOSCOPICAL ILLUSIONS EVOKED BY PRISMATIC AND CYLINDRICAL SPECTACLE-GLASSES.

BY JOHN GREEN, M.D.,

ST. LOUIS, MISSOURI.

IN June, 1867, I prescribed spectacles for Professor G. H. H., aet. 32, as follows: O.D., + 1/8 sph. + 1/24 cyl. axis — 75°; O.S., + 1/6 sph. Professor H., who is an accomplished geometrician, observed that objects seen through these glasses appeared altered in form and thrown into false perspective. Suspecting a possible error in the prescription, or in its execution, he laid the glasses aside and continued to wear + 1/8 sph. O. D. and O. S., which I had previously given him, and which had relieved him of a very troublesome asthenopia. He reported his observation to me by letter.

In explanation of the phenomenon I called the attention of Professor H. to the fact that the two retinal images were magnified unsymmetrically by the two glasses, and that the image formed by the right eye was somewhat changed in form in consequence of the unequal refractive power of the spherico-cylindrical lens in its different meridians. The phenomenon which he described was, therefore, to be classed with the well known stereoscopical effects observed when slightly different geometrical figures are viewed by the two eyes respectively. I predicted that the disturbing illusions would disappear as soon as the judgment should have become educated to the new conditions, but suggested that he might continue to wear the equal spherical glasses until the need of a more perfect correction should be felt. Three years later Professor H. wrote to me that he had lost his old glasses, and that he was then wearing the fully neutralizing spectacles with entire satisfaction.

Following the line of thought suggested by this observation of Professor H., I fitted a trial spectacle-frame with a cylindrical lens, + 1/24, before the right eye, and easily reproduced for

myself the particular appearances which he had noticed. By using different binocular combinations of prisms, and of a plane, spherical, cylindrical, or spherico-cylindrical with a cylindrical or spherico-cylindrical lens, and by varying the direction of the cylindrical axes, the binocular appearances were strikingly and sometimes unexpectedly varied. Some of the observations made at this time I afterwards embodied in a series of stereoscopic cards, which were published in the Transactions of the American Ophthalmological Society for 1878, as practical tests of binocular vision. As these cards have been long out of print, I take the liberty of reproducing a few of them, with some slight variations, in illustration of this communication.

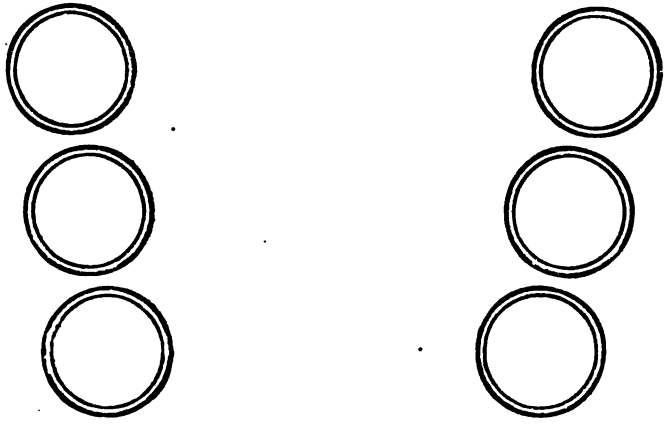

FIG. 1.

Fig. 1.—Three pairs of identical figures (circles) are viewed in the stereoscope by the two eyes, respectively, under different degrees of convergence. By the fusion of the two circles of each pair the impression is made as of an object nearer to or farther from the observer, according as a greater or less degree of convergence is brought into play. Furthermore, as the retinal images are, in all three cases, of the same size, the impression of greater distance carries with it the correlated impression of increased size of the object.

A like change in the apparent distance and in the apparent size of surrounding objects is produced by looking through a

pair of weak prismatic glasses, with their refracting edges turned inward or outward. In the one case all objects are seen under increased convergence of the visual axes, and appear as if nearer and smaller; in the other case they are seen under diminished convergence, and appear as if more distant and larger. The experiment may be varied by rotating the two prisms symmetrically in the trial-frame, or by turning the edge of one prism either inward or outward and substituting a plane glass for the other prism. Similar illusions are evoked by the symmetrical lateral or oblique decentration of weak convex or concave spherical spectacle-glasses; in the case of stronger spherical glasses the excentrical refraction may give rise to other modifying effects due to astigmatism.

Illusions of this kind are of very common occurrence when glasses are first worn, or when one pair of glasses is exchanged for another. In the greater number of cases the illusions are but imperfectly comprehended, or are inadequately described by the patient; they are, moreover, generally quite transient, and cease to attract attention after a few days.

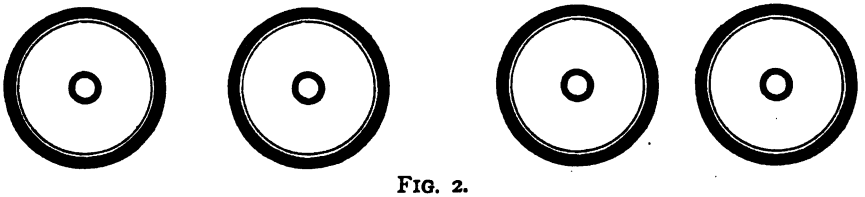

FIG. 2.

Fig. 2. — Two pairs of circles, arranged in a horizontal line, are combined by the two eyes in the stereoscope, under different degrees of convergence, as in the case of the circles shown in Fig. 1. The two figures formed by the fusion of the two circles of each pair appear to lie at different distances from the observer, and also to differ in size.

Fig. 3.* — Two pairs of equal vertical lines, arranged like the

* In the stereoscopic cards shown in Figs. 3–9 identical circles have been drawn within or around the lines or figures by whose fusion the different stereoscopical effects are produced By this means the illusions are considerably heightened, and the typical changes made easier of immediate recognition. Care has been taken not to introduce any lines which might tend to develop other effects than those due to the actual differences in the lines or figures.

FIG. 3.

circles in Fig. 2, are combined, in the stereoscope, by the two eyes. By the fusion of the two lines of each pair the impression is made as of two vertical lines at different distances from the observer, and of unequal length.

FIG. 4.

Fig. 4. — Two pairs of equidistant horizontal lines, differing slightly in length, are combined by the two eyes, in the stereoscope. By the fusion of the two unequal lines of each pair the effect produced is that of two lines rotated about a vertical axis lying in the plane of the paper; the lines appear also to diverge as they recede from the observer, and they look longer than the longer of the two component lines.

FIG. 5.

Fig. 5. — Combining the vertical and horizontal lines of Figs. 3 and 4, as viewed by the right and the left eye respectively, we

have two rectangles of equal height, but of unequal width. The figure formed by the fusion of the two rectangles, in the stereoscope, is a trapezoid, with parallel vertical sides of unequal length, rotated about a vertical axis in the plane of the paper; the upper and lower sides of the trapezoid diverge as they recede from the observer, and the horizontal diameter of the figure is greater than that of either of the component rectangles.

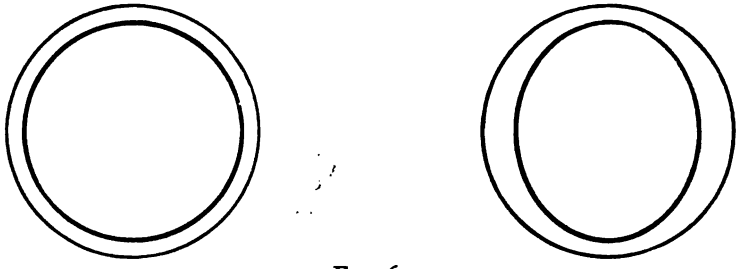

FIG. 6.

Fig. 6. — A circle and an ellipse, or two ellipses, of the same vertical but of different horizontal diameters, appear as an ellipse rotated about a vertical line in the plane of the paper, and of greater horizontal diameter than either of the component figures.

Inequality in the two retinal images, such as is shown in Figs. 3–6, is produced by placing a cylindrical lens, convex or concave, with axis vertical, before one of the eyes. The several illusions of difference in the apparent length of vertical lines (Fig. 3), of rotation of horizontal lines about a vertical axis (Fig. 4), and of rotation and distortion of geometrical figures (Figs. 5 and 6), are all reproduced in a more or less striking manner by looking through any binocular combination of lenses of equal power in the vertical principal meridian and of unequal power in the horizontal meridian. The most striking and most commonly recognized phenomenon is perhaps the distortion of rectangular figures, as shown in Fig. 5. Thus, in looking at a rectangular card through a combination of a plane glass before one eye and a convex cylindrical lens, with axis vertical, before the other eye, the vertical side of the card corresponding to the eye before which the convex cylindrical glass is placed appears

distinctly longer than the opposite side: substituting a concave cylindrical lens for the convex, in the same position, the corresponding side of the card appears shorter than the opposite side.

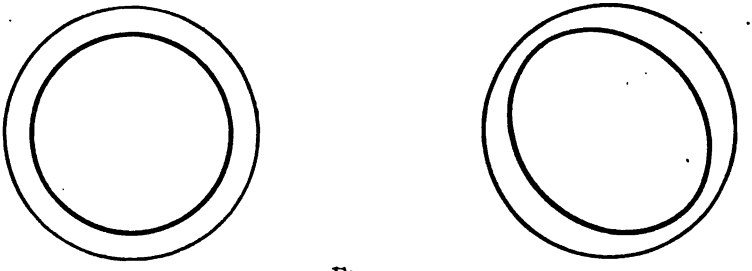

FIG. 7.

Fig. 7. — A circle and an ellipse, equal in height and in horizontal diameter but with the major axis of the ellipse inclined to the vertical, present the appearance of an ellipse, somewhat altered in its proportions, and rotated about a horizontal axis in the plane of the paper. The ellipse appears to tip toward or away from the observer, according as the upper extremity of the axis major is inclined toward or away from the center of the card.

The conditions shown in Fig. 7 are reproduced by looking through a binocular combination of a spherical and a cylindrical, or spherico-cylindrical lens, with the cylindrical axis inclined to the vertical. The relative power of the two lenses must be such that the two retinal images shall be of the same height and of the same horizontal diameter.

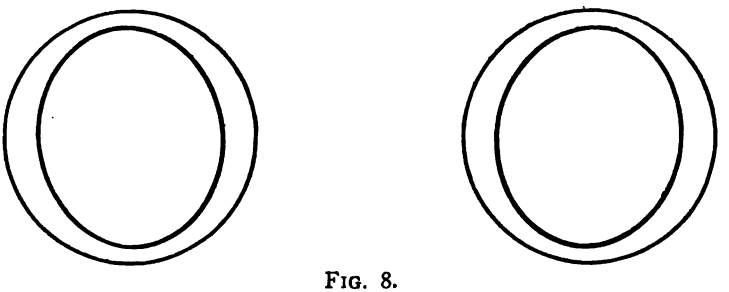

FIG. 8.

Fig. 8. — Two ellipses, with their major axes inclined, symmetrically, a little to the right and to the left of the vertical,

appear as a longer ellipse, rotated about a horizontal axis in the plane of the paper.

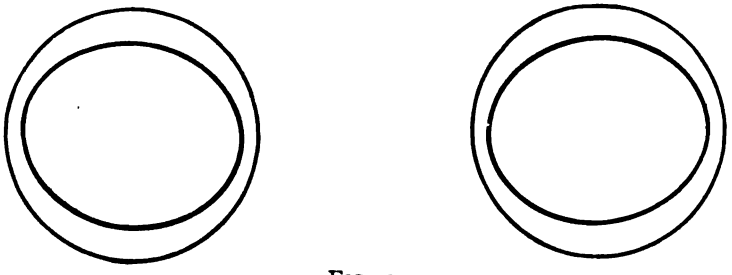

FIG. 9.

Fig. 9. — Two ellipses, with their minor axes inclined, symmetrically, a little to the right and to the left of the vertical, appear as an ellipse approaching more or less closely to a circle, and rotated about a horizontal axis in the plane of the paper.

Conditions similar to those shown in Figs. 8 and 9 are reproduced by looking through two equal cylindrical or spherico-cylindrical lenses, with symmetrical deviation of the cylindrical axes from the vertical or horizontal.

In explanation of alterations in the apparent distance and size of objects viewed through convergent or divergent prisms or through laterally decentrated lenses, and of the apparent rotation and distortion of objects viewed through lenses of equal or very nearly equal power in the vertical, but of unequal power in other ocular meridians, it may be stated, generally, that whenever the two retinal images, as modified by glasses, are such as are consistent with two projections of the object in a position other than its real position, or of some object differing in form from the actual object, the impression made under the artificially produced conditions will often be that of displacement or distortion of the object.

We learn to see things as they are through an education of the sense of vision; when the data upon which we have learned to rely are suddenly changed, as in cases such as those which have been cited, illusions are apt to be evoked, requiring a correction of the judgment in accordance with the new conditions.

This correction requires a certain time, but it is generally complete after the lapse of a few days, if the glasses are worn continuously.

DISCUSSION.

DR. O. F. WADSWORTH, Boston. — I have been especially interested in this demonstration because I had intended to present a paper upon much the same subject, but did not have time to prepare it. I approached the subject from a little different standpoint, although in the main the same. In 1875 I presented to this Society an explanation of a phenomenon which had been observed in one of my patients, and which at the time was new to me. This was the narrowing of one end of a parallelogram caused by placing a concave cylindrical glass with axis vertical before one eye. The explanation was based upon the stereoscopic combination of two images. The principle, with some modifications, I think might be applied to cover a variety of cases, much as Dr. Green has done.

DR. J. A. LIPPINCOTT, Pittsburgh. — I have been much interested in Dr. Green's paper, having but recently devoted considerable study to the subject. In an article on Binocular Metamorphopsia, published in the last number of the Archives of Ophthalmology, I cited a number of facts not previously referred to, so far as I know, some of which seem to me difficult of explanation, e. g., it is not easy to see why a plus cylinder, axis vertical, before the right eye (both eyes being open), should make the right side of a square appear higher; or why, if the axis be horizontal, the corresponding side should appear lower; or why a minus cylinder, axis vertical, before one eye, should make the corresponding side appear lower; or why, if the axis be horizontal, the corresponding side should appear higher. If the cylinder, whether plus or minus, is held horizontal before one eye and the other eye closed, precisely the opposite effect in each case is observed to what is experienced if the other eye also is kept open.

In the article referred to an explanation of these phenomena was attempted, which however did not wholly satisfy myself, as I there intimated.

DR. EDWARD JACKSON, Philadelphia. — Something of the same effect may be seen upon using eserine in one eye. The same conscious effort will produce a different adjustment of refraction in the two eyes, or a different effort will be required to focus for the same distance.

SARCOMA OF THE OPTIC NERVE, NOTABLE CHIEFLY FOR ITS SIZE AND SHAPE.

T. Y. SUTPHEN, M.D.,
NEWARK, N. J.

IN May, 1889, Katie M., 10 years of age, was brought to St. Michael's Hospital, Newark, N. J. She had a tumor located over the left orbit, oval in shape, somewhat nodulated, movable, and measuring over the convex surface, from side to side, 6 inches — vertically 5½ inches, with a thickness of about 2 inches. Briefly, the history as obtained from the child was that she had lost the right eye during infancy. With the left she had seen well until two years ago, when it became inflamed and she was soon blind in that one. Six months later this growth began to develop, and steadily increased in size until at the time of admission it was heavy and burdensome, dragging upon the pedicle, which extended backwards into the orbit. The surface was ulcerated in furrows and constantly bathed with an offensive secretion. Under ether the tumor was readily removed, and was found to have no attachment except to the optic nerve, which was swollen to more than double its normal size and elongated. The globe was entirely absent. The patient quickly recovered from the operation, and rapidly gaining in strength was discharged at the end of the second week. Microscopic examination showed the tumor to be a small cell sarcoma with the optic nerve extensively involved.

TRANSACTIONS

OF THE

AMERICAN

OPHTHALMOLOGICAL SOCIETY.

Twenty-Sixth Annual Meeting.

HOTEL KAATERSKILL,

CATSKILL MTS.

HARTFORD:
PUBLISHED BY THE SOCIETY.
1890.

PRESS OF
THE CASE, LOCKWOOD & BRAINARD CO.
HARTFORD, CONN.

CONTENTS.

PAGE.

Members of the Society, ... 459
Minutes of the Twenty-sixth Annual Meeting, ... 463
Two Cases of Brain Tumor, with interesting Eye Symptoms, by Dr. William F. Norris, ... 470
A Case of Intracranial Neoplasm with Localizing Eye Symptoms, etc., by Dr. C. A. Oliver, ... 479
The Therapeutic Effect of Prisms in Ophthalmic Practice, etc., by Henry D. Noyes, ... 483
Report of the Committee on the Causes and Prevention of Blindness, 531
Legislation for the Prevention of Blindness, by Dr. Lucien Howe, . 540
Contributions to Ocular Tumors, by Dr. W. H. Carmalt, ... 545
The Winking Test, by Dr. Chas. E. Rider, ... 551
New Tests for Binocular Vision, by Dr. J. A. Lippincott, ... 560
Case of a Foreign Body remaining in the Eye about 20 years, etc., by Dr. B. L. Milliken, ... 565
Foreign Bodies in the Orbit, by Dr. W. F. Norris, ... 569
Simple Extraction of Cataract without Iridectomy, by Dr. C. S. Bull, 572
The Extraction of Lenses dislocated into the Vitreous Humor, by Dr. C. S. Bull, ... 598
Removal of a large Exostosis of the Orbit with Preservation of the Eye, by Dr. T. R. Pooley, ... 611
Operation for Ectropium of the Lower Lid by the Sliding Flap method, by Dr. T. R. Pooley, ... 622
Report of a Case of Recurrent Irido-Chorido-Retinitis, by Dr. S. Theobald, ... 629
Two Cases of Glaucoma with Unusual Features, by Dr. C. W. Kollock, ... 634
Transient Amblyopia with Bitemporal Hemianopsia in a Case of Malarial Cachexia, by Dr. Geo. C. Harlan, ... 640

PAGE.

Complete Paralysis of the Lateral Movements of both Eyes, etc., by Dr. B. L. Milliken, ... 644

An Analysis of the Ocular Symptoms found in the Third Stage of General Paralysis of the Insane, by Dr. Charles A. Oliver, . 646

New Operation for Symblepharon, by Dr. Geo. C. Harlan, . . . 651

Transient Pulsation of Retinal Arteries induced by Application of Homatropine, by Dr. Geo. C. Harlan, ... 653

A Case of Metastatic Carcinoma of the Choroid, by Dr. O. F. Wadsworth, ... 654

Can Hypermetropia be Healthfully Outgrown? by Dr. B. Alex. Randall, ... 657

Embolism of Upper Branch of Retinal Artery with Normal Vision, by Dr. W. F. Mittendorf, ... 669

Thrombosis of Arteria Centralis Retinae — large Retino-ciliary artery — Central Vision unimpaired, by Dr. O. F. Wadsworth, . 672

Progressive Hyperopic Astigmatism, by Dr. Edward Jackson, . . 676

An Elementary Discussion of some Cases of Centrical Refraction, etc., by Dr. John Green, ... 690

Cyst of the Iris, following a Penetrating Wound, etc., by Drs. S. D. Risley and B. A. Randall, ... 718

Eight Cases of Rudimentary Zonular Double Cataract, by Dr. Hasket Derby, ... 722

Notes on Twenty-one Cases of Cataract, by Dr. John Green, . . 724

Specimen of Filaria Oculi Humani, by Dr. F. M. Wilson, . . 727

A New Ophthalmoscope, by Dr. Geo. C. Harlan, ... 730

MEMBERS

OF THE

AMERICAN OPHTHALMOLOGICAL SOCIETY, 1889-90.

ACTIVE MEMBERS.

Name.	Residence.	Place.
Dr. F. W. Abbot,	223 Franklin Street,	Buffalo, N. Y.
Dr. A. Alt,	3036 Locust Street,	St. Louis, Mo.
Dr. J. A. Andrews,	9 West 22d Street,	New York, N. Y.
Dr. S. C. Ayres,	64 West Seventh Street,	Cincinnati, Ohio.
Dr. William T. Bacon,	3 Pratt Street,	Hartford, Conn.
Dr. Edwin W. Bartlett,	420 Jefferson Street,	Milwaukee, Wis.
Dr. David D. Beck,	137 West Eighth Street,	Cincinnati, Ohio.
Dr. H. W. Bradford,	6 Beacon Street,	Boston, Mass.
Dr. Charles S. Bull,	47 West 36th Street,	New York, N. Y.
Dr. F. Buller,	838 Dorchester Street,	Montreal, Canada.
Dr. Swan M. Burnett,	1770 Mass. Avenue,	Washington, D. C.
Dr. Peter A. Callan,	35 West 38th Street,	New York, N. Y.
Dr. F. P. Capron,	203 Washington Street,	Providence, R. I.
Dr. W. H. Carmalt,	87 Elm Street,	New Haven, Conn.
Dr. David Coggin,	7 Chestnut Street,	Salem, Mass.
Dr. H. Culbertson,	34 South Fifth Street,	Zanesville, Ohio.
Dr. C. M. Culver,	36 Eagle Street,	Albany, N. Y.
Dr. George R. Cutter,	473 Bedford Avenue,	Brooklyn, N. Y.
Dr. W. S. Dennett,	31 West 42d Street,	New York, N. Y.
Dr. Hasket Derby,	182 Marlboro' Street,	Boston, Mass.
Dr. Richard H. Derby,	9 West 35th Street,	New York, N. Y.
Dr. Lewis S. Dixon,	232 Clarendon Street,	Boston, Mass.
Dr. Stephen Dodge,	27 South Park Street,	Halifax, Nova Scotia.
Dr. Abram Du Bois,	16 West 30th Street,	New York, N. Y.
Dr. J. B. Emerson,	20 East 30th Street,	New York, N. Y.
Dr. Arthur E. Ewing,	2670 Washington Avenue,	St. Louis, Mo.
Dr. B. E. Fryer,	1224 Broadway,	Kansas City, Mo.
Dr. John Green,	2670 Washington Avenue,	St. Louis, Mo.
Dr. Emil Gruening,	109 East 23d Street,	New York, N. Y.
Dr. A. D. Hall,	1623 Spruce Street,	Philadelphia, Pa.

Name.	Residence.	Place.
Dr. H. F. Hansell,	254 South 16th Street,	Philadelphia, Pa.
Dr. George C. Harlan,	1515 Walnut Street,	Philadelphia, Pa.
Dr. David Harrower,	9 Elm Street,	Worcester, Mass.
Dr. Gustavus Hay,	91 Charles Street,	Boston, Mass.
Dr. Neil J. Hepburn,	369 West 23d Street,	New York, N. Y.
Dr. Albert G. Heyl,	1535 Pine Street,	Philadelphia, Pa.
Dr. Edward L. Holmes,	112 Clark Street,	Chicago, Ill.
Dr. E. E. Holt,	723 Congress Street,	Portland, Me.
Dr. Lucien Howe,	87 West Huron Street,	Buffalo, N. Y.
Dr. Edward Jackson,	215 South 17th Street,	Philadelphia, Pa.
Dr. B. Joy Jeffries,	15 Chestnut St., Bea. Hill,	Boston, Mass.
Dr. Samuel J. Jones,	7 Jackson Street,	Chicago, Ill.
Dr. Charles J. Kipp,	534 Broad Street,	Newark, N. J.
Dr. H. Knapp,	25 West 24th Street,	New York, N. Y.
Dr. Carl Koller,	53 East 57th Street,	New York, N. Y.
Dr. Chas. W. Kollock,	Cor. Wentw'th & Com'g sts,	Charleston, S. C.
Dr. Richmond Lennox,	146 Pierrepont Street,	Brooklyn, N. Y.
Dr. J. A. Lippincott,	435 Penn Avenue,	Pittsburg, Pa.
Dr. F. B. Loring,	1420 K Street,	Washington, D. C.
Dr. J. C. Lundy,	52 Lafayette Avenue,	Detroit, Mich.
Dr. M. V. Marmion,	1108 F Street,	Washington, D. C.
Dr. Arthur Mathewson,	139 Montague Street,	Brooklyn, N. Y.
Dr. S. F. McFarland,	76 Front Street,	Binghamton, N. Y.
Dr. Chas. H. McIlwaine,	107 South Warren Street,	Trenton, N. J.
Dr. R. J. McKay,		Wilmington, Del.
Dr. C. S. Merrill,	23 Washington Avenue,	Albany, N. Y.
Dr. B. L. Milliken,	343 Prospect Street,	Cleveland, Ohio.
Dr. H. G. Miller,	262 Benefit Street,	Providence, R. I.
Dr. J. Lancelot Minor,	Gayoso Hotel,	Memphis, Tenn.
Dr. W. F. Mittendorf,	140 Madison Avenue,	New York, N. Y.
Dr. William O. Moore,	128 Madison Avenue,	New York, N. Y.
Dr. Russell Murdoch,	12 Cathedral Street,	Baltimore, Md.
Dr. William F. Norris,	1530 Locust Street,	Philadelphia, Pa.
Dr. Henry D. Noyes,	233 Madison Avenue,	New York, N. Y.
Dr. J. F. Noyes,	101 Shelby Street,	Detroit, Mich.
Dr. Charles A. Oliver,	1507 Locust Street,	Philadelphia, Pa.
Dr. H. S. Oppenheimer,	49 East 23d Street,	New York, N. Y.
Dr. O. D. Pomeroy,	316 Lexington Avenue,	New York, N. Y.
Dr. Thomas R. Pooley,	107 Madison Avenue,	New York, N. Y.
Dr. M. H. Post,	Beaum't St., cor. Wash. Av.,	St. Louis, Mo.
Dr. J. S. Prout,	26 Schermerhorn Street,	Brooklyn, N. Y.
Dr. B. Alex'r Randall,	1806 Chestnut Street,	Philadelphia, Pa.
Dr. Wm. Rankin,	23 Cedar Street,	Newark, N. J.
Dr. R. A. Reeve,	22 Shuter Street,	Toronto, Canada.
Dr. Stephen O. Richey,	732 17th Street,	Washington, D. C.
Dr. Charles E. Rider,	53 South Fitzhugh Street,	Rochester, N. Y.
Dr. Frank W. Ring,	101 Park Avenue,	New York, N. Y.
Dr. Samuel D. Risley,	1722 Walnut Street,	Philadelphia, Pa.

Name.	Residence.	Place.
Dr. Edmund C. Rivers,	16th and Stout Streets,	Denver City, Col.
Dr. D. B. St. John Roosa,	20 East 30th Street,	New York, N. Y.
Dr. John D. Rushmore,	129 Montague Street,	Brooklyn, N. Y.
Dr. Robert Sattler,	64 West Seventh Street,	Cincinnati, Ohio.
Dr. G. E. de Schweinitz,	1401 Locust Street,	Philadelphia, Pa.
Dr. H. W. Seeley,	S.E. cor. 4th St. & B'dway,	Cincinnati, Ohio.
Dr. Henry L. Shaw,	159 Boylston Street,	Boston, Mass.
Dr. J. A. Spalding,	627 Congress Street,	Portland, Me.
Dr. Francis P. Sprague,	229 Commonwealth Ave.,	Boston, Mass.
Dr. Myles Standish,	200 Dartmouth Street,	Boston, Mass.
Dr. George T. Stevens,	33 West 33d Street,	New York, N. Y.
Dr. Samuel B. St. John,	43 Pratt Street,	Hartford, Conn.
Dr. Geo. Strawbridge,	1500 Walnut Street,	Philadelphia, Pa.
Dr. T. Y. Sutphen,	963 Broad Street,	Newark, N. J.
Dr. J. Oscroft Tansley,	28 West 43d Street,	New York, N. Y.
Dr. Lewis H. Taylor,	41 South Franklin Street,	Wilkes Barre, Pa.
Dr. Samuel Theobald,	304 West Monument St.,	Baltimore, Md.
Dr. William Thompson,	1426 Walnut Street,	Philadelphia, Pa.
Dr. John VanDuyn,	111 South Salina Street,	Syracuse, N. Y.
Dr. J. J. B. Vermyne,	10 Orchard Street,	New Bedford, Mass.
Dr. O. F. Wadsworth,	139 Boylston Street,	Boston, Mass.
Dr. Leroy P. Walker,	111 East 19th Street,	New York, N. Y.
Dr. David Webster,	266 Madison Avenue,	New York, N. Y.
Dr. Robert Willard,	120 Charles Street,	Boston, Mass.
Dr. Chas. H. Williams,	C, B. & Q. R. R.,	Chicago, Ill.
Dr. Henry W. Williams,	15 Arlington Street,	Boston, Mass.
Dr. F. M. Wilson,	317 State Street,	Bridgeport, Conn.
Dr. J. P. Worrell,	20 South Seventh Street,	Terra Haute, Ind.

Total, ... 104.

HONORARY MEMBER.

Dr. C. Schweigger, ... Berlin, Prussia.

Whole Number, ... 105.

MINUTES OF THE PROCEEDINGS.

TWENTY-SIXTH ANNUAL MEETING.

HOTEL KAATERSKILL,
CATSKILL MOUNTAINS, July 16, 1890.

The Twenty-sixth Annual Meeting of the Society was called to order at 10 A. M. by the President, Dr. HASKET DERBY, who spoke as follows:

Gentlemen, — It is my privilege to welcome you to the twenty-sixth meeting of the Ophthalmological Society, and I desire, at the same time, to return you my thanks for my election to the office of president. It is not a position that involves much of either labor or responsibility, but it is the highest honor that you have it in your power to bestow; and I can only express my gratitude and regret my unworthiness.

It has never been the custom of this society to open its deliberations with an address by the president. A simple allusion to the members that have passed away during the year has alone been usual. Dr. David C. Cocks of New York was elected in 1887, and attended our last meeting. The face of Dr. Henry S. Schell of Philadelphia was more familiar at our gatherings, he having been with us since 1880, and he not infrequently contributed to our transactions. Both were men of promise, and we can only deplore their early loss.

During the year the larger world of Ophthalmology has also been heavily visited. In addition to the decease of Jacobson, Just, and Strube, there has recently passed away one who was indeed a leader in our midst. And it seems unfitting that we should come together at this time without laying our own humble wreath on the grave of Otto Becker, a type of a manly man, endeared to many of us by ties of personal friendship, and honored by all as a true soldier of science.

The President then announced the following committees:

Committee on Bulletin — Drs. LUCIEN HOWE and J. J. B. VERMYNE.

Committee on Membership — Drs. JOHN GREEN, ARTHUR MATHEWSON, SAMUEL THEOBALD, W. H. CARMALT, and C. S. BULL.

Auditing Committee — Dr. H. S. OPPENHEIMER.

The Treasurer's Report was read and referred to the Auditing Committee, and subsequently accepted and ordered to be placed on file.

Voted, — That the assessment for 1890–1891 be $5.

The Society went into Executive Session, and several nominations for membership were received.

Regular session resumed.

Drs. N. J. Hepburn of New York, A. A. Hubbell of Buffalo, W. B. Johnson of Paterson, N. J., W. C. Gillian of New York, Smith Baker of Utica, F. W. Marlow of Syracuse, and R. H. Johnson of Philadelphia, were invited to attend the meetings of the Society at this session.

The Committee on Bulletin reported, and the following papers were read:

1. "Two cases of brain tumor, with interesting eye symptoms," by Dr. W. F. Norris.

2. "Case of intra-cranial neoplasm, with localizing eye symptoms. Position of tumor verified at autopsy," by Dr. C. A. Oliver.

3. "Transient amblyopia, with bi-temporal hemianopsia, in a case of malarial cachexia," by Dr. G. C. Harlan.

4. "The extraction of dislocated lenses from the eye, whether transparent or cataractous," by Dr. C. S. Bull. Discussed by Dr. T. R. Pooley.

5. "Further observations on the 'simple operation' for the extraction of cataract," by Dr. C. S. Bull. Discussed by Drs.

H. Derby, Theobald, H. D. Noyes, Pooley, Wadsworth, Reeve, Prout, Howe, Lippincott, Harlan, and Bull.

6. "Eight cases of rudimentary zonular double cataract among ten members of the same family," by Dr. H. Derby. Discussed by Drs. Green and H. D. Noyes.

7. "Case of exostosis of orbit," by Dr. T. R. Pooley. Discussed by Drs. Andrews, Reeve, and Pooley.

8. "Operation for ectropion of the lower lid by sliding flaps," by Dr. T. R. Pooley. Discussed by Drs. Howe, Reeve, Wadsworth, and Freyer.

Adjourned at 2 P. M. to meet at 4 P. M.

Meeting called to order at 4 P. M.

Reading of papers resumed.

9. "Case of foreign body in the eye twenty years," by Dr. B. L. Milliken. Discussed by Dr. H. D. Noyes.

10. "Case of foreign body in the orbit," by Dr. W. F. Norris. Discussed by Dr. Taylor.

11. "Case of complete paralysis of the lateral movements of both eyes," by Dr. B. L. Millikin.

12. "The winking test," by Dr. C. E. Rider. Discussed by Drs. Randall, H. D. Noyes, McKay, and Wadsworth.

13. "New test for binocular vision," by Dr. J. A. Lippincott. Discussed by Drs. H. D. Noyes and Lippincott.

14. "Can hypermetropia be healthfully outgrown?" by Dr. B. A. Randall. Discussed by Drs. Norris and Oliver.

15. "The Therapeutic Effects of Prisms in Ophthalmic Practice," by Dr. H. D. Noyes. Discussed by Drs. McKay, Pooley, Randall, Harlan, Taylor, Wadsworth, Jackson, Abbott, and Noyes.

Adjourned at 6 P. M. to meet at 8 P. M.

Meeting called to order at 8 P. M.

Executive Session.

Dr. Oppenheimer reported that the Treasurer's Report had been audited and found correct.

Dr. Green reported for the Committee on Admissions that the following gentlemen were recommended for election to the Society: Drs. ARTHUR E. EWING of St. Louis, NEIL J. HEPBURN of New York City, CHAS. M. CULVER of Albany, RICHMOND LENNOX of Brooklyn, F. W. RING of New York City.

Upon ballot all of the above-named gentlemen were elected members of the Society.

The Committee on Membership made the following nominations:

For President — Dr. HASKET DERBY.
For Vice-President — Dr. GEORGE C. HARLAN.
For Corresponding Secretary — Dr. J. G. PROUT.
For Secretary and Treasurer — Dr. S. B. ST. JOHN.
For Publishing Committee — Drs. W. S. DENNETT, C. S. BULL, and S. B. ST. JOHN.

The above officers were elected unanimously.

The Committee recommended that the next meeting be with the Congress of American Physicians and Surgeons at Washington, in September, 1891, and the recommendation was adopted.

The Bulletin was then resumed.

16. "Report of Committee on Prevention of Blindness," was read by Dr. L. Howe and discussed by Drs. Wadsworth, H. D. Noyes, and Howe.

17. "Purulent ophthalmia," by Dr. J. A. Andrews. Discussed by Drs. Pooley, Bacon, Wilson, Rider, Kollock, Theobald, Oliver, Reeve, Abbott, and Andrews.

Adjourned to 9.30 A. M., July 17th.

Meeting called to order at 9 30 A. M.

The Bulletin was resumed.

18. "Legislation for the prevention of blindness," by Dr. L. Howe.

(At this point the exercises were interrupted by the entrance of a fine salmon, sent to the Society from the Restigouche River by Dr. W. Thomson of Philadelphia, and the Secretary was instructed to return the thanks of the Society therefor.)

19. "Cyst-like bodies of the conjunctiva," by Dr. J. A. Andrews.

20. "A form of xerosis," by Dr. C. W. Kollock. Discussed by Drs. H. D. Noyes and Koller.

The Society then went into Executive Session.

Dr. Randall spoke on the nomenclature of prisms, and moved "that the Society accept the method of numbering prisms offered by Dr. Dennett last year." This was discussed by Drs. Jackson and McKay, and then carried, and the Secretary instructed to communicate this action to Drs. Schweigger and Landolt, of the Berlin Medical Congress.

Dr. Carmalt moved that the President and Secretary and our Delegate to the Congress of American Physicians and Surgeons be directed to make out a list of distinguished ophthalmologists from abroad who shall be invited to attend the meeting of the Society in Washington, in September, 1891. *Carried.*

The Bulletin was then resumed.

21. "Report of case of recurrent irido-choroiditis," by Dr. S. Theobald. Discussed by Drs. Matthewson, H. D. Noyes, and Theobald.

22. "Two cases of glaucoma," by Dr. C. W. Kollock. Discussed by Dr. H. D. Noyes.

23. "Embolism of upper branch of retinal artery, with normal vision," by Dr. W. F. Mittendorf. Discussed by Dr. Pooley.

24. "Contribution to ocular tumors," by Dr. W. H. Carmalt.

25. "Orbital cellulitis secondary to mastoid abscess," by Dr. R. J. McKay.

26. "Three noteworthy cases of ametropia," by Dr. S. Theobald. Discussed by Drs. Matthewson, Jackson, Hubbell, Koller, and Rider.

27. "Progressive hyperopic astigmatism," by Dr. Jackson. Discussed by Drs. H. D. Noyes, Theobald, Reeve, Green, Wadsworth, and Jackson.

28. "An analysis of the ocular symptoms found in the third stage of general paralysis of the insane," by Dr. C. A. Oliver.

29. "Elementary discussion of some cases of tipped spectacle glasses," by Dr. John Green.

30. "New operation for symblepharon," by Dr. G. C. Harlan. Discussed by Drs. Norris and Koller.

31. "Cyst of iris, following penetrating wound," by Dr. B. A. Randall. Discussed by Drs. Howe, Randall, and H. D. Noyes.

32. "Case of metastatic carcinoma of the choroid," by Dr. O. F. Wadsworth. (Read by title.)

33. "Case of thrombosis arteria centralis retinæ," by Dr. O. F. Wadsworth.

34. "Demonstration of specimens of filaria oculi humani," by Dr. F. M. Wilson. Discussed by Drs. H. D. Noyes, Randall, and Wilson.

35. "Temporary pulsation of retinal arteries induced by homatropine," by Dr. G. C. Harlan.

36. "A modification of Noyes' ophthalmoscope," by Dr. G. C. Harlan. Discussed by Drs. Randall and Prout.

Adjourned.

Present at the Twenty-sixth Annual Meeting.

Dr. CARMALT,	Dr. PROUT,
Dr. POMEROY,	Dr. LIPPINCOTT,
Dr. WADSWORTH,	Dr. CUTTER,
Dr. HOWE,	Dr. HARLAN,
Dr. VERMYNE,	Dr. H. DERBY,
Dr. REEVE,	Dr. WILSON,
Dr. KOLLOCK,	Dr. MITTENDORF,
Dr. MILLIKIN,	Dr. NORRIS,
Dr. OLIVER,	Dr. MATTHEWSON,
Dr. ABBOTT,	Dr. GREEN,
Dr. MCKAY,	Dr. THEOBALD,
Dr. FREYER,	Dr. BACON,

Dr. JACKSON,
Dr. RIDER,
Dr. RANDALL,
Dr. CAPRON,
Dr. POOLEY,
Dr. ANDREWS,
Dr. TAYLOR,
Dr. CALLAN,
Dr. H. D. NOYES,
Dr. OPPENHEIMER,
Dr. ST. JOHN,
Dr. KOLLER.

Present by invitation:

Dr. HEPBURN,
Dr. HUBBELL,
Dr. W. B. JOHNSON,
Dr. R. H. JOHNSON,
Dr. GILLIAN,
Dr. BAKER,
Dr. MARLOW.

S. B. ST. JOHN, *Secretary.*

TWO CASES OF BRAIN TUMOR, WITH INTERESTING EYE SYMPTOMS.

By WILLIAM F. NORRIS,
PHILADELPHIA.

GLIOMA OF THE RIGHT TEMPORAL LOBE, INVOLVING THE RIGHT OPTIC TRACT.

CASE I. In January, 1889, I was consulted by Mrs. X., aet. 32, complaining that during the last two months her eyesight, always good previously, had been failing her, and that when she attempted to read for any time the print blurred and she became dizzy. She had no double vision and had not been in ill health, but was known to her friends as a healthy and vigorous woman, fond of lawn tennis and active exercise, and was the mother of two healthy children. She had formerly been able to read as long as she pleased without headache or any inconvenience. The motions of the lids and extra-ocular muscles were normal and the right pupil prompt in its response to light. That of the left eye was slightly larger and was slower in its response to light falling on the eye, although the consensual motions on shading the fellow eye were prompt. In each eye the acuity of vision was nearly normal, 5/5 with difficulty, 5/7½ with ease and correctness. In the right eye the accommodative power was nearly normal, and she could read Jr. 1 over a range from 7″ to 16″, while with the left, the accommodation was less perfect, and she could read with difficulty and for a moment only Jr. 1 from 7″ to 9″. With red glass and vertical diplopia at 20 ft. there was slight exophoria, the images being about 3″ apart. The ophthalmoscope showed in each eye a low grade of hypermetropia and hypermetropic astigmatism, the discs were capillary and normal, and there were no coarse changes in either the choroids or retinae. The field was taken roughly with the fingers and found to be diminished in

CASE I.
24 FEBRUARY, 1889.

LEFT.

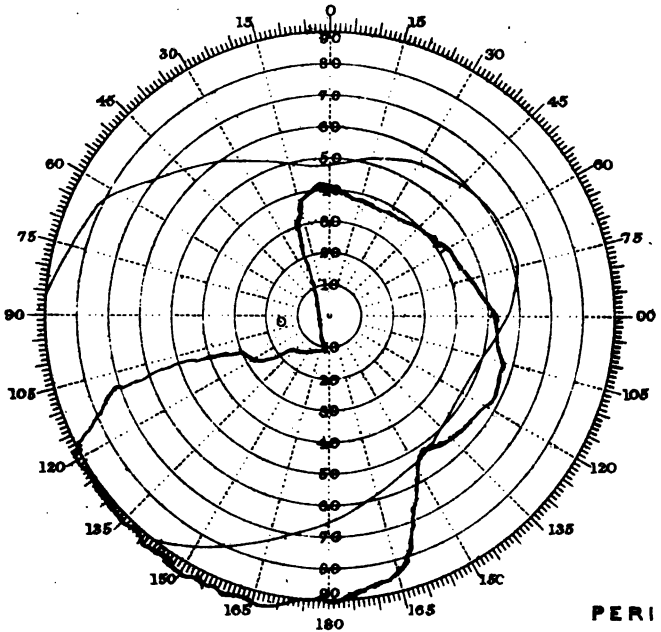

RIGHT.

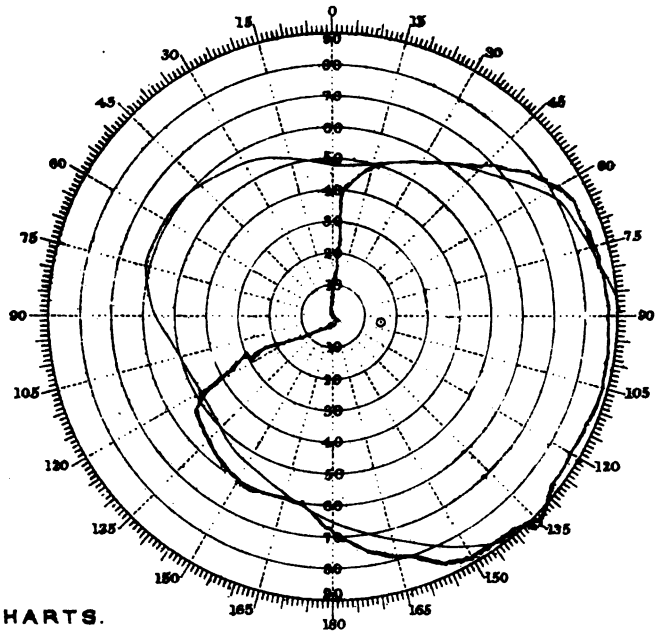

PERIMETER CHARTS.

the upper outer part in the left eye. Next day atropine was instilled, and it was found that in each eye ametropia was corrected by 0.50 Sp.⌒0.50 Cy, the axis of the right eye being at 75 degrees, that of the left at 100 degrees, and with this correction vision was 5/7½. The field was carefully taken on the perimeter, and it was found that in the left eye, the entire upper outer quadrant was missing, while in the right eye there was a corresponding defect of less extent in the upper inner field. In neither eye was the outline of the defect a sharp or exact quadrant, and in neither was the fixation point reached by it, although the blind area came close to it. The patient returned to her home in the interior of the State, and the family physician wrote me that she had for years enjoyed good health, and still did, except that there was a slight laceration of the cervix-uteri, the result of her last confinement. On the 4th of April, while again in the city, the acuity of vision remaining as before, and while sitting at the perimeter, she was seized with a sensation of dizziness and faintness, which compelled her to lie down and rest. In a little while after she was able to enter a carriage and be driven to her hotel, where she felt so badly that she at once went to bed and was seized within an hour subsequently with a slight convulsion. She now commenced to have a good deal of headache in the right side of the head and in the right eye, and occasionally there was pain in the right occiput. The appetite remained good and there was no nausea or vomiting, but the patient got dizzy in walking and preferred to be quiet. The urine was carefully examined but nothing abnormal was detected. On the 6th of May for the first time the optic disc was found to be becoming hazy and slightly prominent. Its nasal outlines were entirely hidden and there was very slight haze of the left retina around the entrance of the optic nerve. There have been no further convulsions and but little pain; when this latter symptom was present, it was always in the right side of the head. The patient is inclined to be drowsy and wants to be let alone. Both pupils are sluggish and there is occasional twitching of the muscles in the right shoulder. Four days later the right disc had become considerably swollen, its summit best seen with +2 D., and there was a slight hemorrhage on it.

In the left eye the summit of the disc was seen with +1 D. Patient less drowsy, but has lost appetite and can scarcely be persuaded to take either solid or liquid food. Frequent nausea, but no vomiting, the headaches increasing in severity. There is marked increase of the knee-jerk on the left side and well-marked ankle-clonus. The knee-jerk is less prompt, although perhaps still exaggerated on the right side. The grip of the left hand is much less powerful than that of the right, and the patient begins to walk with difficulty, on account of want of control of the left leg. When asleep there is frequent twitching of the right side of the face, especially of the levator anguli oris. The patient keeps her bed; the pupils are semi-dilated; the Wernicke hemianopic reflex not obtainable.

5/17. Headaches so severe that an occasional small dose of morphia is indispensable. When one-quarter gr. is administered by the rectum the semi-dilated pupils contract and remain small and immobile for 24 to 48 hours, while the anodyne effect is but moderate.

5/18. Patient has for the first time double vision, and when I was sitting alongside of the bed, she remarked, "Doctor, you have two cravats, one just under your nose." The image of the left eye was the highest. The discs were more swollen, with fresh hemorrhages in them. O. D. +3 D., O. S. +2.50 D.

5/23. Still marked paresis of inf. rectus of O. D. and slight paresis of the internus of the same side, and great dizziness when she is raised in bed; owing to this and her increasing drowsiness and irritability when roused, it was impossible to map out more accurately the position of the double images. On consultation with Dr. W. Osler and Dr. S. Weir Mitchell, it was determined that the patient was suffering from a tumor of the base, probably near the optic thalamus, and that owing to its location any operative interference would be unjustifiable. She therefore was placed on a stretcher and transported to her home.

Her physician reported that the paralysis of the left side became complete and that it was followed by paralysis of sensation. On the third of June she had a convulsion, and on the day following marked nystagmus, the motions of the left eye

CASE I.
28th MARCH, 1889.

LEFT.

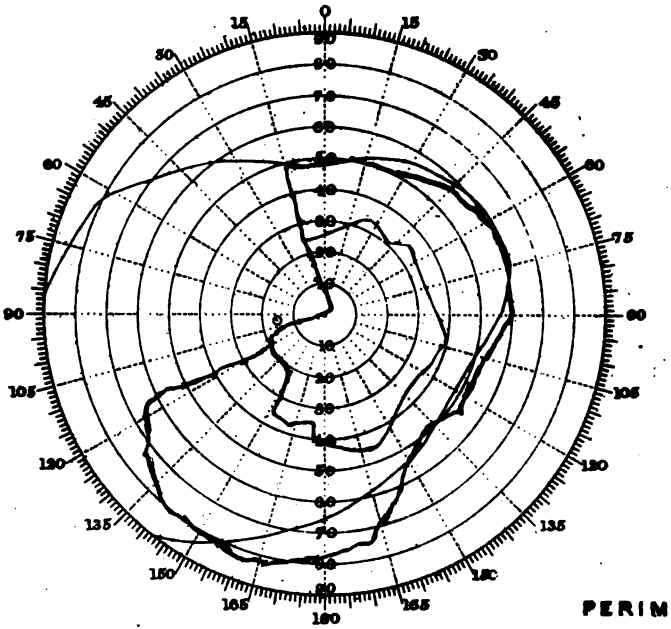

RIGHT.

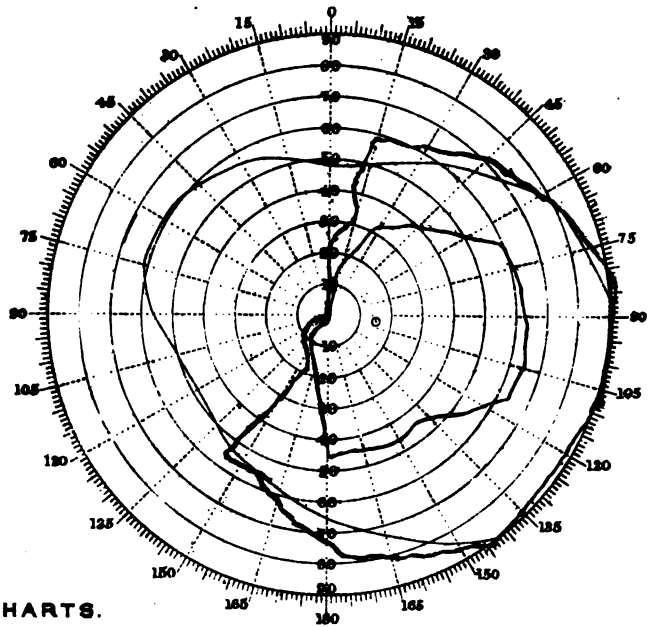

PERIMETER CHARTS.

being most active. Death ensued on the 5th of July, and an autopsy was made by Dr. W. Osler 63 hours later.

Autopsy by Dr. W. Osler:

Body was emaciated; but there were no external evidences of decomposition. The skull cap was thin, the inner table roughened, presenting a finely granular and eroded condition, and was very vascular: this state of affairs being more marked on the right than on the left side. The dura was very vascular and was not especially adherent. The Pacchionian granulations were numerous. The longitudinal sinus contained fluid blood, and at its posterior part its lumen was very broad. The meningeal arteries were normal and the inner surface of the dura was smooth. The hemispheres looked symmetrical, the right side in the lateral region being fuller than the left, and its convolutions were somewhat flattened. The large veins of the pia seemed full and its membranes looked normal and were nowhere thickened.

On removal of the brain, it was seen at its base that the right temporal lobe was swollen, paler, and larger than the left. The arachnoid was smooth and clear and the vessels of the circle of Willis looked normal. The optic commissure was prominent and pushed forward by a gelatinous swelling occupying the entire region of the tuber cinereum.

The olfactory nerves were normal, but the roots of the right nerve were somewhat spread and were upon a plane anterior to those of the left. The optic nerves were a little swollen and both white in color, and the commissure was intact. The left optic tract was normal, but the right was completely involved in a growth which extended from the temporal lobe and whose exact boundaries were indistinguishable. The corpora albicantia were distinct. The Third nerve looked normal at the point of emergence. The pons and medulla, with the nerves emerging from them, had a natural appearance. The left crus was firm and measured two centimetres, the right crus was flattened, looked infiltrated, and measured transversely three centimetres. Its anterior border was indistinct, merging into a tumor of the temporal lobe. The right uncinate gyrus was greatly swollen, and was intimately united to the crus and to the tumor mass occu-

pying the position of the first part of the right tract. The under surface of the right temporal lobe looked swollen and was soft, and the pia smooth; but the uncinate and occipito-temporal gyrus immediately above it were evidently involved.

On opening the ventricles from above, the tumor mass was seen to have extended upward and to have involved the anterior portion of the corpus callosum and of the septum lucidum. The right lateral ventricle was a little enlarged and the ependyma soft. The basal ganglia on the left side were normal; on the right side, the thalamus was swollen, but moderately firm, and its outer and back part, just at the side of the pulvinar, was directly continuous with the tumor. The corpora quadrigemina were large and their outlines distinct, but their consistency was much reduced, probably owing to post mortem change. The anterior and posterior commissures and the pillars of the fornix of the third ventricle were distinct.

Sections made transversely through the right occipital and temporal lobes showed the following conditions: — The tumor mass occupied the white matter extending from within half an inch of the apex of the lobe to a point corresponding to a line about half an inch above the pulvinar. Above, it reached close to the gray matter of the insula, but did not involve it. Anteriorly and internally at the base, it extended to the tuber cinereum, and had involved the optic tract, as already described. Above, it involved part of the lenticular nucleus and the anterior portion of the internal capsule, and extended laterally to the optic thalamus. Posteriorly, it reached to the white matter just outside of the descending horn of the lateral ventricle at its junction with the posterior horn. It came nearest to the gray matter in the uncinate gyrus and inferior temporal and occipital convolutions, which (as has already been mentioned) were much swollen and infiltrated. In the temporal lobe the tumor formed a firm mass, grayish red in color, and in its center presented brown material, which was probably altered blood clot. Towards the tuber cinereum, and where the growth had passed up the corpus callosum, it had a grayish-red appearance, and was exceedingly vascular and soft. The convolutions of the frontal and parietal lobes were normal and the occipital gyri showed

no change on the median or external surfaces, but posteriorly the growth extended for a short distance into the right occipital lobe, involving the white matter of the occipito-temporal convolution. Sections of the tumor, stained and placed beneath the microscope, showed the characteristic structure of glioma.

CARCINOMA IN THE REGION OF THE SELLA TURCICA, EXTENDING ALONG THE WINGS OF THE SPHENOID BONE.

CASE 2. In January, 1889, I was called in consultation to see Mrs. Y., who had entirely lost the sight of one eye and was rapidly losing that of its fellow. I found a slight, emaciated, cachectic woman, with a transparent, yellow, waxy skin, who on account of severe headache, increasing feebleness, and diminished eyesight, had been confined to the house for several weeks previously. She had been married four years, but had had no children and no miscarriages. She had considered herself in fair health till about a year previous, when she was seized with a roaring and partial deafness in the right ear, and visited a physician to have it examined and syringed, in the belief that there was wax in the meatus. He, however, failed to find any, and the tympanum was said to be normal in appearance. Some six months later she was seized with severe pain in the distribution of the right trigeminus, principally seated in the right face and side of the nose; later she had double vision and gradually failing eyesight. There is no paresis of the facial of either side, but the right eye is slightly prominent, and its pupil semi-dilated and irresponsive to light, although a consensual action is prompt. The eye can be moved upward, downward, or inward, but not outward, beyond the median line; and there is apparently complete palsy of the rectus externus. The ophthalmoscope showed that the media were clear and that the choroid was healthy, but there was a dense grayish haze of the retina, most marked in the head of the nerve and immediately around it. The disc was very slightly in advance of the retinal level. The veins were dark and full and the arteries were much diminished in size, but there was none of the filled-in appearance or blue-green hue so often seen when there is shrinking of the nerve which has previously been in a state of swelling.

The left eye appears normal externally, its pupil prompt, and its motion apparently unimpaired. The vision of this eye was diminished, but the patient could still with difficulty decipher some of the words of Jr. VI, holding the book at 5″ to 6″, but said the print looked as if it was seen through a dense fog. The field of vision, as well as could be tested by using the fingers as a perimeter, was apparently normal in all directions except up and in, where it was contracted. The ophthalmoscope showed the media clear, the disc nearly on the normal level, but covered by a grayish, semi-transparent haze which extended into the adjacent retina. There was but little change in the caliber of the main branches of the central vein and artery, the latter being possibly slightly less in diameter than usual. There were no choroid changes. The right side of the nose had lost its sense of smell and the skin and mucous membrane of this region was less sensitive to touch than corresponding areas of the other side. There was loss of taste at the right tip of the tongue and absolute deafness in the right ear. There was not, nor had there been, either sensory or motor paralysis of any other portion of the body. The knee-jerks were prompt on both sides. She has spells of nausea and of violent headache. I saw the patient six days later, and in that time she had entirely lost vision in the left eye, but there was little alteration in the ophthalmoscopic appearances. At this time she complained very much of itching and dryness in the nose and throat, which could only temporarily and partially be allayed by the use of cocaine. I did not see the patient again during her life, but Dr. T. J. Yarrow, the attending physician, reports that there was great and increasing suffering from headache and nausea, and at times the most intense neuralgia in the superior and inferior dental nerves, usually on the right side, and that there was absolute loss of taste and smell, the patient being entirely unable to tell milk from soup. There was frequently intense pain in the head and back of the neck, but there was never any paralysis of the arms, legs, or body. Once only was there any febrile movement, when the temperature remained above normal for 36 hours, reaching a maximum of 102 degrees. A few days before death the right

eye became so prominent that the lids no longer closed over it, and ulceration set in at the lower part of the cornea. On the 10th of June the patient suddenly became comatose and died. It was with great difficulty that the relatives were persuaded to permit even a partial autopsy, and we were obliged to content ourselves with an inspection of the body and an examination of the cranial contents, — the examination of this part being skillfully made by Dr. J. P. Crozer-Griffith. The skin was yellowish, the body very much emaciated, the right eye prominent, and in raising the upper lid there was seen a crescentic ulcer of the lower third of the cornea, with chemosis of the bulbar conjunctiva in the vicinity. The left eye was not prominent, and its cornea showed the usual cadaveric haze, but no ulcers. There was a layer of fat under the scalp. The veins of the cancellated tissue of the calvarium were empty; the veins and sinuses of the dura mater being moderately filled with blue-black blood; the arachnoid and pia were apparently healthy, and there was no sub-arachnoid fluid. The hemispheres were healthy, (except the lower part of the right parietal lobe), as were also the corpora striata, the optic thalami, the internal capsule, and the crura of the cerebrum and the cerebellum. On attempting to lift the anterior part of the brain, a large, firm tumor was seen occupying the sella turcica, it being tightly attached to the thickened periosteum. It extended along the wings of the sphenoid bone on each side, reaching further on the right, where it was also firmly attached to the sharp ridge of the right temporal bone. The optic chiasm was soft and swollen, as were also in a less degree the optic nerves and tracts. The tumor involved the second, the third, the fourth, the fifth, the sixth, the seventh, and the eighth nerves of the right side, and the second and the third on the left. It was so firmly attached to the body and wings of the sphenoid bone, that in cutting it loose the sphenoidal cells were opened, and mucus from them floated into the cranial cavity. The tumor crept down along the periosteum at the base of the skull, almost to the spinal canal. Eyes, chest, and abdomen were not examined. Subsequent careful examination of the tumor by the microscope showed it to be a carcinoma.

The first case is interesting as that of a tumor commencing in the right temporal lobe and posterior part of the optic thalamus, and by its pressure upward on the lower side of the right tract causing difficulty of conduction in the nerve and a corresponding defect in the left upper part of each field of vision. The inability to read for any length of time was the first symptom, and one that lasted for two months before others developed, and was not dependent upon central scotoma, but was probably due to the rapid giving out of nerve fibers where pressure rendered the transmission of nerve impulse difficult. In spite of the pressure on the right tract, no abnormality in the intra-ocular ends of the optic nerves could be seen for a period of five months, when they commenced to become hazy, and the swelling increased so rapidly that in four or five days marked choked discs developed. It also shows that any symmetrical defects in the fields of vision should be a warning to us of the critical condition of our patients, as they are far more apt to be caused by hemorrhage or tumor pressing on the extension of one optic nerve, posterior to the chasm or its cortical center, than by patches of degeneration occurring simultaneously in corresponding parts of the optic nerves, and their internal prolongations.

In the second case, the tumor probably originated in the periosteum of the petrous portion of the right temporal bone, causing neuralgia of the trigeminus and interference with hearing on this side for several months before it spread and surrounded and pressed on the optic nerves at their exit from the cranium. When conduction was thus cut off, there was only gray haze of the head of the nerve and surrounding retina, such as we might expect after division of the nerve by some sharp instrument, and such as we are familiar with as part of the symptoms of a retro-bulbar neuritis, instead of the usual appearances of choked discs or descending neuritis.

DISCUSSION.

DR. HENRY D. NOYES, of New York. — Was the diagnosis of the probable location of the tumor made in both cases during life?

DR. NORRIS. — In the first case we were practically agreed as to the probable location of the tumor, that it was near the

right optic tract. I must confess that in the second case I was not clear in my opinion as to its exact location. From the fact that there was no paralysis, it was tolerably evident that it was in the anterior part of the cerebrum.

A CASE OF INTRACRANIAL NEOPLASM WITH LOCALIZING EYE SYMPTOMS: POSITION OF TUMOR VERIFIED AT AUTOPSY.*

BY CHARLES A. OLIVER, M.D.,
PHILADELPHIA.

On the 28th of February, 1890, Dr. Francis X. Dercum and the writer met Dr. A. S. Gerhard, the attending physician, in consultation in the case of H. N., aet. 39 years, a bridge and wharf builder, who, without any history of traumatism, abuse of stimuli or tobacco, or venereal contagion, stated that for two years previously he had suffered with vertigo, headache, and attacks of momentary blindness. In April of 1889, his right foot felt stiff, numb, and weak, while he repeatedly stumped the toes of his right foot against objects: this persisted until August of the same year. At this time a series of curious motor symptoms of a peculiar nature developed themselves. The right arm was adducted to the trunk, the forearm became flexed upon the arm, the hand was thrown against the forearm, while the fingers remained extended, especially the index, the middle, and the ring finger, the seizures holding their maximum for the fraction of a minute, and then gradually disappearing. These attacks became increasingly frequent until, when the patient was first seen, they occurred every few minutes. Dr. Dercum, who saw several of the seizures, describes them as distinctly athetosic in character. During the attacks the right leg would become extended.

When first seen by Dr. Dercum on February 3, 1890, the patient appeared to be a well-built, healthy man, with seemingly

* Dr. Dercum has presented a short account of this case from a neurological standpoint at the last meeting of the American Neurological Association. The present report is given from an ophthalmic view only.

hard, firm muscles. Careful examination, however, showed that the right leg dragged as if spastic. The right grip was weak, and the right patellar tendon reflex was much exaggerated. Right ankle clonus was pronounced at every examination, while knee clonus could be produced upon the same side at times. No distinct evidences of any mental impairment could be determined. Temperature sense, pressure sense, and muscular sense were all markedly diminished on the right side. Right lateral hemianopsia, without any other gross ocular lesion was found.

On the 26th of February the patient complained of headache associated with marked diminution of sight in the remaining half fields of vision. At this time he became irritable and nervous. Two days later, when first seen by the writer, the following ophthalmic grouping of symptoms were noted:

1. *Acuteness of Direct Vision for Form.* — Reduced to $\frac{1}{8}$th of normal (V. $\frac{5}{40}$) equally on each side, even when error of refraction (M + Am.) was properly corrected by minus lenses, thus showing marked disturbance either of some portion of the ocular apparatus, which is distributed to both ocular retinæ, or of the ocular tunics themselves.

2. *Direct Vision for Color.* — Slightly lowered, especially on the left side, the error manifesting itself for both green and red. This result also shows disturbance either in some part of the ocular apparatus, which is distributed to both ocular retinæ, or in the ocular tunics themselves, the greater disturbance being upon the left side.

3. *Power and Range of Accommodation.* — Normal for age, and amount and character of error of refraction on each side.

4. *Position and Area of Visual Fields.* — Right lateral hemianopsia much more marked on the left side.* These conditions of the visual field are extremely important, as they doubly point, both by the relative smallness of the left visual fields and the left-sided position of both of the remaining areas towards a disturbance of the visual apparatus in the left cerebrum.

5. *Fleeting Negative Scotomata.* — Marked throughout the

* The accompanying chart shows this very well, the remaining fields of the right eye occupying about 1-12th of their normal areas, while those of the left side are at least six times smller.

LEFT.

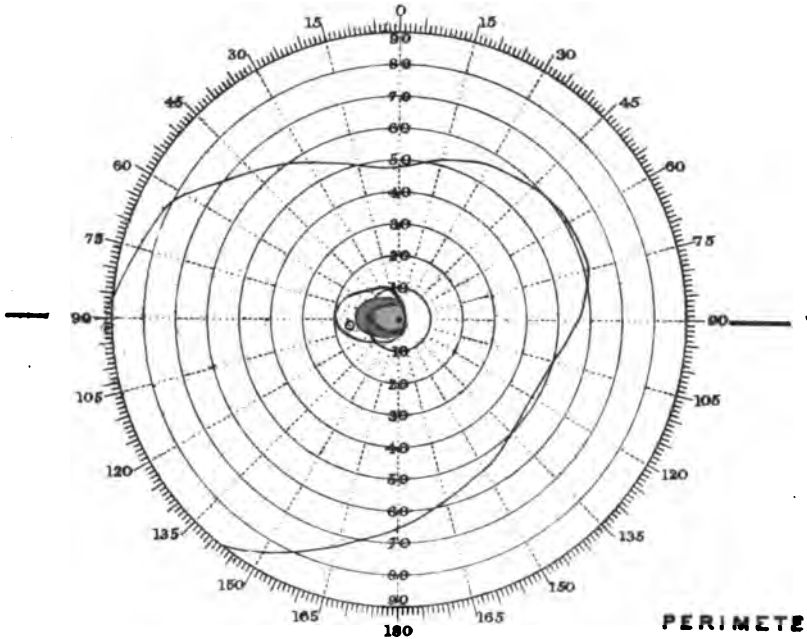

RIGHT.

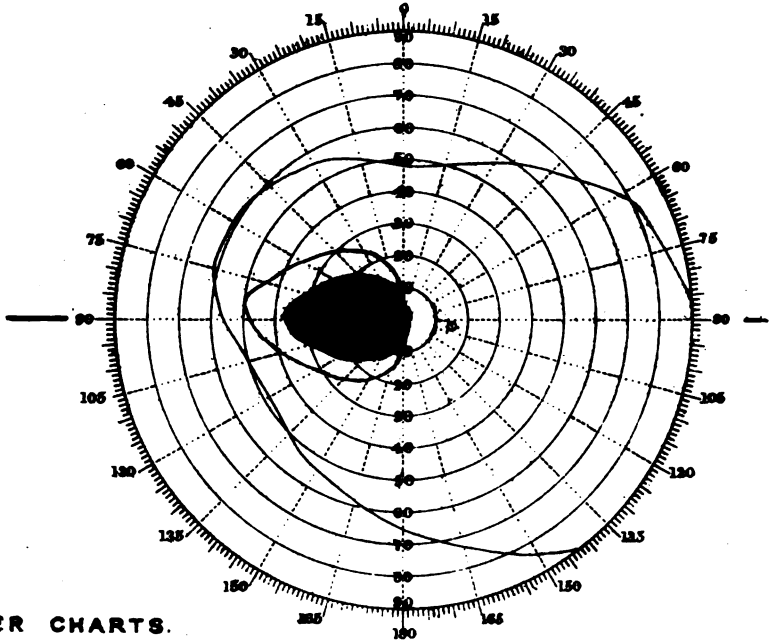

PERIMETER CHARTS.

remaining green color areas, more pronounced in that of the left eye: this symptom is of immense collateral advantage, as it distinctly shows that the greater amount of irritation is on the left side.

6. *Size of Pupils.*—Pupils four millimeters each in horizontal meridian upon monocular exposure to equal degrees of light stimulus.

7. *Action of Irides.*—Wernicke hemiopic pupillary reaction sign, more properly hemianopsic pupillary inaction sign,* plainly manifest upon both sides, the left iris not so prompt to light stimulus as its fellow; these two peculiarities of iris behavior —the hemianopsic want of response and the inequality in amount of action taken in conjunction with the fourth observation—serve to distinctly show some disturbance in the sensory-motor arc of the ocular apparatus at the base of the brain in the left optic tract anterior to the corpora quadrigemina and posterior to the optic commissure.

8. *Extra Ocular Muscles.*—With the exception of a slight insufficiency of both interni, extra ocular muscle motion was intact in all directions.

9. *Fundus Changes.*—(a.) Characteristic peculiarities associated with higher degrees of myopia were equally pronounced in both eyes.

(b.) Both retinal veins and arteries of the right side were enlarged, tortuous, and apparently carrying dark colored blood, a condition which is probably explained by either lymph or blood extravasations into the tissues of the optic nerve and its envelopes.

(c.) A broad superficial splotch-like hemorrhage, extending over the lower outer quadrant of the right disc, and not seemingly connected with any retinal or choroidal stem; this most curious symptom may be partially explained upon the supposition that the mechanical impediment to the passage of fluid into the intravaginal sheaths of the optic nerve by an intracranial neoplastic formation is greater on the affected side of the brain than on the opposite.†

* Seguin uses the term "Hemiopic pupillary inaction sign." As the term hemiopic has been discontinued, the modified term, as above given, is most probably the best.

† Vide article on ophthalmoscopy in Vol. IV of Keating's Cyclopedia of Diseases of Children: "It must be distinctly understood, however, that the rule can only be true when the optic

It will be thus seen that the eight conditions contained in the second, fourth, fifth, seventh, and eighth observations taken together, point distinctly towards a left-sided gross intracranial lesion, situated in such a position as to cause the greatest pressure upon the left optic tract between the corpora quadrigemina and the optic chiasm, with a probable irritation of a few of the contiguous crossing fibers of the right side at the chiasm.

Taken in conjunction with the right hemianæsthesia and right hemiplegia, these ocular changes probably place the lesion near or in the left optic thalamus (the pulvinar).

During the following three weeks the patient complained more and more of diffuse headaches until at last he became somnolent and stuporous, dying on the morning of 21st of March.

Post-mortem examination showed a normal calvarium with no special peculiarities of the membranes, except that they were somewhat injected, and were rather dry. The left hemisphere was distinctly bulging, whilst the superficial substance of the brain appeared pale and somewhat anæmic. Upon horizontal section the left lateral ventricle was found to be shallower than the right, though both were otherwise normal. The left optic thalmus was distinctly indurated and resistant to the touch, its substance being decidedly distended and swollen. Perpendicular section of the hardened mass revealed a neoplasm invading the external portion at the left optic thalmus, as well as the corpus striatum, almost as far as its anterior third. The growth itself was pinkish yellow in color, and was more resistant than the surrounding tissue. The

nerve extravasation has been secondary, as it were to the great increase of cerebral bulk. An illustration of the opposite condition is to be found in Dr. James J. Putnam's most interesting exception, where a sarcomatous tumor, involving the posterior half of the right middle convolution, gave a much greater optic neuritis upon the same side as the tumor mass. Here it is most probable that the extravasation of the increased cerebral fluid into the optic nerve sheaths was quite early in the later history of the case, thus allowing the greatly augmented after-pressure from the sudden and excessive exacerbation of the tumor-growth upon the right side, at the time when first seen at the hospital, to block the previous extravasation and push it more forward into the interior of the right eye than into the left eye, and thus give the greater intraocular swelling upon the right side. This supposition is strengthened by the post-mortem examination, where the surface of the right hemisphere was found pushed across the median line. The base of the brain appeared normal, except that the optic tracts were excessively flattened by pressure, and the right optic nerve was somewhat larger than the left and reddish in color."

capsule was not invaded. The left optic tract, as far forward as the chiasm, was markedly flattened and pressed upon. The right brain was seemingly untouched and unharmed.

Microscopic section of the tumor-growth revealed a glioma with commencing sarcomatous degeneration. Study of the optic tracts, chiasm, and optic nerves resulted negatively.

THE THERAPEUTIC EFFECT OF PRISMS IN OPHTHALMIC PRACTICE: A STUDY OF ONE HUNDRED CASES IN WHICH THEY WERE PRESCRIBED.

HENRY D. NOYES, M.D.,

NEW YORK.

Among the cases herewith presented are included both those in which subjective eye symptoms were the controlling element, those in which these were associated with headache and other nervous disturbances, and those likewise in which headache and nervous troubles were the only symptoms complained of. The subjective eye symptoms were of the kind commonly grouped as asthenopic. In making records, little effort was made to draw from the patient an elaborate story of his sensations; only prominent features were selected both to save time and from a dislike to verbosity. On the contrary, the objective symptoms, in examination of refraction and of muscular capacity, were patiently investigated. The state of refraction was determined by the ophthalmometer, by the ophthalmoscope, by test glasses; and, in selected cases, by the help of full accommodative paralysis with atropia. Every case was examined by two observers. Resort was had to atropia when there were signs of spasm of accommodation, when the finding by the ophthalmoscope and the ophthalmometer did not tally with the examination by glasses, and when no obvious reason appeared for the failure to procure normal visual acuity. If the question is asked how spasm of accommodation is to be discovered without

employing a mydriatic, the answer is: the ophthalmometer discloses what is practically the real degree of astigmatism (admitting an occasional error of 0. 5 D or 1 D, which belongs to the lens), the ophthalmoscope (carrying behind it, if needful, a correcting cylinder) will, in almost every case, disclose hypermetropia; and lastly the patient is asked to read Snellen's line of smallest capitals, No. 1: NPRT, etc., through a pair of convex prisms, consisting of $+\frac{1}{12}$ combined with prism 5°, the bases inwards. Emmetropic eyes see this print if there be no spasm at 12 inches without the prisms, provided the convergence of the visual lines does not induce accommodative effort. If the convergence of the visual lines be abated by prisms amounting to 10°, this stimulus to accommodation is eliminated, and emmetropic eyes, with visual lines converged not to a point 12″ distant but to one about 60″ distant, will read the print at 12″. Hyperopic eyes will read it beyond 12″; myopic eyes at less than 12″. In all cases, having by other methods acquired an approximate idea of the state of refraction, the behavior of accommodation is denoted by the distance at which through the convex prisms the print is read. A variation of one inch is not important; but if emmetropic eyes can make out the print at only 10″ or 9″, this signifies spasm, and suggests atropia. I have employed this plan of proceeding for twenty years, and am satisfied, in a general way, of its trustworthiness. Subjective symptoms of extreme pain, of frequent blur, of lachrymation, etc., will sometimes give decisive indications, and both the youth and sex and excitability of the patient will determine what should be done. This explanatory statement is made to vindicate the avoidance of mydriasis when no rational indications for it appear.

It is proper here to remark that deficient power of abduction is frequently associated with spasm of A, and that it is also set aside by suitable prisms (viz., adductive) without mydriatics.

Among the 100 cases to be discussed atropine was used in 7 instances, and in all these the ametropia was 1 D or less. What has been remarked is intended to rebut the argument that if in the following cases atropia had been more extensively used, a larger amount or a larger proportion of refractive error would have been disclosed, whose correction would have

or might have relieved the symptoms without resorting to prisms.

It is admitted that in some cases an unnoted error of 0.5 D or .75 D might have been brought to light, but it is not admitted that this addition to the correcting glass would have furnished relief. In many instances the experiment had been made of using glasses to correct ametropia, and with only partial relief; while the full benefit was not secured until prisms had been added. A very notable instance is case 51: the patient was provided with suitable cylinders for astigmatism, but did not get relief until she wore prisms for both insufficient abduction and vertical error (hyperphoria).

This paper might be entitled a study in therapeutics. Confessedly, no chapter in medicine is beset with so many difficulties. Especially is this the case when the test of our success or failure is the patient's testimony about pain or improved function. The possibilities of mistake the experienced physician well knows. Patients are eager to be better or are discouraged, and may deceive themselves and him either in one direction or its opposite. It is true we deal with measurable factors when we test ocular muscles by prisms, but experience shows that there is no absolute standard of normal capacity and comfortable use of the eye muscles. Although it will appear, I think, in this paper that some reliable data can be obtained to determine within what boundaries we are to look for pathological conditions, some unexplained discrepancies thrust themselves forward. We find, for example, that in some instances of notable relief there was very little corresponding change in the behavior of the ocular muscles; in other such instances there were improved muscular conditions. But the answer must be, that in such complex problems we do not know all the elements. Nevertheless and in spite of seeming inconsistencies, we have no other reliance than the persistent declaration of a patient that whereas once I could not work, now I can work; whereas I once had pain, I now have no pain or less pain, etc., etc. The one indispensable condition for a just conclusion is, that the patient shall have been under observation long enough to render a judg-

ment sound and correct. In these 100 cases this condition is complied with. In this respect I think it may be claimed that they are removed from the category of imaginative cases of which a most signal class is found among the patients now being dealt with, as the French say, "by suggestion." My aim has been to exclude such; and while in all the cases presented there seemed reason for employing prisms, in not a few their prescription was made as an experiment, just as, in giving drugs, we try this or that at a venture. These tentative cases are reported; and if the result sometimes was failure, an attempt is made to tell why. Sometimes it is as difficult to account for a success as for a failure.

The 100 cases discussed are taken consecutively as they occurred in private practice, and the only rule of selection has been, that there should be definite knowledge of the final result of treatment in each one.

The cases may be classified as follows:

Sex.— Males, 60; females, 40 = 100.

Age.—	Under 10	years,	2
	" 10 to 20	"	32
	" 20 " 30	"	39
	" 30 " 40	"	19
	" 40 " 50	"	5
	" 60	"	2
	" 83	"	1 = 100

Occupation.—	School children, students, and teachers,	39
	Book-keepers,	8
	Lawyer,	1
	Typewriter,	1
	Mechanical draughtsman,	1
	Seamstresses,	2
	Milliner,	1
	Merchants,	4
	Physicians,	4
	Dentist,	1
	Banker,	1
	Managers,	3
	Army officer,	1

Restaurant keeper,	1
Peddler,	1
Commercial traveler,	1
Not specified, and mostly married women,	30 = 100

In more than three-fourths of the cases the occupation was of a character demanding persistent and exacting eye-labor.

Health. — In all cases where conspicuous conditions existed a note was made; but, when there was no evident reason for inquiry because manner and appearances betokened good health, and nothing was said to the contrary, no note was taken.

Health, good in	63
Over-worked or exhausted,	15
Health, not good in	22 = 100

It appears that about 40 % can be said to be in poor condition. Yet, by no means all of them were invalids. All were able to come to my office. Among the cases were not a few instances of persons in typical and even exuberant health. Some were men of large stature and great physical development.

Ocular Symptoms may be grouped as follows: pain, in 49; blurring or unsteadiness of print, in 18; inability to look at moving objects, such as a crowd of people, scenery from a railway window or from a carriage, playing cards, turning leaves of a book, etc., in 17; inability to look fixedly at one object, as at a speaker in church or at a theater or in conversation, 12 (these last two symptoms are eminently characteristic, and much more frequent than the record shows); incapacity for continuous reading or sewing or piano playing, etc., in 60; tendency to lose the place in reading, 2; troubled by seeing the nose, 2; difficulty in keeping eyes open, 2; occasional diplopia, 5; occasional strabismus, 2; photophobia, 4; unsteadiness of globes, especially twitching at the outer angles in lateral movements, in 11 (this symptom is far more common than is thus indicated; it belongs to a majority of the cases, because the recti externi are the muscles chiefly at fault: *vide infra*); spasm of accommodation, in 14; conjunctivitis usually slight, in 35; blepharitis, in 2.

General Symptoms. — Headache, in 57. In many instances it was the determining symptom which demanded relief. In most cases this was general; in some it was frontal or temporal or occipital or at the vertex. A singular feature of headache to which my attention has been called more and more of late is, that it often exists on first waking in the morning, and is increased during the day. I have come to regard this fact as indicating neurasthenia quite as much as asthenopia. But it does not always appear in persons of poor health. Vertigo noted in 9; nausea, in 7; insomnia, 1; melancholia, 1; forgetfulness, 1; inability to fix mind on work, 3; pain in remote parts, 3 (this number might have been much enlarged had care been taken to make thorough inquiry, but lack of time usually prevented); tenderness over supra orbital nerves, 3. Nasal catarrh was found in 16, and this complication was carefully looked for. Sometimes it required treatment; it was always complicated with palpebral conjunctivitis, and often severe. It may be noted that headache co-existed with nasal catarrh in only 5 of the 16 cases; and 11 were free from headache.

Passing now to the *state of refraction*, we have emmetropia, 47; hypermetropia, 25; myopia, 0; astigmatism, 27; viz., as. hypermetropic, 21; as. myopic, 4; as. mixed, 2; antimetropia, 1 = 100.

The refractive condition is certainly noteworthy, because 47% were normal eyes. Moreover, the degree of ametropia was less than 1 D in 45 more, making the total, in whom refractive error was either absent or insignificant, 92. The presentation of this fact seems quite enough to establish the claim that the element of distress in the cases was not the refractive error. A further argument to corroborate this conclusion is found in the fact that in 18 cases exhibiting refractive error, correcting glasses had already been tried without any beneficial result, and relief was obtained where prisms were employed with or without what may be called "focalizing" glasses.

We have next to state what muscles were chiefly affected. It would be most accurate to classify the cases by the functions of adduction and abduction and vertical movement, since in all of them several muscles are concerned; but, for the sake of

simplicity, the interni and externi will represent the groups concerned in adduction and abduction.

The number of cases of actual or supposed weakness of the externi was	92
The number of cases of actual or supposed weakness of the interni was	7
The number of cases of general muscular weakness was	1 = 100

It must be added that among these cases were seven which exhibited, in addition, an error in movements up and down, whether the meridian was vertical or oblique. Since considerable importance has been attached to the influence of this kind of error, reference may be made to the individual cases: they were numbers 10, 11, 19, 26, 50, 51, and 52.

No. 10 was a case of weakness of externi, and there was a vertical error of 2° for both distance and near. He was a medical student, aged 20; was emmetropic; was under observation two years. He wore prisms of 2° each with bases outward, and had complete relief and ability to work; the vertical error disappeared.

No. 11 had insufficiency of the interni, besides vertical error; prisms were of no use, and tenotomy was advised.

No. 19, aged 20, was a typewriter, emmetropic, with weak externi, and a very slight vertical error not more than ½°; wore prisms 1½° bases out constantly; was under observation 2½ years; while wearing glasses, had perfect relief. The remark is made that tenotomy for vertical error was suggested, but was never done.

No. 26, merchant, aged 34, with weak externi, given prisms 1½° O.U. for constant wear; under observation 6 months; was greatly improved, but did not get entire relief. A small vertical error was found, but nothing done for it.

No. 50, male, aged 19, student, with weak externi H + 0 50, was given prisms 1½° bases out for constant wear; was under observation 2 months. The existence of vertical error was predicated upon his habit of carrying the head inclined to the left shoulder. Moderate relief was obtained by the prisms, viz., the

increase of reading ability from 1½ hours to 3 hours daily. This result was not esteemed satisfactory, and tenotomy was advised.

No. 51 had proper glasses for astigmatism, but only got relief, by correcting errors both of abduction and of vertical deviation, viz., O.D. prism 1° base up, O.S. prism 2° base out, added to cylinders.

No. 52, female, aged 20, complains chiefly of headache, and had it for 2 years; under atropine H + 1 D; has weak externi; the head inclines to the right shoulder. Left eye stands higher than the right; asymmetry of the bones of the face; Ord. prisms 1½° bases out which she wore constantly for a month; subsequently used them only in near work; under observation 6 months; almost complete relief. For a time tenotomy was contemplated, but was not done. General health became better under the comforting effect of the prisms, and in the end they were laid aside.

These are all the cases of vertical error included among the present hundred, and in only one was this corrected by prisms. In the remaining cases it had no special import. I can furnish others where prisms with bases vertical were worn to advantage, and in other cases I have done tenotomy of either the superior or inferior recti. I find vertical errors rare, and in the large number of cases they do not need special consideration. I do not omit looking for them when proper relief is not obtained, nor where any suspicion of their existence can arise.

It will be seen that muscular asthenopia falls upon the function of abduction with an overwhelming preponderance. I was being led to this conclusion, in 1884, when a paper was read on this topic before the International Medical Congress at Copenhagen. Wider experience has given rise to absolute conviction that the externi are at fault with far more frequency than the interni. But it is not claimed that the ratio is so high as the present cases would indicate. This fact will more frequently come to the surface, when investigators shall free their minds from the prejudice that muscular asthenopia must be associated with ametropia, whether myopia or hyperopia or astigmatism. As a fact, the number of emmetropic eyes

among the community is immensely in excess of ametropic eyes. They *should* yield the largest contingent of cases of muscular error, provided the searcher looks for muscular error habitually and apart from, as well as associated with, ametropia.

Diagnosis and Mode of Examination. — My examinations have had respect to the working amplitude of convergence. I have not paid any heed to the so-called fusion near point or maximum of convergence. For emmetropic eyes I have taken 13″ or one-third of a metre as a standard for the near (*punctum agendi*), and the same for hypermetropia, with proper refractive correction. Only in myopia has a shorter distance been sometimes employed. I believe we can come to more valuable practical results by testing the patient's capacity to overcome prisms at 13″ than we can arrive at by employing the seemingly more scientific method of the nearest point of absolute fusion and working upon a basis of angles of convergence. We must give a patient time to learn what he is to do with prisms, and for facility of testing I may commend very strongly a simple device for holding prisms and other glasses which I have used for twenty years and which is figured in my text-book on diseases of the eye, p. 195. What we learn by prisms at 13″ is, how much is the reserve power, and what are the relations of opposing muscular groups at the place where the patient does his work. This is the real object of our inquiry, and at this distance should we make our investigation. I make these remarks, because in this I differ from Landolt and most of the European authorities who write on this topic.

Neither do I lay so great stress upon the indications of the so-called equilibrium test of Graefe as many do. Especially do I insist that we ought to abandon the habit of designating the findings by this test as the measure and expression of the muscular insufficiency. For example, many say, and I formerly said, that if, in causing vertical diplopia by a prism with base upward, the images require a prism of 3° or of 6° to bring them into a plumb line with each other, this prism of 3° or 6° is the measure of the muscular insufficiency, and we assume that we have to do with exactly this amount of muscular

debility. (The new nomenclature of Dr. G. T. Stevens gives special names to these deviations, — esophoria and exophoria, — and, by so doing, tends to fix upon them an unwarranted importance in perpetuation of the former opinion.) I admit the great value of this test, and constantly reckon with it, but I shall show that its precision as a standard of measure is overrated; that it must be taken in connection with other elements, viz., the power of adduction and abduction, both for near and remote points. I suggest that a correct phrase, when we make this test, is to simply write in our notes how many degrees of displacement from the perpendicular there may be in vertical diplopia, whether of convergence (v. d. 3° conv.) or of divergence (v. d. 3° div.), and leave the designation of the amount of actual muscular insufficiency to be estimated by all the findings we gather. We may be unable to state the amount in number of degrees with precision, but we can state it proximately, and escape the error of a false estimate by assuming an unreliable standard.

It has become my rule to regard abductive power, at 20 feet, of 5° or less, as sub-normal. Sometimes abduction of 6° is regarded with suspicion. As a rule the normal amount at 20 feet I find to be from 6° to 8°. If adduction stands at 20° or 25°, and after a few days rises still higher, while abduction remains 5°, and *distressing symptoms exist*, the indication for prisms with bases out is clear enough for trial. If abduction be 4½° or less (because half degrees are important), the indication is conclusive.

I do not assert that abduction less than 5°, even with adduction above 25°, must always be regarded as proof of deficient ability for eye-work. I have examined many persons, who come under this category, who made no complaint of their eyes or of headache. My assertion is, that when complaint of eye or head symptoms concurs with such findings in abduction and adduction, we then are entitled to fix upon the muscles as the probable factors in the trouble. In other words, to some persons very feeble muscles or muscles in very great disproportionate power do not cause distress; while to other persons they are most

manifest cause of distress. What the unnamed quantity may be which determines either of these results, is matter for study. It may reside in the muscles or in the innervation or in both combined. Because it is unnamed, and may be various in character, it does not vitiate the conclusions of a scientific induction of ascertained facts.

Treatment.—It is almost needless to premise that any indications to be gathered from the state of health were invariably, and, so far as possible, efficiently, attended to. For example, exhausting causes, viz., over-work, extreme study, physical depression, mental distress, lack of suitable food and exercise, were so far as possible controlled. In some there was an extremely neurotic diathesis or irritating gouty diathesis to be dealt with, and usually with small success. Some were instances of great nervous depression, to be fairly called neurasthenia. In some there was uterine disease; in one there was chronic cystitis; in two there was chorea. Two had epilepsy. Nasal catarrh was noted in 16 cases, and always was attended to, and its influence upon the symptoms carefully discriminated. Mild conjunctival irritation was common, and in some cases was the chief source of discomfort. Usually it disappeared. But in two cases it proved obstinate, and the attempt to relieve it by prisms did not succeed. Giving heed to all that general therapeutics required, it is to be stated that many patients had already, at the hands of other physicians, been submitted to general and local treatment without relief; some had been seen by oculists. All these patients were regarded as having muscular asthenopia, and in the great majority this was counted the efficient factor in their trouble. In some the employment of prisms was tentative, and considered of uncertain value, and in some cases they were given to determine the diagnosis. Sometimes adductive prisms were given when the adduction was as low as 7° or 10°; and if they were afterwards found notably useful, adduction materially increased. In some extremely difficult cases, with both abduction and adduction feeble, such prisms were employed as a possible relief, but proved to be of almost no benefit. I attach controlling importance to the results of examination at the far point. I order prisms with this in view, and have been taught

by experience that errors at the near point will frequently disappear or be so much abated as to secure the patient's comfort. Hence, I prescribe prisms to be worn continuously, and in exceptional cases only do I order a different kind of prismatic glasses for the near point. I sometimes, in a doubtful case, hook a pair of prisms upon the frame of the glasses which a patient must use for refractive error, and this permits their removal when desirable. Schiötz (l. c., p. 183) says: "Prisms are the most difficult things to order, because we can never predict what effect they will have. Many people cannot endure them; to others they are of the greatest assistance. If prisms seem indicated, I always tell the patient that they are chiefly experimental, and may be of no use to him." My experience has taught me to look for benefit from prisms with much more certainty in properly selected cases than most oculists have been able to do. I always insist that the patient must persevere in wearing them for several hours daily until all the preliminary annoyances disappear, and they can wear them for the entire day. I usually say that they must expect to be bothered in crossing streets and going down stairs, etc., and they will not be fully used to them for a week. After that period I want them to report to me. My rule is, to employ prisms of low degree, and it will be instructive to note that in the hundred cases the strength of the prisms was as follows:

Prisms	1°	each	eye	in	7	cases.
"	1½°	"	"	"	65	"
"	2°	"	"	"	20	"
"	3°	"	"	"	4	"
	1½° O. D., 2° O. S.				1	"
	2° O. D., 1° O. S.				1	"
	3° O. D., 2° O. S.				1	"
	4° O. D., 2° O. S.				1	" = 100

In 66 cases the total amount of the prisms reached only 3°, and in 20 it reached 4°. In 1 case it was 5°; in 5 it was 6°. In 7 cases it was only 2°. What physical effect on the visual lines is gained by prisms of 3°? This amounts to a little less than half a metric angle (one metric angle is represented

by a prism of 7° for an interocular base line of 61 mm.). The cases in which the total amount of the prisms was 4° and less, sum up 94. Of these, 88 wore prisms with bases out, 3 wore prisms with bases in, and nearly all wore them constantly. In 4 cases, Nos. 54, 65, 69, and 78, they were only used in reading, and there are some other partial exceptions. We find, therefore, that these weak prisms were used in 88 cases to relieve the strain on divergence; and that the abatement was about one-half a metric angle. The total amount of convergence called for in normal eyes at 13″ or ⅓ metre is 4 metric angles, viz., 3 positive and 1 negative. But the cases under discussion were always defective in the negative metric angle, because their abduction was less than 5°, and we may call it 3½°, which gives them for a working distance of ⅓ metre a total range of active convergence of 3½ metric angles. An abatement of ½ a metric angle is in the case of these persons a reduction of the labor of the adductor muscles of one-seventh. This way of presenting the matter seems fair, notwithstanding the total capacity of convergence is disregarded by leaving out that large part which lies between ⅓ metre and the absolute near point of fusion. The portion considered is what we use, and the continual relief which is bestowed by subtraction of one-seventh the labor required seems to me an adequate explanation of the good results. A closer analysis will be made a little later.

In a general way the results of treatment may be stated as follows:

Relief of symptoms	complete or very great	in		69
"	" moderate or partial	"		10
"	" slight or temporary	"		7
"	" not attained	"		14
Total,				100

The failures were cases 11, 17, 25, 27, 34, 38, 42, 43, 58, 61, 66, 71, 72, 97. Of these, Nos. 11, 25, 66, 71, and 97 were advised to have tenotomy. No. 17 suffered severely from chronic cystitis; and when she made this known and was treated for it, her eye troubles ceased. No. 27 was a proper case for tenotomy, but in health too feeble and too neurotic to per-

mit it. No. 34 had persistent follicular conjunctivitis. No. 38 had blepharitis and conjunctivitis which were hereditary; trial of prisms caused headache, and he used them only a few times. No. 42 was a physician whose health had broken down, and who was extremely neurasthenic. His eye muscles were all weak, and the trial of prisms was made with little hope of good effect. No. 43 was a seamstress of unhappy temper and surroundings. Treatment by prisms, although correctly indicated, did no good, but at a later time, when her life became more comfortable, her eye troubles ceased. No. 58 was a child of many ailments and poor constitution. The trial of prisms was purely experimental, and the negative result was no disappointment to me. On the muscular findings any other result would not be expected. I yielded to a mother's urgency. No. 61 was an epileptic child for whom the trial of prisms was made for the general malady, and with no success. No. 66 was 60 years old, an ardent sportsman, who practiced pigeon-shooting one day in the week for many hours. He had much tremor of the eyes when turned to the temporal angles. The abduction was very unsteady, giving variable findings; neither prisms nor plus glasses for slight H did much good. He had to relinquish his favorite sport in great measure. A careful tenotomy would have been justifiable.

Cases of slight or temporary relief were Nos. 33, 37, 56, 68, 91, 93, 97. No. 37 had uterine disorder; prisms given tentatively on account of low abduction. After using prisms constantly for a month, no important change in behavior of muscles or symptoms. No. 56 had extreme asthenopia; tenotomy advised. No. 68, extremely neurotic; has most severe neuralgic headache; finds prisms helpful; ought to have tenotomy, but unwilling. No. 93, medical student, with weak interni; prisms useful for two weeks, but not longer; both abduction and adduction low, and, therefore, a difficult case.

It is important to discover what results were obtained in regard to *headache*, for which especially prisms were often ordered.

In 48 cases it was severe enough to be noted, and the result of treatment is recorded:

Complete relief	in	19
Great or very great relief	"	19
Moderate or slight relief	"	6
Temporary "	"	1
No "	"	1
Excited headache	"	2 = 48

In 79 % the prisms had a most happy effect, and were warmly appreciated. There can be no doubt, of course, that the soothing effect was by the muscles upon the innervation. Hence, it is evident that for therapeutic purposes we need not trouble ourselves about the ultimate pathology of the condition we now discuss.

In view of the fact that nearly 70 % of all the cases derived marked benefit from prisms, let us analyze the muscular conditions before and after treatment, in hope of discovering some reason for the fortunate effect.

It is proper to remark that in some cases the beneficial effect was greatly aided by diminution in amount of eye-work (case 5, *et al.*), by improvement in general health (cases 22, 47, 52, *et al.*), and by better surroundings. Moreover, in certain cases, as in 48, relief continued for a period of many months (12), and then trouble returned. Note is made of the instances when the above causes were co-operative.

Out of 69 cases much or completely relieved, I find only 33 in which the figures are complete for the muscular findings both for the near and remote distances, and both at the beginning and end of the observation of the case.

After careful scrutiny, no modification in muscular conditions appears with sufficient uniformity to warrant any categorical deductions. Evidently we have to do with some factors which evade our inquiry, and a large allowance must be made for individual peculiarities (the personal equation). We meet this fact in all living organisms; and without attempting to reduce the findings by prisms to averages or any numerical statements, the following conclusions may be stated:

No typical features prevail in the cases, save *low abduction for distance*, and in most instances this is associated with low abduction at 13″. The degree of *adduction* is extremely variable,

and the same relative amount does not, in all cases, hold good for the two ends of the region. We must not lay undue stress on moderate variations in adduction especially for the near. A fluctuation of 4° or 5° need not have great significance, unless the total is small. The ratio which ought to prevail between abduction and adduction cannot be deduced from examination of these cases, because they are all pathological. Neither can it be ascertained from a study of the condition of the cases which had experienced great or complete relief. They present at this stage very diverse features. We find, as the result of treatment of weak abduction, that in most cases abduction grows less or remains the same; rarely does it increase. A change of 1° for 18′ is important. The behavior of the *adduction*, under constant use of prisms with bases outward, is various. First, the most fortunate cases are those in which it notably increases; bringing usually complete relief. If not fully relieved, they are suitable for tenotomy or may even choose it in preference to wearing glasses. Second, some cases of great improvement show little gain in adduction. In them it may be assumed that adduction has always been low, and the asthenopia has been determined by strain on both adduction and abduction, whose ratio to each other is such as to easily be made discordant, because the reserve capacity in both directions is small. In the previous class adduction is strong and abduction weak; it only requires that the latter function be made able to care for itself and balance its antagonist for ordinary ranges. This being done, there arises no impluse to discordant action. In them it seems often true that the real condition is one of *spasm of adduction* rather than *paresis of abduction.* As a result of long continued spasm, the dominant muscles may ultimately become wearied, and show an abnormally low capacity. Under the soothing effect of prisms benefit accrues to all the muscles, and the original status is restored, viz., weak abduction with high adduction, and is kept harmonious by the influence of the prisms. Third, when we have weak externi coupled with weak interni, and trial by abductive prisms demonstrates that the weak adduction is not temporary or induced by fatigue as just noted, the case can derive little benefit from prisms.

We must address ourselves to the general health, and counsel prudence in eye-work. In these cases weak convex glasses in reading will often give some aid. Resort to regulated use of the eyes (Dyer's method) is very helpful; gymnastic prisms give only little help.

In regard to the equilibrium test something further may be said. It is not rare to find that the degree of lateral displacement with the vertical prism is not fixed. For example, if at 18′ the convergence under vertical diplopia is 3°, a patient may accept a prism of 5° or 7° by a little urgency, and the images continue perpendicular to each other. This means an unstable condition of the muscles in which they are ready for more contraction. The supposition that the suspension of correct binocular vision by a vertical prism renders all the muscles passive, leaves out of view the fact that muscles in tonic spasm cannot immediately relax. We recognize this fact elsewhere; and why not in the eye muscles. I call this, as Loring did, latent insufficiency, or still better, latent spasm of the opponents. Admitting the general correctness of the equilibrium test, more consideration must be given to numerous exceptional cases. For example, if this test is to be our exclusive or even chief guide in prescribing prisms, what is to be said in view of case 10 in which, with low abduction and good adduction, and notable increase of the latter by the prisms and complete relief from asthenopia during two years of observation, the convergence under vertical diplopia rose for 18′ from 7° to 10°, and at 13″ from 15° to 19°. This increase in convergence would denote a more abnormal status of muscles than before wearing prisms, —a conclusion completely negatived by the patients' experience. Almost the same remarks are pertinent to case 44, a case under observation nearly ten years, who wore prisms 2° base out constantly and with entire comfort. His abduction, exceptionally low, dropped from 1½° to ½°, and the convergence on vertical diplopia rose from 8° to 12° for 18′. Again, the amount of lateral displacement (convergence) on vertical diplopia bears no constant relation either to the abduction or adduction at either end of the range. In case 50 at 18′ we have abd. 5°, add. 45°, v. d. ≏ or conv. 4°. In case 89 we have at 18′ abd. ½° to 3°,

add. 44°, v. d. ≏. In case 92 at 18′ abd. 0°, add. 25°, v. d. 25° conv. In case 87 at 18′ abd. 4½°, add. 15°, v. d. 3° conv. A glance over the list of cases will verify the assertion that no fixed relation of this kind can be made out. It is a well-known fact that under vertical diplopia the images may, at 18′, be homonymous, and at 13″ be heteronymous. For example, with vertical diplopia at 13″, a divergence corrected by a prism of 5° is so common as to be tantamount to a normal condition, and it need rarely be considered. On this point my views are supported by Schiötz (Archives of Ophthalmology, Vol. xix, Nos. 2, 3, p. 188, Am. edition) who says: "All this goes to show that the equilibrium test sometimes gives no result at all, and in others an incorrect result, but still I do not believe that we are justified in rejecting the test entirely as some have proposed."

We sometimes are wholly deprived of the ability to use the equilibrium test, as in cases of monocular amblyopia or when one eye is wanting. Muscular amblyopia in persons who have had converging strabismus is not rare. Case 45 is an example; tenotomy for converging squint had been done 11 years previous; each eye had the same degree of astigmatism + 1 D, and in one v. = 1, in the other v. = 0.1, and the defective eye had central scotoma. There was no binocular vision, and, despite thorough trial, double images could not be elicited. The history of the case and the jerky movements of the globes, when striving to reach the outer canthi, determined the diagnosis and treatment. Prisms 3° bases outwards gave entire relief. Case 73 had spontaneously recovered from converging strabismus. It was impossible to cause double images in the beginning. After wearing adductive prisms and frequently repeating the tests, a convergence of 11° on vertical diplopia was found at 18′. She was much helped by the prisms. It seemed also that the tendency to epileptic attacks was diminished.

A suggestion already made seems to me of eminent importance and worthy of repetition, that in many cases of low abduction the controlling circumstance is persistent spasm of the adductor muscles rather than paresis of abductors. This may either remain or pass into exhaustion.

The following conclusions may be deduced from the above discussion:

1. Tests for muscular asthenopia at the punctum remotum have greater value than for the punctum proximum or for the punctum agendi (average 13″).

2. The equilibrium test is valuable, but not decisive, and should not be the measure of error.

3. Weakness of abduction is a far more fruitful cause of muscular asthenopia than is weakness of adduction; the preponderance is not far from 3 to 1.

4. Abduction, at 18′ less than 5°, accompanied by headache or eye strain justifies a trial of weak adductive prisms, which should be worn continuously. They may become permanently necessary, and can, in many cases, be superseded by tenotomy. The rules on this subject are not now considered. They may be only a temporary necessity, and symptoms disappear. In these cases we do not always find the abduction to have increased; in other cases all the muscles show a gain in power or disappearance of spasm. Sometimes the prisms are worn in near work only (cases 54, 69, 78). Prisms, after having been worn with benefit, someimes lose their good influence, and in most cases tenotomy will give relief.

5. Refractive errors must always be corrected; but when of low degree, search must also be made for muscular faults; and if detected, prisms are indicated in conjunction with the optical correction.

6. Many neurotic symptoms, such as headache, vertigo, nausea, mental disturbance, and remote neuralgic conditions, may be relieved by prisms.

APPENDIX.

No. Muscles.	Sex.	Age.	Occupation.	History and Symptoms.	Refraction.	Musc. Condition (Primary).	Treatment.	Musc. Condition (Ultimate).	Results and Remarks.
1 Ext.	F.	21	.....	Headache (occipital) Phlyct. Conj. Unable to use stereoscope. Print unsteady Spasm A.	O. U. + 1 D. V.=1+.	18′ abd. 5° add. 20° v. d. 5° conv.; 13″ abd. 6° add. 30° v. d. 10° conv.	Prism 2°, base out, O. U with correction of R constantly. Local applications for conj.	18′ abd. 3° add 26°; 13″ abd. 8° add. 43° v. d. 11° conv.	Under observation 11 months. Headache completely relieved. Unable to read long.
2 Ext.	M.	16	Student.	Conj. Sees nose. Nasal catarrh.	E.	18′ abd 2½° add. 7° v. d. 1° conv.; 13″ abd. 12° add. 17° v. d. 2½ div.	Local applications. Prism 1½°, base out, O. U. constantly.	18′ abd 2° add. 20° + v. d. 2½ conv.; 13″ abd 10° add. 25°.	Under observation 2 years Conj. and catarrh relieved. Unable to use eyes more than a few minutes with comfort. Sister has similar trouble.
3 Ext.	M.	12	.....	Sees nose. Print blurs. Pain in eyes. Nasal catarrh Conj.	E.	18′ abd. 3° add. 24°; 13″ abd. 8° add. 50° v. d. 10° conv.	Prism 2°, base out, O. U. constantly.	18′ abd. — 1° add. 36°; 13″ abd. 0° add. 45+v. d. 13° conv.	Under observation 2 years Great relief.
4 Ext.	F.	8	.....	Eyes diverge at 4″. Occasional diplopia. Pain in eyes, Some headache.	O. U. + 1 D. V.=1.	18′ abd. 3½° add. 24°; 13″ abd. 10° add. 20° v d. 3° conv.	Prism 2°, base out, O. U. for distance.	18′ abd. 4° + add. 24°; 13″ abd 7° add. 40° v. d. 4° conv.	Under observation 1 year Eyes comfortable. Less headache.
5 Ext.	M.	44	Lawyer.	Had + 1 D. 4 years ago, which did not relieve severe neuralgic pain in eyes. Conj. Photophobia. Unable to use eyes regularly, sometimes not over 10 minutes. Nasal catarrh. Not a robust man. Occasional headache.	O. D. + 1 c. 180°. V.=1. O. S + 0 75s. V=1.	18′ abd. 5½° add 14°; 13″ abd 10° add. 30° v d. 5° conv.	Local applications. Prism 1½°, base out. O. U. for distance and in combination with sphero-cyl. glasses for near work.	18′ abd. 6° add. 30° v d. ≏; 13″ abd 8° add. 45° v. d. 17° conv. * Note.	Under observation 3 years. Partial relief Much less pain. Obliged to spare eyes. Tenotomy indicated.
6 Ext.	M.	46	Railroad Manager.	Overworked and exhausted. Vertigo. Unable to read over 15 minutes. Eyes feel strained.	O. U. + 1 c. 180°. V.=1.	18′ abd. 3° add. 15°; 13″ abd 15° add. 18° v. d. 5° div.	Prism 2°, base out, O U. with cyl correction for constant use.	18′ abd 2° add. 19° v. d. 7° conv.; 13″ abd. 10° add. 20° v. d. 2° div.	Under observation 8 months. Reads 2 hours with cylindro-prismatic glasses. Very comfortable with glasses worn constantly. Tried cylinders alone without relief. Daughter similarly affected.

* The sign ≏ signifies equilibrium.

7 Ext.	M.	10	.....	Pain in eyes in reading. Occasional strab conv. O. S. Can't learn lessons. Teacher thinks him stupid.	E.	18′ abd. 4½° add. 36°; 13″ abd. (?) add. 40° v. d 10° conv.	O. D. Prism 3°, base out. O. S. Prism 2°, base out. Atrop used first Prisms worn constantly.	18′ abd 3° add 47° v d. 3° conv.; 13″ abd. 10° add. 40° v. d 5° conv.	Under observation 4 years. Delighted with his glasses. Wears them constantly. Complete relief. No trouble about lessons. Tenotomy indicated. Hereditary tendency.
8 Ext	M.	27	Merchant.	Conj. No trouble in use of eyes until a few months ago, when he broke down from overwork. Pain in eyes after reading. Seldom has headache Nasal catarrh.	E. Slight spasm A.	18′ abd 3° add. 11° v. d. 1° conv.; 13″ abd. 18° add. 20°. Slight vertical error.	Local applications to lids. Dobell's spray in nose Prism 1½°, base out, O. U. for constant use	18′ abd. 3° add. 24° v. d. 4° conv.; 13″ abd. 10° add. 15° v. d. 1° div.	Under observation 2½ years. Able to use eyes in office work at pleasure by daylight. Irritation of lids much less. Unable to go without prisms.
9 Ext.	F.	39	.....	Severe pain in eyes for 2 months. Wakes at night with pain. Unable to do near work. Sick headache.	O. U. + 1 D. V.=1.	18′ abd 2½° add. 4°; 13″ abd. 15° add. 10° v. d. 5° div.	Prism 1½°, base out, O. U. for constant use.	18′ abd. 3° add. 6°; 13″ abd 17° add. 28° v. d. 4° div.	Under observation 3 months Very little pain if she wears glasses all day.
10 Ext.	M.	20	Medical Student.	Fatigue of eyes in reading. Eyes unsteady in movements outwards. Irregular movement of O. S. evidently depending on faulty Inf. Obl.	E.	18′ abd. 3° add. 24° v d. 7° conv; 13″ abd. 5° add. 30° v. d. 15 conv. Vert error of 2° for distance and near.	Prism 2°, base out, O. U for constant use.	18′ abd 1° add 37° v. d. 10° conv.; 13″ abd. 6° add. 40° v. d. 19° conv.	Under observation 2 years. Vertical error disappeared under use of add. prisms. Prisms give entire relief.
11 Int.	M.	28	Medical Student.	Headache, unrelieved by treatment, for 5 or 6 years. Unable to read without pain in eyes and headache. For a few days unable to read at all. Blurring of print.	O D. + 0 75s. V.=1 O. S. + 0.75c. 100°. V.=1.	18′ abd 12° add. 11° v. d. 14° div. Vertical error of 1½° for distance.	Prism 3°, base in, O. U. for constant use.	18′ abd. 20° add. 13° v. d 15° div.	Under observation 2 weeks Prisms utterly inadequate. Operation imperative.
12 Ext.	M.	32	Physician.	Pain in eyes Unable to read at night. Pain so severe that he often has to go to bed. Frontal headache.	E.	18′ abd. 2½° add. 20°; 13″ abd. 17° add. 30° v. d. 4° conv.	Prism 1½°, base out, O. U.	(?)	Under observation 6½ months. Wears prisms only part of the time. Puts them on when he has the old pain and headache, and is always relieved. Brother similarly affected.
13 Ext.	M.	22	Book-keeper.	Headache and pain in eyes. Obliged to give up college course at end of second year.	O. U. + 0.50 D. V.=1.	18′ abd. 1½° add. 13° v. d. 1° conv.; 13″ abd. 14½° add. 18°.	Prism, 1½°, base out, O. U. for constant use.	18′ abd. 2½° add 35°; 13″ abd. 7° add. 23°.	Under observation 8 mos. Very little trouble after putting on prisms. Had only three or four slight headaches after putting them on. Headache if he leaves them off. Brother similarly affected.

APPENDIX.—CONTINUED.

No. Muscles.	Sex.	Age.	Occupation.	History and Symptoms.	Refraction.	Musc. Condition (Primary)	Treatment.	Musc. Condition (Ultimate).	Results and Remarks.
14 Ext.	F.	20	.....	Pain in eyes, headache, and bleph. marg. Not relieved by + 1.50 O. U. for reading. When first seen had had constant headache for six weeks. Is rather delicate. Spasm A. Eyes sometimes feel as if they would burst.	O. D + 0 75s ⌒ + 0.50c 180°. V.=1. O. S. + 1.00s. ⌒ + 0 50c. 180°. V.=1.	18′ abd. 6° add. 12° v. d. 1° div.; 13″ abd. 22° add. 30° v. d 4° div.	Atropine. Prism 1½°, base out, with + 1 D O. U. for reading.	18′ abd. 4° — 5° add. 22°.	Under observation 6 mos. At one time lost glasses and was "in misery" until they were replaced. Died suddenly a few months after last examination.
15 Ext.	M.	17	Student.	Eyes strained from over use. Conj. irritation. Eyes not painful but feel weak. Can read only 15 or 20 minutes. Some nasal catarrh.	E.	18′ abd. 5½° add. 22° +; 13″ abd. 15°(?) add 27° v d. 6° conv.	Prism 1½°, base out, O. U. for constant use, with additional + 1 D. O. U. in reading.	18′ abd 9° add. 21° v. d. ≏; 13″ abd. 18° add. 35° v. d ≏.	Under observation 1½ years. Soon became able to read from four to six hours a day, reading two hours at a time. Ultimately able to discard glasses.
16 Ext.	F.	60	.....	A few striae in lenses. Nasal catarrh. Conj. Pain in eyes for several years, increasing of late.	O. D + 0 50c. 90°. V.=1. O. S. — 1.50s. ⌒ + 2.50c. 80°. V.=0.9—.	18′ abd. 7° add. 17° v. d. ≏; 13″ abd 20° add. 36° v. d. 5° div.	Sphero-cyl. correction for distance with additional + 3 D. for reading, without relief, followed by prism 2°, base out, O. U. as supplementary reading glasses	13″ abd 20° add 30 v. d. 5° div.	Under observation one month. Before prisms were added could not use eyes at all without great pain. After prisms were added could read one-half hour at a time and could also read some in evening, a thing she said she had been unable to do for a long time.
17 Ext.	F.	34	.....	General health not good. Has some cystitis. Conj.	E.	18′ abd. 6° — 3° add. 32°; 13″ abd. 10° + add. 38° v d. 6° conv.	Prism 2°, base out, O. U. for reading.	(?)	Under observation nine months. Could not wear prisms.

18 Ext	F.	27	.....	Inherits eye trouble and has had it as long as she can remember. Pain in eyes, gums, ears, and back of head follows all kinds of eye work. Eyes twitch, and this is prevented only by great effort. Difficulty in looking at moving objects, and easily nauseated in so doing. Sick headache. Pain in eyes, often so severe as to keep her awake nights. Has had some uterine trouble. Occasional attacks of rheumatism. Neurotic tendencies.	O. U. + 1 D. V.=1.	18′ abd. 3° add. 9° v. d ⚟.	Prism 1½°, base out, O. U. for constant use.	18′ abd. 1° add. 25°; 13″ abd. 14° add. 30°.	Under observation five months. + 1 D. gave only temporary relief. Prisms entirely relieved headache. She is dizzy if she leaves them off, and wholly unable to do without them. On account of neurotic tendencies, value of operative interference doubtful.
19 Ext.	M.	20	Type-writer.	Trouble in use of eyes for 18 months. Can read from two to four hours a day. Has little pain or headache, but says he can't use eyes. Eyes twitch, particularly at outer angles. Has very slight vertical deviation (hyperphoria).	E.	18′ abd. 4½° add 17° v. d ⚟; 13″ abd. 10° add. 25° v. d. ⚟.	Prism 1½°, base out, O. U. for constant use.	18′ abd. 5° add. 18° v.d. 1° conv.; 13″ abd 15° add 18° v. d. ⚟.	Under observation 2½ years. At end of that time could read three to four hours a day. Has found that when he breaks prisms he has headache until they are repaired.
20 Ext.	F.	25	.....	Rather delicate, and had a very serious illness six months ago. Unable to use eyes for three months, and has had pain in using them for a longer period. Pain through temples and eyeballs, with nausea, on attempting to use eyes. Considerable headache. Has trouble only in near work. Prism tests provoked vertigo.	E.	18′ abd. 3½° add. 19° v. d. ⚟; 13″ abd. 16° add. 23° v. d ⚟.	Prism 1½°, base out, O. U. for constant use.	18′ abd. 5° add. 33° v d. 4° conv; 13″ abd. 10° add. 30° v d. 5° conv.	Under observation three months. Able to read one-half hour several times a day. Use of eyes beyond that provokes the old pain, but it does not persist if she stops. Formerly had headache whenever she read, now about once a week only. Improvement in general health.
21 Ext	F	18	Mechanical draughtsman.	For three or four years has had pain around eyes, headache and strained feeling in use of eyes. Sight at times blurred.	O. U. — 0.75s. ⌒ + 0 75c. 90°. V.=1.	18′ abd. 5° add. 30° — 20°; 13″ abd. 20° add. 35° v. d. 2° conv.	O. U. + 0 75c 90° ⌒ prism 1½° base out, for work.	18′ abd 4° add. 27° + v d 2° conv; 13″ abd 21° add. 30° + v. d. 3½° conv.	Under observation two months. Continued to use eyes steadily at her work, mechanical drawing. Much less pain with glasses. Hardly able to work without them. Convex cylinders without prisms had been tried without benefit.

APPENDIX.—CONTINUED.

No. Muscles.	Sex.	Age.	Occupation.	History and Symptoms.	Refraction.	Musc Condition. (Primary).	Treatment.	Musc Condition (Ultimate).	Results and Remarks.
22 Ext.	M.	17	.....	Unable to use eyes for two or three years. Almost constant, severe headache. Had to give up school because effort of looking made him feel "bad." Head "seems queer" on looking steadily at anything. Not a rugged boy. Some conj.	O. D. V.=0.7; Oph + 1 D. O. S. E.	18′ abd. 5¼° add. 5°; 13″ abd. 18° add. 15° v. d. 10° div.	Prism 1½°, base out, O U. for constant use. Local applications for conj.	18′ abd. 6° add. 30° + v. d ⚟; 13″ abd. 17° add. 23° v. d. ⚟.	Under observation four and one-half months. Uses eyes very little in reading, but has no pain or headache, whereas before wearing prisms headache was almost constant.
23 Ext.	M.	20	Clerk.	Headache for six years, increased by eye work. Has had to give up reading. Headache in church and theater. Severe nasal catarrh.	E.	18′ abd. 5° add. 20°; 13″ abd. 10° add. 15°.	Prism 1½°, base out, O. U. for constant use. Local applications for catarrh.	18′ abd. 3° add. 30°.	Under observation ten months. After wearing prisms a short time tried to leave them off for a day, but had headache with nausea, which was instantly relieved by putting on prisms At end of ten months could read by daylight but not much in evening. Relief was great.
24 Ext.	M.	25	Medical Student.	Been reading late at night. Sight gives out suddenly after long reading, so that he fails to recognize a person across lecture room. No trouble until a month ago.	O D. + 0 75s. V. = 18-15. O. S. + 0.75s. ⌒ + 0.50c. 180°. V. = 18-20.	18′ abd. 1½° add 15° v. d. 2° conv.; 13″ abd. 18° add. 15 v. d ⚟.	O. D. + 0.50s. ⌒ prism 2°, base out; O. S. + 1c 180° ⌒ prism 2°, base out; for constant use.	18′ abd. 1° add. 21° v. d ⚟; 13″ abd. 16° add 19° v. d ⚟.	Under observation one and one-half years. Complete relief with prisms. Unable to go without them.
25 Ext.	M.	27	Peddler.	Pain in eyes for ten years. Inability to read long. Nasal catarrh.	E.	18′ abd. 4° add 17° (?); 13″ abd. 20° add. 15° v. d. 7° div.	Prism 1½°, base out, O. U. for constant use.	18′ abd. 1½° add. 25° v d 2° conv.; 13″ abd 10° add. 38° v. d. 1° conv.	Under observation four months. Little or no relief from prisms, but they demonstrate the true nature of the trouble. Tenotomy advised.
26 Ext.	M.	34	Merchant.	Troubled with eyes for fourteen years. Unable to read in evening. Conjunctivitis. Nasal catarrh.	E.	18′ abd. 3° add. 7½°; 13″ abd. 15° add. 20° v. d. 8° div.	Prism 1½°, base out, O. U. for constant use.	18′ abd. 2° add. 14°.	Under observation six months. Condition greatly improved, but not entire relief. Able to read several hours. Had tried + 1 D. for reading without benefit. Has slight vertical error, but was relieved without taking this into consideration.

27 Ext.	F.	16	Schoolgirl.	Aching and fatigue of eyes for eight months. Eyes usually feel very tired. Is studying hard and is anaemic. Spasm A. General health poor.	O. D. — 1.c 180°. V. = 1. O. S. E.	18′ abd. 3° add. 12° v d. ⚟; 13″ abd. 20° add. 30° v. d. 5° div.	After trying rest, tonics and atropia for a month, ordered prism 2°, base out, O. U. for constant use.	18′ abd. 3° + add. 20°+; 13″ abd. 18° add. 40° v. d. ⚟.	Under observation three months. Unable to wear prisms with comfort. Often relieved by removing them. General condition poor.
28 Ext.	F.	23	Music Teacher.	Unable to use eyes in evening; they feel strained and "crazy." Difficulty in keeping eyes open in evening. Is "miserable" the next day after going to opera. Conj. and bleph. severe.	O. U. + 1 D. V.=1.	18′ abd. 3° add. 15° v. d. 4° conv.; 13″ abd. 8° add 15° v. d. 1° div	Prism 1½°, base out, O. U. for constant use.	After 3 months: 18′ abd. 3½° add. 21° v d 2½° conv; 13″ abd. 5° add 25° v. d. 4° conv.	Under observation six months. Able to read one and one-half hours in evening. Comfortable with glasses and unable to go without them. Bleph. cured.
29 Ext.	M	21	Medical Student.	Burning pain in eyes and blurring of print after reading a few minutes. Almost constant headache.	E.	18′ abd. 3° add. 9° v d ⚟; 13″ abd. 15° add. 15° v. d. ⚟.	Prism 1½°, base out, O. U. for constant use, with + 1 D in addition for reading.	18′ abd. 1° add. 13° v. d. ⚟; 13″ abd. 13° add. 20° v. d. 3° conv.	Under observation three months. Able to study three or four hours daily. Cannot go without glasses.
30 Gen.	M.	38	Retired Merchant.	Case of general prostration from too close application to business. Unable to use eyes more than a few minutes at a time. Pain in back of head and neck. Pain extends to arm and leg on mental application or use of eyes. Eyes tire in looking at pictures, etc. Difficulty in looking at moving objects. Closes eyes on Broadway and gets relief.	E.	18′ abd. 4½° add. 15° v d 3° conv.; 13″ abd. 18° add. 28° v. d. 3° conv.	Prism 1°, base out, O. U. for constant use; later prisms of 1½°, and still later + 0.75s. O. U. in addition for reading.	18′ abd 4° add. 22° v. d 3° conv.; 13″ abd. 10° add. 14° v. d. 3° conv.	Under observation nearly two and one-half years. Gets a certain amount of relief from glasses. Can read paper ten minutes at a time and can attend to personal business. Has had the best advice for general condition, and the slight improvement in eyes seems due to general improvement.
31 Ext	F.	26	.....	Eyes ache and she has "dreadful" headaches when she reads or sews. Conj. Slight spasm A. Very nervous woman. Trouble for two or three years.	E.	18′ abd. 5° (?) add. 17° v. d. ⚟; 13″ abd. 12° add. 30° v. d. ⚟.	Prism 1½°, base out, O. U. for constant use.	18′ abd. 3° add. 17°; 13″ abd. 8° add. 23°.	Under observation one year. Prisms relieved headache almost completely from the very first. Much less conjunctival irritation. Patient in much better spirits and very thankful for prisms.

APPENDIX.—CONTINUED.

No. Muscles.	Sex.	Age.	Occupation.	History and Symptoms.	Refraction.	Musc. Condition (Primary).	Treatment.	Musc. Condition (Ultimate).	Results and Remarks.
32 Ext.	F.	16	Schoolgirl.	Has been studying hard to obtain first place in class. Trouble with eyes for three or four months. Pain in eyes and fatigue. Photophobia. Slight spasm A. Eyes often feel tremulous Slight twitch at outer angles.	E.	18′ abd. 5° add. 35°; 13″ abd. 18° add. 45° + v. d. 8° conv.	Rest of eyes, no glasses. At end of year condition about the same, although eyes had been used in moderation. Ordered prism 1½°, base out, O. U. for constant use.	18′ abd. 5° (?) add. 45°; 13″ abd 12° add. 50° + v. d. 1° conv.	Under observation one year. Two weeks after putting on prisms reported herself much relieved. Had been able to use her eyes ad libitum without pain in studying for college examinations.
33 Ext.	F.	17	Schoolgirl.	More or less trouble for six months. Conjunctivitis. Hard to keep eyes open. In reading apt to lose the place if she lifts eyes from book. Can not embroider. Health good. Light hurts eyes.	E.	18′ abd. 4° add. 22°; 13″ abd. 16° add. 30° + v. d. 6° conv.	Prism 1½°, base out, O. U. for constant use.	18′ abd. 5° + add. 20°; 13″ abd. 11° add. 25° v. d. 7° conv.	Under observation four months. Used glasses with comfort for two months She then had pain in eyes and was unable to use them. Later had headache, but this stopped on leaving school.
34 Ext.	F.	15	.....	Has follicular conjunctivitis. Reading irritates eyes. Is made tired by prism tests. Lids have been treated for several months. Subject to headache.	E.	18′ abd. 3° add. 20°; 13″ abd. 10° add. 35° v. d. 4° conv.	Treatment of lids. Prism 1½°, base out, O. U. for constant use.	18′ abd. 4° add. 23° v d. ≏; 13″ abd 5° add. 40° v. d. 7° conv.	Under observation nine months. Wore prisms three months without benefit. Conjunctivitis persists. Headache rather worse.
35 Ext.	M.	48	Manager.	Severe vertigo. Pain in head. Creeping sensations for two weeks. Melancholia. Forgetfulness. Sugar in urine. Powerful physique.	O. U. + 1 D. V.=1.+	18′ abd. 5° add. 25° v. d. ≏; 13″ abd 25° add. 35° v. d. 10° conv.	O. U. + 1 D. ⌒ prism 1½°, base out, distance; O. U. + 3 D. ⌒ prism 2°, base out, for reading. Spherical correction later increased to + 4 D. O. U.	18′ abd. 3° v. d. 3° conv.	Under observation for nearly three years. At end of first month said he would not take a million dollars for his glasses. Relief was prompt and not dependent on improvement in general condition. At end of two years said he had "lots of fun" with his eyes. He shortly after this had another break-down from anxiety due to business reverses and death of brother. He had much pain in head, sugar reappeared in urine, and he was unable to read at all. Reading glasses were slightly increased in strength. Subsequently regained eye power. Brother had weak externi.

36 Ext.	M.	28	Physician.	Pain in O. S., a "real ache." Unable to use eyes with com fort Powerful man. Picture of health.	O. D. +3.s. ⌒ + 0.75c. 75°. V.=1. O. S. + 3.s. ⌒ + 0.75c. 120°. V =20-20.	18′ abd. 5° + add. 33° v. d. ≏; 13″ abd. 20° add 50° v. d. 3° conv.	Prism 2°, base out, O U. with correction of refractive error.	18′ abd. 2° add. 15° — 20°.	Under observation one and one-half years. Complete relief. Able to use eyes as much as he wished. Brother of preceding case.
37 Ext	F.	27	.....	Trouble with eyes for two years. No pain or headache, but unable to read more than a few minutes. Under treatment for uterine trouble.	E.	18′ abd 3° add. 15°; 13″ abd. 18° add. 20° v. d. 2° div.	Prism 1°, base out, O. U. for constant use. Dyer.	18′ abd. 4° add. 17°; 13″ abd. 13° add. 25°.	Under observation one month. Thought glasses were of some assistance in reading. Could read with them from twenty to thirty minutes.
38 Ext	M.	21	Clerk.	Irritation of lids for ten months. Trouble in study or work. Chronic conj. and bleph. marg. which is hereditary.	E.	18′ abd. 4° (?) add 22°+; 13″ abd. 16° add. 28° v. d. 5° conv.	Prism 1½°, base out, O. U. for constant use.	18′ abd 4° add. 13° v. d. ≏; 13″ abd. 16° add. 15° v d. 5° div. Prisms not decidedly indicated and failed.	Under observation four months. Wore prisms only a few times and they seemed to make head ache.
39 Ext.	M.	35	Merchant.	Tired feeling in eyes. Reading has become a burden. Has had considerable anxiety. Obliged to discriminate carefully between colors in his business Trouble of recent date. Patient rather overworked and worried. Eyes tire on cars, etc.	E.	18′ abd. 3½° add. 9°; 13″ abd. 18° add. 17°.	O. U + 1-60s. ⌒ prism 1½°, base out, O. U for reading. Two years later increased spherical glass to + 0 75s and prism to 2°, O. U. for reading and to use old ones for distance.	18′ abd. 4° add. 15° v. d ≏; 13″ abd 12° add. 18° v. d. 5° conv.	Under observation three and one-half years. Prisms gave great relief although eyes were severely taxed.
40 Int.	M.	26	Medical Student.	Trouble for two years. Pain in lids, not in eyes, in reading, etc.	E.	18′ abd. 5° add 5° v. d. ≏; 13″ abd. 23° add. 8° v. d. 6½° div.	Prism 2° base in, O. U. for constant use.	18′ abd. 9° add. 13° v. d. ≏; 13″ abd. 35° add. 15°.	Under observation fourteen mos. Wore glasses for over a year with perfect comfort. At the end of that time eyes became a little fatigued from over-work, preparing for examination for degree.
41 Int.	F.	16	Schoolgirl.	Trouble with eyes for a year following excessive use of eyes while confined to bed with injured foot. Spasm A. Able to read a short time only. No headache. Nasal catarrh	E.	18′ abd. 7° add. 13° v. d. ≏; 13″ abd. 12° add. 10° v. d. ≏. Image O. D. ½° lower than that of left.	Atrop., gr. iv ad oz. i, followed by O. D. Prism 2°, base in; O. S. Prism 1°, base in. She had already worn above. Later increased O. S. to 2°.	18′ abd 11° add. 16° v. d. 1° conv; 13″ abd 18° add. 22°.	Under observation two and one-half years. Able to use eyes seven or eight hours a day, instead of one-half hour as formerly. Occasionally goes without her prisms, but generally wears them constantly. Perfectly comfortable with them.

APPENDIX.—CONTINUED.

No. Muscles.	Sex.	Age.	Occupation.	History and Symptoms.	Refraction.	Musc. Condition (Primary).	Treatment.	Musc. Condition (Ultimate).	Results and Remarks.
42 Int.	M.	43	Physician.	Weak constitution. Not much physical stamina. Has large practice and is overworked. About fifteen years ago overtaxed eyes and they gradually gave out. No trouble before that time. Unable to read over fifteen minutes without great distress, and is obliged to wear prisms of from 2° to 7°, bases in. Does not sleep well. Difficulty in looking from one object to another. Diagnosis of weak interni made years ago by Dr. Dyer. Eyes twitch at outer angles Headaches during the last year only.	O. U. + 0.75s. V.=1.	18′ abd. 3° add. 3° v. d. 3° div.; 13″ abd. 15° add. 0° v. d. 15° div.	Has had tonics, electricity, and prisms. O. U. + 1-60 ⌒ prism 1½°, base out, for distance; O. U. + 1-12s ⌒ prism 6°, base in, for reading. To use gymnastic prisms.	18′ abd. 4½° add. 8°; 18′ + 1-60s. add.=15°.	Under observation eight months. Habitually uses but one eye in reading, either one. Case of general muscular weakness. Marked neurasthenia. Had consulted various oculists. Operation suggested. Case of breakdown from too intense application in a person with neurotic tendencies.
43 Ext.	F.	27	Seamstress.	Some conj. Pain in eyes in a warm room. Under some nervous excitement—mental worry—for six months. Headache all the time. Supra-orbital tenderness.	E.	18′ abd. 1½° abd. 17°; 13″ abd. 18° add. 20°.	Prism 2°, base out, O. U. for constant use. Later reduced prisms to 1°.	18′ abd. 3° add. 20° v. d. 2° conv.; 13″ abd. 8° add. 33° v. d. 5° conv.	Under observation three months. Little benefit from prisms. Tenotomy indicated. The causes of nervous tension and worry continue. Is much perturbed. Eye treatment of doubtful value.
44 Ext	M.	30	Medical Student.	O. U. Amblyopia from corneal opacities. Unable to use eyes with comfort.	O. D. + 0.5s. V. = 0.6 —. O. S. + 0.75s. V. = 0.4.	18′ abd. 1½° add. 24° v d 8° conv; 13″ abd 7½° add. 48° v. d. 9° conv.	O. U. + 1 D. ⌒ prism 2°, base out, for constant use.	18′ abd. ½° add. 24° + v. d 12° conv; 13″ abd. 7° add. 23° v. d. 10° conv.	Under treatment nearly two years. Has been able to use eyes fifteen hours a day at times with comfort. Had previously tried spherical glasses without much benefit. Relief very marked in spite of amblyopea.
45 Ext.	F.	17	Schoolgirl.	Has for several months had headache after use of eyes. Movement outwards of eyes jerky. Operation on O. S. for strab. conv. eleven years ago. Central scotoma O. S.	O. D. + 1 c 180° V. = 1. O. S. + 1 c. 180°. V. = 0.1.	No binocular vision.	Prism 3°, base out, O. U. for constant use.	.....	Under observation six months. Entirely relieved by prisms. Able to do full work in school without pain. Case of special interest on account of monoc. amblyopia.

46 Ext.	F.	16	Schoolgirl.	More or less headache for two years. Recently more pain in eyes and head. Strong and healthy.	E.	18′ abd. 3° add. 14° v. d. 2° conv.; 13″ abd. 13° add. 20° v.d. ⚖.	Rest and tonics. Three weeks later, prism 1½°, base out, O. U. for constant use.	18′ abd. 3° add. 15°; 13″ abd 7° add. 20° v. d. 6° conv. At one time after wearing prisms abd. at 18′ sank to — 1°.	Under observation four months. Partial relief from rest. With prisms able to use eyes four or five hours a day. Unable to read without them or even to walk without them. No headache.
47 Ext.	F.	15	Schoolgirl.	Eyes have given trouble for a year. Eyes ache after reading fifteen minutes, and headache follows if she continues to read. Has headache when tired, but with the headache following bodily fatigue she does not have the pain in eyes which follows reading. Under treatment for slight lateral curvature of spine. Has been too closely confined to her studies.	O.U. + 1. D. V. = 1.	18′ abd 5° add. 27° +; 13″ abd. 15° add. 30° v. d. 4° conv.	Prism 1°, base out, O. U. for constant use, later for near work only.	18′ abd. 7° + add. 39° v. d ⚖; 13″ abd. 16° add. 36° v. d. ⚖.	Under observation twenty months. No headache, no trouble of any kind. Has been relieved from pressure of all kinds, been much more in open air and gained fifteen pounds. Part of the relief undoubtedly due to improvement in general health, but prisms gave relief immediately. Prisms to be abandoned, first for distance, later for near work.
48 Int.	M.	33	Commercial Traveler.	Pain in eyes in reading. Print unsteady. Has read much on cars. Much conjunctival irritation.	O. D. + 0.50c. 75°. V.=1. O. S. + 0.50c. 105°. V. = 1.	18′ abd. 8° add. 7°; 13″ abd. 28° add. 15° v. d. 13° div.	Prism 1½°, base in, O. U. combined with cyl. correction for constant use.	18′ abd. 9° add. 10° v.d. 4° + div.; 13″ abd. 20° add. 15° v. d. 8° div.	Under observation three years. Glasses gave almost complete relief for a year. Conj. irritation greatly diminished. At end of three years old trouble returned and he had pain in eyes after fifteen or twenty minutes use. Tenotomy advised.
49 Ext.	M.	13	Schoolboy.	Trouble for six months. Blurring of print after reading a few minutes, passing off with rest. No pain or headache.	O. U. + 0.75s. V. = 1.	18′ abd. 3° add. 10°; 13″ abd. 12° abd. 23° v. d. ⚖. Same result with and without + 0.75s.	At first ordered + 0.75s O. U., but their use in reading gave rise to pain behind ears. Then ordered prism 2°, base out, O. U., for constant use.	18′ abd. 5° add. 27°.	Under observation three months. Wore prisms all the time and did not like to be without them. No trouble in school.
50 Ext.	M.	19	Student.	Occasional diplopia. Occasional migraine. Inclines head toward left shoulder. Some headache, *i. e.*, pain at inner angles. Able to read one and one-half hours. Some vertigo.	O. U. + 0.50s. V. = 1.	18′ abd. 4° (?) add. 36°. Images vibrate. 13″ add. 11° add. 46° v. d. 7° conv.	Prism 1½°, base out, O. U., for constant use.	18′ abd. 5° add. 45° + v. d. ⚖; v. d. l. conv. 4°; 13″ abd. 3° to 0° add. 45° + v. d. 8° conv.	Under observation two months. Able to use eyes three hours a day, one hour at a time. Rather less headache and vertigo. Advised tenotomy.

APPENDIX.—CONTINUED.

No. Muscles.	Sex.	Age.	Occupation.	History and Symptoms.	Refraction.	Musc. Condition. (Primary.)	Treatment.	Musc. Condition. (Ultimate.)	Results and Remarks.
51 Ext. and Int	F.	28	Teacher.	Naturally nervous. All her family have trouble with eyes. As a schoolgirl always had sick headache after writing. Has a "horror" of sitting down to write a letter. Never able to read over one-half hour without pain, and writing always followed by "frightful" headache. Binocular vision not constant. Vertical error of 1½°. Has had for over a year carefully fitted cylindric correction with little relief. Goes home from school daily perfectly exhausted.	O. D. + 0 25s. ⌒+0 75c 90°. V.=1. O. S. — 0.50s ⌒ + 1.50c. 90° V. =1.	18′ abd 5° — add. 7° v. d 1½° conv.; 13″ abd. 12° add. — 10° v. d. 5° div. 18′ vert. error ▽ 1½° O. D.	Her correction with O. D prism 1°, base up. O. S. prism 2°, base out.	After six weeks: 18′ abd. 4° – add. 27°; 13″ abd. 18° add. 30° v. d. 3° conv.	Under observation four and one-half months. "Is tied to glasses," and miserable without them. Went to church sociable without them and had "terrific" headache all next day. With glasses has no headache and is able to read and sew all day and evening and to use eyes as she pleases.
52 Ext.		20	.....	Headache for two years, now almost daily. Often has vertigo. Difficulty in piano playing. Blurring of sight in looking steadily at objects. Reading increases headache and irritates lids. Some conjunctival irritation. Tonics used without benefit. Eyes twitch at outer angles. Prism tests cause frontal headache. Inclines head to right shoulder. O. S. stands higher than O. D. Eyes ache if she spends day in town shopping.	Under atropine, O U. + 1. V. =1.	18′ abd. 3½° add. 10–15° v. d. ≏; 13″ abd. 16° add. 26° v. d. 4° div.	Prism 1½°, base out, O. U. for constant use.	18′ abd 6° add. 42° v. d 1° conv; 13″ abd. 13° add. 40° v. d. 4° conv.	Under observation six months. Wore prisms constantly for about a month, then for near work only. Able to read an hour fairly well. Improvement in general health. At end of six months had very little headache, whereas formerly it was so severe she was frequently compelled to go to bed.
53 Ext.	M.	13	Schoolboy.	Pain in eyes for three months, even when not reading.	O. U. + 0.50s. V.=1.	18′ abd 3° add. 19° v. d. ≏; 13″ abd. 16½° add. 30° v. d. 1° conv.	Prism 1½°, base out, O. U. for constant use.	18′ abd. 4½° add. 20° v. d. 3° conv.; 13″ abd. 15° add. 30° v. d. 2½° conv.	Under observation one year, wearing glasses all the time without "a bit" of trouble.

54 Ext.	M.	15	Schoolboy.	Reads and practices on piano many hours a day Sometimes has pain in eye-balls. Pain in looking at distant objects. Eyes tire in looking at pictures. Spasm A.	O. U. + 0.75s. V. = 1.	18′ abd. 3° add. 8° v. d. ⚟; 13″ abd. 14° add. 20° v. d. ⚟.	After rest, prism 1½°, base out, O. U. only in reading.	18′ abd. 3° add. 40° v.d. 6° conv.; 13″ abd. 13° add. 25° v. d. 5° conv.	Under observation one and one-half months. Wore prisms for near work only Has had no pain in eyes, but has not been using eyes as much.
55 Ext.	M.	10	Schoolboy.	Under treatment more or less for two years for dyspepsia. Much headache and nausea, particularly on use of eyes. Unable to look at moving objects without nausea. Unable to be in school more than one day in a week for several months on account of headache. Vertigo. Delicate, nervous boy.	E.	18′ abd. 3° add. 10° v. d ⚟; 13″ abd. 15° add. 13° v. d ⚟.	Prism 1½°, base out, O. U. for constant use.	18′ abd. 5° add. 23° v.d. 2° conv.; 13″ abd. 14° add. 25° v. d. 4° conv.	Under observation eight and one-half months. Unable to get along without his prisms. Unable to concentrate mind on lesson for over one-half hour. If crowded beyond this has nausea and headache which last until following day. Has nausea if he leaves off prisms. Headache, nausea, and vertigo decidedly relieved by prisms.
56 Ext.	M.	10	Schoolboy.	Headache, vertigo, nausea, and distress in stomach. Unable to read. It distresses him to bend down to take off shoes. Has worn convex glasses without benefit.	O. D. + 0.75s. V. = 1. O. S. + 1.00s. V. = 1.	18′ abd. 1° — add. 25° v. d. 3° + conv.; 13″ abd. 0° add. 12½° v. d. 1½ conv.	Prism 1½°, base out, O. U. for constant use.	18′ abd. — 2° add. 29° v. d. 3° conv.; 13″ abd. 0° add. 15° v d 8° conv.	Under observation one month. Headache nearly every day, but not quite as severe as formerly. Complained of distress of stomach but once since first seen. Tenotomy advised.
57 Ext.	F.	25	.....	Headaches for a month, attributed to reading too many guide books on a recent European trip. Now unable to read at all without headache. Spasm A.	Under atropine, O. U. + 0.75s. V. = 1.	18′ abd 5° add. 17° v. d. 1° conv.; 13″ abd. 8° add. 40° v. d. 18° conv.	Prism 1½°, base out, O. U. for constant use. In fact wore them interruptedly, always for near work. For distance they were not always comfortable.	18′ abd. 6° add. 27° v. d. 9° conv. (latent); 13″ abd. 8° add. 27° v. d. 12° conv.	Under observation five months. Gradual improvement. Complete relief of headache. Able to use eyes more than two hours a day without fatigue.
58 Ext.	F.	8	.....	Tendency to chorea, and has almost lived on arsenic. Occipital headache, pain extending to neck. Never able to study. If she attempts it is prostrated and has to go to bed. Is a bright, lively child ordinarily, but at times becomes moody, obstinate, and almost stupid. Spasm A. Anaemia. Child nervous and easily frightened.	O. U. — 1 s. V. = 1. under atropine. Slight H.	18′ abd. 5° add. 15° v. d. ⚟; 13″ abd. 10° add. 18° v. d. ⚟.	After atropine, prism 1°, base out, O. U. for constant use, without much expectation that they would be of benefit.	18′ abd. 3½° add. 22°.	Under observation one month. Prisms had no effect one way or the other. Two years later learn that condition has improved. Eyes have no bearing on symptoms.

APPENDIX.—CONTINUED.

No. Muscles.	Sex.	Age.	Occupation.	History and Symptoms.	Refraction.	Musc. Condition (Primary).	Treatment.	Musc. Condition (Ultimate).	Results and Remarks.
59 Ext.	F.	16	Schoolgirl.	Formerly had malarial headaches which yielded to quinine. Now under treatment for slight lateral curvature of spine. Has much headache, coming on after school hours and passing off after being in open air. Some conjunctival irritation. Considerable supra-orbital tenderness. For two months headache has been almost constant. Spasm A. Spasm Interni. Rather delicate.	E.	18′ abd. 4½° add. 25°; 13″ abd. 18° add. 30° v. d. 3° conv.	Prism 1½°, base out, O. U. for constant use.	18′ abd. 4° add. 35°+ v. d. 6° conv.; 13″ abd. 5° — 13° add. 30°+ v. d. 5° conv.	Under observation four months. Complete relief of headache.
60 Ext.	F.	31	.....	Thrown from sleigh two years ago. Sun-stroke one year ago. Much headache. Unable to use eyes in reading. Nervous.	E.	18′ abd. 4° add. 15° v. d. 1° conv.; 13″ abd. 11° add. 20° v. d. 2° conv.	Prism 1°, base out, O. U. for constant use.	18′ abd. 2° add. 20° v. d. 2° conv.; 13″ abd. 6° add. 23° v. d. ∞.	Under observation three months. Greatly relieved by prisms. Able to read an hour or more.
61 Ext.	F.	36	.....	Patient has had malaria and is gouty. She is delicate and nervous. She has had the best medical care and has had various glasses without relief. Feels completely unstrung and discouraged. Spasm A.	After atropine, O. D + 0.75c. 105°. V. = 0.9. O. S. — 0.50s. $\widehat{\ }$ + 1.75c. 80°. V. = 0.9.	18′ abd. 8° add. 15°; 13″ abd. 9° add. 18° v. d. 4° conv.	Glasses correcting refracting error, later with addition of prism 1½°, base out, O. U.	18′ abd. 6° add. 20° v. d. 2° conv.; 13″ abd. 4° v d. tendency to divergence.	Under observation six months. Both cylindric and cylindro-prismatic glasses unsatisfactory. Before wearing them was not subject to headache. Since using them has had much occipital headache whether using them or not. Only comfortable when not using eyes, although cylindro-prismatic glasses are restful at evening and she can't play cards without them.
62 Ext.	F.	36	.....	Head feels tired if she watches people while driving in Park, and she has vertigo so severe on first getting out of carriage that for a minute she can hardly stand.	O. D. + 0.75s. V. = 0.8. O. S. — 0.75s. V. = 0.5.	18′ abd. 3° add. (?) v. d. 2° conv; 13″ abd. 10° add. (?) v. d 5° conv.	Prism 1½°, base out, O. U. for constant use. Later added — 0.50s. to O. S., which was afterwards reduced to —0.25s.	....	Under observation one year. Prisms alone gave rise to diplopia, which was relieved by spherical correction added to O. S., and glasses were then worn with comfort.

63 Ext.	M.	19	Student.	Dull headache most of time. Has nasal catarrh, conjunctivitis, and malaria. Trouble in reading in evening, and much pain in eyes after reading an hour or two at any time.	Under atropine, O. U. + 0.75s. V. = 1.	18′ abd. 5° add. 20° v. d 2° conv.; 13″ abd. 18-10° add. 20° v. d. 2° conv.	Prism 1½°, base out, O. U. for constant use, later +0.75s. O.U. added. Glasses in both cases used constantly. Careful attention to general health, lids and nose.	18′ abd. 3° add. (?) v. d 2° conv.; 13″ abd. 12°-15° add. 15° (?) v. d. 1° conv.	Under observation one year. Glasses relieved the headache, and the relief was evidently due to the glasses rather than to any other line of treatment, for on going without them for a few days he again had severe headache.
64 Int.	M.	13	Schoolboy.	Headache almost every day; often wakes with it. Has had chorea and still has some twitching of eyes.	E.	18′ abd. 7° add. 15° v. d. 2° div.; 13″ abd. 18° add. 12° v. d. 7° div.	Prism 1½°, base in, O. U. for constant use. Fowler's Solution.	18′ abd. 7° add. 22° v. d. 3° div.; 13″ abd. 18° add. 20°.	Under observation seven months. Glasses gave immediate and almost complete relief from headache, so that after a few weeks he was allowed to go without them except in reading. At end of seven months did not need them. No headache.
65 Ext.	M.	31	Merchant.	Had palp. conj. every summer for twelve years, especially in O. S. At other times is quite well and can use eyes perfectly.	O D. + 0.75s. V. = 1. O. S. E. V. = 1.	18′ abd. 3° add. 28° + v. d. 3° conv.; 13 abd 20° add. 45° v. d. 4° conv.	Been treated by astringents and local medication with little benefit. Has tried +60 for reading, without benefit. To have prism 2°, base out, O. U. for near work and use Boric Acid for lids.	18′ abd. 4° add 20°.	Under observation six years. Use of prisms one summer made him comfortable. The next year eyes were much better and he seldom used glasses. Since then, 1885, has not used glasses at all.
66 Ext.	M.	60	Restaurant Keeper.	"Weakness of sight," particularly after shooting. Distressed by looking out of car windows. Tremor of eyes at outer angles. Photophobia. Some slight conjunctival irritation. Fine vitreous opacities not impairing vision seriously.	O. U. + 1.25s. V. = 1.	18′ abd. 5° add. 30° v. d. ⚟; 13″ abd. 20°-5° add. 60° v. d. ⚟.	Prism 1½°, base out, O. U. for constant use; later, weak convex glasses substituted.	18′ abd. 5° add. 44° v. d. ⚟; 13″ abd. — 18°-15° add. 60° + v. d. 15° conv. With +3 D O. U., 18′ abd. 23° add. (?) v. d. 3° conv.	Under observation six weeks. No improvement except from the rest.

APPENDIX.—CONTINUED.

No. Muscles.	Sex.	Age.	Occupation.	History and Symptoms.	Refraction.	Musc. Condition (Primary).	Treatment.	Musc. Condition (Ultimate).	Results and Remarks.
67 Ext.	M.	28	Theol. Student.	Has had several pairs of glasses none of which satisfy him. Eyes feel uncomfortable without real pain. Never has discomfort in both eyes at once, usually only in O. D. Spasm A. Excessively nervous.	O. D. + 0.50c. 100°. V. = 1. O S. + 0.50c. 105°. V. = 1.	18′ abd. 7° add. 15° v. d. 2° div.; 13″ abd. 18° add. 20° v. d. 2° conv.	Prism 2°, base out, O. U. with cyl. correction for constant use.	18′ abd. 5° + add. (?); 13″ abd. 10° add (?) v. d. 4° conv.	Under observation nearly two years. Wore cylindro-prismatic glasses for several months with great benefit. He then began to use cylinders alone for distance and used prisms only in reading. Ultimately he used cylinders for all purposes.
68 Ext.	M.	35	Clerk.	For seven or eight years has had severe neuralgic pain in eyes and head. Pain so severe that he usually has to go to bed as soon as he gets home. Never free from pain. Has been under the best medical treatment without relief. Abduction painful. Often has diplopia.	O. D. 0 7—; + 1 D. V. = 1. O. S. 0.5; not improved. O. S. Struck by a piece of wood when he was a boy. No trace of injury visible.	18′ abd. —3° add 20° v. d. 8½° conv; 13″ abd. —7° add. 30° v. d. 24° conv.	Prism 3°, base out, O. U. for constant use.	After 10 days, 18′ abd. — 15° add. 37°; 13″ abd. 13° add. (?).	Under observation two and one-half years, but no examination made after first ten days. Tenotomy urgently advised, but he has been unable to leave his business. He drags along and leads a wretched existence. He can't get along without his prisms, but they are entirely inadequate, as was to be expected.
69 Ext.	M.	47	Banker.	Much severe headache for two months, coming on at all hours of day; often wakes with it. Pain is through temples Prism tests bring on the headache. Prefers to ride backward in cars. Is a large man and takes little exercise. No diplopia. Is a confirmed dyspeptic and gouty.	O. U. + 1.75s. V. = 1.	18′ abd. 3° add. 35° v. d. 2° conv; 13″ abd. (?) add. (?) v. d. 5° conv.; 13″ without glasses (+1.25s.) v. d 10° conv.	O. U. + 1.75s. ⊂ prism 2°, base out, for reading. To use his glasses, +1.25s O.U. for distance.	18′ abd. 3° — add. 27° v. d. 3° conv.; 13″ abd. (?) add. (?) v. d. 5° conv.	Under observation five months. Has very little headache, but thinks relief is due to antipyrin which he began to use shortly after first visit because the headache continued after wearing glasses. Still he is very dependent on his glasses and feels that they help him. Is unable to watch a public speaker without them, and is unable to look at the minister through a whole sermon even with them. Finally gave up prisms.
70 Ext.	M.	16	Student.	More or less trouble for four years, unrelieved by weak glasses. Sometimes has pain in eyes in looking at distant objects, but chiefly in reading.	E.	18′ abd. 2° — add. 30° v d. 4° conv.; 13″ abd 6½° add. 35° + v. d. 10° conv.	Prism 1½°, base out, O. U. for constant use.	18′ abd. 3° add. 35° + v. d. 10° conv.; 13″ abd. (?) add. (?) v. d. 23° conv.	Under observation three months. Much more comfortable with prisms, which he enjoyed and did not like to leave off. Tenotomy advised.

71 Ext.	M.	32	Dentist.	Blurring of objects and print. If very tired has diplopia Slight trouble two or three years but not much until last few months. Never has headache.	E.	18′ abd. 3°—add. 23° v d. 8° conv.; 13″ abd. 11° add. 20° v. d. 7° conv.	Prism 2°, base out, O. U. for constant use.	After 1 week, 18′ abd. 0° add. 30° v. d. 8° conv.	Seen one and one-half years later. Had been from one oculist to another, and was still worrying along. Tenotomy urgently advised. Nothing to be expected from any other mode of treatment.
72	M.	10	.....	Epileptic convulsions for two and one-half years. Sometimes goes a day or two without having one, but usually has from two to five in a day. Under best medical treatment. Has distinct aura. Right side more affected than left. Some frontal headache.	Nearly E. Spasm A.	18′ abd. 5° add. 15°; 13″ abd. 10° add. 25° v. d. 7½° conv. Vert error Δ 1½° O. D.	O. D. prism 2°, base out. O. S. prism 1½°, base up.	18′ abd. 5° add. 21° v. d. ½° conv.; 13″ abd. 16° add. 17° v. d. 5° conv. Vert. error only ½°.	Under observation nine weeks. Wore glasses faithfully for one month without appreciable benefit Has attacks at least every other day.
73 Ext.	F.	48	Married.	Had strabismus in early life, but eyes "suddenly" came into correct position without operation. Can be made to see double images only momentarily, and prism tests show central blind spot O. D. For four years has had some headache following epileptiform attacks. Some illness ("brain fever") two years ago. Has headache after a Park drive.	O. D. Amblyopia. O. S. E.	Undetermined on account of monocular amblyopia.	O. U. prism 1°, base out, for constant use, followed one week later by O. D. prism 3°, base out. O. S. prism 1°, base out.	18′ v. d. 11° conv. She learned to recognize double images momentarily.	Under observation three months. No headache. Comfortable with prisms, and misses them if she leaves them off. Epileptic attacks have occurred, but have never been frequent.
74 Ext.	.	30	.....	Burning pain in eyes and headache for a week, due to excessive use of eyes in China painting. Not subject to headache, but reading the paper will now provoke it. Considerable conjunctival irritation. Health not very good; is depressed on account of serious illness of a very dear friend.	O. U. + 0.50c. 90°. V. = 1.	18′ abd. 3° add. 12° v. d. 1° conv.; 13″ abd 20° add. 20° v. d. 3° div.	O. U. +0.50c. 90° ⌒ prism 1°, base out, for constant use. Strych. Sulph.	18′ abd. 5° add 20° v. d. ⚟; 13″ abd. 18° add. 25° v. d. ⚟.	Under observation eight and one-half months. Headache much abated Health better. Can use eyes moderately.
75 Ext.	M	20	Clerk.	Eyes tire quickly and print becomes blurred. After reading fifteen or twenty minutes lays aside book and doesn't feel like going on, although he has no real pain. Slight conjunctival irritation. Some nasal catarrh, benefited by treatment.	E.	18′ abd. 5° add. 15° v. d. ⚟; 13″ abd. 10° add. 15° v. d. ⚟.	Prism 1½°, base out, O. U. for constant use.	18′ abd. 3° add. 27° + v. d. 2° conv.; 13″ abd. 15° add. 28° v. d. 5° conv.	Under observation one month. With prisms works easily, both by day and night. Eyes do not become tired. No blurring of print. Very little irritation of lids unless provoked by smoke, etc.

APPENDIX.—CONTINUED.

No. Muscles.	Sex.	Age.	Occupation.	History and Symptoms.	Refraction.	Musc. Condition (Primary).	Treatment.	Musc. Condition (Ultimate).	Results and Remarks.
76 Ext.	M.	14	Schoolboy.	Trouble for six months. Unable to read over one-half hour with comfort. Eyes feel sore and painful, print becomes blurred, and frontal headache follows use of eyes. Follicular conjunctivitis.	O. D. + 0.75s. V. = 1. O. S. E.	18′ abd 5° add. 13° v. d. ≏; 13″ abd. 11° add. 16° v. d. 2° div.	Tannin and Glycerine locally. Prism 1½°, base out, O. U. for constant use.	18′ abd. 4°–5° add. 29° v. d. ≏; 13″ abd. 6°–10° add. 30°–35° v. d. 3°–7° conv. Shortly before this abd. at 18′ was only 3½° and at 13″ 6°.	Under observation two years. Pain in eyes and frontal headache continued for about six months with only slight improvement. From one to three headaches a week, coming on after reading. Tenotomy was advised, but when he came a month later, expecting an operation, it was deferred on account of the improved muscular condition, the absence of pain and headache, and the marked subsidence of the conjunctival trouble. Continues to wear glasses.
77 Ext.	M.	23	Medical Student.	Weariness of eyes in reading. Sense of strain in looking out of car windows.	O. U. + 0 50c. 90°. V. = 1. Under atropine.	18′ abd. 4° add. 17° v d. 2° conv.; 13″ abd. 15° add. 20° v. d. 3° div.	Prism 1½°, base out, O. U. to be worn constantly in connection with +0 75c, 90° O. U. which he had been wearing without relief.	18′ abd 2½° add 24° + v. d 4° conv.; 13″ abd 13° add 36° v. d. 2° conv.	Under observation five months. Sense of strain greatly diminished by supplementary prisms. Reported that he could read twelve hours a day.
78 Ext.	M.	19	Student.	Complains that eyes always feel tired after using blow-pipe in laboratory.	E.	18′ abd. 5° add 22° + v. d. 2° conv.; 13″ abd. 13° add. 25° v.d. 12° conv.	Prism 2°, base out, O. U. for near work.	....	Under observation five weeks. Uses prisms in blow-pipe work and gets along very well. Relief permanent.
79 Ext.	M.	30	Book-keeper.	Trouble for eight or nine months. Pain in eyes whenever he uses them. Moderate conjunctival irritation.	E.	18′ abd. 4° add. 7° v. d. ≏; 13″ abd 12½° add. 8° v. d. ≏.	Prism 1½°, base out, O. U. for constant use.	18′ abd. 2°–3° add. 14° v d. 3° conv.; 13″ abd. 10° add. 20° v. d. 3° conv	Under observation fifteen months, at the end of which time he could read two hours without much trouble. Has given up book-keeping and is more out of doors. The case was at first thought to be one of weak interni, and prisms were ordered with bases in. By mistake prisms were set with bases out, with result above mentioned.

80 Ext	M	13	Schoolboy.	Frontal headache and sometimes pain in eyes in reading. Often wakes with headache, and reading one-half hour will bring it on. Conjunctival irritation.	E.	18′ abd. 5° add. 21° v. d. 2° conv; 13″ abd. 20° add. 20° v. d. 7° conv.	Prism 1½°, base out, O. U. to be used constantly temporarily.	.....	Under observation ten days. Wore prisms eight days, found headache cured. Attempted to go without them, and headache returned. Relief known to be permanent.
81 Ext.	F.	42	Married.	Very poor health for four years, following attack of nervous prostration. Uterine trouble. Until recently has been able with care to read three or four hours a day, but read too long a few weeks ago and has been unable to use eyes much since. Has suitable convex glasses for distance and near work. Four years ago began to have "terrible" headaches which persisted for two years. After the "real cure" there was relief for a year, but for the past year the headaches have occurred with the old frequency and severity. Riding in Park fatiguing. Photophobia. Insomnia.	O. U. + 0.75s. V. = 1.	18′ abd. 4° add. 20° v. d. ≏; 13″ abd. 15° add. 32° v. d. 4° conv. After 10 days. 18′ abd. 4° add. 20° v d. 4° conv.; 13″, no glasses. abd 20° add. 23° v. d. 7° conv.; 13″ and +1 75s. O. U. abd. 23° add. 18° v. d. ≏.	O. U. +0.50s. ⌒ prism 1½°, base out, for constant use. Later + 1.50s. ⌒ prism 1½°, base out, for reading.	18′ gl. v. d. 2° conv; 13″ gl. v. d. 8° conv.	Under observation four months. Much less headache. Rest has been of benefit. Health somewhat better. Finds that prisms give much relief for distance, but not for near work.
82 Ext.	F.	15	Schoolgirl.	Subject to sick headache as long as she can remember; during past year has had about one a week. Almost constant dull headache for three weeks. Eyes feel crossed in near work, but she persists in spite of pain.	O. U. + 0.50s. V. = 1.	18′ abd. 3½° add. 27° v. d. 3° conv; 13″ abd. 15° add. 30° v. d. ≏.	Prism 1½°, base out, O. U. for reading.	18′ abd. 3° add. 40° v d. 6° conv.; 13″ abd 15° add. 30° v. d 5° conv.	Under observation five months. Complete relief from pain and headache. Able to do all her school work, besides Christmas fancy work. Tenotomy was advised, but deferred on account of improvement.
83 Ext.	M.	22	U. S. Army Officer.	No trouble until a year ago. During past year eyes have felt tired after reading a few hours. Recently unable to read for any length of time with comfort. A perfect specimen of a man physically. First noticed trouble after target practice.	E.	18′ abd. 5° add. 24° v. d. ≏; 13″ abd. 8° add. 40° + v. d. 7½° conv.	Prism 1½°, base out, O. U. for constant use.	18′ abd. 3½° add. 21° v. d. ≏; 13″ abd. 17° add. 30° v. d. ≏.	Under observation six weeks. Prisms a great relief. Can read two hours, but mechanical drawing is hard for him. Does not like to be without prisms long enough for his morning toilet.

APPENDIX.—CONTINUED.

No. Muscles.	Sex.	Age.	Occupation.	History and Symptoms.	Refraction.	Musc Condition (Primary).	Treatment.	Musc. Condition (Ultimate).	Results and Remarks.
84 Ext.	M.	28	Manager.	Has for three years had so much pain in eyes and head that he could read very little, and has not been able to read at all for six months. Has worn cylindric glasses without relief Rather run down physically. Appetite not good.	O D. — 1. s. ⌒ +2.25c. 90°. V. = 1. O. S. — 0.75s. ⌒ + 2 c. 85°. V. = 1.	18′ abd. 4° add. 22° v. d. 5° conv.; 13″ abd. 12° add. 28° v. d. 12° conv.	Correction of refractive error with prism 2°, base out, O. U. for constant use.	18′ abd. 3° add. 26° v. d. 8° conv.; 13″ abd. 20° add. 34° v. d. 9° conv.	Under observation sixteen months. Can't get along without the prisms, but even with them eyes smart and print blurs, with sense of fatigue. At times perfectly comfortable Feels that glasses are decidedly beneficial.
85 Ext.	M.	35	Medical Student.	Much difficulty in use of eyes for over a year. Lids feel stiff; they twitch and finally close in reading by artificial light.	O. U. + 0.75c. 180°. V. = 1.	18′ abd. 2° add. 13° v. d ≏; 13″ abd. 16½° add. 35° v. d. 1° conv.	Prism 1½°, base out, O. U. for constant use.	18′ abd. 1° add. 19° v. d. 3° conv.; 13″ abd. 10° add. 40° + v. d. 7° conv.	Under observation six months. Can read with prisms for hours. Benefit permanent.
86 Ext.	M.	27	Physician.	Trouble in looking at people passing, moving objects, etc. Objects unsteady and print blurs — letters run together. Eyes become tired in looking at distant objects.	E.	18′ abd. 2½° add. 13° v. d. 3° conv; 13″ abd. 8° add. 38° v. d. ≏.	Prism 1½°, base out, O. U. for constant use.	.....	Under observation for at least twelve months. Perfectly comfortable with prisms, and unable to go without them.
87 Ext.	M.	35	Book-keeper.	Some headache about once a week, and dull headache most of the time. Pain frontal, about eyes. Has been book-keeper for seven years, and works from ten to fourteen hours a day. Was formerly on the western plains and then had headache. Conjunctival irritation.	E.	18′ abd. 5° add. 9° v. d. 1° conv.; 13″ abd. 18° add. 6° v. d. 2° div.	Prism 1½°, base out, O. U. for constant use. Later, +0.75s. additional for desk work.	18′ abd. 4½° add. 15° v. d. 3° conv.; 13″ abd. 6° add. 15° v. d. 4° conv.	Under observation six months. Continues to use eyes excessively. Has very little headache compared with what he formerly had.
88 Ext.	M.	29	Medical Student.	Complains only of blurring of print.	Under atropine, H. = 1 D. V. = 1.	18′ abd. 3° add. 22° v. d. ≏; 13″ abd. 16° add. 25° v. d. ≏.	Prism 1½°, base out, O U. for constant use. Has worn +1-42 s. O. U. without relief.	18′ abd. 4° add 15° v. d. ≏; 13″ abd. 13° add. 23° v. d. ≏.	Under observation four months. Prisms were of great service. Was able to use his eyes all winter as much as he pleased, even in the cramming for final examination.

89 Ext.	M.	12	Schoolboy.	Trouble for six months. Has used + 0.75s. O. U. without relief. Has headache in afternoon. Some nasal catarrh. Slight conjunctival irritation.	O. U. + 1 D. V. = 1.	18′ abd. 2½° add. 25°; 13″ abd 3° add. 30° v. d. 5° conv.	O. U. +1 D. s. ⌒ prism 1½°, base out, for constant use.	18′ abd. ½°–3° add. 44° + v. d. ≏; 13″ abd. 5° add. 38° v. d. 11° conv.	Under observation six months. Wore glasses nearly all the time. Is better with glasses on and has very little headache, but glasses are inadequate. Tenotomy advised.
90 Ext.	F.	21	.....	Unable to use eyes at night for a year. Trouble began after severely taxing eyes in fine painting. Eyes feel strained. Has had + 1.s. for a year without much benefit. Slight conjunctival irritation.	O. D. + 0.50c. 90°. V. = 1 O. S. +0.75c. 90°. V. = 1.	18′ abd 6° add. 12°–17° v. d 1° div.; 13″ abd. 15° add 15° v. d. tendency to div.	O. D. +0.50c 90° ⌒ prism 1°, base out; O. S. + 0 75c 90° ⌒ prism 1°, base out, for constant use After three mos. in reading, etc, only.	18′ abd. 3½° add. 22° v. d. ≏; 13″ abd. 10° add. 23° v. d. 3° conv.	Under observation three months. Strained feeling relieved. Broke glasses at end of three months, and had to go without them for three days. Felt loss of glasses very much the first day, but suffered no inconvenience after that. Allowed to use them in near work only.
91 Ext.	F	16	.....	Trouble for two years. Pain in eyes and inability to read much in evening.	E.	18′ abd. 5° add. 21° v. d. ≏; 13″ abd. 20° add. 30° v. d. 10° conv.	Prism 2°, base out, O. U. for near work.	18′ abd. 6° add. 22° v. d. ≏; 13″ abd. 10° add. 43°.	Under observation four months. Prefers to use glasses in reading, and can do more with them than she could before she had them, but they are not of great service.
92 Ext.	F.	20	Seamstress.	Difficulty in use of eyes for a year. Eyes feel tired. Much pain in eyes and frontal headache. Insufficiency of externi so marked that in the muscular tests there is often convergence with suppression of one image. Pain in eyes often amounts to a real ache and is always worse in evening. Eyes become red and inflamed.	E.	18′ abd. (?) add. (?) v. d 20° conv.; 13″ abd. 15° add. 20° v. d. 18° conv.	Prism 2°, base out, O. U. for constant use.	18′ abd. 0° add. 28° v. d 25° conv; 13″ abd. — 18° add. 23° v d. 18° conv. With red gl. 18′ abd —3° to —9°.	Under observation two weeks. Wore glasses all the time, and had only one headache. Eyes feel much stronger. No pain. Prisms nauseated her at first. Relief probably due to rest, as eyes have not been used much. Tenotomy the only remedy.
93 Ext.	M.	29	Medical Student.	Complains of the inflammation of lids. Diagnosis of weak interni made in another city two years ago Nasal obstruction.	O. U. + 0.50c 90°. V. = 1.	18′ abd. 5° add. 7° v. d. ≏; 13″ abd. 18° add 15° v. d 2½° div.	Prism 2°, base in, O. U. for constant use.	18′ abd. 5° add. 9° v. d. ≏; 13″ abd. 26° add. 12° v. d 7° div.	Under observation three months. Prisms gave relief for two weeks and then failed. Suitable for operation. Probable advancement of interni.

APPENDIX.—CONTINUED.

No. Muscles.	Sex.	Age.	Occupation.	History and Symptoms.	Refraction.	Musc. Condition (Primary).	Treatment.	Musc. Condition (Ultimate).	Results and Remarks.
94 Ext.	M.	18	Bank Clerk.	Trouble for two years. Great difficulty in looking at moving objects, as in playing cards, turning leaves of book. Trouble in piano and violin playing; in the latter the motion of the bow is very annoying. Can not ride forwards in cars and look out of window without great discomfort, but has no trouble in riding backwards. Is much annoyed at table looking at persons opposite. Finds it difficult to keep face in repose looking steadily at anything. Is relieved by pressure on brow and temples, and by clasping hands behind head.	O. D. + 0.50c. 90°. V. = 1. O. S. + 1. c. 90°. V. = 1.	18′ abd. 4° (?) add. 7° v. d ≏; 13″ abd. 18° add 4° v. d. 4° div. Possible vertical error of ½°.	Prism 1½°, base out, O U. for constant use, in combination with correcting cyl. glasses. Also given prisms for gymnastic purposes to increase adduction.	18′ abd. 2° add 50° v. d. ≏; 13″ abd 6½° add. (?) v. d 2° div.	Under observation six months. Unable to get along without his prisms, as he found when he broke them. Is able to do all his work and gets along fairly well. Interni too weak for an operation at first, but their power greatly increased under practice. He may finally come to an operation. Cylinders without prisms did not relieve.
95 Ext.	F.	24	.....	Pain in eyes for three or four years, pretty severe for a year. After ten minutes of reading print blurs and pain comes on. Headache, frontal, temporal, and occipital. As a schoolgirl could not use eyes with comfort. Steady looking at anything painful, and she has to keep eyes closed on cars. Often has to lie down and close eyes to rest them. Has had much care and anxiety, and takes little exercise. Considerable conjunctival irritation. Has worn weak cylinders without relief.	E.	18′ abd. 5° add. 17° v. d ≏; 13″ abd. 13° add. 15° v. d. 3° conv.	Local applications to conjunctiva. Gr. ii Sol. Pilocarpine with Cocaine once a day. After using Pilocarpine two weeks with little or no benefit, prism 1½°, base out, O U. for constant use, and to continue drops as before. Tonics.	18′ abd. 6° add. 25° + v. d. slight conv.; 13″ abd. 10°–15° add 35 + v. d. 5° conv.	Under observation three and one-half months. Able to read nearly one-half hour with prisms. Still has pain in eyes and headache, but less than formerly. The state of health was the main feature. Glasses used tentatively.
96 Ext.	F.	23	Milliner.	Always had more or less pain in head, worse now than ever. Recently had severe pain in eyeballs. Trouble in riding on cars.	O. D. E. O S. Hm. 0.25.	18′ abd. 2° add. 33° v. d 6° conv.; 13″ abd. 3° add. 33° v. d. 11° conv.	Prism 1½°, base out, O. U. for constant use.	18′ abd. 1° — add. 40° v d. 10° conv.	Under observation two weeks. Decidedly better. Has been able to work moderately, and with more comfort. Tenotomy advised.

97 Ext.	M.	32	.....	Three years ago had occasional attacks of what he calls "spasm of eyes," i. e., print became unsteady in reading, and he could see parts of words only. These attacks would be followed by intense headache. He now complains of pain in top of head. Broke down in college.	O. D. +0.25s. ⌒ +0.75c. 75°. V.=1. O. S. +0 50s. ⌒ +0.50c. 105°. V.=1.	Examined by oculist of Baltimore, three years ago.	Three years ago, sphero-cylindric correction as already noted; five months ago same correction with prism 4°, base out, O D.; prism 2½°, base out, O. S.	18′ abd. —6° add. 23°; 13″ abd. —5° add. 25° v. d. 12° conv.	Under observation of former oculist for three years. Since using prisms has had none of the attacks which he formerly had. Suitable for operation.
98 Ext.	F.	83	.....	Pain in eyes and headache after use, for a few weeks. Bright, vigorous, and well-preserved old lady. Reads and writes until eleven o'clock at night Homonymous diplopia in distant vision.	O. D. +1.50s. V.=0.4. O. S. +1.50c. 180°. V.=0.4. Sclerosed lenses.	18′ Homonymous diplopia; 13″ abd. 25° add. 13° v. d. 8° div.	Prism 1½°, base out, O. U. for distance; O. U. +5.0 for reading.	18′ abd. 0° add 12-15° v. d. 3° conv.; 13″ abd. (?) add. 5° v. d. 10° div.	Under observation two weeks. Headache relieved by prisms. No diplopia with prisms.
99 Ext.	F.	20	.....	Pain in eyes; they ache most of the time. Much headache; she often wakes with it. Has been using +0.75s. O. U. in reading, etc., without relief. Brother has weak externi. Some conjunctival irritation.	E.	18′ abd. 4° add. 18° v. d. 1° conv.; 13″ abd. 9° add. 17° v. d. ≏.	Prism 1½°, base out, O. U. for reading.	18′ abd. 4° add. 22° v. d. 1° conv.; 13″ abd 8° add. (?) v. d. 5° conv.	Under observation fifteen months. Great relief. Continues to wear glasses.
100 Ext.	M.	22	Student.	Eyes always feel weak. Often has pain in eyes after using them three or four hours. Conjunctivitis. Nasal catarrh, with obstruction. Has used +0.75s. for reading, without relief. Sister has similar trouble.	O. D. —0.75c. 180°. V.=1. O. S. —0.50c. 180°. V.=1.	18′ abd. 3° add. 18° v. d. ≏; 13″ abd. 17° add. 35° v. d. ≏.	Prism 1½°, base out, O. U. for constant use. Later, prisms combined with concave cylinders for distance, and convex cylinders for reading. Constant use.	18′ abd. 3° add. 24° v. d. 4° conv.; 13″ abd. 13° add. 23° v. d. ≏.	Under observation two years. Prisms gave great relief at once, and enabled him to study eight or ten hours a day, and that before cylinders were added. Nasal obstruction removed *after* symptoms were relieved. At end of two years had no cause to complain of eyes.

DISCUSSION.

DR. R. J. MCKAY, of Wilmington, Del. — I am interested in this subject. I have here a paper which I read a year ago before the Delaware State Medical Society, but before referring to that, I may say that I agree largely with Dr. Noyes in his experience with prisms. I have used them for ten years. One patient has worn them ten years for insufficiency. I have reduced them from 6° to 2°, and he is wearing these with comfort. I cannot find so many cases of emmetropia. In my experience, ametropia far exceeds emmetropia. I never order prisms without correcting whatever refractive error requires attention. I have patients wearing prisms bases out and others with bases in. I have a patient with compound myopic astigmatism wearing prisms with 5° base up and with 3° base in, in combination with her sphero-cylinders of — 8s D⌒D — 67 glass 180°.

Personally, I have been a sufferer from insufficiency, and I am now wearing prisms that I have worn for two and a half years. One degree base in on left eye, one degree base up and in at angle of 45° on the right eye. These are combined with my sphero-cylinders. Until I wore these prisms, I suffered continuous pain in the head. My general condition was poor. It was built up, but I did not get relief until I wore the prisms. I have ordered prisms as high as 8°, never more than that, and have divided this between the two eyes. Above that, I have done partial tenotomy and always with more or less satisfaction. This is a subject that should not be given the go-by. It is highly scientific and important, and the younger members should take hold of it and do good work in the future. I do not order prisms if I can help it, and do not think that because there is insufficiency, prisms should necessarily be ordered. They are not necessary unless there are symptoms of suffering. I shall read a brief résumé of the twenty-one cases included in my paper:

A brief résumé of these twenty-one cases shows two cases, I and II, were slight insufficiencies relieved by wearing correcting glasses, and being exercised with prisms for a few weeks, and taking internal remedies to improve their general health.

Cases III, IV, and VI, are insufficiency of the external recti relieved by correcting glasses and prisms, but case V, with a large amount of insufficiency externi (18° to 20°), required four graduated tenotomies and correcting glasses.

Cases VII and VIII were insufficiency of the interni, and relieved by correcting glasses and prisms, but case IX with 27° of insufficiency of the interni for distance, had a tenotomy done correcting about 20°. Declining further operations, sphero-cylindrical prisms were ordered.

Case X, insufficiency of the superior recti of 27°, was relieved by five graduated tenotomies by Dr. Charles H. Thomas of Philadelphia, Pa., and correcting glasses without prisms.

Cases XI and XII, also insufficiency of the superior recti, were relieved by glasses and prisms.

Cases XIII, XIV, XVI, XVII, XVIII, and XIX, insufficiencies of the superior and internal recti were relieved by correcting glasses and prisms.

Case XV, also insufficiencies of the superior and internal recti, was not relieved by correcting glasses and prisms, until three graduated tenotomies were done.

Case XX, insufficiencies of superior and external recti, was not relieved by correcting glasses and prisms and declined tenotomies.

Case XXI, traumatic in origin, insufficiencies of the superior and external recti were relieved by prisms alone, the insufficiency of the superior recti disappearing.

All these cases I have followed, and only one which wore prisms has turned out unsatisfactorily. I wished to do a tenotomy for her, but she passed from under my hands.

Dr. Thomas R. Pooley, of New York.— I desire to call attention especially to the statement made by Dr. Noyes that he considers headache on waking in the morning as due to muscular asthenopia, and to ask consideration of the claim made by Dr. Greuning, in his article on "The Association of Eye Disease and Disease of the Nose." He claims that headache, on waking in the morning, is never due to muscular or refractive errors, but is caused by a diseased condition of the nose. Hearing him read that paper in the section on opthalmology of the agency, I know that he dwelt forcibly on this point.

Dr. B. Alexander Randall, of Philadelphia.— I have myself long been a sufferer from muscular asthenopia. My headache came on regularly about mid-day during my student life. It still troubles me occasionally, particularly on an extended railroad journey. This set me to thinking about muscular insufficiency, even before I graduated in medicine. In a brief paper that I presented last year, I referred to some of my results in the matter of testing the muscles in a series of cases — the last two hundred from my private practice. My experience has apparently been in conflict with that of Dr. Noyes, in showing that of all cases that come under observation, something over fifty per cent. show what I consider insufficiency of the convergence, always for the near and often for distance. Dr. Theobald adopts the same view, except that he does not consider this pathological, but a normal condition.

As to the other point of forty-five per cent. of emmetropia, I can only say that I have been struck with the exceeding high proportion of emmetropia in New York city.

DR. GEORGE C. HARLAN, of Philadelphia.— Hyperphoria seems to me to deserve more attention than is usually given it, as the effort to overcome it may result in a serious disturbance of the equilibrium of the lateral muscles. I have several cases in which a high degree of exephoria has been relieved by the correction of a comparatively moderate hyperphoria. One patient in particular, an aggravated case, has been so much relieved by a weak vertical prism that he is going on with his work satisfactorily, though he had previously been ordered various prisms and subjected to several tenotomies by another ophthalmic surgeon and myself with very little success.

I have not heard any one speak of the use of the Maddox cylinder in testing the muscles. Since the suggestion of this test I have used it altogether, and can see no reason why it should not supercede all other forms of photometer. It has the advantage over any prism test that you do not have to take into account the varying strength of the muscles. A prism that will be necessary to separate the images at all in one case may in another separate them so widely that one will be lost. With the cylinder you have one image converted into a long streak, which the patient can distinguish at once. The cylinder is set in a slit in a circular metallic disc which is fitted to the lens-holder of the trial frame, and can of course be used in the vertical or horizontal direction without other change than a motion of ninety degrees. The contrast between the images may be made still more striking by placing a strip of red glass behind the cylinder, and the dullest patient can tell their relative position without mistake or delay.

DR. LEWIS H. TAYLOR, of Wilkesbarre, Pa.—I have in my hand a glass cylinder or rod which, mounted to fit the ordinary trial frame, I had prepared after hearing Dr. Maddox's article. I began using the plain glass rod by holding it before the patient's eye, and afterwards I had this made. I have found it very useful in testing the condition of the ocular muscles. As Dr. Harlan has said, there is no difficulty in getting the dullest patient to understand it. I have had some difficulty in using the double prism.

I must confess that my own experience, though not nearly so large as that of Dr. Noyes, has been more in accord with that of Dr. Randall. Frequently having occasion to use prisms for the correction of insufficiency, I find the difficulty more largely in the interni than in the externi. Of course, as Dr. McKay

has said, I never give prisms unless they are necessary. Often the insufficiency will disappear under proper correcting glasses without prisms.

DR. R. J. MCKAY, of Wilmington, Del.—I have had the same experience as Dr. Harlan with the upward swing of the eye. I have corrected that and the lateral insufficiency of the externi has disappeared. I think that in my experience insufficiency of the interni has been greater than any other form.

DR. O. F. WADSWORTH, of Boston.—Probably most of us for many years have given prisms occasionally for vertical as well as for horizontal deviation, but more careful testing of all patients has shown me in the last two or three years that the occasion for using prisms is more frequent than I had before supposed. I agree with Dr. Randall as to the frequency of the condition. In six hundred cases examined within the last two years, which I recently put together, I found that more than one-half showed insufficiency by the tests employed.

I have tried the double prism and have found the difficulty that has been mentioned that patients occasionally unite the images. To avoid this I had a stronger prism made, but found that I could do better by using the ordinary prism and the rotary prism of Dr. Risley in a spectacle frame.

DR. EDWARD JACKSON, of Philadelphia.—I add my testimony in favor of the Maddox rod for testing for muscular insufficiencies, particularly vertical insufficiencies. The double prism comes next to it in value, but if the double prism is only just strong enough to prevent fusion of the images, the patient will often approximate the images upward or downward. The rod avoids any inaccuracy of that kind, and it is a test that any patient can understand, and answer definitely with regard to. There is no tendency to fusion.

With reference to the paper of Dr. Noyes, I was rather surprised at the proportion of cases of insufficiency of the externi. I believe that he afterwards explained that he rather regarded this as occurring only in this special series of cases, and not claiming that 92 % was the general proportion. That is so far from the results that I have obtained that it must be something more than a mere coincidence in this particular series of cases. I should say that insufficiency of the externi constitutes a minority of muscular insufficiencies, except in a certain class of cases — cases of low hyperopia. There are many of these cases, and they frequently, although not always, show before the hyperopia is corrected a tendency to esophoria. This point is so generally understood, it would hardly be worth mentioning if it were not for the other point of the extreme

frequency with which emmetropia was noticed. I cannot help thinking that the two things go together, particularly as Dr. Noyes uses a mydriatic only when there is spasm of the accommodation, and I know no way of certainly determining the presence or absence of spasm of the accommodation except by the use of a mydriatic.

DR. F. W. ABBOT, of Buffalo.—I have found in testing with the cylinder and with the prism that the results do not always agree. One may show a divergence that is corrected by a prism of 7°, while the other requires a prism of 10°. I would ask those who are familiar with the use of these instruments, which they consider the more accurate, the record of the cylinder or that of the prism.

DR. GEORGE C. HARLAN, of Philadelphia.—I should be inclined to trust to the record of the cylinder rather than to that of the prism, as there is less tendency to an effort at fusion.

DR. EDWARD JACKSON, of Philadelphia.—I would agree with Dr. Harlan in placing a higher estimate on the finding of the rod. In making these tests with prisms we are doing something entirely different from measuring the refraction of the eye with lenses. I have a patient wearing a 6° vertical prism which she has worn constantly for 15 months. If she leaves the prism off she soon suffers with extreme headache; but if I give her half a grain of morphia, she can leave off the prism and has no inconvenience, and no tendency to vertical deviation. In another case where there is a much higher tendency to deviation outward, from insufficiency of the interni, three-fourths of a grain of morphia quite abolish it for the time. Where we get certain results with prisms we are inclined to regard them as due to some physical condition of the muscle. But it must never be forgotten, we are dealing with the innervation of the muscle more than with its bulk or the length of its tendon.

DR. O. F. WADSWORTH, of Boston.—In my experience in every case where benefit has been obtained from prisms and in some where there has been no benefit, the manifest insufficiency, whether horizontal or vertical, has been greater after the use of prisms than it was before.

DR. RANDALL.—My own insufficiency, slightly lessened by the use of prisms, but is practically unchanged. The asthenopia is now slight and infrequent.

DR. HENRY D. NOYES, of New York.—The symptom of headache in the morning has been referred to. This I noted without any acquaintance with Dr. Greuning's observation. It was a circumstance that attracted my attention three years ago.

I have never connected it with the existence of nasal catarrh, although I have looked for this condition. I have established the fact that a patient may have nasal catarrh and muscular insufficiency and you have to treat both before effecting a cure. If this headache be found with nasal catarrh in some instances, I must assert that it may be found with muscular insufficiency without nasal catarrh because it is of such frequent occurrence.

I wish likewise to put myself right in regard to what I consider insufficiency of the external recti. I am quite well aware that if a given case be examined by different men, it may have different names given to it. I have grown more and more into the way of thinking that insufficiency of the externi is more common than insufficiency of any other muscles. I have found by an experience of six years that prisms used with the view of correcting that insufficiency will do the work which other prisms will not do. For example, this is not a rare condition to arise: that a patient shall have for the distance such a low power of abduction and high power of adduction as to lead you to infer that the trouble is with the externi, but for the reading distance there is the opposite condition, viz., evidence of insufficiency of the interni and not of the externi; there being a contradictory set of facts. I have formerly treated such cases by giving prisms with bases in for near work and prisms with the bases outward for distance. I have, however, found in working over these cases that I have cured a larger proportion by regarding the condition as intrinsically an error of the externi, and by constantly wearing prisms with the base out, the trouble has disappeared and the case has resolved itself into one in which the most important conditions were those of the externi. In this series of one hundred cases, I have allowed to come in some cases where my prescriptions proved incorrect. The proportion may not be correct so far as the actual percentage of cases of insufficiency of the externi is concerned. I am, however, certain that 75 % is the lowest that will be found to be the proportion of insufficiency of the externi muscles as compared with the other muscles. That is the result of careful observation made for six years past.

I have not used the Maddox cylinder. I employ rectangular prisms. With the square prism you have this advantage, that by reversing the prism you can tell whether or not the patient has any vertical error. You ask the patient how far the images are apart. He may say five or six inches. You turn the prism and again ask. He may say six or eight inches. If in one position the images appear separated by five inches, and in the other by ten inches, you know that there is a vertical error.

Then I resort to a prism with the base horizontal and make the patient turn the head so that the light is far to one side. I watch all these points. I am on the look out for vertical error, but in this particular series of cases I have noted only five with vertical error, and I did not find it necessary to take that into account. I have operated on patients for vertical error.

In regard to emmetropia, I do not deny that some of these patients would show .25 D to .5 D of ametropia. I have made a careful examination of the refractive errors, and in numerous instances correcting glasses had been used but did not give the necessary relief, and prisms had to be added. Some one has referred to spasm of the accommodation. It is a disagreeable thing to diagnose it by the use of atropia, and homatropine will not do it. I have been in the habit of diagnosticating its presence for more than twenty years to a degree which is perfectly satisfactory on the following principles: You all know that if you look through a twelve-inch convex lens and read Jaeger 1 that you should be able to read that at twelve inches if your accommodation is relaxed and your eye emmetropic. If you put before the eyes spectacles with twelve inches focus, you will not read Jaeger 1 at twelve inches unless you have great control over the accommodation, because the act of convergences stimulates the accommodation. You must let the convergence relax. It has been my habit to keep in my box a prism of 5° with a convex surface equivalent to twelve inches. The prisms are square. These are put in the holder and the visual lines are relaxed so that accommodation is not at twelve inches but at four feet. Then I expect the patient to read Snellen 1 at twelve inches. If he reads it at eleven inches I do not take it into account. If he reads it at ten inches or less, I say that he has spasm of accommodation. Then I use atropine. It is this kind of examination for accommodative conditions that has helped me in the determination whether or not it was necessary to use atropine.

I agree with Dr. Jackson that in these cases we are not working with an organic condition,—it is often a phase of innervation,—but because it is a trouble of innervation, our methods are not to be discredited.

DR. O. F. WADSWORTH, of Boston.—The result of my measurements would lead me to agree with Dr. Noyes as regards the greater frequency of insufficiency of the externi. Measurements for the near I think do not amount to much. For many years I have made it a practice to measure the insufficiency with vertical diplopia for the reading distance, and I should say that an average of some 6° of insufficiency of the interni is the

rule, but the amount in the individual case is very variable. I am sorry that Dr. Noyes does not think better of homatropine. I wish to say also that I do not put as much faith in the testing of the refraction for the near point and with small type as he seems to do. Patients show a great deal better vision when you give them small type. Many will read Snellen 5 at the distance of a meter, and most of those with normal eyes will read it at least twenty-six inches. Then as the type is brought nearer the image increases more rapidly in proportion than the dispersion circles.

DR. HENRY D. NOYES, of New York.—In testing for spasm of accommodation, I do not give any letters that make words. I give them Snellen's line of separate letters given in capitals No. 1, which I have pasted on a special card for that purpose.

REPORT OF THE COMMITTEE ON THE CAUSES AND PREVENTION OF BLINDNESS.

At the meeting of the Ophthalmological Society, three years ago, the chairman of this committee presented a note on the increase of blindness in the United States, and the facts therein stated indicated that apparently the number of blind in this country had increased in a far greater ratio than the population. That the subject appeared to be of some interest was evinced by the discussion which followed, and it was deemed advisable to appoint a committee, in order to verify as far as possible these statistics, to ascertain at least the more prominent causes of that increase, and to recommend means for its prevention.

In order to make clear the reason for any such action, it may be well to recapitulate, as briefly as possible, the statistics offered at that time; moreover, with a view to making these comparisons at a glance, the figures are given now, as then, by means of diagramatic representations. If we compare the United States census of 1880 with the census of 1870 we find that

The population in 1870 was . . .	38,558,371
And the number of blind then was . .	20,320
Whereas in 1880 the population was .	50,155,783
And the number of blind was . .	48,929

That is to say, that while the population increased 30.09 per cent., the number of blind increased 140.78 per cent.

A closer examination of the increase in the different States shows that there existed in the United States the same geographical distribution of the blind as has been found by Zeune in Europe, and elsewhere with few exceptions, namely: that the proportion gradually increased from north to south, dividing the United States into three parts, as represented by the accompanying map, the first situated above the 40th parallel of latitude, the second between the 35th and 40th, and the third below the 35th parallel. It will be found that

In the northerly range of States	there	are	7.09	blind	to each	10,000.
In the middle range	"	"	9.42	"	"	"
In the southern range	"	"	10.81	"	"	"

Again, we find that blindness decreases as we pass from the east toward the west, dividing the United States and territories into three groups. According to longitude, the *first* including the States that lie between the Atlantic Ocean and the Mississippi River, the *second* between the Mississippi River and the Rocky Mountains, and the *third* between the Rocky Mountains and the Pacific Ocean, as indicated in the accompanying map. We find

In the easterly range of States	there	are	10.34	blind	to each	10,000.
In the middle range	"	"	7.90	"	"	"
In the western range	"	"	5.68	"	"	"

In the paper referred to, stress was laid on the fact that since the census of 1880 was unusually accurate as compared with the census of 1870, it was probable that the remarkable increase in the number of blind was deceptive and misleading in a great degree. A fair consideration of the facts, however, showed that while the increase was decidedly exaggerated, still the proportion of these unfortunates is certainly greater than the increase of population warrants.

An examination, more recently, of the statistics presented to this Society three years ago, has confirmed what was stated then, and indeed as far as the United States as a whole is concerned, there are no other data available to guide an inquirer in

judging accurately of the question of blindness within its boundaries.

It remained for the committee, therefore, to select some one State, and by more exact examination to obtain details rather than these general statements, ascertaining, if possible, by these means something further in regard to the causes of this apparent increase. For various reasons the State of New York was so selected, as offering particular advantages for the proposed inquiries, although it should be stated at once that the increase here has been greater than the average in the other States. When we compare the report of the United States census of 1870 with 1880 we find that the population in 1870 was 4,382,759, and in 1880 it was 5,082,871, whereas the number of blind in New York State in 1870 was 2,213, and in 1880 was 4,981, that is to say, that while the population increased 15.9 per cent., blindness increased 125.07 per cent. In a similar manner, if we compare the New York State census of 1875 with the United States census of 1880 we find while the population increased 8.1 per cent., blindness increased 111.03 per cent., or, in other words, during the ten years preceding 1880, blindness in New York State increased 8.2 times as rapidly as population, and during the last five years of that decade, it increased 13.7 times as rapidly.

Sufficient data, however, have perhaps been given, concerning the probable increase of blindness in the entire United States, — certainly in the one State, taken for exemplification, — to justify the inquiry into its causes.

We come, therefore, in the second place to ask, what are the most important causes of blindness in the United States or in any special portion of it? The most satisfactory method of answering this question is by an examination of the eyes of a large number of those who have become blind; either as they are collected together in institutions, or as they are scattered through various portions of the country. Unfortunately, in no national census has any attention been given to this point, nor in that of any single State in the Union, so it was necessary to seek these facts by a system of personal examination of the blind in some locality, the State of New York being again selected as the field of inquiry.

This was particularly preferred for the reason that considerable data relating to the blind had recently been collected for a report which was presented at the New York State Medical Society in February, 1889. For each of the individuals examined then, and later, especially for this report, a blank was filled out almost identical to the one proposed by Magnus, and to show that it was to a certain extent complete, a copy is here given.

Name of the Blind Asylum?
Location?
Date of the examination?
Name of the Examining Physician?

1. Name of the Blind Person?
   Residence?
   Name of Father or Guardian?
   Residence?
2. Sex?
3. Age?
4. Religion?
5. Nationality?
6. For Adults, occupation before blindness?
   " Children, " of the parents?
7. Color of the hair?
8. Color of the Iris, if possible?
9. Degree of blindness?
   A. Count fingers at $\frac{1}{3}$ meter?
   B. Quantitative perception of the light?
   C. Absolute Amaurosis?
10. Cause of the blindness of the right eye?
11. " " " " left "
12. Condition of the Right Eye?
13. Condition of the Left Eye?
14. Age at which right was lost?
15. " " left "
16. Can the blindness be referred to scrofula?
17. Can it be referred to syphilis?
18. Is the blindness the result of any disease of the general system?
19. Are there any other bodily infirmities?

For those who have had small-pox. 20. Was there blindness before vaccination?
21. Was the vaccination effectual?

22. Did the blindness occur when in a town or when in the country?
23. Were the parents related to each other?
24. Did the parents have normal vision?
25. Were any of the relatives blind?
26. Were there any other circumstances which might be of importance in connection with the affection?

At that time 398 cases were examined. 168 cases at the New York Institution for the Blind were examined by Dr. W. H. Bates under the supervision of Dr. H. D. Noyes. 128 cases at the New York State Institution for the Blind at Batavia, New York, were examined by the chairman of this committee, and under his direction 102 cases were examined by physicians at the poor-houses in different parts of this State, due credit to each being given in the report referred to. Inasmuch as the chairman of this committee was also chairman of the committee making that report, and inasmuch as the plans of the investigation were to a certain extent similar, we have here considered it advisable to make use of the data there obtained, adding such as were possible otherwise, and drawing conclusions from the whole. Since then, Dr. Andrews has added to the list 120 cases examined at the Almshouse in New York, and for each individual a blank was filled out exactly the same as that already given. This addition gave a total of 509 cases, and as the plan of investigation was the same, it was easy to formulate the result on a common plan. The following, therefore, is a list of 509 cases of the blind of all ages, 288 being from asylums, and 221 being from poor-houses. They are classed together and presented here for the reason that these statistical details were unnecessary to the object of the other report, and now published here for the first time. They are:

Anophthalmos and microphthalmos,	0.70
Atrophia nervi optici congenita,	1.31
Other form of congenital blindness,	0.26
Blenorrhoea neonatorum,	14.51
Trachoma and blenorrhoea,	7.78

Conjunctivitis diptheritica,	0.75
Corneal ulcer,	3.33
Corneal ulcer from small pox,	3.33
Diseases of the cornea, primary and secondary to conjunctivitis,	12.51
Iritis,	3.33
Choroiditis and cyclitis,	6.30
Myopic choroiditis,	0 26
Irido-choroiditis with meningitis,	0.26
Irido choroiditis,	3.35
Choroiditis,	0.26
Glaucoma,	2.05
Cataracta accreta congenita,	1.31
Cataract,	9.86
Neuro-retinitis,	2.70
Atrophia nervi optici,	8.25
Sublatio retinæ,	0.26
Ophthalmia sympathetic,	8.21
Direct injury to eyes,	6.25
Injury indirect,	3.25
From operation,	0.26
Tumor of eye and its surroundings,	1.00
Syphilis,	0.26
Scrofulosis,	0.26
Scarlatina,	0.26
Variola,	0.26
Undeterminable and unknown,	3.83

There is a temptation to comment at length upon several points elucidated by this table of percentages; such a digression, however, would be foreign to the object of this report, and it is therefore deemed advisable to simply give the causes of blindness here, as they are indicated by the table, and to pass at once to the next point under consideration, namely: the prevention of blindness.

As to this phase of the subject there is so much that could be said, that this portion of the report must necessarily be exceedingly brief and trite. Our recommendations, however, would be as follows:

First — To familiarize the profession with the advantages of Credé's method as a means for lessening the number of cases

of ophthalmia neonatorum. It is a lamentable fact that a large portion of physicians in active practice, and many obstetricians, are entirely ignorant of the advantages of this simple procedure, or, for some reason, have neglected to make any systematic attempts to test its efficacy. A great deal depends upon those whose practice affords them opportunities of seeing the dire effects of purulent ophthalmia, for by the presentation of papers at medical societies, or by discussion with persons with whom they come in contact, much good work can be done in this respect.

Second—It should be the endeavor of those familiar with the subject to appeal particularly to the examiners of midwives, and, when possible, to midwives themselves, in order to impress upon them the dangers of ophthalmia neonatorum, or, still better, to encourage the enactment of laws in various States which would require nurses to promptly report every such case to some legally qualified practitioner. The fact that nurses and midwives in most States have a very irresponsible position, which enables them to do much harm; the fact that a very little negligence or delay with this class of cases often results most disastrously to the patient; and the fact that the duty of nurses in this respect in foreign countries has already been established, and at least by one State in the Union, inspires the hope that creditable reformation may take place in other parts of our own land.

A certain amount of attention paid to these two suggestions by a few of the prominent American oculists might diminish appreciably the baneful results of that one disease, ophthalmia neonatorum, which produces the largest number of these unfortunate sufferers.

In the third place, the committee would recommend that greater care be taken in instructing physicians to asylums and residential schools, and other persons having charge of such institutions, concerning the dangers of contagious ophthalmia in any form. Here, also, it would be well to seek the aid of legislation in limiting the number of inmates, proportionally to the size of the school, to the air space in the dormitories, etc., as has been done already in the State of New York.

Fourth — Greater care should be exercised in the prevention and intelligent treatment of cases of purulent conjunctivitis and other contagious conjunctival diseases of adults. In workshops, hotels, and other public places, where practicable and advisable, notices could be posted calling attention to the danger of contagion from roller-towels, from imperfectly clean wash-basins, or similar sources of contamination.

Fifth — In order to prevent the introduction of cases of trachoma and other forms of contagious eye diseases it is desirable that more stringent regulations be made by the commissioners of immigration. Suspicious cases should be quarantined, and if there is danger of blindness to the individual he should be returned to his own country. It is certain that a considerable number are admitted each year the condition of whose eyes necessitates application for public relief, either at the time of landing or soon after, and it is very probable that the apparent increase of blindness in the United States is due, in no small degree, to the number of cases of contagious eye diseases, more or less developed, that come among the immigrants each year and are distributed to different parts of the country.

Sixth —As a certain number of cases of very imperfect vision or blindness result directly or indirectly from myopia acquired in youth, superintendents or school teachers and parents ought to be instructed concerning those precautions, which taken early undoubtedly lessen the proportion of myopes. This phase of the subject has already received considerable attention in certain parts of the country, and is too familiar to require any further mention.

Seventh — As another considerable portion of cases of blindness are due to accidents which occur in factories, and are the almost inevitable results of the pursuance of certain trades, it seems advisable to post notices near grindstones, in boiler shops, machine shops, and similar places, cautioning the workmen against those habits of carelessness most apt to occasion accidents. This might be stated briefly, and a few words added advising against the use of poultices, lead washes, etc., and other noxious forms of treatment.

Eighth—Finally, the committee would strongly recommend in the medical colleges throughout the country more attention be given by the faculties to the course of Ophthalmology, making it as long and thorough as the requirements of other branches will admit. The committee is fully aware that in making these statements and recommendations regarding the causes and prevention of blindness it simply formulates in brief what is for the most part well known from similar observations made in other countries. It is hoped, however, that the action of this body in recognizing formally the importance of the subject may draw to it the notice of practitioners in general, and it seems fitting that a society whose object is the advancement of Ophthalmology should also be the pioneer in any combined effort of the profession for the prevention of blindness.

LUCIEN HOWE, M.D.,
SWAN W. BURNETT, M.D.,
JOSEPH A. ANDREWS, M.D.

DISCUSSION.

DR. O. F. WADSWORTH, of Boston.—I wish to refer to one point in regard to the statistics given. We appreciate the great value of such investigations, but one point that we must all have been struck with is, the rapid increase of blindness as shown by comparison of the census of 1870 and of 1880. I was interested in that after hearing the preliminary report presented a year or two ago. I spoke about it to General Walker, who was in charge of the census of 1870 and 1880. He told me that the appropriation in 1870 was insufficient to permit a special inquiry in regard to blindness, but in 1880 the inquiry was made and that any comparison between the statistics of these two years was utterly worthless.

DR. HENRY D. NOYES, of New York.—The increase of blindness in New York City may be partially accounted for by the fact that every blind person receives forty dollars annually.

DR. LUCIEN HOWE, of Buffalo.—Dr. Wadsworth brought up the same objection at the meeting before, and I mentioned that point in the report which I made three years ago. I laid special stress on that—the census of 1880 being much better than that of 1870. If these statistics are without any value, however, they are an exception to those relating to other defective classes, as to the insane for instance. The same question

was raised in New York by the Chairman of the State Board of Charities. He studied the matter and went over the statistics of the different asylums, and to his astonishment he found that there was a similar rapid increase. This, as far as blindness is concerned, is due to several causes. One point especially must be taken into account, and that is, immigration, for many blind are sent to our shores every year. I have a letter addressed to the gentleman in charge of these immigrants, and I have his reply. I asked "what examinations are made of the eyes?" The reply is, "None." "What statistics have you in regard to those partially or totally blind who enter?" The reply is, "We pay no attention to that." "What care is given to them?" "None." The replies were in that style. The greatest possible laxity exists. When this is taken in connection with the large number of immigrants that arrive at the port of New York alone, and remain on the Atlantic coast, it is one explanation why the increase of blindness is greater there than elsewhere. This is particularly true in regard to the lower classes of Irish among whom granulosa is so common.

LEGISLATION FOR THE PREVENTION OF BLINDNESS.

BY LUCIEN HOWE, M.D.,
BUFFALO, N. Y.

As it is generally admitted that prevention is better than cure, I venture to call attention to a method by which that disease which produces a greater number of blind than any other, may be, to a considerable extent prevented, or in certain States, made largely to disappear. I refer to legislation for lessening the dangers of ophthalmia neonatorum. The title of this paper would indicate the intention of treating the subject from a more general standpoint, and there is certainly a great temptation to consider here those laws relating to children in asylums and residential schools, whereby contagious diseases of the eyes in those institutions can be, to a certain extent, prevented. It is undoubtedly the fact that if examinations were made in other large cities, similar to those investigations undertaken in New York a few years ago, by members of this society, the results

would demand immediate and proper legislation, having for its object the prevention of blindness, such as was found necessary in this State.

Enticing as these phases of the subject may be, I fear that by occupying time and directing attention in their consideration, I should fail to establish, as I hope to do, the importance of passing laws which have for their object the lessening of the dangers of ophthalmia neonatorum. In regard to this, therefore, I wish to show as briefly as possible—

First,— That it *should* be done, — or the reason for it.

Second,— That it *has* been done, — or the attention given to the subject in other countries and in the State of New York.

Third,— That it *can* be done easily in other portions of the United States as well as in the State of New York.

It seems almost unnecessary to dwell at length upon the advantages to be derived from any method which would decrease in the least the dire effects of ophthalmia neonatorum. Statistics show beyond doubt that of all diseases of the eye this is more productive of blindness, and that particularly among children. Of 3,204 cases in asylums, in different parts of Europe, Magnus found 23.5 per cent., or nearly one-quarter of the whole number, were made blind by that disease. The asylums of Switzerland give 26.02 per cent., Germany 25.83 per cent., and Hungary 20.47 per cent., etc. That the same condition of affairs exists in this country is proved by an examination made of 128 cases at the New York State Asylum at Batavia, where I found that 19.5 per cent. were there because of that disease. A similar large proportion has been found in the New York Institution for the Blind by Dr. Andrews and by Dr. Bates. Without dwelling further on the statistical aspects of this question, I would simply remark in passing, that the census returns in 1880, as compared with 1870, apparently show that blindness has increased in the entire country more than four times as rapidly as population, while in some States it is greater still. In the State of New York, for instance, the increase in blindness was 8.2 times as rapid as the population. During that decade, making allowance for the large sources of error which undoubtedly

exist in these enumerations, it is but fair to infer that the prevention of blindness is of some importance, and especially the limiting of the effects of that disease which unquestionably produces nearly one-fifth of all the blind of early life. Again, it should be noted that in the treatment of ophthalmia neonatorum almost everything depends upon promptness.

There is perfect unanimity of opinion that when these cases are seen at the very outset, the eye can be saved in almost every instance with little or no injury, while, on the other hand, ulceration and perforation often occur when the children are neglected until the disease is far advanced.

The question of lessening the number of blind—in other words, lessening the effects of ophthalmia neonatorum—resolves itself then simply into this: How can these children be brought at once under the observation of some person qualified to deal intelligently with the case? In many instances, it is true, the patients are from first to last under the care of the family physician, who has not only perhaps made use of Credé's method for preventing the attack, but when it occurs, is competent to treat it intelligently. Unfortunately, however, the large proportion of such cases, especially in crowded cities, are only seen at first by a midwife, or if a physician has been called at all, the child is subsequently left in the care of such midwife or nurse. While under her observation the first appearance of the disease manifests itself, and she, either through neglect or ignorance, or a desire to continue in charge of the infant without interruption, fails to call for intelligent advice until the disease is so far advanced as to threaten the integrity of the eye. In such instances, which are unfortunately well known to every oculist, we believe it would be advisable to compel the nurse by law to report the case, as she would any other contagious disease, to some person who is at least legally qualified to practice medicine. As to the justice and reasonableness of this there can be no doubt.

It is unnecessary, in a short paper like this, to refer at length to official actions in this respect abroad. Any one sufficiently interested in the subject, will find more exact statements in Fuch's prize essay on the causes and preventions of blindness

in Magnus Blindness of Early Life,* or in the articles of Adder,† and Steffan.‡

These cite the more or less stringent regulations adopted by Germany, by France, and by Switzerland, which demand of nurses certain extra precautions when assuming charge of a suspected case of ophthalmia neonatorum, or require the nurse to report the case to the proper medical officer, and turn its management over to him.

The question has arisen there, as it might well here, whether any obstetrician should not also be required by law to drop into the eyes of every new-born child a two per cent. solution of silver nitrate, after the manner recommended by Credé. But as it may appear later that some other method is better than this, it seems unwise at present to compel physicians to adopt any one method of prophylaxis, but rather require the nurses and midwives to report suspicious cases to some physician, and then hold him responsible for the treatment. Unfortunately, he is often as ignorant of his duties then as the nurse is of hers, but if so, the law looks after him in the result of a suit for malpractice.

The plan of having midwives report to some physicians has been adopted in the one State which, thus far, has recognized the matter by any legal action. In February of '89, I presented a short paper, at the meeting of our State Medical Society, on the "Purulent Conjunctivitis of Infancy and Blindness," in New York State, and closed it with a recommendation that the committee on legislation be instructed to formulate and urge the passage of a law which should require nurses and midwives to report at once, to some legally-qualified practitioner any suspected case of ophthalmia neonatorum.

This was done, and early in the next session of the Legislature the following became a law:

* J. F. Bergman, Wiesbaden, 1886.
† Millheilmigen des Wiener-Medicini schen Doktoren-Collegiums, b. ix, No. 14.
‡ Central Blatt fur Allgemeine Gesundheitspflage, 111 Jargang Bonn, 1884.

CHAPTER XLI.

An Act for the Prevention of Blindness.

SECTION 1. Should any midwife or nurse having charge of an infant in this State, notice that one or both eyes of such infant are inflamed or reddened at any time within two weeks after its birth, it shall be the duty of such midwife or nurse so having charge of such infant, to report the fact in writing, within six hours, to the health officer or some legally-qualified practitioner of medicine, of the city, town, or district in which the parents of the infant reside.

SEC. 2. Any failure to comply with the provisions of this act, shall be punishable by a fine not to exceed one hundred dollars, or imprisonment not to exceed six months, or both.

SEC. 3. This act shall take effect on the first of September, eighteen hundred and ninety.

A few corrections will undoubtedly be necessary to convince this class of people that there is such a law and that it must be obeyed. But there seems no reason why it should not be the means of saving many a cornea from ulceration, many a child from blindness.

I have ventured to occupy the attention of this society with so many details in the hope that other members would think it worth while to interest themselves in the cause of similar legislation in other parts of the country. The Ophthalmological Society has now representatives in sixteen of the largest and most populous States, and if even the majority of these would call the ignorant and careless nurses to account for the mischief done to the eyes of the children, we would certainly count on a less number being sent each year to the blind asylums in those States.

The passage of such a law is easily obtained, especially if endorsed by a State Medical Society. The average legislator is happy to identify himself with a measure for the public good, which for once has no suspicion of political aims about it. With every reason then for such legislation, and apparently none against it, does it not seem almost the duty of members of a society like this, at least by individual effort, if not by combined action, to interest themselves in some such legislation for the prevention of blindness.

CONTRIBUTIONS TO OCULAR TUMORS.

By DR. W. H. CARMALT,
NEW HAVEN, CONN.

Small round-celled Sarcoma of conjunctiva, Extirpation — Recurrence — Death.

On February, 1883, O. DeW., aged 8 years, was sent to me by the family physician for an excrescence which had been noticed in the inner surface of his left eyelid for a short time previously, and treated as granular lids. The child was a rather delicate lymphatic-looking boy in otherwise apparently good health. Attention being called to his eyelids, a fullness of the left upper eyelid was noticed, and on everting this a reddish mass, flattened against and projecting forwards upon the globe came to view. It bore a striking resemblance to the comb of a cock projecting from the upper cul-de-sac, somewhat papillary in outline along the edge so that the resemblance to very exuberant trachomatous granulations was not far-fetched. It was covered by and apparently included the conjunctiva. It was freely movable on its free edge and attached far up in the cul-de-sac by a narrow, flat, pedicle-like portion. I removed the mass without difficulty, and though in doing so I cut through something more than conjunctiva, it appeared as if I had gotten beyond the growth, and the fullness of the upper eyelid (after the first inflammatory swelling subsided) disappeared entirely. The tumor removed was about an inch in length by half an inch in breadth and less than one-eighth in thickness. It was lost after the operation, and consequently no microscopic examination was made. In about six weeks the child was brought to me again with a growth in the same situation, but so large that the lid could not be closed over it without an effort, and palpation indicated a tumor presenting itself above the eye, but evidently with deep orbital attachments. It was firmly attached to the orbital plate of the frontal bone, but could be apparently circumscribed laterally. I advised its immediate removal, and on the following day, assisted by Dr. Harris of Lyme, Conn.,

the family physician, proceeded to operate, making a slightly curvilinear incision through the upper lid parallel to the edge of the orbit. I found on getting down to the growth, that it was exceedingly vascular, and that it infiltrated the orbital tissues to such an extent that it would be futile to attempt to isolate it, the levator palpebræ superioris being buried in the tumor; so explaining to the father, who was present, that it would be necessary to remove the whole contents of the orbit, including the globe, and even that must be without an assurance that the growth would not return, he decided not to proceed farther with the operation, and I have never blamed him for his decision. The wound was plugged to control the hemorrhage. It healed readily, but the growth of the tumor continued, soon invaded the tissues beyond the orbit, and extended over the cheek and side of the head. For a time the child's general health continued good, but in the course of a few weeks he became weaker, the surface of the tumor ulcerated, and he died in the summer of the same year. No autopsy was made. A piece of the tumor was excised at the time of the operation and submitted to Dr. Prudden for examination, who reported it to be small round-celled, lympho-sarcoma.

Glio-Sarcoma of Retina (?) Enucleation, Recurrence, Removal, Metastases in Brain, Death.

On January 6, 1888, M. C., aet. 10, a girl, was brought to my office for consultation with regard to her left eye, which presented the following appearances, viz.: The pupil was widely dilated and blocked up completely by a soft cataract. The iris looked hazy and there was a slight circum-corneal injection. T. normal, no tenderness. She denied all perception of light. The pupil was unaffected by the instillation of eserine. She denied having ever received any injury. The history was simply that about eight months before the mother noticed a "faded look" to the eye, and in the course of a month or two afterwards that the pupil became filled up. The child never complained of pain, and the redness seen at the consultation had been more or less persistent. The diagnosis of chronic irido-choroiditis, with probable detachment of retina and general disorganization of the interior, was made, but as she was abso-

lutely without pain or other unpleasant symptom than the loss of vision, no operative interference was proposed.

The following January, six months afterwards, she again presented herself with the account that for two weeks the eye had pained her greatly, the suffering being quite unbearable without large doses (for her) of morphine. The sclera was now of a livid red color. The lens dislocated upwards into the anterior chamber, the whole anterior segment of the eye appeared bulging forwards, iris and lens were both of dirty greenish brown color, the T + 2, but the globe was not tender. Enucleation of the eye was advised and submitted to four days afterwards, January 28, 1889. Nothing in the operation or external condition of the eye requires comment, and on opening the globe it presented the appearance simply of a general disorganization, detached retina, and the interior filled with a diffluent mass, more or less whitish in color, presenting the appearance of broken-down blood clot, but nothing to support a tumor, so that the entry was made in the hospital records, "on section of the globe after enucleation the interior was found thoroughly disorganized." In due course of time an artificial eye was inserted and I heard nothing more of the case until just one year afterwards, when on January 25, 1890, she again presented herself with the orbit completely filled with a firm tumor mass, of which the first evidences were about two months before, when it was found difficult to insert the artificial eye, so that it had been left out. The child had been very much excited at the idea of again being subjected to an operation, and at the time of the consultation, and before, was in a highly hysterical condition, and it was difficult to determine the vision of the other (right) eye. She wept during the whole examination; insisted that she was entirely blind, but it was impossible then to make an ophthalmoscopic examination. The pupil was dilated and irresponsive to light, and she groped about, but there was nothing in the appearances externally to account for it.* The media were perfectly clear, and the only suggestion of abnormity in the fundus was a generally pale condition; but as the child was a blonde this appearance was not remarkable — there was

* She was sent to the hospital and the following day the examination was continued.

not the faintest trace of "choked disk," and I still suspected her of maligning in respect to her vision.

The thorough removal of all the contents of the orbit was carried out on the following day. The mass filled the orbit completely, but there was no considerable difficulty in getting all around it, except of course at the apex of the orbit where the tumor was continuous with the optic nerve, and where it was necessary to cut through the tumor growth. After cleaning out the orbit as thoroughly as possible with the scissors, down to the apex where the mass was removed to the optic foramen, all of the orbital surfaces were thoroughly cauterized over with a solution of zinc chloride, 20 grains to the ounce, and the cavity filled with a plug of cotton saturated with the same pushed down to the foramen opticum. This was left in twelve hours, and the orbital surface found to be an eschar, and in due time the whole bony lining of the cavity exfoliated, and in the floor an entrance was made into the nasal cavity. The child's general health improved greatly, and she became fat and happy, but time showed that her statement as to want of vision in the remaining eye was correct, though no lesion in the fundus to account for it ever became apparent. She was about to be discharged from the hospital, the surfaces of the orbit having become nearly cicatrized over, when one day she complained of nausea and weakness, and on the third day afterwards she had a convulsion. This was followed by others; she kept her bed, became rapidly weaker, lost control of her discharges, and died on the 8th day of June, four and one-half months after the extirpation of the orbital tumor.

The autopsy showed no return of the tumor in the orbit, but on attempting to remove the brain, it was found that at its anterior portion over the sella Turcica, and over the orbital plates of the frontal bone, the brain tissue was occupied by a neoplasm which involved the optic chiasm and both optic nerves; it penetrated into the brain substance anterior to the optic thalamus and as far as the fissure of Sylvius on the left side, and well over the orbital plate of the right anterior lobe. The sella Turcica was eroded as well as the wings of the sphenoid at the apex of the orbit. The growth had involved both dura and brain substance, and was attached to as well as eroding the bone.

There was also a tumor mass as large as an English walnut occupying the center of the right side of the cerebellum; this was itself very soft and friable, and surrounded by a pultaceous mass of broken-down tissue. The tumor removed from the orbit on June 26th, and these tumors of the brain were found to be glio-sarcoma, so that the pultaceous disorganized mass found in the eye at its extirpation, but not diagnosed at the time, was undoubtedly of the same character, the later growths being really secondary.

Double Glio-Sarcoma in an infant — Both eyes enucleated — Apparent Recovery.

On July 11, 1889, a delicate female child, M. B., aged one and one half years, was brought to me by Dr. Stone of Meriden, Conn., as it appeared to be blind. On examination each pupil was seen to be occupied by a brilliant yellowish white reflex, proceeding from some little distance behind the iris. In the R. E. it was nearly smooth and regular across the whole pupil, and by ordinary observation with daylight appeared to be a dense post-capsular cataract. In the L. E. the general appearances were similar, but at the lower external quadrant of the pupil the reflex was less brilliant, and the iris was pushed forward nearly, but not quite, to the cornea; the globes are both fairly firm in tension; both pupils are moderately dilated and react to light. By oblique illumination and by direct examination with the ophthalmoscope, vessels are plainly seen running across the surface of the mass in both eyes, and in the left there is besides quite a congeries of vessels lying in the sulcus between the two parts described as presenting somewhat different appearances. The history was of "something the matter with the eyes" in infancy, and as the child began to creep about and observe for itself, it always tried to look at things out of the side of the eye; it also acquired the habit, often observed in blind children, of poking the fingers into the eyes. The diagnosis of double glioma retina was made and the immediate enucleation advised. On July 26, 1889, this was done, the L. E. being removed first and opened into, in order to confirm the diagnosis. It was found occupied, but not filled, with a whitish, diffluent, pultaceous mass of the consistency of softened brain

substance; the rest of the contents were fluid and broken-down blood-clot. There was nothing remarkable in recovery from the operation, and the child improved in strength and general condition. No return of the growth has shown itself to this date as shown by a postal read at the meeting opened just one year from the operation. The eyes were sent to Dr. Prudden of New York, for examination, who reported each to be "the seat of a moderately vascular glio-sarcoma," and in one (presumably the left) he says: "There is a commencing encroachment of the tumor tissue into the optic nerve."

Sarcoma of Conjunctiva — Removal, Recurrence; Second Removal, Non-Recurrence to date.

On January 21, 1890, I removed a small tumor, about the size of a kidney bean, from the inner and lower quadrant of the left conjunctival cul-de-sac of B. A. W., aged seven years. It had been noticed about two weeks. It was freely movable, bore a decided resemblance to that of O. DeW. first reported, except that it was not papillary on the surface, and was without difficulty entirely removed. The wound healed at once. On May 7th the child was brought to me again with the statement that a slight redness had remained at the site of the wound, and about a month ago, *i. e.*, two and one-half months after the operation, a thickening of the conjunctiva just outside of the cicatrix had appeared, and gradually increased, until now there is a flattened disk-shaped growth about the size of a small pea, pink in color, confined to the conjunctiva; there appears to be a sulcus of healthy conjunctiva between the tumor and the conjunctival cul-de-sac. This was also removed, and nothing has been reported yet as to a return, although the time is too short to predict upon. Dr. Prudden reports the first tumor removed as "a small spindle-celled sarcoma." *

The interest in these four cases, taken as a series, centers in the varied outcome of apparently identical growths, two being the small-celled sarcomata derived from the orbital connective tissue, and two glioma retina, and of these the apparently most malignant being operated upon without return, although

* On August 23d, patient returned with recurrence of growth extending deeper into orbit and firmly attached to globe; the latter was enucleated, and the contents of the orbit down to the periosteum removed. I anticipate a recurrence and the death of the patient from the disease.

it is possible that if the first of these two cases, that of M. C., had been presented to me in time to have made an accurate diagnosis, the result would have been different.

It is of further interest to note that in this same case, where there was total blindness of the remaining eye, without definite recognizable lesion, and yet there existed a tumor of the brain as described as large as a goose egg, involving both chiasm and nerve; that while the new growth had abolished by its pressure the function of the nerve, and a secondary tumor had appeared in the cerebellum, nothing of choked disk was ever seen.

THE WINKING TEST.

BY CHARLES E. RIDER, A.M., M.D.,
ROCHESTER, N. Y.

I.

It is my object in this paper to show that a relation exists between the ease with which the lids of one eye are closed, independently of the other, and the relative visual acuteness of the two eyes. The writer believes that this relation has never been noticed heretofore. As will appear, it is quite constant, yet it has been repeatedly overlooked. For instance, Landolt (Refraction and Accommodation of the Eye), in describing the classical experiment for determining the eye most used in anisometropia, says: "He has only alternately to close his eyes. If he closes the eye which is imperfectly adapted, the finger will keep exactly the same position relatively to the distant object that it had when both eyes were open; if, on the contrary, he shuts the better eye, the finger will appear sensibly displaced toward the opposite side."

Schmidt-Rimpler (see Ophthalmology and Ophthalmoscopy 1889), in writing of the use of the ophthalmoscope, states, "Some individuals find it difficult to close the one eye, and only learn it by long practice."

Had Landolt known that in a large percentage of cases his anisometropes close the better eye with difficulty, or not at all, he probably would have mentioned it. In reference to the other authority it may be said, that inability to close one eye indicates

marked visual inequality on the part of the ophthalmoscopic student, and that while endeavoring to close the unused eye he is probably using a very defective one for his examination.

II.

There are no terms known to the writer expressing equality or inequality of visual acuity, irrespective of refractive conditions; he ventures to suggest two words for adoption,. Isopia (Gr. ἰσωπία, equal vision) to denote equal visual acuteness of the eyes; Anisopia (Gr. ἀνισωπία, unequal vision) to denote inequality of acuity arising from any cause whatever.

By the term "wink," as used in this paper, is meant the voluntary closing of one eye by the unaided lids, leaving the fellow-eye open.

III.

For the satisfactory explanation of this relation between the facility of winking an eye and that eye's visual acuteness, it is necessary to consider the advantages of monocular over binocular vision. Briefly stated, the chief value of binocular vision lies in the perception of the third dimension and the large visual field. In many instances, however, the value of monocular vision is greater, for some of the following reasons:

(1) Lessened exposed surface, *e. g.*, in the presence of irritating vapors, smoke, gusts of wind, dust, etc.

(2) Single retinal impression, *e. g.*, sighting firearms, lining-up objects, as in the mechanic arts, in looking through small apertures.

(3) Lessened illumination, *e. g.*, in the presence of very bright light one eye is frequently closed.

(4) Avoidance of imperfect image in the other (defective) eye.

(5) As a means of resting the eyes while continuing work in asthenopia.

(6) In certain cases of anisometropia, where for close work the more myopic eye is employed.

Now, it will be seen that if these are the incentives to monocular vision obtained by closing one eye and keeping the other open, there is no reason why one blind from birth or early in-

fancy should ever have learned by experience to wink, and as proof of this the following is of value:

Fifteen males, of the average age of about twenty years, with eyes of normal size, and with good lid motion, blind, or nearly so, from an early age, were asked to wink one eye and leave the other open. No one was able to comply; a few by extreme contortion of the face succeeded, after much effort, in imperfectly doing so.

Furthermore, it appears that we should expect a difference in winking ability in the sexes, resulting from the differences of employment, similar to the distinction observed in the statistics of fractures of the extremities. The cases which are tabulated in this paper illustrate this point well, for it will be seen that in 180 females examined, 30, or 17 per cent., cannot wink, whereas of 120 males one only, or less than one per cent. cannot wink either eye.

Further, if unequal visual acuteness of the eyes exist in a given case, the binocular vision will generally equal that of the better eye; whence it follows that in the effort to obtain monocular vision the individual will habitually, though generally unconsciously, close the poorer eye; for should he close the better eye the resulting acuity of vision would be below that which he habitually enjoys, and therefore unsatisfactory. Since good and bad are merely relative terms, the conditions of each case must be considered. Usually the eye having greater distant vision is the better; in myopic subjects employed at close work the more myopic eye may be the better — in the sense in which the terms are employed in this instance.

IV.

The 300 cases here classified were examined during the past few years, the record of each being kept on specially printed blanks, having spaces for number of case, the series, date, name, age, residence, vision of both, and vision of each eye — both before and after paralysis of accommodation; spaces were also provided for recording refractive corrections with subsequent result. These cases have been divided into groups of equal and unequal vision, and again according to winking power. The

sexes have been kept separate for the reason above stated. Females, throughout, vary more widely than males, from the rule, as we should expect. Thus, where with equal eyes, 88 per cent. of males wink either eye equally well, only 51 per cent. of females can do so. Again, where with anisopia (unequal visual acuity) 20 per cent. of males wink either eye equally, only 13 per cent. of females close either eye with the same facility.

As this manœuver of winking one eye is accomplished by the effort of closing one and at the same time opening the other eye, it follows that an individual closing the right most readily, leaving the left open, will open the left eye leaving the right closed with the same relative effort, the co-ordinated muscular action being the same in both winking the one and opening the other. This effort has been often tested in these cases, and sometimes is more delicate than the one first described.

V.

300 CASES.

			Males.	Females.
Can not wink,			1	30
Insopia,	Wink equally,		30	33
	Wink unequally,		4	27
Anisopia,	Wink equally,		17	12
	Wink unequally,	better eye more easily,	4	12
		poorer eye more easily,	64	66
		Total,	120	180

Reducing these numbers to percentages we have the following table:

17 per cent. of females cannot wink either eye.
1 per cent. of males cannot wink either eye.

With eyes of equal visual acuity:

88 per cent. of males wink equally; 12 per cent. wink unequally.

51 per cent. of females wink equally; 49 per cent. wink unequally.

With eyes of unequal visual acuity:

20 per cent. of males wink equally.
4.7 per cent. of males wink better eye more easily.
75.3 per cent. of males wink poorer eye more easily.

13.3 per cent. of females wink equally.
13.3 per cent. of females wink better eye more easily.
73.3 per cent. of females wink poorer eye more easily.

Again classifying according to the winking power we have,
Winking either eye equally well:

63.8 per cent. of males have equal eyes; 36.2 per cent. unequal eyes.

73 per cent. of females have equal eyes; 26 per cent. unequal eyes.

Winking one eye better than the other:

5.5 per cent. of males have equal eyes.
5.5 per cent. of males wink the better eye more easily.
89 per cent. of males wink the poorer eye more easily.

25.7 per cent. of females have equal eyes.
11.4 per cent. of females wink the better eye more easily.
63 per cent. of females wink the poorer eye more easily.

If it be known that the eyes are unequal, and one eye be more easily closed than the other, we have the following:

94 *per cent. of males are winking the poorer eye more easily.*
84.5 *per cent. of females are winking the poorer eye more easily.*

VI.

To place this test upon a more certain foundation, a large number of cases must be recorded and classified; the age at which monocular vision is sought by the individual in each sex must be approximately determined. From imperfect observation with this object in view, of 200 children I think it will be found to be at the age of about five years in boys, later in girls. It must also be shown how long we may expect the habit once formed to remain when conditions of vision are reversed. It

will be of value to know how far the varying degrees of inequality affect the relative winking power. Into this detail the writer has not yet ventured extensively. Of 64 males, however, with anisopia and closing poorer eye best, 20 were unable to close one eye at all. In these cases the vision of the poorer eye was as follows: 16/20, 1; 16/24, 3; 16/40, 1; 16/30, 1; 16/50, 2; 16/80, 1; 16/100, 1; 16/160, 1; 16/180, 1; 16/200, 3; less than 16/200, 3; fingers at a few feet, 2. One-half, therefore, of such individuals had less than one-tenth vision in the poor eye. Such calculations can be made profitably in each group.

VII.

I give briefly a few cases illustrating this law:

CASE I. E. D. W., male, 25 years, vision right eye 16/50, vision left 16/80. Can close left easily, cannot wink the right eye. Vision each eye is 16/30 when corrected as follows: Right eye —.50s ( ) —1.50 c. 90 deg. Left eye —1.25 sph.

CASE II. A. S., male, 54 years old; vision of right eye 20/40 raised to 20/30 by —.50 sph.; vision of left eye less than 20/200. Can wink left eye but not the right. Has always wondered why he could wink one eye only. Thinks defect of vision is congenital.

CASE III. E. O. T., male, 29 years; vision right eye 16/12, vision left 16/20. Winks right eye with difficulty, winks left without effort.

The following case shows the origin of the winking habit recognized by the individual:

CASE IV. Judge A. O., 70 years; presents himself for cataract operation. Closes right eye easily, left with difficulty. Says he always shot left-handed because vision of right was inferior.

The following illustrates how slight a difference in visual ease can often be determined by this method of examination:

CASE V. M., male, 32 years old; vision of each eye 16/14. Closes right easily, closes left not so well. Opens right with left closed not easily, reverse readily. The right has hypermetropia 1. D., left but .75 D. Formerly had strabismus convergens; at age of seventeen was operated upon with complete correction by R. Brudenell Carter.

This case will illustrate how long the habit will persist when conditions of vision are reversed.

CASE VI. L., male, about 60 years old; left eye always myopic, right eye good vision. Ten years ago the right lens began slowly to become cataractous, and patient depended upon this left eye for vision; he wore — 18. D., and the eye diverged. For ten years, until a successful operation restored vision to the right eye, his left eye was the better eye. He never could, however, wink the right, but closed the left readily.

CASE VII. H., male, 40 years. Reads Snellen XII at sixteen feet; thinks right eye is better. Was given lines of Snellen type No. XII to read; made three mistakes with right, none with left. Closes one eye more easily than the other, conforming to the rule.

CASE VIII. A female, aged about 55, whose mother has senile cataract; has slightly better vision in one eye. She violates the rule in winking. It is assumed that she formerly conformed to the law, but that some recent loss of visual acuity has reversed the conditions of her sight. By ophthalmoscopic examination the fundus is clearly seen and nothing abnormal noted, the pupil is well dilated, and in the periphery of the lens slight radial opacities can be noted. She, herself, had not noticed visual defect, and unless specially sought it probably would have escaped notice for some time.

CASE X. A patient, in a neighboring town, was suffering with a temporary paralysis of the abducens. To avoid falling in descending stairs, etc., he was advised to close one eye. An acquaintance tells him it is well he is able to wink one eye separately — he, the friend, cannot. Learning this from the patient, the acquaintance is induced to submit to a hasty examination, he being, so far as statistics go, a rarity, viz., a male unable to wink either eye. When closely questioned, he admits that he can close one eye, having, he says, just discovered his ability to do so; he stoutly denies the inequality of vision, insisting that doing close work constantly, he would have discovered any visual defect. When made to read about Snellen XX at twenty feet, the eye he closes is found to be very decidedly defective.

Thus an unrecognized defect has led this man unconsciously to acquire a habit, being alike ignorant of habit and defect.

VIII.

Much time need not be consumed in pointing out the application of this law. In general it may be said that each eye carries with it, in its power of independent winking, the history of its relative visual usefulness. Thus, if a man with a senile cataract presents himself for operation, and all the tests hitherto employed fail to demonstrate any reason for preference in the choice of the eye to be operated upon, the winking test may be of great value; for, if he be found to close the right eye more easily, that eye, according to this somewhat limited number of cases, is or has been for a long time relatively defective in 89 per cent. of cases.

If by close questioning we could establish the fact that one eye had formerly been imperfect, we should be able to select the better eye 94 times in 100.

In a certain class of medico-legal cases the application is obvious.

Newly acquired defects of vision are differentiated from those of long standing; special attention will be drawn to the former where they lead to an apparent violation of this rule, and in the case of the latter it can be demonstrated to nervous patients, who have just discovered visual troubles that they have long existed.

DISCUSSION.

DR. B. ALEXANDER RANDALL, of Philadelphia.—This matter seems very interesting, and I may say that I am a case in point. Although the difference between my two eyes is very slight, due to an astigmatism of only .25 D. on the left, my vision is about 20/xii on the right, nearly 20/xvi on the left. Yet in my earlier life I could wink only with my left eye which is so little poorer, and only by most painstaking effort gained a like control on the right. I am ashamed never to have investigated the subject, for I was brought up on the "Tale of a Pony" by Bret Harte, who, after referring to how

"All that is false in this world below, betrays itself in a love of show,"

goes on to say that

"Bean pods are noisest when dry,
And you always wink with your weakest eye."

DR. HENRY D. NOYES, of New York. — I would ask the members of the society to think of another point which is not exactly in this line. It has been asserted that persons who are right-handed have unconsciously acquired the habit of sighting objects with the right eye, while persons who are left-handed sight objects with the left eye. This means that if I point my finger at an object with both eyes open and then close one eye to see which eye I am sighting with, I find that I am using the right eye. I sight with the same eye no matter with which hand I point. You always sight with the same eye whether you point with one hand or the other. This observation was made by Prof. LeConte of San Francisco.

DR. R. J. MCKAY, of Wilmington, Del. — I have been interested in this matter, because, up to four or five years ago, I could only wink with the left eye. I can now wink both eyes equally, and vision is equal.

DR. CHARLES E. RIDER, of Rochester. — There are many apparent contradictions in this matter, but if we could secure the full histories of these cases from early life, these apparent contradictions would be explained. I was led to investigate this matter from examining countrymen and asking them if they ever shot a rifle, and if so whether they shot right-handed or left-handed. This put me upon the theory, and I began to investigate the matter more thoroughly. I think that if the gentlemen will take hold of it, they will find something interesting and useful. I have indicated some of the points of utility.

NEW TESTS FOR BINOCULAR VISION.

J. A. LIPPINCOTT, M.D.,

PITTSBURGH, PA.

Tests for binocular vision are of two classes: 1st, those for determining the presence or absence of monocular blindness; and 2d, those for establishing the existence or non-existence of binocular single or stereoscopic vision. The former class includes all the methods of preventing the sound eye from seeing, *e.g.*, placing a strong convex glass in front of it as suggested by Harlan,* or a strong concave glass as mentioned by Juler,† or rendering certain letters of a word invisible as in Snellens'‡ test, etc. This class also includes the examination of the pupil reflexes, direct and indirect. The second class includes Hering's test, and the temporary strabismus test with a prism, as well as the various tests with the stereoscope, etc.

The tests which I venture to present for your consideration to-day belong to the second class. Like other tests of this class, they may, of course, when they elicit positive results, take the place of tests of the first class, and so may be of use in the detection of malingering. If, on the other hand, the results are negative, they demonstrate only the absence of binocular single vision, and not the presence of monocular blindness.

In 1875, Dr. Wadsworth§ reported a case in which a $-\frac{1}{18}$ cyl., axis vert., before the left eye, and $+\frac{1}{48}$ cyl., axis 45°, before the

* Trans. Amer. Ophthal. Soc. for 1882, p. 400.

† Ophthalmic Science and Practice, Phila., p. 227.

‡ Snellen's test is to be considered as a test rather for the absence of monocular blindness than for the presence of binocular single vision, because, as ordinarily applied, viz.: with one eye covered with a colored glass — if all of the letters are visible we know that both eyes see, but we do not know that they see in unison, since the covered eye may no longer fix. If on the contrary we cover one eye with a glass of one, and the other eye with a glass of the other, complementary color, and if the whole word still remains visible, we demonstrate the presence not only of *binocular* but of *binocular single* vision.

The test just alluded to, and the various prismatic tests, with the exception of one to be mentioned in a subsequent footnote, are, strictly speaking, tests for binocular single vision, but not for stereoscopic vision, the latter involving the element of depth or estimation of distance in which the varying degree of convergence of the optic axes plays the leading rôle. The distinction, however, may be regarded as theoretical rather than practical.

§ Trans. Amer. Oph. Soc. for 1875, p. 342.

right, produced an apparent convergence of parallel lines towards the left side. The journal of the American Medical Association of November 3, 1888, contained an article by Dr. H. Culbertson, in which he referred to phenomena similar to that observed by Dr. Wadsworth. In March, 1889, I published in the "Archives of Ophthalmology," an article on "the binocular metamorphopsia produced by correcting glasses," in which I gave the results of a large number of observations and experiments. These results, or rather those of them that have a bearing on the purpose of the present paper, may be briefly restated as follows:

(1) A + spherical placed before one eye makes the corresponding side of a rectangle appear higher than the other side.

(2) A − spherical makes the corresponding side appear lower.

(3) A + cyl., vertical, *increases*, whereas a + cyl., horizontal, lessens the apparent height of the corresponding side.

(4) A − cyl., vertical, lessens, whereas a −cyl., horizontal, increases the apparent height of the corresponding side.

(5) A + cyl., axis pointing upward and outward before either (and still more decidedly before each) eye, makes the top of a rectangle appear narrower than the bottom, while if the axis point upward and inward, the top appears wider.

(6) − cylinders, axes upward and outward, increase, whereas those with axes pointing upward and inward lessen the apparent relative width of the top.

(7) Binocular vision is necessary for the production of optical metamorphopsia. Hence the lens must not be so strong as to make the image sufficiently blurred to be incapable of fusion with that formed by the other eye. For in that case the blurred image is suppressed mentally and monocular vision thus practically established.

At the last meeting of this society, Dr. Green suggested the most plausible explanation yet given of the appearances above-described, although the explanation seems unsatisfactory in some respects.

These appearances can be elicited in the case of all persons — emmetropes, ametropes, or anisometropes. The only *sine qua non* is the possession of binocular single or stereoscopic vision.

Such being the case, it has occurred to me to employ the phenomena of optical metamorphopsy as stereoscopic tests.*

In applying these tests I usually hold a + 2 cylinder, vertical, before one eye with one hand, while with the other I hold up a twelve-inch square card at the ordinary reading distance, and then ask which of the two sides is the higher. The answer is generally pretty prompt and decided. I then quickly put the card to one side, turn the axis of the cylinder to the horizontal, and again hold up the card. The side which in the first instance appeared higher, now appears lower than the other. If I wish to confirm the results obtained with the + cylinder I employ a − 2 cylinder, first with the axis vertical, making the corresponding side appear lower, and then with axis horizontal, producing the contrary effect. If I wish to make assurance doubly sure, I make the top of the card appear wider or narrower than the bottom by holding either one or two cylinders with axis oblique before the eyes, etc.

The advantages which may be claimed for these tests are their variety and their simplicity. They are stereoscopic tests with the steroscope left out. The unsuspecting patient may, in the space of a few minutes, be examined and cross-examined again and again with no more extensive apparatus than a rectangular card or book, and two or three lenses from an ordinary trial case.

Besides enabling the examiner to dispense with the stereoscope and its attendant paraphernalia, a signal advantage is that we have the patient more completely under control. We can better observe him than if his eyes are hidden behind the eye-pieces of the stereoscope, and can thus effectually guard against any experiments which he may, if of an investigating turn of mind, desire to try as to the effect of closing one eye. Besides, the changes can be rung with such rapidity as to confuse the most accomplished malingerer if he actually possesses binocular single vision.

I think it important on practical as well as on theoretical grounds to have a test for stereoscopic vision which can be

* The apparent concavity (krümmung) and convexity (wölbung) produced in a plane surface by prisms, bases out or in, explained by Nagel in Graefe u. Saemisch's Handbuch, B. 6, s. 366, answer the same purpose.

quickly and easily applied. In refraction work, for example, we are sometimes in doubt as to the propriety or necessity of correcting both eyes, owing to the patient's inability to decide whether or not he sees better with both eyes than with one. In such cases we may be aided by knowing whether the stereoscopic faculty is present. To illustrate:

CASE I. E. P. A. has S. R. E. 8/cc; L E. do. R. E. −13 −4 c., 20°, S.=20/LX; L. E. −12−4 c., 165°, S.=20/LX. Reads best with R. E. −7−3.5 c., 20°, L. E. −7−3.5 c., 165°, P. D. 62 mm. With these glasses a vertical prism develops at 20 feet distance esophoria = prism 5, and at reading distance exophoria = prism 6. In near fixation, each eye on being covered swings out about 2 mm. With both eyes corrected for reading, patient cannot positively state whether or not the two eyes are better than one. Sometimes they seem better, and sometimes not. The metamorphotic test shows that stereoscopic vision is possible though not constant. Hence I corrected both eyes in the expectation that the binocular impulse, although now feeble, may in time be developed and strengthened.

CASE II. Dr. A. M. N., aet. 58, S. R. E.=20/c+. With + 1.25+1, c., 110°, S.=20/XX L. E. emm. 20/XX. Reads best R. E. +4+1, c., 110°; L. E. +3. Thus fitted patient could not say whether or not the right eye helped vision. But metamorphopsia was present and therefore I corrected both eyes. Of course I do not mean to say that the possession of stereoscopic vision always makes it desirable to correct both eyes, because every one knows that there are cases of anisometropia which, although showing undoubted stereoscopic vision (and indeed because of it) will tolerate the correction of only one eye. On the other hand the absence of stereoscopic vision is not an infallible indication for correcting only one eye, because we in rare instances find persons who use one eye for remote and the other for near vision.

On one occasion the stereoscopic test led me to discover a condition which I had previously overlooked:

CASE III. Miss C. L. F., aet. 55. R. E. (operated upon for cataract October, 1887) +11+2 c. hor. S.=20/XX−. L. E. (operated upon October, 1888) +12 S.=20/XXX. At the time, I

was making some experiments with regard to metamorphopsia in aphakial eyes, and I found that in this case metamorphoptic phenomena could not be elicited. On seeking the cause, there was discovered a slight deviation upwards of left eye = prism 4. On adding to her reading glasses the appropriate vertical prism, stereoscopic vision was promptly established, and reading was now better accomplished with both eyes than with one.

Not long ago I was asked by a man who had been operated upon for cataract whether he could go back to his trade of bottle-maker. His vision is unusually good, R. E. +6.5+.75 c., 62°, S=20/XX+; L. E. +6.5+1.5 c., 172°, S.=20/XII. Before answering his question, knowing how important it would be for him to estimate distance correctly, I tested his stereoscopic vision and found it perfect. I unhesitatingly assured him that he would have no difficulty. He has since told me that he can now work better than ever. This is doubtless owing to the fact that, before the cataracts developed, he must have been myopic, as may be inferred from the comparatively weak glass now required to overcome his aphakia.

In conclusion it may be said that the tests here suggested furnish a convenient means of investigating certain theoretical questions such as the comparative frequency of stereoscopic vision in general, and especially in anisometropia, in monocular amblyopia,* after the correction of strabismus, etc. But a discussion of these points is beyond the purpose of the present paper.

DISCUSSION.

DR. HENRY D. NOYES, of New York. — How is this distortion of the retinal images overcome, if it is ever overcome?

DR. LIPPINCOTT. — The trouble generally cures itself in from three to six months. It is never cured if the glasses are worn only for reading — they must be worn constantly. One curious feature is that after the disappearance of the metamorphopsia the phenomena are immediately reproduced on removing the correcting glasses. The patient is thus, by the use of glasses, brought back, as I have already expressed it, "to a state of nature" — to the visual condition of infancy, before experience had taught him how to allow for the inaccuracy in the information derived through the sense of sight.

* "*Anisopia*," or inequality in the visual acuity of the two eyes, as suggested by Dr. Ryder.

CASE OF FOREIGN BODY REMAINING IN THE EYE ABOUT TWENTY YEARS, FOLLOWED BY ABSCESS IN THE SCLERAL WALL; OPENED AND FOLLOWED BY RECOVERY.

BY B. L. MILLIKIN, M.D.,

CLEVELAND, OHIO.

On the 18th of March, 1871, E. N. O., then about ten years old, was struck in the right eye with a bit of a musket cap, which he supposed at the time did not enter the eye, but the piece was never found. Following the injury the eyeball was very greatly inflamed, and he was confined to his room for nearly three months. For two years the eye then slowly improved, so that the vision was pretty fair, and he could readily read ordinary type. The eye gave him no trouble afterward until about 1883, when he had a severe attack of inflammation in it, producing almost complete blindness. From this attack the eye again improved and vision became fair, and he had no more serious trouble until the latter part of 1887, when the eye again became painful, red, injected, and the sight failed.

I first saw Mr. O. on February 28, 1888, when he gave me the above history, and stated that three or four days before this time, the eye suffered another attack of inflammation and he was then suffering very great pain through the eyeball and the entire side of his head.

Examination at this time shows the following conditions present: In the cornea to the outer side of the pupillary margin and a little below the horizontal meridian, is a linear opacity extending outward and slightly downward, perhaps a couple of mm. in length, or a little more. Lying directly behind this, and in the same direction, is a slit in the iris extending from near the pupillary border to the outer margin of the iris, and so much separated toward the periphery that the red reflex of the fundus is readily seen, and also the border of the lens. Under several instillations of homatropine hydrobromate, the pupil was well

dilated,— the dilatation being free in all directions, except at the border near the slit where it was attached to the anterior capsule. Both the ophthalmoscope and oblique illumination showed very plainly directly behind the slit in the iris an opaque track directly through the body of the lens, where the foreign body had evidently penetrated. In the anterior portion of the vitreous, in the lower outward quadrant, was plainly seen, both through the pupil and the slit in the iris, a grayish white body of considerable size projecting well into the vitreous body. This had the appearance of an encysted body, being quite different from a sarcoma or other neoplasm. There was also a broad crescent outward, numerous floating opacities in the vitreous, a M = 2 D. The vision at this time in O. D. was 6/36, and in O. S. 6/6. Directly over the position of this body the sclera and conjunctiva were much injected, and pressure produced a good deal of pain. By a little pressure over this point, the body could be seen to project farther into the vitreous. At no other portion of the eyeball was there any tenderness, Tn. He was put upon the use of atropia, three or four times daily, and boric acid collyrium, together with hot applications.

On March 7th, he reported that four days previously he had had a very sharp attack of severe pain through the eyeball and side of the head, this subsiding after two or three hours, since when the eye had continued to do well. The only change in the appearance of the eye, noticed at this time, was a peculiar discoloration over the seat of the body, as if the sclera had become partially eroded.

From this attack the eye rapidly recovered and there was no more trouble until September, 1889, when he had another severe inflammatory attack, but owing to my absence from town I did not see him again until Nov. 27, 1889, when I found the eye in an active state of inflammation with vitreous showing numerous opacities, especially in the neighborhood of the foreign body. Under active treatment this slowly subsided. Nothing noteworthy occurred until about the middle of December last, when an enlargement began to show itself directly over the position of the foreign body, and increased quite rapidly, so

that by the 31st of December it was quite pronounced, somewhat irregular in shape, hard to the touch, and felt as if the sharp edge of the piece of cap might be forcing its way through the sclera.

Pressure over this point produced much pain while other portions of the eyeball were quite free from any pain. No change seemed to take place in the interior of the eyeball.

By Jan. 14, 1890, the eyeball was quite free from any general inflammation, and had been so for some days, but the projection over the foreign body had increased, was quite narrowly circumscribed, and there was no redness except in the immediate neighborhood of this enlargement. The impression I had was that the bit of cap had become encysted, had gradually, by the repeated inflammatory attacks, and the increase of connective tissue formed about it, and the action of the ciliary muscle, worked its way through the retina and choroid and into the sclera, and would probably eventually cut through the sclera externally. Following ordinary surgical principles the thing to be done seemed perfectly plain, viz.: to give exit to whatever was contained in the swelling. Under cocaine a needle was first passed through the most prominent portion of the enlargement until it came in contact with a quite hard resisting body. Then a triangular portion of the conjunctiva was dissected from the sclera at this point and a free incision made directly into the swelling. From this escaped three or four drops of material, evidently pus, and with it the anterior walls of the sac collapsed. With a spoon I then scraped out a number of black particles which were pretty hard and resisting to the fingers and under a lens seemed to be metallic, like broken down, rotten, metallic substance, which I have no doubt were the disintegrated portions of the piece of cap. As much as possible of the interior of this sac was removed with the spoon, forceps, and scissors. A needle was passed in two or three portions of it directly through and into the vitreous, in order to determine definitely if there was any hard substance remaining. What surprised me very much was the extreme thickness of the scleral wall at this point. It certainly must have been more than a centimeter thick, and notwithstanding the freedom with which I spooned

out and tore out with the forceps, and cut out the hard portions with scissors, I did not enter the vitreous chamber, or disturb it in the least. Both before and during the operation the eye and its appendages were thoroughly cleaned and washed with 1–5000 bichloride of mercury solution, and every precaution taken to keep the wound clean.

The pain from the operation, notwithstanding the very free use of cocaine, was quite considerable. The cavity of the wound was freely washed by injecting the bichloride solution, and the eyeball was dressed with a compress moistened with the same solution and a bandage.

Briefly, the eye recovered without a bad symptom. As soon as an ophthalmoscopic examination could be made it was found that the body in the vitreous chamber, previously so prominent, had entirely disappeared, and could not be seen through the dilated pupil even by looking as peripherally as possible. By the 22d of January the eye had become quiet, and all tenderness had subsided, except a trifle over the wound and V=3/30.

Up to the present time there has been no pain, no tenderness even over the point of the wound, where he has had some tenderness on pressure, during the past six or seven years, at least. Now, by looking well forward through the pupil there is a slight whitish reflex, but this has not increased at all since the wound has healed, and the opacities in the vitreous have been slowly disappearing. The scar externally is not noticeable except by the closest scrutiny, and the whole condition of the eye is better than it has been for years. He is able to work steadily at his business, that of a merchant, and suffers no inconvenience whatever.

I have been led to give a pretty detailed account of this case, because of the unusual features connected with it, and thus far I have not been able to find any report on a similar case in the literature at my command.

DISCUSSION.

DR. HENRY D. NOYES, of New York — The spontaneous expulsion of a foreign body from the eye does not come under the notice of many persons. I have seen it a few times, but it is comparatively rare.

FOREIGN BODIES IN THE ORBIT.

BY W. F. NORRIS, M.D.,

PHILADELPHIA.

CASE I. — *Shell of Railroad Torpedo lodged in Left Orbit.* Thomas L. Lanehart (3, 8, '89) applied at Wills' Hospital, complaining of severe pain in the left forehead and orbit. The eyeball is wanting on this side, the eyelids bear scars of cicatrized wounds, the left orbit is partly filled with a mass which is very sensitive to the touch, and covered with scarlet and inflamed conjunctiva. At the bottom of the orbital cavity is an opening which discharges an unhealthy pus and in which lie some yellow shreds of connective tissue. The eye on the other side was normal and showed hypermetropia of 1. D. The socket of the inflamed eye was so painful that even after the free use of cocaine, satisfactory examination was impracticable; but a probe introduced into the opening grated against some hard substance lying at the inner lower part of the orbit. His statement was that eighteen months previous (November 22, 1887) he was hewing ties on a railroad, when a torpedo, such as are used to alarm express trains, exploded and felled him to his knees. A doctor, name unknown, examined the injured and shattered eyeball and removed what was left of it. He was taken to the hospital of the Jefferson County Almshouse, Ohio. He was feeble and suffered much pain; was abed six weeks. The injured orbit has since been treated by several physicians, but has never healed, and he has frequent attacks of severe pain in it. Two days after admission the patient was etherized and the orbit explored with the finger, which could be carried back along the roof and outer side to the foramen opticum, but lying along the floor of the orbit on the inside was an irregular hard mass covered everywhere by granulations, but in some places a sharp metallic edge could be detected. Powerful bone forceps were introduced along the finger into the orbit and the sharp

edge seized, and with some difficulty a piece of malleable metal extracted, but the bulk of the foreign body remained behind, and could be only withdrawn by reintroducing the forceps and making powerful traction with them, at the same time pulling the body from side to side. The metallic mass which I here exhibit was finally thus extracted. Its weight was 123 grains. The accompanying phototype gives a very good idea of the size and shape of the mass. The inflammation rapidly subsided, the purulent discharge ceased, and the patient left the house. There had not been, so far as could be detected with the fingers, any fracture of the orbital walls.

CASE I'.—*Piece of nail imbedded in the lower inner part of the left Orbit.* Phillip Beck, aet. 47, on the 28th of November, 1877, was ripping a piece of wood with a circular saw, when the rapidly revolving saw struck a nail imbedded in the wood. A piece of the nail thus struck flew up and hit the left lower eyelid. Twelve days later he presented himself at the Wills' Hospital. The left lower lid was much swollen and presented a zig-zag cicatrized scar. There was considerable subconjunctival hemorrhage on the eyeball, with a chemotic bloodstained lump at the inner angle of the eye, and a scar in the bulbar conjunctiva corresponding in position with the scar on the lower lid. The upper outer third of the cornea was hidden by a fold of red and chemotic conjunctiva. The cornea was clear, the iris, under a mydriatic, dilated readily *ad maximum*; and there were remnants of absorbing blood-clot in the anterior chamber. The entire eye is slightly more prominent than the right, and its motion somewhat limited. The patient complains of severe pain in the forehead, nose, and temple of the injured side. The media are too hazy to permit a view of the fundus. On careful inspection, a minute black point was seen projecting from the bulbar conjunctiva near the caruncle and part above the lower retrotarsal fold, and on touching this with a probe it was found to be metallic. The opening was then slightly enlarged and the metallic splinter seized and withdrawn. It was found to be a piece of a nail three-quarters of an inch in length, and more or less pyramidal in shape, measuring three-eights of an inch at its widest, and one-quarter of an inch at its narrowest part. A

week later, the chemosis had disappeared and a good deal of the subconjunctival hemorrhage had been absorbed. The media had so far cleared that the exit of the retinal vessels and outlines of the disc could be dimly seen, as well as numerous small hemorrhages in the vitreous humor. The tension of the eye was still less than of its fellow, and vision was still much impaired, but the pain having ceased and the prominence of the eyeball diminished the patient went out before complete recovery had taken place.

DISCUSSION.

DR. LEWIS H. TAYLOR, of Wilkesbarre, Pa.—I had a case some five years ago, which I reported elsewhere, in which a foreign body was removed after remaining in the orbit three weeks. The patient, a child less than two years of age, was brought to me with the history that it had been playing with a pen-holder three weeks previously, and had fallen forcibly forward toward the floor, the pen-holder running into the nose and breaking off. A physician in the neighborhood had extracted two pieces of the pen-holder soon after the accident, but the nose and eye remained swollen and painful. When seen by me the eye was much swollen, but the nose was apparently all right. On forcibly opening the lids, which I succeeded in doing with great difficulty, I found a dark body which I succeeded in extracting. It was a piece of the pen-holder an inch and an eighth long. This had been in the orbit over three weeks, causing great pain and completely closing the eye. The child entirely recovered.

SIMPLE EXTRACTION OF CATARACT WITHOUT IRIDECTOMY.

BY CHARLES STEDMAN BULL, M.D.,

NEW YORK.

In apologizing for the presentation of another paper upon simple extraction of cataract, the writer offers in extenuation a more extensive experience in the operation. A previous paper upon the subject, based upon the detailed report of one hundred cases, was read before the New York State Medical Association in September, 1889. Since then the writer has continued to operate by this method in all cases which were deemed suitable for it; and an increased experience, while leading him to modify some of the views previously expressed, has, in the main, confirmed him in the justice of the claims advanced in favor of the operation.

The controversy as to the wisdom or necessity of an iridectomy in the extraction of cataract is still unsettled, but as time goes on and our experience increases, our knowledge upon this point, as upon others, becomes crystallized into something like a positive opinion.

It is interesting to compare the views of such men as Schweigger, Sattler, and Meyer on this subject, as already published. *Schweigger* starts out with an assumption with reference to the corneal section, which we all admit, viz.: If an incision with a sizeable flap is to be made with the narrow knife, it can only be completed by a to-and-fro sawing motion. Every turn of this narrow knife in the wound makes the course of the incision irregular, and must retard the healing. A smooth healing of the wound means the avoidance, as far as possible, of an irregular corneal curvature, which is generally recognized as the greatest cause of imperfect vision after extraction with iridectomy. He considers that there is great danger of prolapse of the iris after such a flap extraction, and hence he argues that it is better to make the corneal section in

the inner margin of the limbus, and not too peripheral. He believes in using a binocular bandage in all cases where an iridectomy is not made, and thinks that the eye should not be opened for three days at least, all drops being instilled in the angle of the lids, without opening them. He considers that the disadvantages of a prolapsed iris consist mainly in the great irregularity of the corneal curvature. If the prolapse is large, he cuts it off. If it is small, he thinks it better to leave it undisturbed, for these small prolapses become flattened in the course of cicatrization, with an improvement in the corneal curvature. He believes that the presence or absence of an iridectomy makes very little difference in regard to the acuity of vision, and in so far as this remark refers to central vision, the writer agrees with him, for the latter depends much more upon the irregularity of the corneal curvature caused by the incision. *Schweigger* employs a capsule-forceps for opening and removing a piece of the anterior capsule. He uses a triangular knife, shaped something like the old Beer's knife, for making the corneal section. This knife is seven millimeters wide at a distance of thirty millimeters from the point, and with it he makes a corneal flap four millimeters in height. In sixty (60) cases of extraction made with this knife, prolapse of the iris occurred in five (5) cases. (See *Bericht über die neunzehnte Versammlung der Ophthalmologischen Gesellschaft*, 1887.)

Sattler of Prag. makes his flap include one-third ($\frac{1}{3}$) of the corneal circumference, the incision being entirely in the cornea. He also uses a capsule-forceps for opening and removing a piece of the anterior capsule. By the simple extraction he removes all hard, or homogeneous, or brownish-gray cataracts, and also all immature cataracts which can be removed entire from the capsule. If the case is one in which the cortex is probably friable and cannot therefore be removed with the nucleus, he always performs an iridectomy. He agrees with Schweigger in the wisdom of not looking at the eye too soon after operation. *Sattler* has found more corneal astigmatism after the simple extraction than after the peripheral linear extraction with iridectomy, and in this view the writer agrees with him. He

prefers the narrow knife in operating. *Meyer* of Paris also prefers the narrow knife of Von Græfe for making the flap operation, and the narrower it is the better he likes it. He makes his section entirely in the limbus, and endeavors to remove a piece of the anterior capsule. He exercises great care in bandaging the eyes, and his first bandage is left on for forty-eight (48) hours. *Meyer* makes a good point when he states that with prolapse of the iris, incarceration is always left behind, even after complete abscission of the prolapsed iris.

Preparation of the patient. If the patient be a hospital case, he should have a bath of the entire body on the morning of the operation, special attention being paid to the cleansing of the hair and beard with soap and water. This is not considered necessary in the case of a private patient. Just before the operation, the patient's face should be carefully washed with soap and water, and then laved with a solution of mercuric bichloride (1-5000). A saturated solution of boric acid should then be used for irrigation of the conjunctival cul-de-sac. The patient should be placed in the bed which he is to occupy throughout the entire course of treatment, so as to avoid all unnecessary moving about. This precaution reduces to a minimum the dangers which may arise from prolapsed iris, opening of the wound, loss of vitreous, hemorrhage, etc. The writer attributes to this one precaution, as much as to any other, the immunity from secondary prolapse which his experience shows.

After the necessary local anæsthesia has been produced by a few drops of a five per cent. solution of cocaine hydrochloride, the conjunctival cul-de-sac is again thoroughly irrigated with the boric acid solution, and the patient is then ready for operation. The instruments are all previously cleansed and sterilized in boiled water and placed in a bath of alcohol. From this bath they are taken wet as they are required for the operation. The hands of the operator, and of the assistant, if he has any, are carefully cleansed with soap and water, and then washed with a solution of mercuric bichloride (1 2000). The surgeon should sit behind his patient and operate on the right eye with the right hand, and on the left eye with the left hand. In this way he is never in his own light. If he is not naturally ambidex-

trous, he should strive to make himself so. A speculum is then introduced to hold the lids open, and the eyeball is firmly grasped with a pair of fixation forceps, the latter being made to seize the conjunctiva and sub-conjunctival tissue over the insertion of one of the straight muscles of the eye, usually the inferior rectus.

A straight, narrow knife, somewhat more slender and delicate than the cataract-knife of Von Græfe, is then introduced on the temporal side in clear cornea, near the limbus, and is passed quickly across the anterior chamber horizontally in front of the iris, and is brought out at a corresponding point in clear cornea on the nasal side, and the incision is then completed, if necessary, by a to-and-fro movement. The length of the incision should involve about two-fifths ($\frac{2}{5}$) of the circumference of the cornea, and is always an upward section. The incision should be entirely in clear cornea, and the flap should be large enough to admit of the easy extrusion of a large lens. The writer feels sure that a too-peripheric location of the corneal section favors both prolapse and incarceration of the iris. The writer never makes a conjunctival flap if it can be avoided, as he regards it as a useless complication unless the patient has a chronic conjunctivitis or dacryocystitis, and it undoubtedly increases the danger from primary inflection by enlarging the wound. Furthermore, in order to make a conjunctival flap, the corneal incision must be well in the limbus, and against this is raised the objection already referred to — the greater tendency to prolapse, or incarceration of the iris, if the wound is peripheric. In making the corneal section, care should be taken to pass the knife quickly across the anterior chamber, and thus complete the section as rapidly as possible. This prevents the escape of aqueous almost entirely, and there is but little danger that the iris will fall over the edge of the knife and be divided.

The writer formerly advised that, in case the iris prolapsed outside of the wound as soon as the section was completed, it was better to restore it to its place in the anterior chamber before opening the capsule. This step he now regards as an unnecessary manipulation of the iris, that might cause additional bruising in unskilled hands. As a matter of experience the iris rarely prolapses until pushed out by the extrusion of the lens.

The capsulotome is then introduced and carried well behind the inferior margin of the sphincter of the iris, and the capsule is lacerated by a T-shaped incision, or better, by a quadrilateral one, care being taken to avoid wounding the iris. The object of the quadrilateral incision in the capsule is not only to make a free opening for the passage of the lens, but also in hopes of effecting a possible removal of this square piece of the anterior capsule with the lens, and this in many cases succeeds. The capsule forceps have also been employed for the purpose of removing a piece of the anterior capsule, and often with success, though not always so. When the latter fails to remove the piece of capsule, the opening made is not sufficiently wide and must be enlarged with the capsulotome. The speculum is then removed, in order to avoid all undue pressure on the eyeball, and this is to be regarded as a wise precautionary step, in view of any possible straining by the patient. The extraction of the lens then follows. This may be done in two ways, viz.: 1st. The upper lid may be lifted up and away from the eye by a wire elevator or broad strabismus hook, and the lens expelled by pressure with a spoon upon the lower portion of the eyeball, and thus indirectly on the lens; backwards toward the center of the eye at first, and then upwards and backwards. In this way the flap rises, tilts forward, and the lens passes through the pupil with the least bruising of the iris. Or, 2d, the extraction may be effected by pressure on the eye above the wound with a narrow spoon or spatula, and counter-pressure on the lower portion of the cornea with a broader spoon. This causes a gaping of the wound, and a revolution of the lens upon its horizontal axis, the upper margin of the lens coming forward and presenting in the wound. A brief continuance of this pressure and counter-pressure causes the extrusion of the lens, and a more or less extensive prolapse of the iris. The removal of the speculum before the extraction of the lens should always be done in cases of complicated cataract, especially when the suspensory ligament is defective and the vitreous disorganized, or the lens partially dislocated.

The next step in the operation is the removal of the remnants of soft lens matter or cortex from the anterior chamber

and between the lips of the corneal wound. The removal of the cortex can usually be accomplished by rapidly and judiciously following up the escape of the lens by pressure with the spoon upon the lower portion of the cornea and also with the lower lid. If this does not succeed, it is better to make repeated and continuous rotary massage of the lids upon the eyeball, aided by repeated slow movements of the curette, spoon, or spatula over the cornea from below upwards toward the wound. These manœuvres should be accompanied by frequent irrigation of the conjunctival cul-de-sac and lips of the wound, and even of the anterior chamber if necessary, by a warm saturated solution of boric acid. Solutions of mercuric bichloride should never be used for irrigation of the anterior chamber, as they cause transient opacities on the internal surface of the membrane of Descemet in the endothelium. It is very rarely necessary to introduce any instruments into the anterior chamber for the purpose of removing bits of cortical lens matter. For irrigation of the anterior chamber, any small lachrymal syringe or a pipette may be used, but it should always be sterilized and kept exclusively for the purpose. The nozzle should be carefully introduced between the lips of the wound, and the fluid should be injected very slowly and gently, and in small quantities.

The next step is the replacing of the prolapsed iris, which occurs spontaneously in about half the cases. Among the first one hundred (100) cases reported by the writer, the iris was replaced spontaneously in fifty-six (56) cases. If the iris has not spontaneously replaced itself during the manipulations employed for removing fragments of cortex from the anterior chamber, it may be readily replaced by gently stroking and pushing it within the lips of the wound with a smooth probe or spatula. If on reduction of the prolapsed iris, the pupil is neither central nor round, do not make an iridectomy at once, as some surgeons advise, but endeavor by a careful, gentle, and continuous rotary massage of the eye through the closed lids, to bring about such an absolute replacing of the iris in its normal position, as will make the pupil round and central.

The final steps in the operation, before the application of the bandage, are a careful irrigation of the lids and conjunctival cul-

de-sac with the saturated solution of boric acid, and the instillation of a few drops of a solution of eserine sulphate (half a grain to the ounce) into the cul-de-sac. The writer again takes advantage of this opportunity to warn against using solutions of eserine of a greater strength than half a grain to the ounce, in the eye. He has seen during the past year several bad cases of iritis directly caused by solutions of two and four grains of eserine to the ounce. In many cases a solution of one-tenth ($\frac{1}{10}$) of a grain is strong enough to produce any desired contraction of the iris, and no risk is here run of causing any irritation.

The lids of both eyes are then closed and covered with a piece of coarse-meshed cotton or linen saturated in a solution of mercuric bichloride (1-5000). Over this is laid a pad of antiseptic absorbent cotton, and a double roller flannel or gauze bandage is applied over both eyes.

The after-treatment should vary with the temperament and general condition of the patient and the nature of the case. The patient should be kept in bed on an average for three or four days, but may be allowed to sit up in bed while eating and at other times, in order to avoid inducing fatigue in his back. He should be allowed to rise from bed to answer the calls of nature. Both eyes are to be kept bandaged for a varying period, according to circumstances. The room need not be darkened. The bandage and dressings are to be removed at the end of forty-eight (48) hours, and sooner, if any reason for so doing arises. The edges of the lids are to be gently cleansed with a warm, saturated solution of boric acid, or a warm solution of mercuric bichloride (1-5000), and the lids are then gently opened and the eye inspected. If the pupil is still contracted, a weak solution of atropia (one grain to the ounce) is instilled for the purpose of preventing as far as possible the formation of posterior synechiae, which occur in about sixty per cent. (60 %) of the cases. If there is any mucous secretion, or any swelling of the lids, the cul-de-sac and eyeball must be thoroughly and carefully irrigated with the warm boric acid solution, and an inspection of the whole length of the wound made. If, on the contrary, there is little or no secretion, and if the lids look well, the eye need not be inspected until the fourth or fifth day, but

the dressings should be renewed and the lids cleansed daily. If on the fourth or fifth day the pupil is round or central, the eye is carefully irrigated, and if the wound has closed throughout its entire length, the bandage is discontinued during the day, and at night is replaced on the operated eye. The eye not operated upon is usually left uncovered after the second or third day. Should there be any pain or circumcorneal injection present, a weak solution of atropia may be used several times a day until both these symptoms have subsided. The writer considers it a mistake to give the cataract patient too much liberty, and in this respect Wecker and others in Paris, and some of our American surgeons have decidedly erred. When patients are sent home on the day of operation or discharged from treatment in two or three days, any report of the result obtained in such cases is valueless, and detailed statistics are impossible. The court-plaster dressing without a bandage has been tried by the writer and found wanting. It is irritating to the skin of the lids, and has been abandoned. The binocular roller bandage should be put on with great care. In warm weather it is better to use a roller bandage of linen or cambric gauze, which is much less heating than flannel.

Complications Occurring in the Course of the Operation.

1st. The iris may fall upon the edge of the knife in its passage across the anterior chamber, and may be wounded or excised as the corneal section is completed. This accident may happen to any surgeon, and is much more likely to occur if the patient strains or contracts any of the muscles of the eye or the orbicularis. The rapid passage of the knife across the anterior chamber to its point of exit in the cornea on the opposite side, and the avoidance of any undue pressure on the eyeball by the fixation forceps, will do much toward preventing the occurrence of this accident. The rapid completion of the corneal section also aids in this endeavor, and is very necessary to the completion of a smooth operation. Should the iris be cut or excised in this first step of the operation, an iridectomy must be done at once, and the artificial pupil made clean and smooth. As a matter of fact this accident rarely happens to the skilled operator.

2d. *More or less extensive hemorrhage into the anterior chamber.* This may be in great part prevented by avoiding the formation of a conjunctival flap. If the hemorrhage comes from a wounded iris, the latter is to be smoothly excised, and the hemorrhage from the divided vessels must then be controlled, and the blood, as far as possible, removed from the anterior chamber before the further steps of the operation are completed. The presence of the blood in the anterior chamber interferes with the proper laceration of the capsule and the removal of the lens.

3d. *Retraction of the iris towards the ciliary processes*, or its dilatation and folding away in the upper part of the angle of the anterior chamber. This is not a common accident, but it is an awkward complication of the subsequent healing process After the lens has been extracted, and the anterior chamber thoroughly cleansed, the retracted iris may sometimes be made to assume its normal position by continuous rotary massage of the eye, assisted by a drop or two of eserine. It may also sometimes be replaced by very careful and delicate stroking with the end of a hard rubber spatula. If the iris is crowded up into the angle of the anterior chamber, it is better at once to pull it out of the wound and cut it off. In any event, the necessity of an iridectomy is an unfortunate complication, for, owing to the location of the wound in the cornea, at some distance away from the periphery, it is not possible to make a perfectly smooth coloboma.

4th. *Prolapse of the vitreous.* This may occur at any step of the operation, and is always a misfortune. In the hands of a careful operator it is usually slight, especially if the speculum has been removed after the opening of the capsule and before the extrusion of the lens; and it need not interfere with the usual careful manipulations employed in evacuating the lens. Any portion of vitreous that remains in the wound after the lens has been removed must be immediately cut off close to the wound, and great care must then be exercised in any manœuvres undertaken for removing any fragments of cortex from the anterior chamber. In cases of prolapse of the vitreous, all irrigation of the anterior chamber must be avoided, as it would certainly increase the loss of vitreous. If the latter is fluid and

the prolapse extensive, the lens should be removed at once with the blunt hook or spoon, and the eyelids immediately closed for a few moments. The iris should then be replaced, gentle irrigation of the cul-de-sac should be done, eserine instilled, and the eye then closed with the usual antiseptic dressings and bandage.

Complications of the Healing Process.

1st. *Posterior Synechiæ,* or adhesions of the posterior surface of the iris to the remains of the anterior capsule of the lens, occurring independently of any actual iritis. These adhesions are very common, being met with in at least sixty per cent. (60 %) of the cases. They are in many instances filiform in character, and rarely obstruct the pupillary area. They are caused by the edges of the lacerated anterior capsule coming in contact with the sphincter margin of the iris, which has already been somewhat bruised by the passage of the lens through the pupil.

2d. *Iritis,* almost always of the mild plastic type, occurring but seldom (in less than eight per cent. (8 %) of the cases), and sometimes involving only a segment of the iris. This is best treated by weak solutions of atropia and warm applications.

3d. *More or Less Complete Obstruction of the Field of the Pupil by the Opaque or Thickened Capsule of the Lens.* This is a very common complication of the healing process, not only in simple extraction, but in all forms of extraction. It almost always requires operative interference of some kind, usually discision, in order to give satisfactory ultimate vision. In the experience of the writer, discision is demanded in at least two-thirds ($\frac{2}{3}$) of the cases.

4th. *Incarceration of the Iris or Anterior Synechiæ.* This consists in a more or less marked adhesion of the iris to or in the inner lips of the wound. This condition should be carefully distinguished from actual prolapse of the iris, where the iris either entirely fills the wound or is actually prolapsed outside of it. This complication unfortunately occurs too often after simple extraction, the writer having met with it in fifteen (15) of his first one hundred (100) cases. Since then he has

met with it less frequently, and this is probably due to the less peripheric location of the corneal wound in his later operations. These adhesions may sometimes be diminished, or even broken, by using a one-half grain solution of eserine several times a day; but the risk of exciting irritation or actual inflammation in the iris militates against any prolonged use of the drug. An incarceration of the iris is an unfortunate complication, for it distorts the pupil, and may be a source of irritation to the eye; but the danger of its occurrence may be reduced to a minimum by making the entire length of the section in clear cornea.

5th. *A more or less irregular pupil*, usually oval, caused by a puckering of the iris in the upper part of the angle of the anterior chamber, without any actual adhesion or incarceration of the tissue of the iris in the lips of the wound. There seems to be no certain means of averting this, and it does not appear to exert any unfavorable influence upon the vision.

6th. *Secondary Prolapse of the Iris.* This is almost always of traumatic origin, that is, due to some sudden or unexpected movement or action on the part of the patient, such as lying on the operated eye, and thus reopening the wound, or displacement or actual removal of the bandage by the patient. It may, perhaps, sometimes be due to a premature opening and examination of the eye by the surgeon. It is probably safe to say that its prevention depends on careful nursing, and partly also on the location of the corneal section. If the incision is in the limbus, prolapse of the iris would be more likely to occur than if the incision were in clear cornea, away from the limbus. The views of the profession have changed in regard to the necessity of cutting off all prolapses of the iris. Formerly all were abscised, but now we reason differently. If the prolapse occur soon after the operation, and it cannot be reduced, it should be cut off as neatly as possible and the edges gently stroked into place in the anterior chamber. If the wound has already partially closed, and the prolapse of the iris is a late occurrence, it is better to leave it undisturbed. Many, if not all, of these prolapses, when left to themselves, disappear or cicatrize in a smooth manner, and are not specially apt to give rise to any sympathetic trouble. Great care in operating, and the

strict exclusion of all such unsuitable cases as rigidity of the iris, dislocation of the lens, unmanageable patients, will all aid in reducing the cases of secondary prolapse of the iris to a minimum.

7th. *Capsulitis, or Inflammation of the Capsule of the Lens,* is a somewhat rare complication. It is almost always of the mildly plastic character, and is usually associated with the mild form of iritis. If it is of the suppurative type, it is almost always, if not invariably, accompanied by a purulent inflammation of the iris, and infiltration of the tissue of the cornea in the vicinity of the wound, and is always the result of secondary infection from without, the purulent infiltration beginning in the wound.

8th. *Purulent Infiltration of the Lips of the Corneal Wound.* This cloudiness of the lips of the corneal wound is fortunately a very rare complication, thanks to modern cleanliness and antiseptic precautions. It is always the result of secondary infection from without, and if not attacked at once by energetic measures, it may end in total loss of the eye from suppurative panophthalmitis. The writer has met with it but three times in something over one hundred and sixty (160) operations, and in all three cases it was almost immediately checked. Its origin is usually a chronic conjunctivitis or dacryocystitis, and it should be treated energetically by immediate removal of the bandage and dressings, repeated irrigation of the wound, eyeball, cul-de-sac, and inner surface of the lids with a hot solution of mercuric bichloride (1-5000), and prompt cauterization of the entire length of the wound by the galvano-cautery. The latter may be repeated daily for several days, if necessary, or as long as it seems to influence the course of the suppurative process.

Secondary Operations.

It is often necessary to perform secondary or after-operations in order to improve the vision, after the cataract has been extracted, and these secondary operations may be divided into two classes, viz.: 1st. Discision or laceration of the posterior capsule. 2d. Excision of a piece of thickened capsule, or of a piece of membranous or pseudo-membranous tissue, composed of the thickened posterior capsule, and the products of inflam-

matory exudation. A subsequent division of the capsule, some weeks after extraction, plays almost as important a part in restoring the ultimate vision as the extraction of the lens itself. All after-operations should be done with great care, and under strict antiseptic precautions; and when so done, there is usually but little reaction following them. The gain in visual acuteness following a secondary operation is often very great.

1st. *Discision* or laceration of the posterior capsule is very often, perhaps in the great majority of cases, necessary, and almost never dangerous in the hands of a skilled operator. The best instrument for the purpose is probably the slender, sharp, curved knife-needle with cutting edge. This is plunged through the cornea near the limbus, on either side, wherever it seems most indicated, and the capsule is lacerated by a single vertical or transverse stroke of the blade, or if necessary the opening is made crucial. Under cocaine this may be done without the employment of fixation forceps, and thus all undue pressure on the eyeball is avoided. The difficulty and danger of the operation are of course proportionate to the density and position of the membrane to be divided. When it is possible, it is better to employ the electric light for this operation; for with this intense illumination the faintest cobweb of a capsule may be seen and readily lacerated. A capsule which has been thickened by the products of inflammation, such as is met with after iritis or irido-cyclitis, cannot safely be approached in this way, and for such cases, we resort to the more serious operation of excision.

2d. *Excision* of a *piece* of *thickened capsule* or *pseudo-membrane*, which blocks the field of the pupil, and its *removal* from the *interior* of the *eye*, is a more serious operation. This class of cases should be studied with great care, before deciding upon what is to be done. When it has been decided that a piece of the capsule or pseudo-membrane must be removed, an incision should be made in the cornea near the limbus, and over that part of the membrane which it is proposed to remove. This incision may be made with a narrow knife, or a Beer's knife, or better still with a straight lance knife. If the membrane is very thick, the knife may be plunged through it from

the periphery towards the center, at the same time that the corneal incision is made. Sometimes by this manœuvre the thickened capsule gapes sufficiently to admit of decidedly improved vision, without the necessity of removing a piece of it. More often, however, this does not occur, and then the next step is to insert a Tyrrell's hook, catch and draw out a flap of the thickened capsule, and cut it off close to a wound in the cornea. Another way of performing this second step, is to introduce a fine pair of Wecker's knife-scissors through the corneal wound, and then excise and remove a triangular piece of the thicked capsule or membrane. This is decidedly a more difficult and dangerous operation than simple discision, as it may set up a fresh attack of iritis or irido-cyclitis, with subsequent closure of the opening made in the capsule by the knife, or somewhat rapid atrophy of the eyeball.

The manœuvre of opening the capsule with the point of the cataract knife while making the corneal section is not to be commended. It is the revival of a method practised many years ago by Wenzel and others, the capsule being split horizontally in the upper portion of the pupillary space. It was at that time claimed that it simplified the operation of extraction, by lessening the number of instruments required for the operation. It is not an easy manœuvre to perform, and may make an irregular and ragged corneal wound, thus protracting the healing process, and also rendering the wound more liable to secondary infection. If the capsule happened to be thick and tough, the point of the knife might fail to open it sufficiently, and there might be some danger of rupture of the suspensory ligament and partial dislocation of the lens. This manœuvre is very difficult if the pupil is narrow and the anterior chamber shallow, and the iris would almost certainly be wounded.

The difference between primary and ultimate vision is sometimes enormous, and the gain in the latter is due to the secondary operation. Moreover the ultimate vision after discision becomes even better as time goes on, and as the cloudiness of the vitreous, which follows the operation, clears up. Furthermore, it should not be forgotten that many cataractous eyes have a more or less unhealthy fundus. In almost all elderly people

there is more or less disease or degeneration of the choroid, and the more extensive the choroidal degeneration is, the more likely is the retina to be involved in the process. Such eyes would of course have a diminished visual acuity, entirely distinct from the loss of vision due to the presence of cataract. Hence we should not be surprised at the low degree of visual acuity in many cases after a successful extraction of cataract, and if the vision cannot be improved by careful correction of the existing astigmatism as well as the aphakia, we should look for the cause of the failure in some existing lesion or degeneration in the fundus.

A Comparison of the Advantages and Disadvantages of Simple Extraction of Cataract.

The *advantages* of simple extraction may be summed up as follows:

1st. If successful and without complication, it preserves the natural appearance of the eye—a central, circular, and movable pupil.

2d. The acuteness of vision, with the astigmatism carefully corrected, is somewhat greater than after the old operation.

3d. Eccentric vision and orientation are decidedly better than by the old operation.

4th. Small particles of capsule are much less likely to be incarcerated in the wound, and thus act as foreign bodies and excite irritation.

5th. It is a shorter operation in point of time, by reason of the absence of an iridectomy.

6th. As there is no iridectomy, there is little or no hemorrhage, and this may be considered a very decided advantage. How often do we see an operation for the extraction of cataract delayed, sometimes for many minutes, by extensive extravasation of blood from the divided blood vessels of the iris, often filling the anterior chamber and becoming coagulated. Many an operation has been interrupted, and the extraction of the lens postponed to a future day, because the hemorrhage from the iris was so profuse as to render the further steps of the operation well nigh impossible, until the blood in the anterior

chamber had been absorbed. If blood remain in the anterior chamber after the opening of the capsule and the extrusion of the lens, the coloring matter is frequently deposited in the lacerated capsule, and by its dark color interferes considerably with the ultimate vision.

The disadvantages of simple extraction are as follows:

1st. The technique of the operation is decidedly more difficult than that of the old operation. The corneal section must be larger, in order that the passage of the lens through it may be facilitated, as the presence of the iris acts as an obstacle to its passage. The section must be performed rapidly so as to avoid the danger of the iris falling on the knife and being wounded. This rapid passage of the knife across the anterior chamber renders it difficult to make the height of the flap an even curve, particularly when the incision is entirely in clear cornea, as it should be. The cleansing of the pupillary space and the posterior chamber is much more difficult than after the old operation.

2d. Posterior synechiæ, secondary prolapse, and incarceration of the iris are more frequently met with than after the old operation. The two latter may be largely avoided by making the corneal section, as before stated, in clear cornea and not in the limbus, which is too peripheral, and rather favors both prolapse and incarceration of the iris.

3d. The operation is not applicable to all cases. This objection, however, may be applied to all operations.

DISCUSSION.

THE PRESIDENT.—I have as yet adhered, in the main, to extraction with iridectomy, and still regard this method as the safer one for the majority of practitioners. Although I have to some extent performed simple extraction, my experience will not compare with that of the writer of the paper; and my objections are to be regarded as somewhat based on theoretical considerations. There are two points, often insisted on, that I should have been glad to have had Dr. Bull refer to at length. The one is the trouble encountered in clearing the pupil of cortical remains, a manœuvre so readily performed in presence of an iridectomy, so difficult of accomplishment over the limited

area afforded by an intact sphincter and with the impediment of a temporarily prolapsed iris.

The other point is the chance of a subsequent presentation of the iris between the lips of the wound. The operation may have passed off without accident, the lips of the wound left in perfect apposition, and no discomfort experienced by the patient during the healing process. And yet the first examination of the eye may reveal a serious prolapse. Should this examination have been deferred, as I have always believed is best, for several days, the prolapse may be impossible to replace and even difficult to excise. As I have said, it may occur without giving any warning and without assignable cause. Either then we must examine the eye early and often in a case of simple extraction, a practice to be deprecated; or we must, in my opinion, be prepared to face a serious complication, from which extraction with iridectomy is comparatively free.

It is true that we find operators of admitted skill and experience disposed to minimize this danger, and to deny the frequent occurrence of prolapse. My own somewhat limited observation leads me to disagree with them, and confirms me in the belief that the average surgeon will obtain a larger percentage of success if he performs extraction with iridectomy on the average patient.

DR. SAMUEL THEOBALD, of Baltimore.—Dr. Bull speaks of removing the speculum and proceeding to manipulation. Does he use fixation forceps when making the manipulation? My own experience with extraction without iridectomy is very limited, but it has been very satisfactory. It has occurred to me, and I have put the idea in practice in a few cases, that it would be well to instill eserine before the actual steps of the operation are begun. It should not be put in soon enough to cause the pupil to contract before the extraction of the lens, but I have instilled the eserine when applying the cocaine, so that in some measure it counteracted the dilating effect of the latter. The action of the eserine in this way gets a little start, so that when the operation is completed the pupil shows some tendency to contraction, and there is less difficulty in causing the iris to return into the anterior chamber, and the pupil to regain its central position. If the eserine were instilled too long before the operation, the contraction of the pupil would, of course, prove a serious obstacle to the removal of the lens.

DR. CHARLES S. BULL, of New York.—I use no forceps whatever for the fixation of the eye.

DR. HENRY D. NOYES, of New York.—I have done the linear extraction of cataract to a considerable extent in the last

three or four years. I cannot say in how many instances, for I have not consulted my records. Without being able to offer any positive conclusions, I may give certain general impressions.

It is absolutely true that one must make a selection of cases suitable for this operation. These are those in which an easy extraction is to be anticipated, from the denseness of the lens, the dilatability of the pupil, the general healthfulness of the eye, and the probability of being able to control the patient. These conditions are all of importance.

The performance of the operation is in a certain sense more difficult so far as the section of the cornea goes, as compared with the operation with iridectomy. This is, however, pretty well counterbalanced by the fact that in certain cases we find the iridectomy the most difficult part of the operation, now that we use cocaine which does not remove the sensibility of the iris. If you employ cocaine, you must notify the patient that there will be a painful period in the operation. That circumstance must be taken into consideration as in favor of simple extraction against extraction with iridectomy.

The extraction of the lens is naturally more difficult where the pupil is small, and the possibility of prolapse of the iris is the circumstance against which we have the chief apprehension. I may say that with a larger experience this mischance has grown less and less frequent both primarily and secondarily. I think that the suggestion that the wound be made in the clear cornea is perfectly sound. It is a precaution which I have more and more set before myself; nevertheless it happens sometimes that one fails to bring the wound into the clear cornea as far as intended, and under these conditions you are more liable to prolapse. I have found no difference in the rapidity of the healing process, but secondary prolapse of the iris has occurred less frequently than formerly. Secondary prolapse is favored by two things: first, an irregularly-made wound, and second, a not well-controlled or an ill-behaved patient, as you are at his mercy during the first twenty-four hours.

On the whole, I have been more and more disposed to resort to the operation without iridectomy. In regard to results, there are two things that may be referred to. In the first place, the amount of astigmatism after the operation without iridectomy is greater than after that with iridectomy. This may be due to the lower position of the wound coming nearer to the axis of vision, and to the fact that it partakes more of a flap character. In the second place, in the disposition of the capsular opacities, I am satisfied that there is much more difficulty in doing secondary operations where you have a circular pupil than

where there is a coloboma. One reason of this difficulty is that the adhesions which may have formed between the iris and the capsule prevent the full effect of atropine, and the operation has to be done through a small pupil. This necessarily gives only a limited space for your lever-like movements. It has consequently occurred to me that I have been obliged to use two needles instead of one. When the capsule has become thickened to an important degree, I have in a number of instances resorted to an old and abandoned method. One such case occurred in the past year. The patient was very myopic and quite deaf, so that she had to be communicated with by an ear-trumpet. The capsule was considerably thickened. This was operated on four months after the original extraction. In this instance I attempted to divide the capsule through the cornea with a narrow-bladed knife, but failed to do so satisfactorily. I then introduced a needle behind the iris through the sclera. I am satisfied that this method which comes to us from old ophthalmic surgery is a method which we can use to material advantage at the present day. With antiseptic precautions it is not attended with such risks as we should expect, from our having to go through the inner vascular tunics of the eye. It gives a larger space in which to work, it gives a more advantageous leverage, and enables you to divide obstructions in the pupil with more certainty. These are some of the points which occur to me in reference to the matter to which attention has been called in this interesting paper.

May I append to these remarks an experience which has occurred within the last year, bearing upon the question of infection of the eye after extraction? I had occasion to operate on a very delicate woman who was also myopic. It was desired that the operation be done at the house instead of sending her to a hospital. When I entered the room I was saluted by an extremely unpleasant odor due to sewer contamination. I ventilated the apartment as thoroughly as possible by opening the windows. I gave extraordinary attention to the cleansing of the eye, and to the performance of the operation, resorting to the most rigorous antiseptic precautions from beginning to end. The operation was done without any misfortune, and the woman behaved very well under cocaine. She was put to bed, and it was necessary to give her an anodyne for nervous irritability. In twenty-four hours reaction commenced. It did not begin in the external lips of the wound. It began about the inner lip of the corneal section, and presented itself in the form of an exudation, running down the surface of the iris, until the anterior chamber was largely occupied with inflammatory exudation. I

speak of this as a clear case of infection due to unfavorable hygienic conditions because on examination it was found that the wash-basin in the room had no trap on the sewer pipe. It may be asked why I performed the operation under these circumstances? I hoped by rigorous antisepsis and what I did towards purifying the atmosphere immediately about the patient to escape infection, and that keeping the eye bandaged under wet bichloride dressings would be a sufficient guarantee. This hope proved erroneous. By the continuous application of water at a temperature of 100° to 114° Fahrenheit, all the exudation was absorbed, and she now has perception of light. I expect in two or three months to perform a secondary operation which will give vision sufficient to justify the performance of the original operation.

THE PRESIDENT.—What is Dr. Noyes's experience in regard to the relative difficulty of clearing the pupil in the two operations?

DR. NOYES.—It is more difficult to clear the pupil in simple extraction than where iridectomy is performed. Irrigation of the anterior chamber is a necessary adjunct to this operation. If you depend upon mechanical means you will find yourself in great trouble. Whereas, a small stream of water projected upon the wound will satisfactorily remove the cortical substance, although it is true that a certain amount of material may remain in the peripheral portion of the posterior chamber. In the majority of cases it removes all matter, and it forces back into the anterior chamber any fragments of the capsule which may incline toward the anterior wound. The solutions used should be either boiled water or a saturated solution of boric acid in boiled water, used warm. It should never be the bichloride solution. I made experiments with the bichloride solution several years ago. I found that it not only caused opacities of the posterior surface of the cornea, but also made scale-like opacities which were permanent, being due to irritation of the endothelium or membrane of Descemet.

DR. T. R. POOLEY, of New York.—There is one step that I consider important in the relief of dense capsular membrane where iridotomy is done. I did not follow the doctor so closely as to be sure whether or not he mentioned the importance of cutting the sphincter edge of the iris. This should be done in making iridotomy.

Another thing is that after the horizontal wound has been made in a dense capsular membrane and the hook introduced, in many instances it will not be necessary to drag the membrane into the wound or to cut it off. Simple traction serves to enlarge the wound sufficiently to get good sight.

DR. O. F. WADSWORTH, of Boston.—My personal experience with simple extraction is so limited as to be hardly worth referring to. But I wish to mention an impression that I have received from almost everything that has been written on this subject. The advocates of the operation seem to have, to a certain extent, gauged its merits by comparing a series of cases which were selected, with the general run of cases operated on by other methods. As Dr. Noyes has said, the cases suitable for this operation are those where you can control the patient, where the iris is healthy and dilatable, where the lens is firm, and is likely to come out readily. Yet these are the cases which are likely to do well under any method of operation. Looking at the matter as an outsider, so to speak, it seems to me that the fact that selected cases have been chosen for this operation, and cases as they run for the other operations, has not been given sufficient weight.

DR. R. A. REEVE, Toronto, Can.—What has surprised me during the last few years in the reports of cases of simple extraction is that gentlemen are able to do their operations continuously by this method. In my experience there are cases in which this simple method is not proper. My rule is to instil a four per cent. solution of cocaine twenty or thirty minutes before the operation, repeating the instillation two or three times at intervals of five minutes, keeping the eyelids closed. If at the end of this time the pupil is not dilated I consider that iridectomy is indicated in that case, for if it is not done extraction of the lens will be rather difficult. In cases where there seems to be a good deal of soft cortex, I should consider the simple operation less advisable than the operation with iridectomy.

In regard to the tendency to prolapse produced by the to-and-fro movement necessary with the narrow knife, I would say that I have been extremely gratified with the nature of the incision made by the knife introduced by Dr. Edward Jackson. Except in cases where the eye is deeply placed and the orbit narrow, this knife makes the beau ideal incision with the minimum risk of injuring the iris.

If I may be permitted to criticise one who has operated so often, I would say a word in regard to one point. The reader spoke of cleansing the lids and flushing the conjunctival sac, but I did not understand him to lay special stress upon the necessity for cleansing the edges of the eyelid. It strikes me that it is more important to cleanse the edges of the eyelids than even the eyebrows or the eyelids. After instilling the cocaine I wash the parts and the edges of the lids with absolute alcohol, not allowing any to run into the cul-de-sac. I also

wash the instruments, as well as the tips of the fingers, with absolute alcohol. The instruments are kept in absorbent cotton saturated with alcohol until needed. My experience with cases done during several years is that prolapse of the iris is more common, and always occurs at the summit of the wound, which, I think, takes away the objection that the reader makes to incision in the limbus.

I should like to refer to what Dr. Theobald said in regard to the instillation of eserine before operation. I tried that several years ago in a number of cases where I expected that the extrusion of the lens through the pupil would be readily effected. I found that the contraction of the pupil interfered with the extraction of the lens, and I have ceased to use solution of eserine before making the section. Instillation after the removal of the lens, I think effects all that is desirable.

DR. J. S. PROUT, Brooklyn.—Dr. Michel's suggestion, as I recollect it, was to use the *taffetas français*, which I have tried, but the American skin plaster is equally good. Patients have not complained of irritation from it, but it is sometimes difficult to make it adhere on account of its lightness and general stickiness. To remove it from the lids it is simply necessary to moisten it with water. For this reason no medicated solution can be used while it is in place. To overcome this objection in a recent case of simple extraction, in which there was chronic conjunctivitis, I closed the eye by means of a stitch, and then directed frequent instillations of a weak solution of the bichloride of mercury in alternation with a weak solution of eserine. The other eye was closed by means of the plaster as usual. The patient was allowed to sit up during the day. The stitch caused no irritation whatever, and was removed in about four days. The result was good. In this connection I would like to recommend the use of the stitch in similar cases, and also in injuries of the eye, especially in young children, in whom, when the cornea is injured, it is so important and so difficult to keep the eye quiet. While the stitch is in place medicated solutions can be instilled without disturbing the eye, which, at the same time, has the constant support of its natural covering or splint—the properly curved tarsus—thus keeping the edges of the wound in more accurate apposition than can be otherwise secured. I thoroughly believe that no matter how skillfully it may be applied the bandage makes its greatest pressure on the center of the cornea, and therefore tends to produce unequal apposition of the lips of the extraction-wound. Then, again, all of us no doubt have noticed that the bandage worn for several days sometimes causes conjunctivitis in old eyes. For these rea-

sons the suggestion of Michel to dispense with the bandage and close the eye after cataract extraction by means of this delicate plaster met with my hearty approval. Its only drawback was the fact that the eye was not sufficiently protected from accidental injury by the patient's own hands, a difficulty that the use of a wire mask (suggested to me by my friend Dr. Skerry of Brooklyn, at the time the house surgeon of St. John's Hospital), has in very large degree removed. This mask consists of a piece of wire netting, such as window-screens are made of, about three inches wide, and long enough to reach from temple to temple, from which a triangular piece is removed, so as to prevent disagreeable pressure on the nose. This also assists in keeping the mask in place. The cut edges are bound with wide tape to protect the skin, and at each corner are sewed narrow tapes which are to be passed round the head and tied at the temple. This mask stays well in place, does not annoy the patient as much as a bandage in warm weather, and can be removed and replaced without causing any necessary movement of the head. A recent writer in the *American Journal of Ophthalmology* has suggested the use of pasteboard for the same purpose. The wire mask is lighter, cooler, and can be more easily made and adjusted to the face. When the eyes are prominent the wire over them can be readily made convex, so as to obtain a space of half an inch between them and the mask, which is stiff enough to prevent injury from ordinary movements of the patient's hands. The use of this mask renders Michel's suggestion complete, and, with the occasional use of the eyelid stitch, will, it is hoped, be found a useful contribution to eye-surgery.

DR. LUCIEN HOWE, of Buffalo.— Two years ago, Dr. Prout mentioned this method of dressing to me. Since then I have used it most satisfactorily, especially if, before making the application, the lashes are cut off. It does simplify matters a great deal. Secretions can be removed more readily.

As to the method to be selected, I think that in deciding this we could well ask ourselves the question which Critchet asked Wecker, "If that were his own eye or his father's eye, which method would he choose?"

DR. HENRY D. NOYES, of New York.— I have grown very much in favor with the use of a cotton pledget soaked so thoroughly in a bichloride solution that it remains moist for several hours. Where chronic conjunctivitis exists and there is fear of infection, I have kept the pledget wet continuously until I saw fit to remove the bandage. That of course prevents incrustations and retention of secretion. I know that I have brought myself out of much trouble by the use of this simple measure.

DR. SAMUEL THEOBALD, of Baltimore.—I would ask Dr. Noyes whether he agrees with Dr. Bull in regard to the efficacy of weak solutions of eserine. I should also like to know his practice in regard to the instillation of atropia. He speaks of posterior synechia and extensive adhesions. Does he use solutions of atropia, and of what strength?

A better plaster than the isinglass has been introduced recently, which I have used with advantage. This is the gelato plaster. It is softer than the other plasters, does not become stiff, and is, therefore, more comfortable. One objection may be that it does not become stiff enough, and so does not afford the splint-like support to the lids which the stiffer ones do. I have had no irritation from the plaster, although I have used it exclusively for some months.

Dr. R. A. REEVE, of Toronto, Can.—I would ask Dr. Noyes whether two drops of a solution of eserine stronger than one

In Dr. Prout's remarks on Dr. Bull's paper on "*Simple Cataract Extraction*," the words: "A recent writer in the *American Journal of Ophthalmology* has suggested the use of a pasteboard mask for the same purpose," the fourth sentence from the end, are to be stricken out, and the following inserted in their stead: Dr. Gifford, in the *Archives of Ophthalmology* (xix. 1, p. 42,) has suggested and figured a pasteboard mask for the same purpose.

by Dr. Bull, viz.: the importance of removing the speculum before the extraction of the lens. I think that in some cases it is desirable to remove it before using the cystotome. In one case of milky cataract, when I put the cystotome in, the contents poured out with such rapidity that the posterior capsule, coming in contact with the instrument, was ruptured, and fluid vitreous spurted out of the eye before the speculum could be removed.

The other point is the resulting acuity of vision in the two operations. It seems to be universally claimed that the simple operation is followed by better vision than the combined. I have not seen this claim substantiated by statistics. I have recently reported the results of fifty-three cataract extractions, in which a preliminary iridectomy had been made. In twenty-six cases vision was 20/xxx or over. This result was reached without secondary operation except in one case.

The causes of the imperfect vision in the cases showing 20/xl or under, were atrophy of the optic nerve, choroidal atrophy, opacity of the cornea or of the vitreous, and opaque capsule. The latter was found in only seven of the fifty-three cases. Secondary operation, therefore, was indicated in only a small proportion of the cases. Dr. Bull has stated that secondary operations were necessary in two-thirds of his cases. Dr. Knapp's experience is similar. Both of these operators find the risks of operations on the capsule insignificant in comparison with the advantages which accrue; but there are other distinguished surgeons who consider these operations dangerous in a high degree. I think it will be granted that any method which reduces the number of cases requiring a secondary operation is advisable. At least this is an element which is to be taken into account in deciding upon the operation to be performed.

I should add that I attribute a great deal of the want of opacity of the capsule and the absence of necessity for secondary operations to the fact that in these cases I have used thorough irrigation of the anterior chamber. I do not confine myself to irrigation from without; I introduce the nozzle of the syringe into the anterior chamber, and wash away every portion of loose cortical substance. Where masses of cortical stick to the pupil edges, the nozzle of the syringe may aid in separating them.

Another point in regard to syringing is, that it spreads apart the lips of the wound in the capsule, and leaves a large space absolutely clear, so that in these cases we can afterwards study the details of the fundus as well as if the eye had never been affected with cataract.

DR. GEORGE C. HARLAN, of Philadelphia.—The elevator is, I think, much safer than the spring speculum in this operation. In regard to the rapidity of the incision, with the view of preventing prolapse of the iris, I think that is important. I was much struck by the method of operating of Trousseau of Paris. He used no speculum and no fixation. The operation was done with greater rapidity than I have ever seen before. The incision consisted of a plunge and an upward dash. In the three or four cases on which I saw him operate there was no disposition to prolapse of the iris, and the pupil was round immediately after the operation.

DR. CHARLES S. BULL, of New York.—In regard to the danger of secondary prolapse or incarceration, the result of my experience has been to make me confident that the reason I have had so very few cases of secondary prolapse is because I operate on patients in bed where they are to remain, and because the whole length of the wound is in clear cornea.

In regard to corneal astigmatism, I mentioned that corneal astigmatism from this operation was greater than from the old peripheral linear operation. This in the horizontal meridian may amount at first to 6 D. But I have seen this decrease in one month to 1.5 D. from cicatrization and flattening of the wound.

In regard to the charge of Dr. Wadsworth, that these operations were done on selected cases, I would say that in the first one hundred cases the operation was done on every case successively. Since then I have preferred to select my cases. I have never taken the view that the Graefe extraction has been on its trial, and that the simple extraction is its competitor.

Dr. Pooley suggests that in exsecting a piece of membrane an incision be made in the sphincter margin. This I have done. I have not thought it safe to trust to pulling aside the edge of the opening, but I prefer to cut out a piece.

In reference to antiseptic precautions, I statedly distinctly that in preparing the patient I cleansed the surface and edges of the lids with a solution of bichloride of mercury, and that I consider it necessary. It is more important to clean the ciliary margin than the external cutaneous surface. The instruments are boiled in water and kept in absolute alcohol, and removed as wanted.

It has been my experience that in these simple extractions, the necessity for secondary operation is no more frequent than after the operation with iridectomy. In the great majority of cases of extraction it is necessary to do a secondary operation, usually merely a discision. In regard to irrigation, I make a distinction between irrigation of the anterior chamber and irrigation of the corneal wound. The latter I always use. It has been my experience in these 160 cases, that it has been rarely necessary to use irrigation of the anterior chamber, that is the introduction of some instrument into the corneal wound to convey the irrigating fluid.

DR. CHARLES E. RIDER, of Rochester.—Thus far I have not practiced simple extraction of cataract. I have seen it done by my son several times, and have seen the results, and they have been satisfactory. It seems to me that the best method of extracting cataracts is that which gives the smallest number of total failures. To illustrate: if there are two operations, one giving ninety-five per cent. of good successes, and five per cent. of total failures, the other giving ninety per cent. of brilliant results, and ten per cent. of losses, I should choose the former. It is desirable to get these brilliant results that we get from successful simple extraction, but it seems to me that

the number of cases has not been sufficient, nor have they been analyzed with sufficient exactness to enable us to determine anything definitely. I am watching this matter with interest. But having learned to do one operation satisfactorily to myself, I hesitate to make any changes.

One objection which has been made to the operation with iridectomy is the pain of cutting through the iris. I have obviated this by injecting a solution of cocaine on the iris before doing the iridectomy. This benumbs the sensibility of the iris to such an extent that the operation can be done without any great discomfort.

THE EXTRACTION OF LENSES DISLOCATED INTO THE VITREOUS HUMOR.

By CHARLES STEDMAN BULL, M.D.,

NEW YORK.

Since the publication of the recent papers by Drs. Agnew, Webster, Pomeroy, and Knapp upon the subject of the extraction of lenses dislocated into the vitreous, the writer has collected a number of cases of this nature due to traumatism, which have been operated upon by himself during a period of several years. The histories in detail of the following thirteen cases, with some remarks upon the method of operating, are now presented to the Society for their consideration. The interest excited by a description of the method devised by Dr. Agnew, with an instrument, the bident, invented by himself, has not sufficed to conceal from the mind of the writer the real value of the objections raised against the use of this instrument. None of the cases described in detail in this paper were operated upon by the bident, and the writer has had no personal experience with the instrument. No very great difficulty has ever been experienced in attempting to remove lenses dislocated into the vitreous by the methods hitherto in general use, and in none of the cases here reported have any bad results followed. The extraction of a lens from the vitreous is a more or less difficult operation, and any case may very well differ from all

others in some minor points, which, taken together, make it complicated. The more serious the traumatism has been, and the greater the resulting disorganization of the eye, the more difficult will be the operation for the removal of such a dislocated lens, and the more serious the possible accidents during the operation. The writer's experience is in accord with that of Dr. Knapp, who believes it possible "by external manipulation to extract lenses dislocated and swimming in the vitreous without accident and with preservation of the natural pupil." Not only is this true with regard to lenses entirely dislocated and floating freely in the vitreous, but the same remark may be applied to partially dislocated lenses, and to lenses floating in the vitreous but attached at some point to the ciliary processes. The writer believes it possible in many cases, perhaps in the majority, to extract the lens by external pressure, and to confine the use of instruments to assisting in the removal of the lens after it has presented in the wound, or at least in the field of the pupil. Of course in each case the possible difficulties are an unknown quantity, and the blunt hook, the delicate wire spoon, or the broad silver spoon, should be ready at hand to use in case of necessity. The manipulation which the writer has found useful in this operation may be described as follows: The eyelids are held open by the ordinary wire-speculum, and the corneal section is made upward with the narrow knife, the ends of the incision being in the limbus and the apex in clear cornea, just below the limbus. The speculum is then removed, and the upper lid is lifted up and away from the eyeball by the finger of an assistant, or better by a wire elevator held by an assistant. Pressure is then made upon the lower part of the eyeball with the thumb or finger of the operator, by pressing the lower lid against the eye directly *backwards.* Almost immediately the lens will be seen to rise and appear in the field of the pupil, and in not a few instances comes partially through the pupil and engages in the wound. Sometimes the assistance of a blunt hook or the wire spoon becomes necessary to complete the removal of the lens at this stage of the operation. If continued pressure backwards fails to push the lens through the pupil, or causes a prolapse of the vitreous, it should be dis-

continued, and the lens removed at once by hook or spoon. It is surprising to see how often a dislocated lens is removed by this simple pressure *backwards*, without the introduction of any instrument into the eye. If a criticism may be passed upon the use of the bident by one who has never used it, it would be that the objections to its use raised by Dr. Knapp are just. The sclerotic and ciliary region are pierced in four places by the teeth of the bident, and after the lens is extracted, both aqueous and vitreous chambers being open, this instrument must then be withdrawn. Another objection to its use is that it decidedly complicates the operation by adding one more to the number of instruments necessary to the operation, and by the introduction of this instrument inside the eye, where it must remain until the lens has been extracted.

CASE I.—Patrick McD., aged 75, June 3, 1878. Has had gradually failing vision in both eyes for several years. One month ago received a severe blow on the left eye, and lost the sight in this eye at once, and since then he has had only perception of light. There have been occasional attacks of pain. R. E. 20/70; partial opacity of lens—sluggish iris—senile degenerative choroiditis.

L. E. perception of light. Pupil irregularly dilated and iris immovable. Iris discolored and fluttering. Lens dislocated downwards into the vitreous, entirely opaque, and floating free. Tension + 1.

It was determined to attempt the removal of the dislocated lens. This was before the days of cocaine, and the patient declined to take ether. The patient was placed on his back in bed, and the lids were held open by a wire speculum. The eye and cul-de-sac were carefully washed with a warm saturated solution of boracic acid. The eyeball was then seized with fixation forceps, and an upward corneal section with a narrow Græfe knife, the ends of the section being in the limbus and the apex in clear cornea. The speculum was then removed, in the course of which the lens presented in the pupil, which was a fortunate accident. A blunt hook was then carefully introduced through the corneal wound, hugging the upper segment of the iris, and passed slowly behind the upper presenting

margin of the lens. By a sudden delicate twist, the blunt point of the hook penetrated the lens capsule, and the lens was at once lifted through the pupil and corneal wound and removed from the eye, followed by a small amount of vitreous. The cornea at once collapsed, and as a consequence the wound gaped. Atropia was instilled and a bandage carefully applied. The prolapsed iris had replaced itself as the cornea collapsed. Much of the success of this operation was due to the extraordinary self-control of the patient, who lay perfectly still, with an immovable eye, until all was over. The eye was dressed daily, but the wound remained open for a long time, and did not entirely close for nearly a month. There was no improvement in vision, probably owing to the effects of the contusion. This patient subsequently underwent an operation for the extraction of cataract in the right eye three years later, and recovered useful vision of 20/70.

CASE II. — Henry H., aged 65, December 16, 1878. Twenty years before this patient had received a violent blow on the right eye, which caused complete dislocation of the lens into the vitreous. The blow destroyed the sight at once, and nothing more than perception of light has ever been regained. Attacks of intraocular irritation have appeared at irregular intervals, but subsided after a few days of treatment. Two weeks ago an unusually severe attack began with much pain, and has continued ever since.

R. E. perception of light. Marked ciliary injection and photophobia; Iridodonesis. Large opaque lens floating in the vitreous.

L. E. 10/200, cataract. Field and projection normal. The patient was etherized, a speculum was introduced, and the eye and cul-de-sac carefully irrigated with a saturated solution of boric acid. The eye was then held by fixation forceps, and an upward corneal section was made with a narrow knife, entirely in the limbus. The speculum was then removed and an attempt made by pressure on the eyeball backwards through the medium of the lower lid, to bring the lens into the pupil. This partially succeeded, but vitreous presented in the wound in front of the lens. A wire spoon was then introduced through

the wound, and through the pupil into the vitreous behind the partially presenting lens, and at the first attempt the lens was extracted intact in its capsule. Scarcely any vitreous was lost in the operation. The prolapsed iris was stroked into place in the anterior chamber with a spatula, a drop of eserine solution was introduced, and the eye carefully bandaged. The operation was done on this patient while he was lying on his back in bed. The eye made an excellent recovery, and the signs of ciliary irritation soon subsided.

CASE III. Jane K., aged 23, October 6, 1880. Patient has had defective vision from birth, with nystagmus and great intolerance of light. Repeated attacks of inflammation in both eyes. For the past two months the *right* eye has been extremely painful and continually inflamed.

R. E. 1/200. Hazy cornea with numerous depressions from old ulcers. Congenital aniridia. Lens, dislocated downwards and inwards into the vitreous, but still attached by two bands to the ciliary processes downwards and inwards, the remains of the suspensory ligament. Lens opaque.

L. E. 5/200. Congenital aniridia. Opacities in lens and capsule. No dislocation of the lens.

Owing to the dangerously inflamed condition of the right eye, the patient was advised to have this eye enucleated, but this she declined, and it was then decided to attempt the removal of the lens. The patient was etherized and a speculum introduced. An upward corneal section was made, the ends being in the limbus and the apex in clear cornea. Much to my surprise, the lens presented at once in the wound, accompanied by a little vitreous, and was readily removed by the wire spoon, with a very slight loss of vitreous. The eye and lids were then carefully and gently irrigated with a solution of mercuric bichloride (1/5000) and an antiseptic bandage applied. This bandage was left undisturbed for three days, and was then removed. The lids looked well, and there was no discharge of any kind, so the eye was not opened, and the bandage was reapplied and left on for forty-eight hours longer. At the end of this period it was removed, the eye was examined, and the corneal wound ound entirely closed. There was still considerable ciliary

injection and irritation, which was treated by atropia and dark glasses, and soon subsided. At no time was there any irritation of the fellow eye.

CASE IV. James B., aged 68, January 28, 1884. Patient has had failing vision in both eyes for some years. Three months before he received a violent blow on the right eye from a potato, which for a time completely abolished the vision. After about a week he began to regain sight, and it has steadily improved since.

R. E. 1/200, with sph. + D 12 = 2/40: Widely dilated pupil. Lens opaque and floating freely at the bottom of the vitreous. Tension + 1.

L. E. 20/200. Cataract.

On February 13th it was decided to attempt the removal of the lens which remained in the vitreous, and could not be induced to fall into the anterior chamber by any change of position or manœuvre. The patient refused to be anæsthetized, and the operation was performed while the patient was seated in a chair. The eyeball was opened by corneal section upwards, the apex in clear cornea, and made with a narrow knife. The speculum was then removed, and pressure was made upon the lower portion of the eyeball with the thumb and index finger alternately through the lower lid, directly backwards. This caused a lifting upwards and forwards of the lens, and at the same time produced a slight gaping of the lips of the wound. As this pressure was continued, its direction was changed slightly from backwards to backwards and upwards, and as the lens rose and came forward through the pupil, a blunt hook was introduced through the lips of the wound, engaged in the lens, and the latter was lifted out of the eye in its capsule without the slightest difficulty. It was followed by some fluid vitreous. The cornea collapsed, but the patient complained of no pain. The usual antiseptic dressings and bandage were applied and remained unchanged for two days. The case did well, there being no adverse symptoms, but the wound healed very slowly, and it was nearly a month before the anterior chamber was re-established. The ultimate vision in this eye was 20/50 with sph. + D 12.

CASE V. — Margaret W., aged 22, May 5, 1884. Patient was struck a violent blow with the fist on the left eye six days before, and vision was lost at once. Since then there have been at times attacks of severe pain.

R. E. 20/20. L. E. perception of light. Small amount of blood in anterior chamber. Iridodonesis, Traumatic irido-choroiditis. Lens dislocated downwards and backwards into the vitreous. Blood in the vitreous. Tension + 2.

On May 28th all the blood was gone from the anterior chamber, and most of the signs of acute inflammation had subsided under the influence of cold applications and atropia. But the tension remained above normal, and there was at times considerable pain, and the removal of the lens was deemed advisable. The operation was done with the patient lying on her back in bed, the incision being the usual corneal section upwards made with the narrow knife, the apex being in clear cornea. A small bead of vitreous presented in the wound on the withdrawal of the knife, and the speculum was removed at once and the lids closed. After a lapse of five minutes the lids were opened, and the upper lid raised by a wire elevator. Gentle pressure directly backwards was then made on the lower portion of the eyeball through the lower lid with the finger, and this soon brought the lens into the field of the pupil; but any attempt to force it through the pupil towards the wound increased the prolapse of the vitreous. The elevator was then given to an assistant to hold, and a wire spoon was introduced through the wound through the pupil and behind the presenting upper margin of the lens, and the latter was then easily lifted out, without any further loss of vitreous. The eyeball and cul-de-sac were gently irrigated, and the lids closed under the usual antiseptic dressings. The case did extremely well, no unusual reaction of any kind occurred, and the patient was discharged at the end of the third week with a perfectly quiet eye. The vision, however, was not improved.

CASE VI. — Moses G., aged 45, June 22, 1885. Patient has always been very myopic. He lost the sight in the left eye sixteen years before by a blow from a stick, and the eye was inflamed and painful for several months after the injury. Since

then there have been repeated attacks of inflammation in the left eye, the present one having begun one week ago, and the sight of the fellow eye has steadily failed.

R. E. fingers at 6 feet — myopia — cataract. L. E. perception of light. Lens opaque, dislocated downwards and backwards completely, and floating freely in the vitreous. Iridodonesis. Divergent squint. Marked ciliary injection. Tension + 1. The patient was advised to have the eye enucleated, but positively refused to allow it. It was then proposed to him that an attempt should be made to remove the lens, and to this he consented. Owing to the existence of pronounced valvular and hypertrophic disease of the heart, it was thought unwise to administer any anæsthetic, and the operation was done with the patient seated in the operating chair. The usual upward section was made in the cornea, the apex being in clear cornea. The iris prolapsed at once, and this apparently prevented a prolapse of the vitreous. Owing to the complete disorganization of the vitreous, it seemed as if any pressure from below would cause extensive prolapse of the fluid vitreous. The prolapsed iris was therefore carefully replaced, and a wire spoon was then gently introduced through the wound and pupil, and behind the lens. Slight pressure backwards against the lower part of the eyeball brought the lens into the hollow of the spoon, and it was then readily removed, followed by a prolapse of the iris. Gentle irrigation of the iris and eyeball was then done, the iris was replaced, and a pressure bandage applied for twenty-four hours. The ciliary irritation and injection in this case remained for nineteen days without any visible improvement, after which date the case healed in the usual manner, but with incarceration of the iris. There was, of course, no improvement in the vision.

CASE VII. — Francis E. R., aged 23, November 12, 1885. Patient had lost the sight of the right eye twelve years before by a blow from a ball, but since then it had given him no trouble, except from a cosmetic standpoint. He had been advised to have the eye removed, but his father was unwilling to permit it. At times the opaque, dense white lens would appear in the pupil, and caused an unsightly appearance.

R. E. perception of light, cornea somewhat cloudy. Iridodonesis. Lens opaque, dense white in color, and floating in the clear vitreous, but attached at one point downwards and outwards to the ciliary processes. Tension normal. No irritation.

L. E. 20/20. Normal in every respect.

The operation was done on the patient while seated in the operating chair. The usual upward corneal section was made with the narrow knife, apex in the clear cornea. The speculum was then removed and the upper lid lifted away from the eye by a wire elevator. Pressure was then made with the index finger through the lower lid on the lower part of the eyeball, directly backwards, and the lens at once rose and came forward into the pupillary area. As the pressure backwards was continued, the point of adhesion downwards and outwards ruptured, and the lens at once came almost entirely out of the corneal wound and was received in a small silver spoon. The iris of course prolapsed, and several drops of vitreous followed. The iris was then replaced, and the eye antiseptically dressed and bandaged. There was no reaction, and the wound healed throughout in three days, without any prolapse or incarceration of the iris. The loss of vision of course remained unchanged.

CASE VIII. — Nicholas E., aged 56, February 18, 1886. Patient was struck in the right eye by a ball three weeks before.

R. E. 9/200. Irregular and immovable pupil. Partial dislocation of the lens upwards and inwards. Lens entirely opaque. Zonule only partially ruptured.

L. E. 20/100. Senile choroiditis and beginning cataract. The irritation caused by the blow was still intense, and as the lens was entirely opaque and partially displaced, it was decided to remove it. An upward section was made entirely in the limbus, and then an iridectomy was made upwards in the usual manner. The pressure made upon the eyeball by the fixation forceps had caused a partial rotation of the displaced lens upon its vertical axis, and it was thought that it might be removed in its capsule. A small wire spoon was introduced through the wound and coloboma of the iris on the temporal side of the lens, and a slight lifting motion brought the lens away in its capsule, and it was removed from the eye without the loss of any vitreous. This

may be considered a fortunate termination to a rather dangerous operation. The ultimate vision was somewhat improved, having risen from 9/200 to 20/200.

CASE IX. — Mrs. Catharine S., aged 44, July 12, 1886. This patient was struck on the right eye four days before by a piece of wood, and had lost her sight at once. She had had failing vision in both eyes for some years.

R. E. fingers at 6 inches. Iridodonesis. Blood in the anterior chamber, and vitreous. Lens opaque and dislocated into the vitreous.

L. E. 20/200. Old choroiditis and opacities in lens and vitreous. Nearly three months later the right eye was still injected and painful, and, as she refused to have an enucleation, it was thought best to remove the lens.

October 11th. The usual upward corneal section was made, but owing to the ciliary injection an iridectomy was not done, on account of the possibly profuse hemorrhage. Pressure upon the lower portion of the eye directly backwards threw the lens at once into the pupil, and at the same time caused prolapse of the iris and the loss of some fluid vitreous. As the pressure, however, kept the lens presenting in the pupil, a blunt hook was introduced through the wound and behind the lens, thrust into the lens, and the latter was then readily removed in its capsule, without any more vitreous being lost. The iris was then replaced, and the eye dressed and bandaged in the usual way. The irritation and injection began to subside on the fifth day, and the patient was discharged on the thirty-first day, with a round, central pupil, and vision = 20/200, with some prospect of still further improvement.

CASE X. — John S., aged 27, February 7, 1887. This patient had been struck on his *left* eye three years before by a clod of earth, and lost his sight immediately. The eye was inflamed and painful for nearly two months, but since then has given him no trouble.

R. E. 20/30+, faint corneal macula.

L. E., V=0. Tension—1. Discolored and fluttering iris. Pupil central. Lens opaque and floating freely in the vitreous,

attached by a single narrow filament downwards to the ciliary processes.

March 4, '87. The usual upward corneal section was made, the patient being seated in the operating chair. As the knife completed the section and the aqueous escaped, the lens presented in the pupil, the upper margin nearly touching the cornea. A blunt hook was at once introduced, engaged in the lens, and the latter was removed in its capsule without the slightest difficulty. The prolapsed iris replaced itself at once, and not a single untoward symptom appeared in the course of of the case, the patient being discharged on the fifteenth day.

CASE XI.—Daniel F., aged 64, April 4, 1887. This patient was struck one month ago on the right side of the nose and superior orbital margin of the right eye with a stone. The right eye became inflamed at once and has remained so ever since, with frequent attacks of very severe pain.

R. E. 3/200. Marked ciliary injection. Tension + 1. Iris dilated and discolored. Very shallow anterior chamber. Lens opaque and dislocated into the vitreous. Condition glaucomatous.

L. E. 20/20—. Slight opacity at periphery of lens. Normal fundus.

April 6th. Operation for removal of the lens. Corneal section upwards entirely in the limbus. Broad iridectomy upwards, followed by profuse hemorrhage which filled the anterior chamber and checked the further steps of the operation for a time. After the hemorrhage had been arrested by cold applications, and part of the blood had been removed from the anterior chamber, the lens was found tilted forwards, its upper margin lying in the pupil and resting against the cornea. It was at once removed in its capsule with a small spoon, and with no loss of vitreous. The healing process in this case was very slow, and although the wound was clean, and there was no prolapse of the vitreous, the wound did not close for nearly three weeks. Vision improved somewhat, having risen to 10/200.

CASE XII.—Frederick G., aged 56, February 19, 1888. This patient received a blow on the right eye from a hard rubber

ball in October, 1889, and lost the sight of this eye immediately. The sight of the other eye had previously failed from the growth of a cataract.

R. E. perception of light. Iridodonesis. Lens was dislocated entirely into the vitreous, and lay tilted forwards, its upper margin resting on the iris and just appearing at the edge of the pupil. Eye quiet. Tension normal.

L. E. 20/200. Cataract.

February 24th. The patient was seated in the operating chair, and the usual upward corneal section was made, the apex in clear cornea. There being no prolapse of the vitreous, pressure was made from below backwards, but the lens did not move. A delicate blunt hook was then introduced through the wound, passed through the pupil and behind the lens, and by a single twist penetrated the capsule and caught the lens. The latter was then drawn through the pupil and out of the lips of the wound, inclosed in its capsule, and without any loss of vitreous. The wound healed readily under the usual antiseptic dressings, and without either prolapse or incarceration of the iris. There was no improvement of the vision, and the vitreous remained cloudy as long as the patient was under observation.

CASE XIII.—Mary O'B., aged 30, February 25, 1889. Patient was struck on the right eye six months ago by a blow from a fist, and lost the sight at once. She had always been quite myopic. R. E. perception of light. Pupil irregularly oval in shape and displaced inwards towards the nose. Iridodonesis. Lens dislocated downwards into the vitreous. Tags of broken adhesions on the posterior surface of the sphincter margin of the iris. Floating opacities in the vitreous. Tension normal.

L. E. 20/200; with sph.—D 2.50 = 20/70. Large annular posterior staphyloma, and patches of chorio-retinitis disseminata.

An upward corneal section was made, the apex in clear cornea. The speculum was then withdrawn, and the upper lid held away from the eye by an elevator. Pressure was then made on the lower part of the sclera directly backwards by the finger through the lower lid. The iris prolapsed at once, and the lens appeared in the field of the pupil. Every attempt at further pressure

caused prolapse of the vitreous without advancing the lens in the slightest degree, and this method was therefore abandoned. Keeping the lens in the field of the pupil by moderate pressure below, a delicate wire spoon was introduced through the corneal wound and behind the plane of the iris, gently insinuated behind the lens and then withdrawn, bringing the lens in its capsule with it. The iris was then replaced, a drop of a solution of eserine was instilled, and the eye dressed and bandaged in the usual way. There was but little vitreous lost, and the eye healed with very little reaction, but with a rather extensive incarceration of iris in the inner lips of the wound. There was no improvement in vision.

DISCUSSION.

DR. SAMUEL THEOBALD, of Baltimore. — Do I understand Dr. Bull to say that it is possible to get the lens out, when it is completely dislocated into the vitreous humor, without inserting some form of traction instrument? I have had only a limited experience in this direction. Two cases operated on in the past eighteen months were not instances of such complete dislocation as I allude to. The lenses were not floating in the lower portion of the vitreous, but were in the hyaloid fossa. One of these I removed by external manipulation; but I found it impossible to remove the other in this way. I first tried a sharp hook, but the hold was not secure enough. I then introduced a cataract loop and extracted the lens without difficulty. The eyes healed kindly. I should suppose that where the lens was floating in the lower part of the vitreous chamber, external manipulation would almost surely bring out the vitreous humor rather than the lens, especially as in these cases the latter is usually more or less fluid.

DR. BULL. — I do not want to be misunderstood. There are certainly cases where pressure backwards causes the lens to rise and appear in the pupil and sometimes to pass through the pupil into the corneal wound, yet there are some cases in which the use of a hook or wire spoon becomes necessary. It is, however, a number of years since I have been compelled to introduce a spoon into the vitreous chamber for the removal of a dislocated lens floating in the vitreous.

DR. THOMAS R. POOLEY, of New York. — I consider the plan advocated by Dr. Bull one that can almost always be put

in practice. I have seen Dr. Knapp remove, by this method, lenses partially or wholly dislocated. On several occasions, I have succeeded in the same way. I agree that the majority, if not all, dislocated lenses can be removed by this procedure, and thus the necessity of the introduction of an instrument into the vitreous obviated, a point of great value in the subsequent healing of the case.

REMOVAL OF A LARGE EXOSTOSIS OF THE ORBIT WITH PRESERVATION OF THE EYE.

THOMAS R. POOLEY, M.D.,

NEW YORK CITY.

In offering to the Society a history of the following case of exostosis of the orbit, with an account of the operation for its removal, I desire to do so without entering into detail of the literature of the subject, which has quite recently been fully done by Dr. Joseph A. Andrews of New York in an admirable paper in the *Medical Record*, September 3, 1887. Very few such cases are on record, and those in which successful operations have been made are still fewer.

The patient, a healthy young Irish girl, twenty-three years of age, first consulted me on August 21, 1888, on account of the condition of her right eye. Two years ago she first began to notice protrusion of the eyeball, and to be troubled with lachrymation. There was, however, no pain or other annoying symptom, and she was led to seek advice mainly on account of the increasing deformity. The inner part of the upper lid was slightly prominent and pushed downward, conjunctiva and eyeball normal. There was a moderate degree of exophthalmos forward, outward, and slightly upward, with impairment of the movement of the eye inward.

Upon palpation, a tumor could be felt in the upper and inner angle of the orbit, which was of bony hardness and painful upon pressure; the growth also could be felt beyond the inner wall, extending to the floor of the orbit. There was no abnormal

appearance of the fundus, and with —1 D. c. axis 180° vision was normal. There was no diplopia. The diagnosis of orbital exostosis was made. The nature of the growth and the danger attendant upon its removal was explained to her relatives. They consented that an exploratory incision should be made to determine the exact size, seat, and nature of the tumor, and the consequent dangers of its removal. This was accordingly done, but upon fully explaining the state of affairs the friends declined further operation. The incision confirmed the previous diagnosis and revealed a large ivory-hard exostosis attached to the upper, inner, and lower walls of the orbit by a broad base, firm and immovable. The patient was not seen again until Thursday, February 6, 1890, when she came to the clinic of the New Amsterdam Eye and Ear Hospital. Her symptoms were now very alarming, and she was desirous of having something done for her relief, but again deferred operations until she could consult some one else. There was now intense swelling, redness, and tenderness of the lids, with great chemosis of the ocular conjunctiva, especially below, where the swollen conjunctiva protruded beyond the palpebral fissure. The exophthalmos too had greatly increased and the eyeball was pushed forward, outward, and somewhat upward, and the movements of the eye greatly restricted in every direction, especially inward and downward. There was well-pronounced optic neuritis $V = \frac{xx}{200}$.

On the night of the day following I was called to see her at her house, on account of the appearance of urgent symptoms, and now found her suffering from great pain in and around the orbit, with increased pulse, rise of temperature, nausea, and when she fell asleep, mild delirium. The exophthalmos and swelling of the lids had greatly increased, even since I last saw her, and I urged immediate operation, being under the impression that suppuration of the orbital tissue, or some acute inflammatory complication, had set in. The next morning she was admitted to the New Amsterdam Eye and Ear Hospital, and at 3 P. M. the same day I began the operation for the removal of the tumor, with the assistance of Drs. Ward, Roberts, and E. A. Kirkpatrick, the house-surgeon. An incision was begun along the upper margin of the orbit, near the middle of the

superciliary ridge, and carried to the inner margin, care being taken to keep on the bone. It was found necessary to extend the incision downward to the floor of the orbit, beyond the margin of that part of the tumor which could be felt in this location. When completed, the incision was curvilinear, 75 mm. in length, and embraced about two-thirds of the orbital circumference. Upon cutting through the tense periosteum the dense, yellowish-white bone characteristic of ivory exostosis was seen. There was no escape of pus or serum. The place of attachment of the tumor was now clearly exposed, and I began by the use of chisels to attempt its detachment from the upper and inner wall. To my great delight I found that a groove could readily be made in the bone with a chisel, without even using the mallet, but by merely using the ball of my hand as such, and it was not necessary throughout the entire operation to use it. I kept the chisel close to the walls of the orbit, cutting toward the bone, and, after a somewhat tedious endeavor, found that the broad base of attachment was nearly severed, and that the tumor, when seized by bone-forceps, was freely movable in the orbit. I now with the chisel cut the only remaining fragments which held it, but found it a very difficult matter to dislodge the now dissevered tumor from the orbit. This was, however, at last accomplished by turning the tumor so that its long axis, which corresponded with the vertical meridian, was horizontal; and, now by putting an elevator under it, it could be pried out. Care was taken throughout the operation not to divide any of the ocular muscles, nor to injure the eye, which during the operation was kept drawn out of the way by a spatula. The orbital walls from which the tumor had been removed were rendered smooth by the use of the chisel and the periosteum knife. No attempt, however, was made to draw the periosteum over it. The wound was now united by six catgut sutures, except in the most dependent part, where an antiseptic rubber drainage-tube was inserted into the orbit. The usual antiseptic precautions were adhered to throughout the operation. The operation, which was made under ether, lasted about one hour and a quarter, was attended by considerable hemorrhage, and was well borne by the patient, who, upon coming from

under the influence of the ether, saw well. There was no diplopia, some bloody discharge through the nose and mouth. One-tenth grain of morphine was given hypodermically. Antiseptic iodoform gauze perforated by a number of holes, smeared with carbolized vaseline, a layer of borated cotton, and firm compressive bandage applied, and patient put to bed. At 11 P.M. the patient had not slept, and complained of slight pain in the orbit, radiating superiorly from it; pulse, 100. Gave ten minims of Majendie by the mouth.

Sunday, 9 A. M.—Pulse, 90; temperature, 98$\frac{3}{5}$° F. Wound dressed and found healed by primary adhesion throughout its entirety, except at the drainage-tube, lids swollen, cornea clear, chemosis somewhat lessened, vision good, some nausea, otherwise comfortable. Slept a few hours during the day. Pulse, at evening, 90; temperature 100$\frac{1}{5}$° F.

Monday, 10th.—Did not sleep well; wound about the same. Pulse 84, temperature 98$\frac{4}{5}$° F. The patient cheerful and free from pain. Discharge takes place freely through the nose and mouth, but little through the tube.

Wednesday, 12th.—No. 3 stitch removed, as suppurative appearances were making themselves apparent in its track.

Thursday, 13th.—Had a restless night; pulse 100, temperature 100$\frac{2}{5}$° F.; tenderness and swelling below the right ear due to enlarged chain of lymphatics; stitch No. 2, and the drainage-tube, removed, which was not replaced, as all drainage seemed to take place through the nose and mouth. Considerable thin discharge oozed through the wound at the site of No. 2 stitch, especially on pressure. In the evening pulse had fallen to 84, and temperature to 99° F.

Friday, 14th.—Patient slept well, pulse and temperature good, considerable discharge, but swelling going down and chemosis disappearing.

Saturday, 15th.—Pulse 72, temperature normal, exophthalmos decreasing.

Sunday, 16th.—Stitches Nos. 1 and 3 removed,—or at least what remained of them—as they had been partially absorbed and suppuration was appearing in stitch-canals, a natural wrinkle beginning to appear in the upper lid.

Monday, 17th. — Remaining stitches removed; considerable headache of the nature of migraine, which disappeared by evening after a dose of antipyrine.

Tuesday, 18th, Wednesday, 19th, and Thursday, 20th. — A gradual improvement, without any untoward symptoms. Little ulcers have formed at the site of the stitches, and there is considerable thin, pus-like discharge through the opening at stitch No. 1. Chemosis still present, but in less degree. Red precipitate ointment spread on iodoform gauze, to be renewed three times a day, was applied to heal the little ulcers.

Saturday, 22d. — Headache again, otherwise doing well; sleeps well, and has a good appetite.

Sunday, 23d. — Five grains of quinine was given to ward off the headache, which usually comes on at the same time in the afternoon, and had the effect of greatly relieving this symptom.

Monday, 24th. — Sixteenth day after the operation. Exophthalmos nearly, and chemosis entirely gone; ulcers healed; no discharge from the wound, which is now entirely healed; eyelids beginning to assume a natural appearance; still some slight discharge through the nose; temperature normal, and pulse 86; bandage left off for the first time; vision equals $\frac{20}{200}$, with $-\frac{1}{80}$ C., axis 180° = $\frac{20}{100}$, optic neuritis almost disappeared.

On 26th. — Still improving, homonymous diplopia, which has existed in the lower part of the field of fixation since the 18th, is daily decreasing. This appears to be due to a mechanical displacement of the eyeball, since the double images do not correspond to any of the known forms of paresis of the ocular muscles, and is daily improving.

The following diagrams, kindly made for me by Dr. E. A. Kirkpatrick, (Figures 1 to 3) show the situation of the double images and a gradual diminution in the double vision area, while figure 4 shows the situation of the double images in the diplopia, caused by paresis of the superior oblique, the only muscle which would have been likely to be injured during the operation.

On 28th. — Three weeks after admission patient was discharged from the hospital. There was some conjunctival injection and swelling of lower lid, slight discharge through the

nose, incision firmly healed, scar not very conspicuous, diplopia as shown in the diagrams.

March 3d. — The patient came to my office; vision $\frac{20}{70}$ without any glass, — which no longer improved the sight; diplopia still exists, but does not annoy her; no longer any discharge through the nose or mouth, nor any appearance of neuritis, ex-

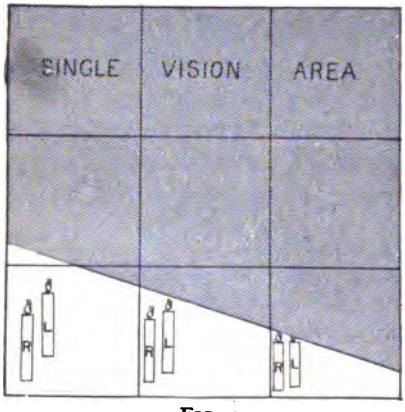

FIG. 3.

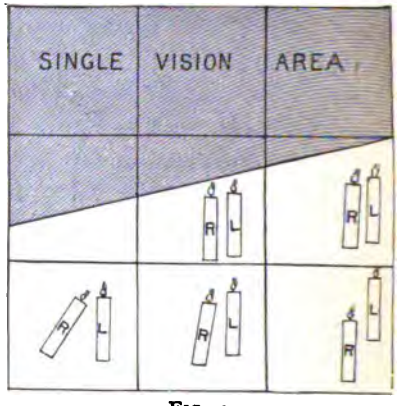

FIG. 4.

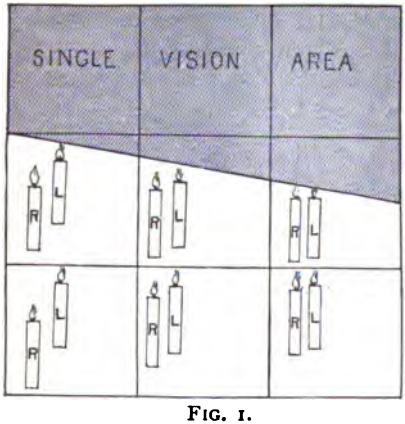

FIG. 1.

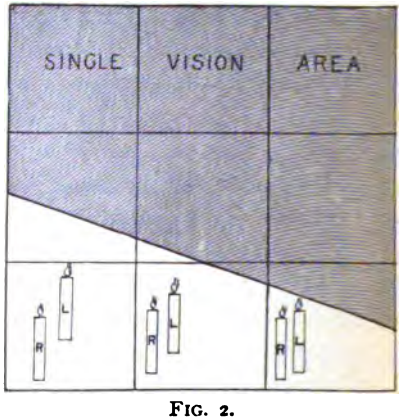

FIG. 2.

cept that the disk is still somewhat red; no exophthalmos; free movements of the eyeballs in every direction; some lachrymation.

The last examination, made in my office April 29th, one day before the patient sailed for Europe, showed the following:

V. = $\frac{20}{40}$ without any glasses; diplopia still exists, but the area of double images less and inconstant. (See Fig. 3.) Complains of rather frequent headaches, all evidences of neuritis gone, disk normal in appearance, but little deformity, except slight puckering of the scar where the stitches were; still some slight œdema of the lower lids and lachrymation. Since then I have had a letter from the patient, who says: "The scar is scarcely perceptible, the double images have almost worn away, and the only annoying symptom remaining is slight watering of the eye."

The tumor removed is covered with periosteum, except where it was attached, and apparently consists of compact bone throughout, except at its point of attachment, which is soft and cancellated. It is of an irregular oval, with a projecting portion which extended into the orbit, about the size of a horse-chestnut, covered with irregular nodules and traversed by numerous sulci. It weighs twenty-six grammes. (See Figs. 1 to 6.)

Its longest antero-posterior diameter (obliquely forward and a little downward) measures 39 mm. Its greatest lateral diameter 28 mm., and its vertical diameter 30 mm. The base of attachment of the tumor, which resembles an irregular oval, was to the orbital walls, and the points of the attachment separate, respectively, the os planum of the ethmoid, the frontal and lachrymal bones, and probably a part of the superior maxillary. Its base of attachment measures antero-posteriorly (slightly obliquely upward and outward) 27 mm. Anteriorly (obliquely downward) 24 mm. In its longest diameter, which is nearly vertical (slightly inclining backward), 30 mm. The shortest diameter of the attachment, in what may be said to constitute an irregular circle, measures 20 mm.

Whether the tumor originated in the ethmoidal cells, or was of purely orbital origin, it is difficult to say. The whole of the tumor lay in the orbit. The patient had never complained of obstruction of the nose, and no portion of the growth was extra-orbital; hence, while the point of origin of the tumor may have been in the ethmoidal cells, the entire development and extension was into the orbit. The rough surface of attachment, as

shown in the specimen, would seem, too, to indicate its orbital origin, and does not show any extension into the adjacent pneumatic cavities. In regard to the operative procedure, I may briefly mention what seems to me to be the more important

FIG. 5.—Superior.



FIG. 6.—Inferior.



FIG. 3.—Anterior.

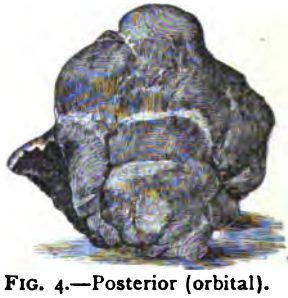

FIG. 4.—Posterior (orbital).

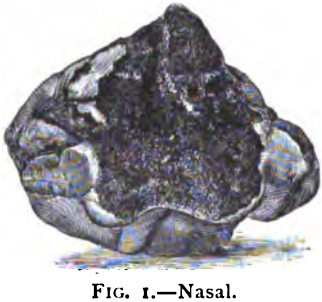

FIG. 1.—Nasal.

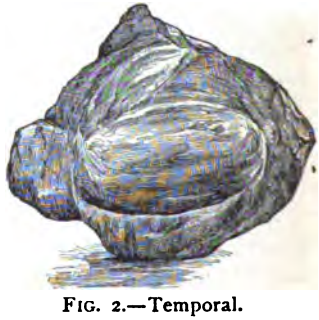

FIG. 2.—Temporal.

FIGS. 1 to 6.—Surfaces of the Tumor. (Natural size.)

features, and first of all is the comparative ease with which the operation may be accomplished, when the exostosis projects into the orbit only, and does not invade other adjacent cavities.

Although as shown by Knapp's * and Andrews' † successful cases, even here the obstacles to a successful operation are not insurmountable; but the method suggested by Knapp, of the enucleation of these tumors, from their periosteal capsule, does not seem to me to have been indicated in this case. The feature in my case which seems to be of the greatest interest, and which no doubt added to the comparative ease of the operation, was the occurrence of the acute symptoms, which were, no doubt, due to an acute ostitis in the site of the attachment of the tumor, thus causing this part of the growth to become comparatively soft and so to readily yield to the attacks of the chisel, and thus to do away with any necessity for the use of the mallet. To this rather than to any cerebral pressure caused by the impact of the tumor on the orbital roof, and thence on the brain, may be attributed the constitutional symptoms. In regard to the technique of the operation: The instruments used were small hand-chisels of different construction, some grooved, others straight, spatulas, and elevators. The latter were especially useful in prying the impacted tumor from the orbit when its basis had been severed; in doing which it became necessary to turn the tumor, so that its long axis corresponded with the palpebral fissure, and then to pry it out of the orbit, which proved the most difficult part of the operation. I was at times greatly aided during the operation by a small portable electric light, devised by Dr. Milton Josiah Roberts, which was so arranged as to throw a bright light into the depths of the orbit. The recovery from the operation was as favorable as, under the circumstances, could be expected. There was the reaction, both constitutional and local, which might naturally be expected after such a protracted operation, and although the wound had first united by primary adhesion, some little suppuration, most marked in the course of the catgut sutures, which certainly in this case seemed to be less innocuous than I have seen in the use of fine silk, occurred. The drainage tubes seemed to have been of little, if any use, for the natural drainage which took place through the nose and throat did away with any necessity for it, nor do I think that in under-

* Archives of Ophthalmology, vol. ix, page 464 et seq.

† *Medical Record*, September 3, 1887.

taking another operation of this kind I would use one at all. The rapid disappearance of the optic neuritis, the improvement of vision, and the return of the refraction to an emmetropic condition, are all of great interest. While it is easy to account for the occurrence of neuritis and consequent diminution of vision, I am at a loss to account for the occurrence of the astigmatism and its subsequent complete disappearance.

DISCUSSION.

DR. J. A. ANDREWS, of New York.—As Dr. Pooley has stated, bony growths of the orbit and neighboring cavities are rare. A few cases only are on record. Two years ago I published in the *New York Medical Record* the reports of two cases of osteoma, one of which sprang from the frontal sinus, the other from the ethmoid cells. At that time I made a careful study of the literature of the subject. I also examined the reports of the Ophthalmic Institutions in New York. I found that in about 430,000 cases of eye diseases treated in these institutions since 1821 only eight cases of osteoma of the orbit had been observed.

As to the actual starting point of these tumors it is, of course, difficult to decide. Before the operation it is often impossible to determine whether the growth came from the frontal or the ethmoidal cells. When the growth originates in the frontal sinus it generally presents itself at the *upper inner angle of the orbit.* In Dr. Pooley's case the growth probably sprang from the periosteum, as he states that it was not connected with any of the neighboring cavities. I feel sure that Dr. Pooley carefully examined as to the possibility of there being a growth in any of the other cavities, especially the ethmoidal cells. We should, therefore, call this a case of *external exostosis* without a history of traumatism. These external exostoses spring from the periosteum. The exostoses of the frontal, ethmoidal, or sphenoidal sinuses, are believed to originate in various ways. Virchow, *e. g.*, supposed that a number of them originate in the diploë, while Arnold has suggested that the tumors in question were developed from remnants of foetal cartilage. If Dr. Pooley's case was one of exostosis of the ethmoid, there might still be another tumor in the nasal cavity which escaped observation. My own case was one in point. There, half of the tumor appeared in the orbit, while the other half was removed from the ethmoidal cells. In the center of the tumor there was spongy bone.

A few years ago Dr. Knapp published a case of osteoma of

the ethmoid, I believe in the Transactions of the International Ophthalmological Congress, 1876. Two years ago, at Dr. Knapp's invitation, I had the privilege of seeing that same patient from whose nasal cavity he removed a loose bony growth. This growth was not found at the time of the original operation. I believe that at the time of the first operation there was no suspicion of a growth in the nasal cavity. This growth was of the size of a walnut, and was removed by drawing it through the nostril after the latter had been enlarged by an incision. I believe the operation for the removal of these growths should be done under antiseptic precautions.

DR. R. A. REEVE, of Toronto, Canada.—I should like to show an ivory osteoma which I removed in September, 1881. The point of origin was the frontal sinus, and the extent of its seat of attachment is well shown here. It was removed by the method of enucleation, advocated by Dr. Knapp. The patient recovered, and had useful vision. I expect to publish the case in full in the *Archives*. These photographs show the appearance before and after operation.

I should like to offer a criticism of one observation made by Dr. Pooley. He thinks that the softening at the point of attachment was due to acute osteitis. In my case there was no recent inflammation, and after failure with the drill, and other means, I enucleated it with a simple curved elevator. The roughened surface shows the extent of *dura mater* exposed. The tissue was soft at the point of attachment, simply because the bone was absorbed. The tumor seemed to be attached simply at its margin. No special efforts were required in order to remove it from the orbit.

I should like also to show the photograph of another case, which illustrates the difficulty of differential diagnosis without exploratory incision, which is now the rule. This was a case which would naturally be declared to be a case of osteoma of the frontal sinus, involving the orbit. As will be seen from the photograph, the region of the frontal sinus is prominent. Evidently the bony floor of the frontal sinus was depressed and pushed forward, causing decided exophthalmos. A guarded diagnosis was given, and it was stated that, without exploratory incision, it could not be decided whether it was an osteoma or chronic inflammation of the cavity with dilatation. Exploratory incision showed an immense cavity, involving the frontal sinus and the ethmoid cells. There was no fluid in this cavity.

DR. THOMAS R. POOLEY, of New York.—There was positively no evidence of extension of this tumor into adjacent cavities. I laid stress upon that in the history of the case. It is well

known that these tumors usually invade other cavities; but in this respect this one was an exception.

In regard to the softening of the base of the tumor I think that there can be little doubt that the acute symptoms can only be accounted for upon the supposition that there was an acute inflammatory process in the bone, the softness of which was evidently thus caused. When this tumor was shown to the New York Ophthalmological Society a suggestion of that kind was made by Dr. Noyes. I had never before seen an exostosis removed without the use of the mallet. Here it was readily accomplished without it.

OPERATION FOR ECTROPION OF THE LOWER LID BY THE SLIDING FLAP METHOD.

THOMAS R. POOLEY, M.D.,

NEW YORK CITY.

The method of operating by sliding flaps to fill the defects left after the removal of morbid growths is not a new one, but has only of late been much adopted in operating upon the eyelids, and is now described in all modern books on ophthalmology. The object of this communication is to show the adaptability of this method to the cure of cicatricial ectropion of the lower lid, which, so far as I know, has not hitherto been very generally put in practice.

Mrs. W., æt. 48 years, was admitted to the New Amsterdam Eye and Ear Hospital March 17, 1890, suffering from an ectropion of the lower lid. On Sept. 9, 1889, she was operated on for the removal of an epithelioma of the lower eyelid, the subsequent healing resulting in ectropion. To relieve this the same surgeon essayed an operation which, however, not only failed, but, as she says, made the ectropion much worse.

The condition shown by the patient on her admission was that usually seen in cicatricial ectropion. The lower lid was dragged downward and somewhat outward, the conjunctiva exposed to its *cul-de-sac*, forming in its extent an equilateral triangle, at the apex of which was situated the most dense cic-

atricial tissue. The lower canaliculus was pulled about 4.5 mm. from its normal position. The exposed conjunctiva in a state of hyperæmia and hypertrophy, and the eye constantly overflowing with tears, complete closure of the eye was impossible.

I began the operation with the intention of practicing the method known as Wolfe's transplantation of flap without a pedicle, but after the relief of the lid, removal of the cicatricial tissue, and stitching together of the eyelids, I determined to fill the gap with a sliding flap from the temple instead.

The operation was made as follows: Having slit the lower canaliculus, I introduced a probe and pushed it horizontally into the lachrymal duct, then made a curved incision a little beyond the puckered edge of the cicatrix, dissected it free from the malar bone to which it was adherent, keeping my finger in the conjunctival *cul-de-sac* to avoid cutting through. The cicatricial tissue bands, which proved to be very extensive and to extend up to the inner canthus, were all carefully removed and the whole extent of the gap exposed. I now pared and stitched the eyelids together by four points of interrupted suture. The large defect left was filled by carrying an upper incision along the cheek over the zygoma, well out upon the temple and toward the ear, and a lower one in the same direction over the cheek, the outer end of the upper incision being directed upward, and the outer end of the lower incision downward, diverging from each other, in such a manner as to secure greater width of the pedicle. The length of the upper incision was 10 cm., and of the lower, 8 cm., 7.5 mm. This flap was then carefully dissected up, only the skin and immediate subcutaneous tissue being included; and, this done, the flap was slid inward over the whole area of raw surface, which it completely filled without any traction, and united by sutures to the opposite side. After waiting for all bleeding to subside, they were carefully adjusted with points of interrupted sutures of fine black silk, 24 in number. Only a moderate amount of bleeding took place during the operation, and when finished the color of the flap was quite similar to the same area on the opposite side of the face. During the progress of the operation

and while stitching the flap, a towel wrung out of hot water was occasionally applied to the surface to maintain its vitality. The patient was allowed to come from under the influence of the ether before all the stitches were applied, and bore the operation well. The dressing consisted of iodoform gauze smeared with carbolized vaseline, and a thick layer of absorbent cotton, all of which was held in place by a roller bandage applied in such a way that traction was made on the flap in the direction of its apex. Time of operation, one hour and three-quarters.

The next day the patient had no pain, the pulse and temperature were normal, and the dressing was not disturbed. The day following, March 20, the dressing was removed, and the wound was found to be entirely united by first intention; no swelling; no evidence of suppuration.

From this time on the healing took place without an untoward symptom of any kind. At no time was there any suppuration, not a drop of pus was discharged.

On March 22, several of the stitches were removed. Union of the upper and lower lid had only taken place in its outer quarter.

The day following all the other stitches were removed, and the apposition of the flap was everywhere perfect, with no tendency to separate, the line of union being everywhere firm.

March 25, bandage was left off, and on the 27th the union of the lids severed by the scissors.

The patient was discharged two weeks after her admission with the most gratifying result imaginable. There was complete cure of the ectropion. The margin of the lower lid lay in nice apposition with the eye; closure of the lids was perfect, and it was really surprising how little deformity resulted from the operation. At a little distance off the scars were hardly noticeable, since they lay in the natural wrinkles of the face. There was slight redundancy of the inner lower part of the flap, numbness and occasional neuralgic pains in it.

It seems to me that when this method is applicable, it is much to be preferred to Wolfe's flap without a pedicle, in which the author himself seems to have had better results than anyone else, nor does it leave in a suitable case more deformity.

The uniting of the free margins of the lids is not necessary, but in my case was included when I had the intention of practicing Wolfe's method, for if properly made the whole traction of the healing will be horizontally in the long axis of the scar and consequently will tend to render the ectropion less.

DISCUSSION.

DR. LUCIEN HOWE, Buffalo. — Why did you change your plan after beginning with the intention of making Wolfe's graft?

DR. POOLEY. — It seemed to me that the gap could be filled very well with such a flap, and that the result would be nicer.

DR. HOWE. — I can imagine but few cases where we have not much more to gain by Wolfe's method than by the sliding flap. Surely another scar is made, and if it is a failure with the sliding flap, it is a great failure. If it is a failure with Wolfe's method, the failure is very slight and afterwards the same patient can have the sliding flap operation made. Moreover, it is necessary to make the flap so much larger than the wound that this seems another reason for selecting Wolfe's method. I have reported a case in which I transplanted a flap a little over three inches in length, and that is not the largest recorded. It seems to me far better to at least attempt Wolfe's method.

DR. POOLEY.— I have several times undertaken Wolfe's operation, but have not had as good results as others have reported. The method which I have described, which I have resorted to in removing epithelioma of the lower lid, has given such good results that I was led to adapt it to the treatment of ectropion.

DR. R. A. REEVE, Toronto, Canada. — I have done Wolfe's operation in a number of cases and have had better results than Dr. Pooley reports. One case in particular, which was very successful, was one where the ordinary sliding flap method would not have been applicable, because there was cicatricial tissue all about the region. This would have jeopardized any flap that would have been transferred.

DR. O. F. WADSWORTH, Boston. — I have had some success with Wolfe's operation, but where the region is not surrounded by cicatricial tissue, I should prefer sliding flaps. I have done many more operations by sliding flaps than by Wolfe's method, and I think that the chances of success are better with the sliding flap, provided we can get a pedicle of healthy skin. Usually

the edges of the denuded part can be so united that the cicatrix will be linear and practically invisible.

DR. B. E. FRYER, Kansas City, Mo. — The trouble with Wolfe's operation is in regard to the final result. A few weeks ago, I saw a case on which I did Wolfe's operation six years ago. I put in a flap one and a quarter inches in length. It had contracted to about one-third of an inch, and there was eversion of the lid.

A FORM OF XEROSIS.

CHARLES W. KOLLOCK, M.D.,

CHARLESTON, S. C.

A rather peculiar form of this disease is quite prevalent among negro children in Charleston, S. C. These children are for the most part scrofulous, emaciated, and generally miserable in appearance. At first sight the examiner is attracted by the pigmented condition of the conjunctiva as seen through the palpebral fissure. It has a dirty-white and yellowish-green hue, that gives the eye a most disagreeable appearance. The portion of the conjunctiva visible between the lids is darker than the rest and generally thicker near the corneal margin. The pigment is distributed well back into the retro-tarsal folds, but does not invade the palpebral conjunctiva. The ocular conjunctiva may be merely thickened and discolored, and again, besides the discoloration, it is relaxed and flabby, so that every movement of the ball throws it into folds or wrinkles about the cornea, which are more noticeable laterally, but in some cases entirely surround the cornea. Occasionally these folds are capped by the silvery scales which some writers have described as being diagnostic of hemeralopia, and indeed the parents of a few of the children have mentioned night-blindness as the sole cause of bringing them for treatment. The conjunctiva of the lids has never been found in a granular or contracted condition, but is generally in a state of passive congestion, and in no case has the disease been known to follow ophthalmia. The ocular conjunctiva is dry and scaly and closely resembles in appearance

the skin of the cavalla, or pompino fish. The condition of the cornea is extremely interesting. Frequently it is bordered by an ulcerating ring that is generally below the surface, but at times is slightly elevated as a soft, grayish ridge. This ulceration has never been seen to encroach further on the cornea, though the circle is sometimes broader at its upper and lower quadrants. The edges of the cornea are always hazy, whether ulcerated or not, but the center may, or may not, be clear. A bluish, hazy sheen is a common condition, which upon close in spection is found to be due to a partially opaque state of the epithelium. In one of the most pronounced cases the corneal epithelium was in folds and ridges like the conjunctiva. It is doubtful whether the inner layers of the cornea became involved, but there was certainly no iritis. The eye is not painful, nor is there any photophobia, but on account of the low vitality of the majority of patients, and their ages (from one to eight or nine years), it was impossible to obtain accurate information about subjective symptoms. Treatment was usually followed by beneficial results, and consisted principally in building up the weakened constitutions. It was found that, as strength and tone improved, so did the ocular symptoms, the cornea first showing the results of treatment by becoming clearer. Locally a weak ointment of the yellow oxide of mercury (gr. ss. vaseline ʒi) was effective and at times along with this a collyrium of boric acid was used. Occasionally, when ulceration existed about the cornea, a solution of atropine (gr. i ʒi) was instilled, but whether beneficial or not was uncertain. Improvement in the condition of the ocular conjunctiva was less rapid, moisture and contraction returning gradually, but the pigment remaining unchanged. There is no doubt but that good nourishing food and a change of air to locations where sanitary surroundings were unexceptionable would in many cases bring about cures, for it seems more than probable that hereditary taint, poor hygienic surroundings, and bad food are potent causes of the disease.

This form of Xerosis is interesting from the fact that it has only been seen among negro children, that there has never seemed to be reason to think it followed any attack of oph-

thalmia, but originated *de novo;* that the conjunctiva is never contracted, the cornea is generally more or less affected but never destroyed; and that under proper treatment recovery will take place. The accounts found in the books are very meager, and none describe a form which is exactly similar. It more nearly resembles a type reported by Bitot and Blessig to have occurred among the lower classes of Russians, especially during Lent. It also bears resemblance to that seen to follow ophthalmia Brasiliana, but has its points of difference from both of these.

DISCUSSION.

DR. HENRY D. NOYES, New York.—This condition is probably never seen in this part of the country. Xerosis of the conjunctiva occasionally appears as a result of trachoma, and as a simple affection it sometimes occurs as a result of pemphigus. This last spring I saw a case of marked xerosis of the conjunctiva in a patient who had an eruption of pemphigus on other parts of the body. The features of the condition as described to-day are novel.

DR. KOLLER.—I have listened with great interest to the paper of Dr. Kollock, for I have seen a number of these cases in my own country. It is not a rare occurrence in Austria to see patients suffering from xerosis, not so much of the conjunctiva as of the cornea. This is almost always connected with night-blindness. These cases occur in epidemics, especially in orphan asylums. On investigation it is usually found that there is some surface of water or white wall in the neighborhood which reflects the light, thus causing the disease. It is difficult to form an idea how night-blindness and affection of the cornea go together. Let me venture on a theory which would cover these points. It seems to me that in the conjunctival and corneal xerosis we have an affection similar to what is known as sun-burn of the skin, result of the irritation of the sun or its reflection from snow or water. This same cause, by over-irritation of the retina, would be able to induce night-blindness, making the eye blind to the lower degrees of light, so that it will respond only to strong irritation.

REPORT OF A CASE OF RECURRENT IRIDO-CHORIDO-RETINITIS.

SAMUEL THEOBALD, M D.,

BALTIMORE, MD.

Ida R., aged 25, came under my care at the Baltimore Eye, Ear, and Throat Charity Hospital, July 8, 1889. She was unmarried, slight, and rather delicate in appearance, was regular in all her functions, and gave no evidence of either inherited or acquired syphilis. She came from a healthy (non-malarial) part of Baltimore County, and her general condition was fairly good. She was suffering from recurrent attacks of inflammation in the left eye, which she said had begun two years before, and had entirely destroyed the sight of this eye six weeks before her visit to the hospital. The eye was without light perception, was injected, had rather high normal tension, and had evidently been the seat of severe irido-choroiditis. The anterior chamber was obliterated, the iris, which was adherent to the lens, being in contact with the posterior surface of the cornea, and the media were too cloudy to permit of ophthalmoscopic examination. The fellow eye, at this time, showed no signs of disease, but, as I considered its safety was jeopardized by the condition of the left eye, I strongly advised the enucleation of the latter. The patient would not consent to this at once, but promised to return and have the operation performed after consulting with her parents. In the mean time, she was put upon small doses of iodide of potassium, and atropia was prescribed for application to the inflamed eye.

After this nothing more was heard of the patient for nearly five months, when (December 4th) a relative came to the hospital to report that the other (right) eye had become inflamed about three weeks before, and that she was now almost blind in this eye. I presumed, of course, that this trouble was of sympathetic origin, and directed that the patient should be brought to the hospital without delay, and, at my next visit, two days afterward (December 6th), I found her there. She stated

that the right eye was already better than it had been, and that the sight had considerably improved. It was, however, still somewhat injected and photophobic, and V. was 15/LXX, with ability to distinguish only short words of J. No. 1, with difficulty. Owing to the photophobia and contracted state of the pupil a satisfactory ophthalmoscopic examination was impossible. The left eye was enucleated at once, under chloroform, and atropia was applied to the right eye.

The next day the right eye was nearly free from photophobia, and the pupil having responded to the atropia, a ring of pigment dots could be seen upon the anterior capsule of the lens, showing that there had been a mild attack of iritis. There was a want of transparency about the deeper media, and slight inflammatory changes were seen in the retina near the optic nerve entrance. The patient was now placed upon biniodide of mercury and iodide of potassium, and later, compound tincture of cinchona, and the condition of the eye slowly improved. December 23d she had V=15/L+, and the mercury was discontinued, five grains of iodide of potassium being given three times a day instead. December 27th she could read J. No. 1 tolerably well. One week after this (January 3, 1890), without premonition and without assignable cause, the eye grew suddenly worse. The patient waked with a headache and a tired feeling about the eye, and found that she could not see as well as on the previous day. At my visit in the afternoon the retina in the region of the macula was found to be markedly œdematous, and she could with difficulty distinguish words of J. No. 10. The next morning the eye was still worse. In the retina, near the macula, there were three whitish exudation spots and one small hemorrhage, also a well-marked opacity in the vitreous humor near the optic disc; Tn.; V=7/CC. The pupil was dilated by means of homatropia, to facilitate the ophthalmoscopic examination, and no signs of iritis were discovered. The artificial leech was applied to the temple, and the iodide of potassium was increased to five grains every three hours, and on the following day a large blister was applied to the nape of the neck. On January 8th the vision had improved to 15/CC, but there were evidences of commencing iritis — the

iris having a muddy appearance and there being dots upon Descemet's membrane. The iodide was now discontinued, and in its place $\frac{1}{16}$ gr. of hydrarg. biniodide was given three times a day, and atropia was applied to the eye.

Under this treatment a most satisfactory improvement set in, and by January 29th the retina and vitreous had nearly regained their normal appearance, and V had risen to 15/XLV. Up to February 11th this improvement continued, but on that day she noticed that the sight was more obscure, and within twenty-four hours the eye was as bad as ever — the retinitis, with numerous exudation spots and several hemorrhages, being even more severe than before. There was also marked conjunctival and peri-corneal injection, and V. fell again to 15/cc; Tn. This attack, like the former one, was preceded by frontal headache, chiefly upon the right side. The installations of atropia, which had been omitted, were resumed, and, as the biniodide of mercury was well tolerated, the number of daily doses was increased from three to five.

Not to prolong the history of the case unnecessarily, it may be stated, briefly, that the patient recovered from this attack (during which the iritis was more marked than in the previous one) much better than could have been anticipated, so that on March 10th V. was again 15/LX, and the pupil was round and free from adhesions. On March 28th, however, there was another severe relapse, during which V. fell to 3½/cc, and finally to scarcely 1/cc. After this there was still another surprising rally, which by May 2d brought V. up to 15/CV+, at which time the vitreous and retina had nearly regained their normal appearance, though the optic nerve began to look too pale. Three days after this (May 5th) the headache (now referred chiefly to the occipital region) returned, the eye became injected and the cornea slightly steamy, and another severe relapse seemed imminent. As the attacks had shown some regularity in their recurrence (about once in six weeks), the propriety of trying the effect of quinine suggested itself, and, without discontinuing the mercury and iron that she had been taking, I prescribed quinine in generous doses, which soon produced cinchonism.

Whether due to the influence of the quinine or not, this relapse was the least severe one which had occurred, and, when the attack subsided without decided impairment of vision or marked retinal changes, I began to congratulate myself that I had probably found, in quinine, the key to the situation. I therefore ventured, on May 23d, to discontinue the biniodide of mercury, continuing only the quinine, iron, and collyrium of atropia. The V. at this time was 15/xc—. My confidence, however, was soon seen to have been misplaced, for, in a much shorter time than usual, on May 28th, the crucial and most severe attack of all set in. The biniodide was at once resumed, and mercurial ointment applied to the forehead and temples, as had been done previously with apparent benefit. The condition of the eye, however, grew rapidly worse, the iritis being more severe than ever before, and by June 4th the media had become too cloudy to permit of ophthalmoscopic examination, and V. had fallen to mere perception of light; Tn. still present. Small and frequently repeated doses of calomel were now prescribed, instead of the biniodide, and inunctions of mercurial ointment to the inside of the arms, as well as to the forehead, were ordered and pushed until the gums were decidedly affected.

June 13th the eye began, for the first time, to show T somewhat above normal. A seton was now inserted in the right temple. June 24th no appreciable change; +T. 1 (?); pain, more or less constant; media no clearer; anterior chamber very deep, indicating increased pressure in front of lens; pupil irregularly dilated, with several points of adhesion to lens capsule; V. = light perception. As a last resort I decided to perform an iridectomy. The iris, however, in spite of several preliminary applications of eserine, remained so completely retracted into the periphery of the anterior chamber opposite the point of incision, which was made upwards, that I found it impossible to grasp it with the forceps, and, as a result, the intended iridectomy was converted into a simple sclerotomy. The effect of the operation, however, so far as the reduction of tension and the relief of pain was concerned, was most satisfactory, but the cloudiness of the vitreous and the vision remained as before. Indeed, for several days after the removal of the bandage, the patient in-

sisted that she could not tell light from darkness, but she afterwards gave proof of undoubted light perception. On July 7th the patient was permitted to leave the hospital. She was then suffering no pain, and the activity of the inflammation in the eye had subsided, but the vitreous was as cloudy as before, the anterior chamber was shallow, the iris was beginning to show atrophic changes, and I could not satisfy myself that there was present even perception of light. The fate of the eye seemed settled beyond peradventure, and there appeared not a ray of hope that the patient would ever see again.

The case is one which, throughout its varying course, has interested me a great deal, and, as to its true nature, has puzzled me as much. Syphilis, I think, may be safely excluded as a causative factor, and the course of the disease in the second eye, which seems to have been a repetition of what occurred in the primarily affected eye, certainly does not sustain the view which I entertained at first, that the affection was of sympathetic origin. To my mind, the explanation which appears most probable is, that the inflammation in the primarily affected, as well as in the second eye, was preceded by, and, through the medium of sympathetic or trophic nerves, was dependent upon pathological changes in ganglionic centers which have to do with the nutrition of the eye, and which changes, I take it, were not unlike those that, I am disposed to maintain, occur as an essential link in the development of sympathetic ophthalmitis.* As in some measure supporting this view, by showing an abnormal state of the sympathetic nervous system, I may state that upon several occasions, when the patient was not suffering at all, and when there was no apparent cause for such a condition, I found her with a flushed face and a rapid pulse which, upon different days, varied from 130 to 154 beats per minute.

In conclusion, I may add that I have the notes of several cases, in which only one eye was involved, that I believe were, in their pathogenesis and in their pathology, exactly like the one just described; but this case, happily, is the only one I have encountered in which both eyes were attacked.

* Archives of Ophthalmology, Vol. XIII, No. 1, p. 73.

DISCUSSION.

DR. ARTHUR MATTHEWSON, of Brooklyn.—Was electricity used in this case? I speak of it because in all cases of ophthalmia that I have seen connected with *herpes zoster frontalis*, and especially those in which Jonathan Hutchinson laid down the rule that in all cases where the eruption extends down the nose the cornea is involved, I have found the electric current of great benefit. The cornea is always cleared up, and there has been great mitigation of the pain. In a recent case I did not use it at first, but when it was used I found it of great service in relieving the pain and clearing up the cornea.

TWO CASES OF GLAUCOMA WITH UNUSUAL FEATURES.

CHARLES W. KOLLOCK, M.D.,

CHARLESTON, S. C.

Although glaucoma is almost an everyday occurrence in the experience of those who have large private practices and are in charge of the eye dispensaries and hospitals of the large cities, still this disease continues to excite greater interest than any other ocular trouble, which is doubtless due to the fact that, even yet, much doubt remains as to its real etiology, and difference of opinion exists as to its treatment, as is plainly shown by the numerous theories constantly brought forward concerning the former, and the varied experiments that are being made in the latter. The cases here reported have seemed of unusual interest, though it is more than probable that with those of wider experience the histories will only be repetitions of what they have at times met.

On the 9th of December, 1889, Miss L., white, aged fifty, consulted me for her eyes. The left eye had been affected for more than a year by constantly recurring attacks of neuralgic pain, and now vision was failing rapidly. The sight was at times uncomfortable, but only occasionally was vision dimmed. An examination was made with the following results:

R. V. = 15/XL — with + 0.75, D. V. = 15/15. Anterior per-

forating veins were full and very tortuous; Tn.; anterior chamber well filled, and pupil normal in size and movements. The ophthalmoscope showed nothing of special interest beyond slight paleness of the papilla.

L. V. = 15/cc. with + 1.25, D. ⌣ + 0.75 D. cyl. 180°, V. = 15/xx. The anterior perforating veins were very full and tortuous; anterior chamber shallow; pupil somewhat dilated and T + 1. Ophthalmoscopic examination showed deeply cupped disk, with the retinal vessels climbing out over the edges; arteries pulsating beautifully, veins but slightly, and in this eye no symptom of glaucoma was lacking.

As the vision was so much improved by glasses I hesitated at first about advising an operation, but thinking that an eye in which every symptom of the disease was so well marked could scarcely escape destruction, especially as the attacks of pain and dimness of vision were becoming more severe, and the intervals shorter, an immediate operation was advised, and performed on the 11th of December. A large upward iridectomy was made, followed by considerable bleeding, which filled the anterior chamber. A weak solution of eserine (gr. 1/6 ʒi) was instilled, and the eye closed with a small piece of isinglass plaster.

On the 12th the eye was comparatively comfortable, but on the 13th the tension increased rapidly until it was + 3, and vision as quickly became nil. The solution of eserine was instilled every two hours with no beneficial result, and for two days the ball was of stony hardness, and vision absolutely gone. Knowing that unless something was done soon to reduce the tension total destruction of the globe would follow, I rapidly revolved in my mind the different procedures, viz.: a second iridectomy, posterior sclerotomy, and the employment of a stronger solution of eserine. Feeling sure that the patient would not willingly consent to a second operation, the use of a strong solution of eserine was decided upon, and accordingly the old stereotyped four-grain solution was at once instilled, —one drop every hour until a decrease in the tension was produced. The effect was magical, the tension quickly becoming normal, and vision as rapidly returning.

On the 20th, nine days after the operation had been per-

formed, V. = 15/cc; and with stenopaic slit at 180°, V. = 15/LXX. Examination with the ophthalmoscope now revealed an exceedingly interesting condition The extreme pressure upon the cornea in its weakened state had so changed its curvature that the ophthalmoscopic picture of the fundus was that of a highly irregular astigmatic eye, as was proved by the eye rejecting entirely the correction made before the operation was performed, and when a disc with a stenopaic hole was placed before eye, V. = 15/XXX (?). Headaches being caused by the stronger solution of eserine, the weaker was substituted, and tension has since remained about normal. The anterior chamber has regained some depth, the pupil contracted slightly, and all pulsation of the arteries has ceased. As vision did not increase beyond 15/LXX, she was placed upon ascending doses of strychnine from gr. 1/30 t.i.d. to gr. 1/10 t.i.d., and vision slowly improved until, with the slit at 180°, she could read some of 15/XXX, and with the stenopaic hole some of 15/XX. She was now advised to wear glasses constantly for distance, and the following were ordered:

R. + 0.75, D. s. L. + 2.25 D. cyl. 180°. In the meantime the weaker solution of eserine has been instilled at intervals, the tension kept at the normal, and the perforating veins are much less conspicuous on the left (worse) eye. No ophthalmoscopic changes have been noted in the right eye, and as tension and vision remain normal, no operation has been advised. The interesting portion of this history is the alarming increase of tension that followed the operation; the length of time (two days) it continued; its rapid fall under the influence of the stronger solution of eserine, which the weaker failed to effect; the entire change in the refractive condition from the great pressure, and the satisfactory improvement of vision under large doses of strychnine.

CASE II. — On the 19th of February, 1890, Mr. H., aged 56, white, a man of rather full habit, but anæmic and rather flabby in appearance, came to have his left eye examined on account of failure of vision. He said that five or six days before his visit, while suffering from an attack of the "grip" and indigestion, he was suddenly taken with a most intense pain in the top

of his head and left temple. After having been relieved he thought the vision of the left eye was not as good as usual, but there had been no pain in the eye. Externally the left eye showed nothing worthy of note, in fact, did not attract as much attention as its fellow, the lids of which were constantly twitching from some chronic affection. An examination revealed the following conditions: no external inflammation, anterior chamber normal in depth, pupil natural in size and appearance, V. = l. p., and very large objects were indistinctly seen, and with the ophthalmoscope all media were proved transparent.

The disk was typically "choked," the vessels not seen until they emerged from its edges. The fundus was a most beautiful picture of retinal hemorrhages, linear, round, and irregular in shape, especially confluent over the macular region, and here and there completely concealing the vessels. There were numerous remains of old hemorrhages and the white dots and spots so often seen in albuminuric retinitis. Albuminuria was immediately suspected, but an examination of the right eye was absolutely negative, and with + 0.75 D. s. V. 15/15. The urine was next examined, sp. gr. found to be 1018, and tests for albumen proved it to contain about one-fifth its volume. Under the microscope a few granular casts were found. I felt certain that it was a case of albuminuric retinitis, but had never met with a case where but one eye was affected, though it occasionally happens. The patient was referred to his family physician, with a report of the examination, but a positive prognosis was withheld, owing to the fact of but one eye being affected.

On the 29th of March (more than a month later) he returned for another examination. Externally the eye was slightly suffused, and he said it was at times a little painful. Vision was nil. The ophthalmoscopic examination gave a totally different picture from the former in many respects. The numerous hemorrhages last seen had, with few exceptions, been entirely absorbed; the papilla had lost its rough and striated appearance, and now closely resembled the delicately pink-tinted cloud of a summer sunset, beneath which, as silvery cords, the vessels were seen approaching the edges, and then disappearing, to appear again farther away as bright silvery lines, a few of which have

tinted centers, proving them still pervious to the trickling blood current. Many white spots were irregularly scattered over the fundus, and especially in the temporal half between the papilla and macula were numerous small spots.

April 8th. The eye was more inflamed and painful, ciliary injection marked, pupil not dilated, T + 1; the interior cannot be illuminated. The tension continued to increase steadily until the eye became of stony hardness, the anterior chamber became shallow, the pupil dilated, pain was intense, and neither pain nor tension was affected by eserine.

On the 16th of April posterior sclerotomy was performed, with the hope of relieving tension and pain; but though the former was reduced somewhat for a few hours, the latter continued unabated. This operation was chosen instead of iridectomy, on account of the known weakness of the retinal vessels, as had already been fully proved by the numerous hemorrhages, and if a rupture occurred from the sudden relief of tension by performing an iridectomy, the entire contents of the globe would necessarily be forced out. Nothing relieved his sufferings now but morphine, and in a lesser degree antipyrine, so that, on the 3d of May, enucleation was advised and performed. Recovery was from this time rapid, and now he wears an artificial eye with comfort. In appearance he is much improved, the complexion being less muddy and typically albuminuric than when first seen. The urine still contains albumen, and at a recent examination some casts were found. That this was a case of retinitis apoplectica, or hemorrhagica, is undoubted, but, complicating as it did a case of chronic Bright's disease, the mistake in thinking it albuminuric retinitis seems excusable.

Wells gives as causes of retinitis apoplectica, disturbances of the general circulation, caused by liver, heart, or uterine disease. No heart trouble existed in my patient; the liver was not examined; but as disease of the kidneys was present, that must have been the exciting condition. This and the exposed life he led — being sheriff of one of the largest and most malarial coast counties of South Carolina — must have brought on the hemorrhagic attack. The gradual sclerosis of the retinal vessels brought on the glaucomatous attack, not suddenly, but

insidiously, first producing but a suffused appearance of the globe, occasional twinges of pain, and failure of the little remaining vision. Even as the globe became harder, the pupil dilated but slowly, and the cornea remained transparent to the end. A section of the globe, after removal, showed the disk plainly cupped. My reasons for reporting these cases are that both had unusual features that seemed worthy of recording, and which must be of benefit to those, like myself, whose experience is still limited.

DISCUSSION.

DR. HENRY D. NOYES, of New York. — It is worth while to say a word in regard to the second case. The occurrence of glaucoma in a case of albuminuric retinitis is rare, although it is occasionally seen. Likewise the affection of one eye in kidney disease is unusual, but I have seen it. I think that the remarkable thing about such cases is that glaucoma does not more frequently happen than it does. My assumption is that the second case is one in which there was true kidney disease. In such disease there is a secondary result — extensive changes in the vascular system. Recent studies clearly point to the fact that the essential feature of glaucoma is such a change in the vessels. It is therefore remarkable that the two things do not come together more frequently. The entire loss of the organ is not remarkable. Posterior sclerotomy, which is rather rarely performed, is looked upon as a resort in hopeless cases, as a substitute for enucleation. I have heard of one or two cases in which it proved effectual after iridectomy and anterior sclerotomy had failed. I have tried it in one case which proved entirely unsuccessful.

TRANSIENT AMBLYOPIA WITH BITEMPORAL HEMIANOPSIA IN A CASE OF MALARIAL CACHEXIA.

GEO. C. HARLAN, M.D.,

PHILADELPHIA, PA.

This case was the subject of a clinical lecture at the Pennsylvania Hospital by Dr. Da Costa, not yet published, and the following brief abstract is from the notes of the resident physician, Dr. Jos. Leidy, Jr.

T. B., aged 22, a sailor just arrived from a southern port, was admitted to the hospital, Sept. 2, 1889, suffering with a chill at the time, and with the history of several chills, followed by fever, while on shipboard. During the following month he exhibited various nervous symptoms, such as outbreaks of mania, neuralgic pains, hallucinations of sight and hearing, perversions of the senses of taste and smell, violent headaches, sensory paraplegia, and disturbance of coördination.

He was treated with quinine, sixteen grains daily, and after, wards with iodide of potash, but without result, except that there never was a return of the chill. Subsequently, the use of Fowler's solution was followed by decided temporary improvement. The hallucinations of sight and hearing returned, however, and, on Nov. 12th, there was another outbreak of mania controlled by hyoscyamine.

On Nov. 14th, he complained of dimness of sight, and inability to see at all to either side, stating that he "was like a horse with a big pair of blinders," and could see only directly in front of him. He staggered in walking, and could not stand with his eyes closed. He was referred to me for examination of the eyes, Nov. 14th. The ophthalmoscopic appearances were found absolutely normal, but vision was very much diminished (V. 1/cc), and existed only in small nasal fields, which were sharply defined and perfectly symmetrical. These charts represent them, in a scale of one space to 2.½″, as taken on a flat field at a distance of 12 inches. Their actual dimensions at this dis-

O. D.

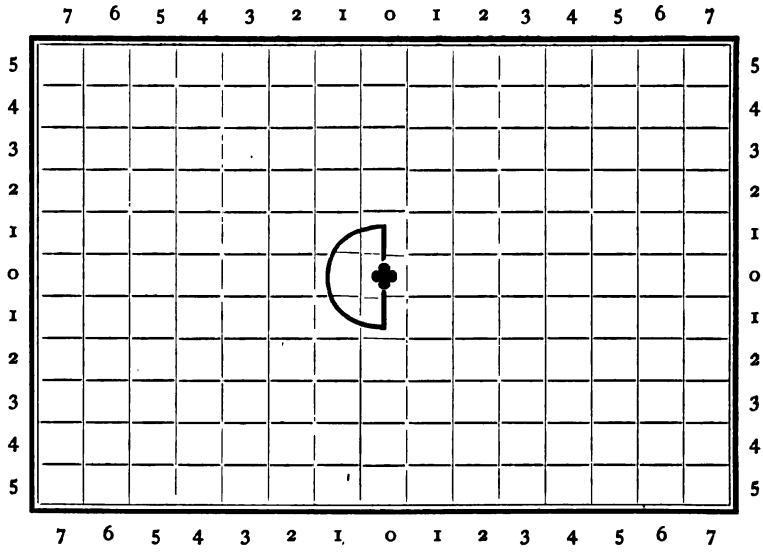

Scale 1 to 2.5″. Distance, 12 inches.

O. S.

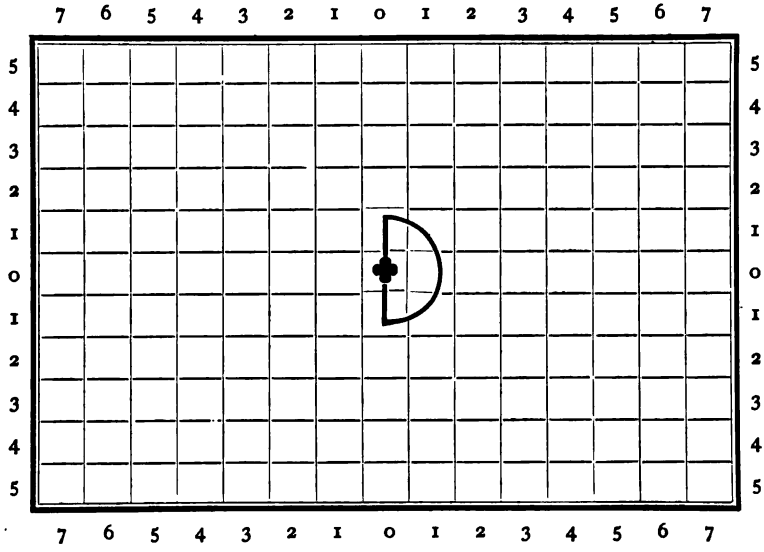

Scale 1 to 2.5″. Distance, — inches.

tance were 5 by 2½ inches. A second examination, made on the 16th, showed no change, but on the 18th, the patient rather suddenly became entirely blind. On the 19th, he could see light and recognize colors on the nasal fields, but could not distinguish objects, and there was no perception on the temporal sides.

All therapeutic attempts having, so far, practically failed, and the pathology of the case remaining obscure, Dr. Da Costa, excluding all other probable causes, returned to the abandoned theory of malaria, and had a microscopical examination made of the blood. This showed the pigmented corpuscles in great numbers. Quinine was given in doses of twenty-four grains daily, and decided improvement in all the symptoms appeared at once. Vision returned, first to the nasal fields, and extended rapidly to the temporal, and on the 24th was reported as normal. Repeated examinations of the blood showed a daily decrease in the number of pigmented corpuscles, and on the 30th they had entirely disappeared. The patient was discharged, quite well, on the 5th of December, and when seen, two weeks afterwards, had had no return of any of his symptoms.

This case is of interest on account of the unusually well-established connection between the symptoms and the cause, and the peculiar form of the visual disturbance. Amblyopia as a result of malarial disease was frequently reported before the invention of the ophthalmoscope, and since then retinal hemorrhages, retinitis, retino-choroiditis, peripapillary œdema, neuritis, and optic atrophy have, in a considerable number of recorded cases, been referred, with more or less probability, to malaria as a cause; while in others decided visual disturbances have been observed without any changes discoverable by the mirror. According to Nuel,* ocular affections without ophthalmoscopic changes are more likely to occur in marked cases, accompanied by little fever and of difficult diagnosis; in other words, in obscure cases of malarial cachexia, like the present. Poncet,† in an extensive experience in Africa, found ophthalmoscopic changes in only ten per cent. of his cases of pernicious intermittent and malarial cachexia; but states that in a large

* Landolt and Wecker.

† Annales d'oculistique, May, 1878.

number of post mortem examinations the microscope showed pathological conditions that the mirror had failed to reveal, and that retino-choroiditis was the rule.

In nearly all cases of malarial amblyopia, either with or without changes in the fundus, the field of vision has shown permanent or variable scotomata or concentric limitation or both, and bilateral hemianopsia has been observed by Peunoff and by Reich,* but I have been unable to find a case of bitemporal or binasal hemianopsia.

The pathology of these cases, even where well-marked lesions are found, is obscure. Galezowski † suggests pigmentary emboli as the cause, and Poncet ‡ takes strong grounds in favor of this view. The latter found the capillaries of the papilla containing only white globules, with each a black spot in the center, the same pigmented globules on the retinal and choroidal vessels in quantities inversely to the size of the vessels and numerous pigmented emboli on the external layers of the retina. The claims that this pigment gives a grayish tint to the swollen disk of neuritis as seen by the ophthalmoscope. The pathology of these cases, in which the mirror shows no changes, is still more unsatisfactory, and Poncet cuts the Gordian knot by insisting that these also are, nevertheless, instances of retino-choroiditis.

Bitemporal hemianopsia always presents a discouraging problem, and this case is by no means an exception. The exact symmetry of the small nasal fields and their sharply defined outlines, as well as the absence of visible changes on the fundus, preclude the probability of local lesions and locate the cause of the ocular symptoms in the brain. Frerichs § discusses convulsions, paralysis, headache, mental derangement, etc., in connection with pigment deposits in the brain, and says, "That the deposits of pigment in the substance of the brain and the abnormal central symptoms are connected with one another as cause and effect, is a probable supposition which acquires the more weight from the fact, that in general there is an unmis-

* Quoted by de Schweinitz, Med. News, June 7, 1890.

† Journal d' Ophthalmologie, I, 1.

‡ Loc cit.

§ Clinical Treatise on Diseases of the Liver.

takable correspondence between the intensity of the two, hence the earlier observers had no hesitation in attributing the central symptoms to the occlusion of capillaries with pigment." He, however, gives his reasons for withholding his unconditional support from this view, and in the present case the promptness and completeness of the recovery make such coarse lesion as cerebral embolism more than improbable.

Wecker* suggests, as an explanation of a case of recurrent transient bitemporal hemianopsia, an insufficient supply of blood in certain regions of the brain supplied by symmetrical arteries, and it is conceivable that something of the kind might occur from spasmodic contraction of vessels.

CASE II.—COMPLETE PARALYSIS OF THE LATERAL MOVEMENTS OF BOTH EYES—ABILITY TO CONVERGE REMAINING INTACT.

B. L. MILLIKIN, M.D.

CLEVELAND, OHIO.

The following case, a unique one in my own experience, I present, both on account of the interest in the case itself and in order to elicit some opinions on the diagnosis of the case: M. McL., aet. 33, married, born in Ireland, laborer, presented himself at the Outpatient Department of the Western Reserve University, March 21, 1890, with the following history: Twelve or thirteen years ago first noticed that he saw things double, but this passed off in a short time. He can remember no other symptoms; occasionally since then he has seen double, but he is not able to give any definite information about these attacks. Six or seven weeks prior to the time I first saw him, he states that he had an attack of the grippe, and since that time he has had a great deal of pain in the head, in different parts, quite severe at times, and he has been much annoyed by the double images. The patient is a large muscular looking-man, weighing 190 to 200 pounds, somewhat stupid in his men-

* Maladies des Yeux, p. 384.

tal make-up, and has been addicted to the excessive use of alcoholic stimulants for ten or twelve years. Denies any history of syphilis. Examination shows in each eye V = $\frac{6}{9}$ (?) In his winking, one notices that the left eye does not close nearly so quickly or fully as the right, as if acting very sluggishly, but it does close by forcible use of the orbicularis muscle. When an object is carried up or down before the eyes, they follow it perfectly well and freely; when, however, the object is carried to the right or left of the median line, both eyes are firmly fixed, and in no position of the field can the eyes be seen to turn laterally. When we ask the patient to fix the finger and this is carried toward the eyes, the two eyes are seen to converge, so that the finger may be carried to within seven or eight inches of the eyes, they still fixing in the median line. Pupillary reaction is normal in both eyes. The ophthalmoscope shows each optic disc small, round, with a narrow choroidal ring, a slightly deepened pearly color, a slight degree of H., and fundus otherwise normal. The general condition of his nervous system was examined by my friend, Dr. H. S. Upson, who reported no paralysis or anæsthesia of the upper or lower extremities, knee-jerk fairly marked, equal, no ankle clonus, and no tenderness on percussion over the skull. The only history of any illness we can find is that he had an attack of malaria about three years ago, lasting four or five weeks. The patient was ordered gr. x. of potass. iodid. three times daily. One week later he returned, the right eye especially showing very perceptible lateral motion, with vertical movements free. The excursion outwardly of the right eye was well marked, while the inward excursion was much less. The left eye would barely turn beyond the median line outward. I should have been disposed to attribute great virtue to the use of iodide of potassium had I not taken the precaution to inquire if he had taken the medicine, when he informed me that he had spilled it, and had only taken a few doses.

On April 4th, I again saw him when I found the lateral movements of the right eye seemed to be quite normal, while the condition of the left eye was improving with very perceptible movement of the eyeball outwardly beyond the median line, but the movements of the eye very plainly still lagged

behind those of its fellow, in both lateral directions; much more so, however, when the object was carried to the patient's left. The other movements of the eyeballs continued normal. The iodide of potash had been continued. Since this date I have not seen the patient, and do not know the final outcome of the trouble. The only indication of there being, or having been, any other paralytic symptom about the face, other than of the eye-balls themselves, was the slight impairment of motion observed in the left eye in winking.

The case seems to me unusual in the paralysis being confined to the eyes alone, the trouble being an acute one, not being congenital, and subsiding so rapidly.

AN ANALYSIS OF THE OCULAR SYMPTOMS FOUND IN THE THIRD STAGE OF GENERAL PARALYSIS OF THE INSANE.

CHARLES A. OLIVER, M.D.,
PHILADELPHIA, PA.

These observations and their deductions, which form a part and, in fact, conclude those which were presented to the society at its last annual meeting, are here given in hope of offering a few more facts to the ocular symptomatology of the disease.

As before stated, care was taken that each subject was seemingly free from any gross extraneous disease or local disorder, and discretion was exercised that competent and authoritative medical opinion had been given as to the type and stage of the general complaint; also, for reasons given at that time, the study has been limited to the male sex.

In a disease of such complex symptomatology, where, doubtless, quite a number of pathological peculiarities exist at one time, accurate pathognomonic changes cannot be expected in each case, and for this reason a great number of seemingly similar cases have been studied in the effort to obtain an idiocratic picture of a few of the oculo-motor and retinal changes to be found in this disorder. However, as the disease seems, as

shown by the microscope, to expend its greatest force upon both the motor and sensory regions of the cerebral cortex with involvement of the related higher mental areas, the symptoms which are improperly described as paretic only, assume types of both motor and sensory derangement with associated mental peculiarities of a distinctly related character. As a part of these the ocular apparatus, with its six channels on each side to the cortex of the brain, becomes not only a useful situation to study these changes, but is really invaluable as an exponent of intracranial changes.

OBSERVATIONS.*

First. Direct vision for form was reduced in every instance, where obtainable to any degree of certainty.

Second. Direct vision for color was subnormal in the few instances where it could be properly studied, showing itself more particularly for the colors green and red.

Third. Accommodative action: though impossible to obtain any reliable results by various subjective methods, yet by objective means (retinoscopy) it was seemingly lessened in every unequivocal case tried.†

Fourth. Visual fields: no determinate answers could be gotten.

Fifth. Pupils, as a rule, were somewhat larger than normal.

Sixth. Pupils were ofttimes unequal in size, and in some instances had a difference of one or two millimetres in their longer diameters.

Seventh. Pupils were frequently oval and ovoid in shape; their long axes being opposed to one another or placed at equivalent angles.‡

Eighth. The pupillary border of the iris, in several instances, was quite irregular in outline, without any visible evidences of localized inflammatory change.

Ninth. Changeability of pupillary form still persistent in

* A portion of these observations will form a part of the Fifth Annual Report of the Ophthalmological Department of the State Hospital for the Insane at Norristown, Penn.

† Curiously one case, upon several occasions, gave distinct ophthalmoscopic evidence of spasm of accommodation.

‡ It must not be forgotten that the pupils of many mentally healthy, present similar characteristics, especially in cases of astigmatism where asthenopia is complained of.

one case that had been so noted in the second stage of the disease.

Tenth. Irides were devoid of any gross peculiarities in comparative tint.

Eleventh. Irides, as a rule, were either extremely slow in response or absolutely immobile to the strongest light stimulus, though fairly responsive to efforts for convergence and accommodation.

Twelfth. The iris of the larger pupil in some instances was not so responsive to light stimulus as its fellow, this inequality of action seeming to bear no relation to the degree and character of the refraction error, and in some cases seemingly free from the apparent amount of objective optic-nerve change.

Thirteenth. The secondary movements of the iris were almost, if not entirely, lost in all instances in which light stimulus produced a reflex act.

Fourteenth. Irides, in quite a number of cases, were very feebly responsive to efforts for accommodation and convergence only; the want of this character of action being very changeable and unequal at the same time upon the two sides.

Fifteenth. Irregular and incomplete dilatation of the pupil followed the employment of strong solutions of atropine — sufficient to give full mydriasis in ordinary subjects — the comparative positions of the greatest amount of partial results being unequally situated at fifteen to thirty degrees differences, although several cases yielded peculiar and fantastic forms.

Sixteenth. Insufficiency of the interni was noted in several cases, though on account of the mental condition of the subject, nothing could be positively determined.

Seventeenth. Ataxic nystagmic motions of the extra-ocular muscles were present at times in a few instances, especially noticeable with the third and sixth nerve distributions, either in separated or conjoined action.

Eighteenth. The optic discs in many instances were decidedly and unequally semiatrophic; the degeneration being especially pronounced in the deeper layers and on the temporal side of the nerve.

Nineteenth. The capillarity of nerve substance was ma-

terially lessened, the greatest amount of blood supply being recognized in a rather narrow crescentic area to the nasal side of the disc.

Twentieth. The disc in a few instances was of a suffused and gelatinous appearance; its edges being plainly seen, and the surrounding retina somewhat œdematous.

Twenty-first. A series of minute venous and arterial loops in the retinal vessels on the disc were seen in one well-marked case.*

Twenty-second. The scleral ring was sharply cut all around and quite broad; this, as a rule, being more noticeable to the temporal side of the disc.

Twenty-third. Blackish crescents of pigment, broken and somewhat absorbed, beyond the scleral ring, at the outer edge of the optic nerve head were frequent.

Twenty-fourth. Pigment lines of different widths and varying degrees of absorption were seen beyond the scleral ring at the inner edge of the optic nerve head.

Twenty-fifth. Pigment layer of retina was, as a rule, diminished in thickness, the greatest amount of striation being seen at the superior and inferior borders of the optic disc.

Twenty-sixth. Retinal striation in a few instances was very pronounced, rendering the disc edges quite hazy.

Twenty-seventh. Retinal arteries were reduced in size, and sometimes slightly tortuous.

Twenty-eighth. Retinal veins were somewhat undersized and quite tortuous in a number of cases.

Twenty-ninth. Blood currents of the retinal vessels were apparently normal in tint.

Thirtieth. A few lymph reflexes were seen, these being generally situated in the walls of the main retinal stems.

Thirty-first. Fine pin-point opacities in the retina between the disc and the macula were seen in two cases; no other gross changes in the retina.

Thirty-second. The choroid was granular and disturbed in the majority of cases.

* Acquired syphilis was suspected in this instance.

Thirty-third. Refraction was generally hypermetropic with marked degrees of astigmatism.*

SUMMARY AND CONCLUSIONS.

1. The oculo-motor symptoms of the third stage of general paralysis of the insane, which consists in varying though marked degrees of loss and enfeeblement of iris response to light stimulus, accommodative effort, and converging power; lessening of ciliary muscle tone and action; weakening and inefficiency of extra-ocular muscle motion — all show paretic and paralytic disturbances connected with the oculo-motor apparatus itself, of greater amount and of more serious consequence than those seen in the same apparatus during the second stage of the disease.

2. The sensory changes of the third stage of general paralysis of the insane, which, though similar to those found in the second stage of the disorder, are so pronounced as to show a semiatrophic condition of the optic nerve head and a marked reduction in the amount of both optic nerve and retinal circulations, with consequent lowering of centric and excentric vision for both form and color, all indicate a degenerate condition of the sensory portion of the ocular apparatus, with impairment of sensory nerve action.

3. The peculiar local changes seen in these cases, which consist in conditions of the choroid and retina indicative of more pronounced local disturbance and irritation of these tunics than those found in the second stage of the disease, all represent the results of greater wear and tear given to a more delicate and a more greatly-weakened organ.

4. Both the motor symptoms and the sensory changes of the ocular apparatus, as thus described in the advanced or third stage of general paralysis of the insane, furnish not only evidences of a local disturbance of a more pronounced type than those shown in the second stage of the disorder, but plainly show themselves as one of the many peripheral expressions of fast-approaching degeneration and dissolution of nerve elements most probably connected with related cortex disintegration and death.

* Thanks are due to Drs. Henry Sidebottom and Henry C. Cattell, for their kind assistance during the study of these cases.

A NEW OPERATION FOR SYMBLEPHARON.

GEO. C. HARLAN, M.D.,

PHILADELPHIA, PA.

Cases of extensive and close adhesion of the lid to the ball are admittedly so difficult and often so unsatisfactory to treat that attempts at new procedures are always in order. When the adhesion has been stretched into a kind of band a good result can generally be obtained by dissecting it freely from the ball, doubling it in with its sound side toward the eye, and holding it in position by double threads passed through the skin and tied over a piece of buckskin or cork; but when the whole lid is firmly adhered to the ball, and the conjunctiva is destroyed, there has hitherto been but little hope of successful operation, except in the transplantation of a rabbit's conjunctiva. This operation, which is troublesome and difficult, has a history of some brilliant successes and a good many failures, with an unwritten history of a considerably larger proportion of the latter. The operation I am about to describe was suggested to me by the very respectable conjunctiva formed on a new lid which I had occasion to make of skin by a flap operation.

The patient was a young mechanic, who had suffered a severe injury of the eye from molten metal. Nearly all of the lower half of the ball was firmly adhered to the lid, and the eye was practically immovable. The lid was freely dissected from the ball until there was no limitation of the upward movement of the latter. An incision just above the margin of the orbit was carried through the whole thickness of the lid, which was separated completely from its attachments, except at either extremity, where a broad band was left. A thin flap a little wider than the lid was then dissected from the skin just below it, turned up, applied with its raw surface to the inner surface of the lid, and held in place by suturing its edge to the lid margin. This left a deep cul-de-sac, with sound skin turned toward the ball. Care was taken, in dissecting up the flap, not to separate it at its base line, but to carry the incisions a little

deeper there into the muscle, to allow it to be inverted without strain. The bare space left by the dissection was easily closed with a small sliding flap. The operation was done with antiseptic precautions, and afterwards the parts were freely dusted with iodoform, and covered with a bichloride compress. The wounds healed promptly, without a sign of suppuration.

Since performing this operation my attention has been called to one done by Snellen, which had escaped my observation before. They, however, have little in common, except the reliance upon nature to manufacture mucous membrane out of skin. Snellen makes a long skin flap from the cheek, with a narrow pedicle at the outer canthus, and passes it through a button-hole in the lid.

DISCUSSION.

DR. WILLIAM F. NORRIS, of Philadelphia. — I have seen one of the cases operated on by Dr. Harlan in this way. It struck me as a great improvement on our methods for the treatment of symblepharon. The case did well, although the adhesions were very extensive. I know of no other method that would have been likely to have given as good a result. The ball is free from all attachments.

DR. KOLLER, of New York. — How much transverse contraction of the flap has there been?

DR. HARLAN. — The time since the operation has not been sufficient to enable that point to be determined. I, however, do not expect any considerable contraction, as the nutrition of the flap has been very little disturbed.

TRANSIENT PULSATION OF RETINAL ARTERIES INDUCED BY APPLICATION OF HOMATROPINE.

GEORGE C. HARLAN, M.D.,

PHILADELPHIA, PA.

J. M., æt. 66, applied to me on the 1st of July, complaining that his sight had not been so good as formerly for several years, but had failed more rapidly in the last three months, and that he had a sensation as if of some obstruction before the left eye. No pain in eyes or headache. His pupils were of medium size and fairly responsive; cornea sensitive. Fields not restricted, and tension recorded as normal, or + (?). O. D. V. = 20/50, and some letters of 40. O. S. 20/50 (?). Suspecting the lens, I made an application of homatropine, which I do without fear, even in old people, as it is easy to control its effects by eserine. The lens was quite clear, but the ophthalmoscope showed an energetic pulsation of all the larger arteries of the disc. The disc was pale, though not decidedly changed, and there was a pretty well marked, though very narrow sclerotic ring. There was no decided cup, certainly not more than —.50 D, and no bending of the vessels at the margin, but a slight continuous curve. No other symptom characteristic of glaucoma but the pulse except, what I had not noticed before, some enlargement of the anterior ciliary vessels.

I applied eserine, and asked the patient to call again on the 3d. Then the pupil was of medium size, the same as its fellow, and no pulse could be discovered, even under partial dilatation with cocaine, but the slightest pressure on the ball produced it. Application of homatropine dilated the pupil to 6.5 mm., and the pulse reappeared. Eserine again applied. On the 7th the pupil in moderate daylight was 3½ mm. After dilatation to 6.5 mm. by homatropine, the pulse was this time so slight as to be almost doubtful. It occurred to me that the difference in his general condition might account for this. It was late in the afternoon; he was a night watchman, and had slept during the

day, while on the other occasions he was just off duty. Eserine was again applied, and he was directed to use a ¼-gr. solution at home, and to come next time in the morning, which he did on the 12th. The pupil was well contracted, and V. had improved to 20/40 (?). Homatropine again produced an energetic pulse. No pulse could be produced by homatropine on the other eye, though its external and ophthalmoscopic appearances were the same as in the right, and the slightest pressure caused pulsation. This case seems to me interesting as showing, in the most direct and positive manner, the effect of the mydriatic in increasing intraocular pressure.

A CASE OF METASTATIC CARCINOMA OF THE CHOROID.

O. F. WADSWORTH, M.D.,

BOSTON, MASS.

Several cases of metastatic carcinoma of the choroid have been reported in the last few years, but the number is not so great as to make it unadvisable, perhaps, to report the following one:

Miss T., 46 years of age, consulted me June 14, 1890. Three weeks before she had observed a blur before her eyes, and discovered that the sight of the right eye was much impaired. She thought there had in the interval been little or no change.

The left eye was of normal appearance in all respects; V. = 14/15 +. The right eye appeared normal externally; the media were perfectly clear; V. = 14/100; T. not increased. The lower portion of the retina was pushed strongly forward; the upper and upper lateral edge of the elevated portion was sharply defined and formed a regularly curved line, the highest point of which was situated very nearly at the center of the macula. From this point the edge curved gradually downward to either side, on the inner side curving below the disc and reaching somewhat to the nasal side of a vertical line drawn through the nasal edge of the disc, while on the temporal side it extended

to about an equal distance. All the upper part of this elevated portion presented a smooth surface, and the retinal vessels ran over it, curving sharply forward at its edge, of very nearly natural size and color and without losing their light streak, only the fine vessels running upward toward the macula being rather larger than normal. Rapid movement of the eye produced no change in the defined upper and lateral contour, nor in the level of the surface. The color of this part was rather lighter and more uniform than that of the upper half of the fundus, which was not very strongly pigmented. No vessels other than the retinal vessels could be made out. Well downward, and extending to the limit of the visible field, the retina appeared to be floating; it had lost some of its transparency, its surface was uneven, its vessels dark and winding. The disc and the upper half of the fundus apparently normal.

The opinion was expressed that in all probability there was a solid growth within the eye, and that in that case the eye should be removed. To settle the diagnosis, I proposed that a needle should be passed into the supposed tumor. This proposition was acceded to, and, under cocaine, a cataract needle was thrust through the sclera, 8 or 10 mm. to the inner side of the cornea and a little above the horizontal meridian, and, by the aid of the ophthalmoscope, its point directed to the upper central part of the elevated portion. The point could be very distinctly observed, was seen to reach the surface of the growth about 1 mm. (two-thirds disc-diameter) below the center of its upper edge, at a point where there was no visible vessel. It caused no depression of the surface, while a distinct resistance to lateral movement was felt. From the point of contact a small hemorrhage ensued, forming a bright red stripe, perhaps 1 mm. wide, extending downward over the surface of the retina some 5 mm. Five minutes later this did not seem to have increased.

It was only after I had advised removal of the eye that I learned the earlier history. Sixteen months before Dr. D. W. Cheever had removed the right breast for a cancer. The mammary tumor had existed for some time, was of moderate size, dense, and had puckered in the skin. There was no microscopic

examination, but no doubt was felt as to its nature. She had made a good recovery, and her general health had continued good. Dr. Durgin, who had seen her for a slight cough a few weeks before her visit to me, informed me that at that time there was a nodule the size of a bean in the cicatrix, which was said not to have enlarged in the two or three months since it was first noticed, and that there were no enlarged glands in the axilla. The idea of a cancerous deposit in the lung had suggested itself to him as the cause of the cough, and he had thought there was slight dullness at the lower part of the right chest; but the cough was readily thrown off, and did not recur.

Consideration of the fact that the ocular tumor was a secondary one, and that there were doubtless other deposits elsewhere, led me to change my proposition of immediate enucleation, and to advise that there would be no harm in postponing the removal of the eye until the growth should perhaps cause pain. The patient, however, after two or three days, decided for immediate removal.

I did not see her again until the time of operation, June 26th. Vision had rapidly failed after I first saw her, and there was now only perception of light. The iris reacted well to light, but there was no reflex from the pupil with the ophthalmoscope. The eye was enucleated, and placed in Müller's fluid.

July 1st, the eye was divided by a vertical section antero-posteriorly through the optic nerve. The vitreous was stained with blood, and a small, loose blood-clot lay in its lower part. The tumor was situated in the choroid, was light-colored, moderately firm, nearly circular, with smooth surface. It measured 10 × 12 mm., attained a thickness of 3 mm. at its thickest part, and thinned gradually toward the periphery, where it presented a rounded edge. Its most posterior part was at about the center of the macula, and its inner edge curved below and somewhat to the nasal side of the disc. Over fully the posterior half of the growth, and over the greater part of the fundus, the retina was in position; over the anterior part of the growth, and forward to the ora serrata, it was loosely detached.

Dr. H. F. Sears kindly made sections of the tumor. Microscopically it showed larger and smaller masses of cubical and

irregularly-shaped epithelial cells, with areas of hyaline degeneration, in alveoli formed by connective tissue stroma. It was in the choroid, and in places had invaded the inner layers of the sclera. The retina was not involved.

The ophthalmoscopic appearance was very characteristic of a solid growth, and the result of the puncture with the needle left no possible doubt. Although the hemorrhage which immediately followed the puncture was of very small amount, and a few minutes later had not increased, yet it must have recurred later and been the cause of the subsequent rapid loss of sight.

CAN HYPERMETROPIA BE HEALTHFULLY OUTGROWN?

B. ALEX. RANDALL, M.D.,

PHILADELPHIA, PA.

In the study of refraction and its anomalies, it might be claimed that little advance has been made, in spite of the immense amount of work that has been done in this direction, since the era inaugurated by the treatise of Donders. That treatise marks a stage to which some of the ophthalmologists of to-day have not yet attained; and while progress, real and considerable, has been achieved at many points, there is a large part of the profession which seems to close the eyes to this, and persists in holding views no longer sustained by the facts. One of the views thus adhered to is that of the general prevalence of emmetropia, an assumption that has its comfortable side, and its long list of authoritative upholders, yet is surely in conflict with the experience of every careful student. We have outlived Jaeger's teaching, that infants are born myopic; and have quite generally accepted the showing of all later investigators, that they are, almost without exception, hypermetropic. Yet the investigations which show hypermetropia in the majority of school-children have met less acceptance; and studies which even *define* emmetropia as "having normal vision" are offered as competent to prove the contrary; while the known preval-

ence of H. after loss of the accommodation is explained by a theory of "hypermetropia acquisita," backed by the great name of Donders.

Much as we have received from that master which seems destined to remain an enduring monument of his labor and insight, there is danger that admiration may go much too far in upholding hypotheses which he framed to fill the wonderfully few gaps in his knowledge of this difficult subject. Surely his pupils have ill-learned the lessons which he taught, if they insist upon the points which he himself held only tentatively, and try to maintain his unsupported dicta in the face of strong evidence. It is as a most admiring follower of Donders that I wish to call in question some of the views which to-day pass current largely upon the authority of his name; for I believe them to be erroneous, and would wish that his sanctioning of them should be forgotten. In a previous paper (read before the Ophthalmic Section, American Medical Association, May, 1890) I have endeavored to show that he did not hold the view generally adduced from his much misused paragraph as to "tone of accommodation," which undermines his formal definition of emmetropia; and in the present instance I would call attention to another misunderstood passage of his treatise—that on the frequency of the occurrence of myopia, page 341. He here gives a diagram, based principally on his case-books, to indicate the relative frequency of the various degrees of refraction-error in the Dutch population—a diagram which might be understood to indicate that Em. is about as common as the lowest grades of M. or H., were it not expressly stated that the lines representing these are only 1/10 of their proper length. In fact, then, he distinctly states that Em. constitutes less than 2.5% of the population, although he had made outside observations in order to correct the possibly erroneous indications obtained from eye-cases only. M.=1/96 or less, he reckons at 37.5%—the corresponding grade of H. at 45%; and it is only by counting these as practically emmetropic that the percentage 85% Em. is obtained. Donders is far from teaching, therefore, that Em. predominates; and although he indicates a larger proportion of myopes than of hypermetropes in his experience,

and that the medium grades of H. are not very common, his results are not extremely different from those which I would urge as correct.

In previous publications ("American Journal Medical Sciences," July, 1885; Transactions VII, International Ophthalmological Congress, 1888) I have brought together as completely as possible all the investigations, to date, of the refraction of the eyes of school-children and others, in the endeavor to learn what is the prevailing refraction of the human eye; with the result of showing a decided preponderance of H., a small percentage of Em., and a varying proportion of M., depending upon the age, class, and education of those examined. Divergent as were the results which had been obtained by various investigators, the consensus of them all gave distinct pointings; and critical study of the methods used in each examination rarely failed to give full explanation for the deviations from the average result.

Such results have hardly received wide acceptance, reiterated though they have been by many of the best students of the subject; and they have been given little of their due weight in practice. Theoretically it is generally conceded that all children, as well as the new-born, are usually hypermetropic; yet it is constantly being rediscovered as a new fact, peculiar to some special group of individuals, and is employed as a positive proof of any theory that needs support. The importance of refraction-errors in many cases is incontestible, and will be little weakened by such misuse of the facts; yet it does not speak well for the judgment of the profession that they are so prone to ignore or try to explain away these teachings, except when they have special employment to make of them.

Most of the investigations referred to were undertaken in order to throw light upon the etiology of myopia. They showed a disquieting rise in the percentage of this defect from the lower to the higher classes in the schools, and of course there were enthusiasts to raise a hue and cry, thunder at the overburdening of the scholars, and draw all sorts of wide-reaching conclusions from ill-determined and insufficient data. Reaction was inevitable; and Donders, whose dictum, "a myopic eye is a diseased eye," had been the war-cry of the crusade against myopia, led the recoil toward the view that myopia is a mere

evolutionary adjustment of the eye to its environment, and wrote, "Were it in my power to eradicate all myopia, I would not do it." To-day Cohn and others are contending that myopia is a curse of civilization, to be fought by the "school-physician" and his hygienic dictatorship; while Stilling and others regard all except the high grades with equanimity — rather proud of its prevalence in Germany, as a proof of the national evolution into special fitness for the highest civilization. Hypermetropia, it is held, is a condition of under-development common to the brute, the infant, the savage, and the idiot — it is put off with other childish things when the full stature of manhood is attained.

This view, with various modifications and corollaries, is quite widely held, having gained ground since it was advanced, especially by Landolt and Dor, some twelve years ago, and it is to it particularly that I wish to draw attention on this occasion.

The short hypermetropic eyeball has always been regarded as in a condition of under-development; yet it is a newer and less prevalent view, that hypermetropia is merely a *stage* of incompleteness. It is quite natural that further growth toward the emmetropic standard should be expected of this, as of other infantile organs; and this *a priori* view gains strength from the fact that, as Jaeger has shown, the infantile eye lacks some six mm. of its adult axial length. Add that infants are almost invariably H., often in considerable degree — while adults are assumed to be Em. — and the position seems hardly open to attack. Further, it has been claimed by some investigators that they have demonstrated this progressive decrease of the juvenile H. — as when Germann found the average H. to be 5.3 D. in the first month of life, only 3.3 in the second month, and 2.3 in the earlier years. Hansen also found an average H. = 1.75 in the tenth year, declining to 0.75 D. at the fifteenth.

Increase in the refraction of eyes, especially of children and young adults, has been frequently observed, not only in cases of progressive myopia, but in a considerable series of hypermetropic eyes, as has been recorded by Drs. Risley and Norris. Yet I fail to find in any of the instances any reason to believe that such a change has been brought about by a physiological growth; all have presented clear evidences of pathological pro-

cesses; and the combatting of these by the usual therapeutic measures for reducing intra-ocular inflammation has been followed by a relief of the distressing symptoms usually present, and by a cessation of the change in the refraction. Many of the cases alluded to I have had the privilege of studying, and I have had others in my own practice, so that I have some experience of the pathological form of change. But of an increase which could be regarded as healthy, I have met no single instance among many thousand cases.

In a lecture recently published, MacNamara urges that young hypermetropes, even those with absolute H., should not be given their correcting glasses, or even under-correcting lenses, for more than absolutely necessary use at near work, much less for constant wear; claiming that the normal development of the eye, whereby the H. would be outgrown, might thus be interfered with, and the defect rendered permanent. The same idea had previously occurred to me and led me to give under-correcting glasses to cases of high H.; for I had seen enough cases of this kind in which five years had brought no change in the refraction to feel confident that *under the full-correcting glasses* hypermetropia did not tend to decrease. I have since found occasion in some of these instances to increase the convex lenses, because the patient gave evidence of requiring fuller correction. In no case have I observed decrease in the hypermetropia; and I am now wholly skeptical as to it, and shall rarely repeat the experiment.

Inclining to reject this view, then, as unsupported by any facts derived from my own experience, and conflicting with much that I have observed, it remains to be seen if it is tenable in the light of the studies of the eyes of the children in the schools. Some supporting results have been already cited. Are they corroborated by the general result, or by other reliable investigations? My answer must be in the negative, since the small decline in the H. observed seems quite fully accounted for by the causes of pathological distension, which are known to be at work during childhood.

The study of the average refraction of children will be best begun by examining the findings as to the eyes of new-born infants, as to which five investigations are wholly available:

TABLE I.—REFRACTION GRADES OF NEW-BORN INFANTS.

Examiner.	H. Eyes	0.5	1.0	1.25	1.5	2.0	2.5	3.0	3.25	3.5	3.75	4.0	4.5	5.0	5.5	6.0	6.25	7.0	8.0	9.0	10.0	11.0	12.0	?	Ag. H	Av. H.
Germann, .	220	4	4	6	..	14	14	10	8	4	7	34	16	..	25	10	11	34	..	12	2	2	3	..	1073.	4.87
Ulrich, .	204	..	30	..	..	132	..	8	..	..	..	16	2	..	..	2	..	..	..	..	..	..	..	14	406.	2.14
Bjerrum, .	122	..	..	..	..	34	..	..	..	..	..	88	..	..	..	..	..	..	..	..	..	..	..	..	420.	3.44
Schleich, .	300	..	6	..	..	27	..	41	..	..	..	68	..	68	..	58	..	31	1	..	..	..	..	..	1368.	4.56
Horstmann,	88	..	16	..	..	16	..	36	..	..	..	14	..	4	..	2	..	..	..	..	..	..	..	..	244.	2.79
Total, .	934	4	56	6	..	223	14	95	8	4	7	220	18	72	25	72	11	65	1	12	2	2	3	14	3511.	3.80

TABLE II.—REFRACTION GRADES OF UNSCHOOLED CHILDREN.

Examiner.	H. Eyes.	0.5	.75	1.0	1.25	1.5	2.0	2.5	2.75	3.0	3.25	3.5	4.0	4.5	5.0	5.5	6.0	7.0	8.0	9.0	Ag. H.	Av. H.
Koppe, . . .	61	..	1	15	..	20	3	7	..	7	..	2	6	..	..	..	..	..	..	..	128.7	2.19
Horstmann, .	74	18	..	21	..	14	13	..	..	5	..	..	2	..	1	..	1	..	..	..	111.0	1 37
Horstmann, .	84	..	..	24	..	..	32	..	..	18	..	..	6	..	4	..	..	..	..	..	194.0	2.31
Germann, . .	119	10	..	22	3	16	17	22	2	1	2	2	8	7	..	2	2	1	1	1	276.2	2.32
Total, . . .	338	28	1	82	3	50	65	29	2	31	2	4	22	7	5	2	3	1	1	1	710 0	2.10

Some caution is probably necessary in accepting as general the results of several of the investigations, even though they give evidence of rather special accuracy. Their discordance with others, presumably as well done, brings their weight somewhat into question, and indicates that they may, though perfectly accurate, be accidental. Thus Germann found 19=11% of infants to have H.=9—12, and 50%, H.=4.5—8 in the first month; while later there were none over 8, and only 14=24% over 4 D. In his young children he found three eyes with H. =7, 8, and 9 D. respectively, 2=6, 2=5.5, and 7=4.5—only 14=12% over 4 D. Yet Schleich found but 1 in 300 as high as 8, and 31=7 D.; and none of the other investigators met any such grades. The high average hypermetropia shown by the table rests, therefore, upon the work of these two upon 520 eyes; while among 414 eyes examined by others the average was only 2.6 D.; and among 756 eyes as to which the grade is not specifically noted, the lower grades seem to have predominated—*e. g.*, 2—2.5 among Koenigstein's 562. Horstmann's very careful work was done after the first week of life, and it is highly probable that just as he saw practically nothing of the retinal extravasations frequently met in the first week, so too he did not see the accompanying swollen discs, the temporary prominence of which was probably measured by the others. Thus only can we understand the remarkable decrease of 2 D. in the average H. from the first to the second month of life (from 5.37 to 3.30) found by Germann. It seems probable that the average hypermetropia about birth is rather below than above 3 D.

Passing on to the results in young children not yet of school age (Germann's were from 1½ to 10, but unschooled), the few available records will be found in table No. 2, page 662.

Only Horstmann's earlier study differs from the rather remarkable coincidence of the other figures, with which a further study of his seems to have been in close accord. We may, therefore, accept this average as a little above 2 D. as shown.

Turning now to the results in the schools, and using as before every group of figures which affords the requisite data as to age and grade of refraction, we obtain from the studies of Callan, Dennett (Hyde Park and Nantucket), Howe, Emmert, Risley, Collard, Van Anrooy, Hansen, and Randall:—

TABLE III.—REFRACTION GRADES IN THE SCHOOLS.

Age.	H. Eyes.	+ 5	.65	.75	.90	1.0	1.25	1.50	1.75	2.0	2.25	2.5	2.75	3.0	3.25	3.5	3.75	4.0	4.5	5.0	6.0	?	Ag. H.	Av. H.
6 years, .	212	18	11	17	22	52	24	45	9	12	..	..	..	2	..	..	..	..	..	..	..	..	244 0	1.15
7 " .	222	15	6	18	19	58	22	43	20	16	..	2	..	2	..	1	..	..	..	..	..	..	282.5	1.27
8 " .	281	13	7	33	41	95	49	21	2	17	..	..	..	1	..	1	..	..	..	..	..	1	304.5	1.08
9 " .	366	14	10	62	34	89	38	45	36	20	2	..	..	5	..	..	2	3	..	1	3	2	452.6	1.23
10 " .	795	26	21	24	24	124	75	229	40	197	3	23	4	5	..	..	..	..	..	..	..	..	1180.7	1.48
11 " .	955	37	96	73	47	189	83	296	29	79	..	17	..	6	..	.	..	3	..	..	..	..	1186.0	1.24
12 " .	1044	54	26	69	57	300	92	288	60	52	2	14	3	10	2	5	..	4	5	..	1	..	1349.2	1.29
13 " .	889	39	32	91	38	296	96	178	49	40	..	12	..	12	1	3	..	..	..	..	..	2	1156 7	1.30
14 " .	849	183	32	93	44	218	64	115	51	31	..	4	..	9	..	3	..	1	..	1	..	..	922 4	1.09
15 " .	454	25	27	48	14	131	60	70	26	20	3	9	..	8	1	1	1	3	5	..	.	2	579.4	1.27
16 " .	381	23	21	41	23	113	40	61	23	18	4	1	..	3	2	..	..	4	..	1	1	2	481.3	1.26
17 " .	400	57	10	51	23	143	35	40	7	19	2	3	..	4	..	2	..	3	..	..	..	1	434 0	1.08
18 " .	338	61	18	54	6	99	21	41	4	18	..	2	2	2	..	1	..	5	..	1	1	..	369 3	1.09
19 " .	143	22	1	30	7	39	7	20	2	12	..	2	..	1	..	..	..	..	..	..	..	..	143 0	1.00
20 " .	50	13	..	6	..	17	5	5	..	..	..	4	..	..	..	..	..	..	..	..	..	..	51.3	1.03
21 or more,	151	31	2	30	..	39	4	6	1	4	..	3	1	15	..	2	..	10	3	..	..	..	217.0	1.43
Total, .	7530	631	320	740	399	2002	715	1503	350	555	16	96	10	85	6	19	3	36	13	4	6	10	9354 0	1.24

An almost unvarying grade of hypermetropia would seem to be the average during this period, for the utmost variation is less than .5 D., and even this may be regarded as perhaps accidental. Much of the variation is due to Hansen's figures —his 412 eyes, with an average H. = 1.75 at ten years and 242 eyes with only H. = 0.75 at fourteen, change the averages at those ages from 1.20 and 1.22 to 1.48 and 1.09 D. A very slight downward tendency appears when we sum up the results for each five years of life, the average grade being 1.31 for the second period, 1.24 for the third, and 1.13 for the fourth, that for the whole 7,530 eyes being 1.24 D.

Data are lacking from which to endeavor to compute the average H. in early adult life, Seggel's examination of recruits in the Munich garrison standing about alone. He found with the test glasses an average H. m. = .50 in over 3,000 eyes.

Such, then, is the evidence bearing upon our question which I am able to find in the literature — figures which, taken at their face-value, as all of equal weight, go but a short way toward proving any notable decline in the hypermetropia with the growth of the individual. Yet it requires no deep study of the investigations furnishing these results to convince one that that they are far from being all of equal value. Further, there are many studies which do not furnish their results in shape for our tabulation, yet are very distinct in their pointings, and probably more trustworthy than some of those used. The strongest case possible has been made for the view that H. is outgrown; and while I do not propose to undertake the invidious task of showing the flaws in the studies cited, I will point out some of the investigations which seem to me of much weight and offsetting more or less the results above given.

In his study at Schreiberhau under atropine, Cohn found the average H. of 299 eyes of children, 6 to 13 years of age, to be 1.20, with no relation of the grade to the age. Callan, among 346 eyes of negro pupils, found the average grade 1.23, present at all ages, from 6 to 19 years, with only accidental variations. Schadow, among the 240 H. eyes which he studied in Borchum, found an average of 1. at 7 to 8, 1.7 at 9 to 10, and intermediate grades at the other ages (6 to 14). Conrad found

an average H. about 1.26 among his youngest pupils (6 years), with rather higher grades in the next years. Emmert, among his 3,279 hypermetropic eyes, found an average of 1.16 in the 5 to 10 years, 1.38 in the 11 to 15, and 1.31 in the 16 to 20; the general average being 1.31 D.

Numerous other points could readily be cited in support of the conclusion which I have drawn from my study, that there is a very insignificant decline, if any, in the grade of hypermetropia during school life; and when the occurrence of quite frequent pathological progression toward myopia at this age is taken into consideration, the surprise must be that the decline is so little. Before the school period there is some evidence that higher averages of hypermetropia are to be found than later; but a number of considerations more or less completely explain away this apparent showing. All the reliable measurements of the refraction of the very young have been made under a mydriatic; and while very far from believing that this introduces any element of error, I must hold them as not strictly comparable with results obtained without mydriatics. The grades of hypermetropia met in such work have no need of being scaled down for the reason sometimes urged, that the mydriatic must be discounted because it gives a fictitious H. Properly used, the mydriatic can only have increased the accuracy of the results. But to make them really comparable, the averages found without a mydriatic most certainly need to be scaled up—increased by a considerable increment to represent the latent hypermetropia which escaped measurement. The use of the ophthalmoscope, which was all too rare in the investigations which have been above cited, can do something towards this end; but only an ultra-enthusiastic ophthalmoscopist could shut his eyes to its numerous shortcomings, and believe that its results could not be decidedly improved upon. One of the investigators quoted above (Koppe) suggests the discounting of his results on the ground that with the ophthalmoscope he was measuring hypermetropia of his own instead of that of the patient; yet a comparison of his objective and subjective results shows that while he uncovered H. in 35 eyes which had no manifest H., he failed to see the hypermetropia with the

ophthalmoscope in 105 eyes which had already revealed it to the test-glasses. Such results are common among the younger pupils; but my own study among medical students shows that the same holds among the elder. Not only did the ophthalmoscopic measurement raise the percentage of H. eyes from 26 to 67%, but it also increased the average grade from .57 to .85 D. So, too, Cohn found among his 299 atropinized eyes 98% H., and an average of 1.20, where without the mydriatic there had been but 82% H. m., with an average of .75 D. Reasons have already been given for the belief that the hypermetropia at birth is below 3 D.; and we here see that the 1.24 of school-life should be considered to represent a real average of about 2 D.; so I believe we shall not go far astray if we accept a dioptry and a half as representing the extreme limit of the real average decline in the refraction from birth to adult life.

Such a change in the refraction is far from unimportant, and would abundantly serve the purpose of those who claim that hypermetropia is outgrown, could they adduce any evidence that it is due to physiological growth. In the utter absence of any such evidence, so far as I am aware, and with the all too probable explanation that the pathological progress towards myopia is alone responsible for the change in the many, as it undoubtedly is in the few, the position of skepticism as to any normal decrease in hypermetropia seems fully justified. The burden of proof certainly rests upon those who wish to uphold such a view.

Two arguments deserve notice in closing. In twenty sections of the eyes of new-born infants V. Jaeger found the average axial length to be 17.5, as against 23.4 mm., in as many adult eyeballs. Yet these were by no means the shallow balls of high hypermetropia, for in almost every instance the axis was the greatest diameter of the globe, the vertical averaging but 16.4, and the horizontal 17.2 mm. While such an axial length in an adult eye might correspond with a hypermetropia of some 35 D., it must not be forgotten that the lens has its full adult thickness, although its diameter is only 6.3 instead of nearly 9 mm. Consequently its curvatures are such as probably, even in its comparatively homogeneous condition, to fully

compensate for the proximity of the retina. Whether it has a proportionately forward position, as indicated by the shallow anterior chamber, need not be discussed until some evidence is brought forward to show that the other compensation would not be complete. If it can nearly compensate, as we know it to do, for so huge a grade of axial shortening, it will be difficult to prove that it is not fully competent—however wonderful it may seem that the eyeball should undergo such changes in its dimensions without alteration of its refraction. It is quite probable that many of the cases of myopia found at birth, some of which have been observed to decrease greatly in the following months, have been due to a forward displacement or subluxation of the lens.

The other point that deserves a passing notice is the view that the tendency towards myopia is an evolutionary adjustment of the eyeball for the demands of near-work which environ it in modern civilized communities. Until the proof, yet lacking, is adduced to show that myopia is actually inherited, such a view has no claim to be treated as even a scientific hypothesis; and its demonstration is almost impossible. It has been repeatedly observed that scoliosis and myopia were developed together by the faulty positions of school-children, especially in writing; and whoever undertakes to champion the evolutionary value of myopia, may well be challenged to uphold the same view as to spinal curvature.

DISCUSSION.

DR. WILLIAM F. NORRIS, of Philadelphia.—An interesting point is made as regards the refraction of the eyes of the newly-born The tables of Dr. Randall would show a much higher degree of hypermetropia than my own limited experience would have led me to expect. Many years ago, through the kindness of Dr. George Pepper, I had the opportunity of examining the eyes of newly-born children at the Philadelphia Hospital. Atropine was used sufficiently to cause dilatation of the pupil without paralyzing the accommodation. Some forty odd cases were examined, showing hypermetropia from .75 D. to 2 D. The ages of the children varied from one or two days to one week.

DR. CHARLES A. OLIVER, of Philadelphia.—In confirmation of what has been said by Dr. Randall, I would state that I have

been making investigations at the Pennsylvania Institution for feeble-minded children among different school-grades of imbeciles. A paper which I brought before you two or three years ago with reference to the eye of the adult male imbecile showed a persistence of hypermetropia,—a grade of cases where there had never been any use of the eyes. To my astonishment, this year and last year, when I pursued my investigations amongst those of the higher grades at that institution, I found a higher percentage of myopia than I think would be found among the mentally normal. I have thus far more than 50 cases: 35 or 40 of these cases show low grades of nearsightedness, varying from 2 D. to 3 D., with characteristic fundus changes.

EMBOLISM OF UPPER BRANCH OF RETINAL ARTERY WITH NORMAL VISION.

W. F. MITTENDORF, M.D.,

NEW YORK CITY.

I wish to place on record, in addition to a case which I reported to this society several years ago, where the presence of so-called cilio-retinal vessels was the cause which prevented total blindness, a second, in which the ascending branch only of the retinal vein was obstructed by the embolus, while the division of branches of the descending arteries was so favorable, that although vision was somewhat veiled, my patient retained almost normal sight, while in the lower part of the field of vision it failed totally.

A similar case with cilio-retinal vessels present was published some time ago by my friend, Dr. Birnbacher of Gratz, and Dr. Benson of London, but I have yet to learn from any published case that the power of vision was little or not at all impaired from the beginning of the treatment till the end, as it was in my case, which I am now to relate.

My patient was a German lady, 35 years old, a dressmaker, who shortly before the attack took charge of a new establishment, and, owing to pressure of business, was compelled to work late into the nights. In consequence of this arduous, sedentary

labor, she contracted indigestion and palpitation of heart, and, moreover, had suffered for several years from painful attacks of rheumatism in the right knee. While sewing black silk, on the evening of April 24th, at 11 o'clock, she was seized with a peculiar twitching of the right eye, and, simultaneously, seeing with it became very difficult. Believing this condition to be the result of overtaxing her eyes, she hurriedly went to bed, in the hope of recovering her normal sight the following morning.

The next morning her sight was better, but now she realized that she could not see in the lower half of the field of vision at all, as she declared, that if she looked at her husband, she could only see his head and chest, and nothing below that, all of which appeared to her highly comical. No material improvement occurring, she came to me on the fifth day after the attack.

The examination disclosed that the sight of the good eye was better than normal, also that the affected eye presented nearly normal power of vision, recognizing, although as if through a thin veil, the letters of the lowest line of Snellen's trial types at twenty feet.

The examination with the ophthalmoscope revealed a milky cloudiness of the upper half of the retina, while the macula lutea appeared somewhat more red than in the other eye, otherwise quite normal. The upper part of the papilla seemed somewhat veiled and reddened; the upper part of the arteria centralis retinæ was very pale and noticeable only in parts; especially was this the case in the smaller branchlets; the veins seemed but little changed.

In face of these marked changes of the retina, I could scarcely explain to myself the existing good visual power, until, after a more careful examination, I discovered that a small branchlet of the descending branch of the arteria centralis retinæ was given off soon after its beginning and near the center of the optic disc, which, turning upwards and crossing over the ascending branch, still on the optic papilla, took its course toward the upper part of the macular region, supplying with blood from the lower branch of the central artery this portion of the retina, which, under normal conditions, is nourished by

the ascending branch. This helps to explain the nearly normal appearance of the macula, and explained the normal acuity of vision at once.

I need scarcely remark that the rest of the field of vision was in conformity with the pathological condition; the power of seeing was entirely wanting in the lower half, in which part even strongly reflected light could not be seen. As it was impossible to produce pulsation of the upper branch of the artery or upon the veins, there was no difficulty in diagnosing an embolism of the arteria centralis retinæ superior.

A general examination of the patient by my friend, Dr. Warner, resulted in diagnosing hypertrophy of the heart, and faint valvular murmurs above the aorta.

In the course of time the sight in the direction below improved somewhat; the patient began to notice the movements of the hand. No marked degenerations seemed to have taken place in the vessels, as the consequent collateral circulation probably facilitated the nourishment of the retina.

The treatment of this disease is not very satisfactory. I think that digitalis to stimulate the heart, in the beginning, and corrosive sublimate and strychnia later on, have somewhat aided me. Massage should be resorted to at once, as later on it appears to be of little use.

DISCUSSION.

DR. THOMAS R. POOLEY, of New York.—Is it not usual that central vision is good in embolism of the branches of the retinal artery? That has been the case in the few observations that I have made, and also in those described by Dr. Knapp in the Archives of Ophthalmology.

DR. W. F. MITTENDORF, of New York.—In my cases of embolism of *one of the main branches of the retinal artery*, they were accompanied by sudden and great impairment of vision, and this was the case in nearly all the cases I have seen reported.

THROMBOSIS OF ARTERIA CENTRALIS RETINAE —LARGE RETINO-CILIARY ARTERY— CENTRAL VISION UNIMPAIRED.

O. F. WADSWORTH, M.D.

BOSTON, MASS.

It has been suggested that the presence of a so-called retino-ciliary artery might, in the event of embolism or thrombosis of the arteria centralis, serve for the preservation of central vision, but no instance of the kind has, so far as I am aware, been reported. The following case is, I believe, an example:

Katie C., 24 years of age, unmarried, weaver, discovered, on the morning of February 4, 1890, that the sight of her left eye was much affected. She had a headache at the time, but in other respects was well, and continued in her usual fair health. She had observed no special change in the sight until I saw her, a week later, Feb. 11th.

The external appearance of both eyes was normal. V. of either eye $\frac{14}{12}$. The right eye, except for a few dots of pigment on the anterior capsule, was quite normal. In the left eye, although central vision was perfect, the field was contracted to a small oval, measuring in its long, horizontal, diameter some 20°. The media were clear. The greater part of the disc and of the fundus for a wide extent around it was obscured by a uniform whitish haze, such as is characteristically seen in embolism or thrombosis of the central artery.

But in embolism or thrombosis of the arteria centralis it is characteristic that the haze appears most dense in the macular region, and here the macular region was wholly unaffected. Perhaps $\frac{1}{10}$ or $\frac{1}{12}$ of the outer part of the disc, and an area of the retina, measuring at the edge of the disc about a third of the disc diameter in the vertical direction, gradually widening as it extended outward, and at the center of the macula having a width of about $1\frac{1}{3}$ diameters, was entirely free from haze. This free area reached farther above than below the fovea, and the haze at its upper border was very well defined, at its lower bor-

der shading off imperceptibly. Except in this free area, the haze over a wide extent around the disc was sufficiently dense to hide or greatly obscure the vessels, only a few short portions of them on and close to the disc appearing with defined outlines; it completely hid the outline of the disc except for a short distance on the temporal side; toward the periphery it gradually faded.

A striking peculiarity was the presence at the edge of the haze, where it bordered the free area that extended outward from the disc, of several irregular wide bands of a more dense and brilliant white, recalling in tone the white, defined patches seen so frequently in albuminuric retinitis. These were not perfectly uniform in whiteness, but showed slight markings, as if they might have been formed by coalescence of smaller patches. They were sharply defined against the free area on one side, and although the haze reached in undiminished intensity to their other side, yet their brilliancy of tone was such that the definition was hardly less pronounced on that side also. Two of these bands (the word is not very closely descriptive) extended outward from close to the edge of the disc something more than half a diameter; two others were situated at intervals at the upper edge of the free area; a fifth extended downward and outward from a point about a diameter outward and downward from the fovea. The latter three suggested in shape and markings a length of large intestine.

For a moment or two the appearance of the fundus was puzzling, but the explanation was soon found. A retinal artery of considerable size emerged from under the outer edge of the disc a little below its horizontal diameter, described a semicircle on the disc, and then ran nearly a diameter straight toward the fovea, when it swung in a wide curve upward and outward to descend and branch something more than a diameter to the outer side of the fovea. From the point where it turned upward and outward on the retina a small branch ran outward and downward a little below the fovea. Evidently the circulation in the macular region was kept up through this artery.

Two days later, Feb. 13th, the haze was beginning to diminish. I spent some time in making a sketch of the fundus, and while I rested Dr. Cheney examined the eye again. He dis-

covered in a branch of the inferior temporal vein, some distance below and a little to the outer side of the fovea, an irregular movement of the blood column. The branch in question ran nearly horizontally and joined another of the same size coming from above and outward. The color of the blood in the latter branch, as in the larger vein formed by the union of the two, was normal. In the horizontal branch the color was much darker, the blood column was broken into lighter and darker masses, and these masses oscillated rhythmically to and fro, but at the same time advanced. Where the dark blood passed into the larger vein it flowed at first along its lower side, so that for

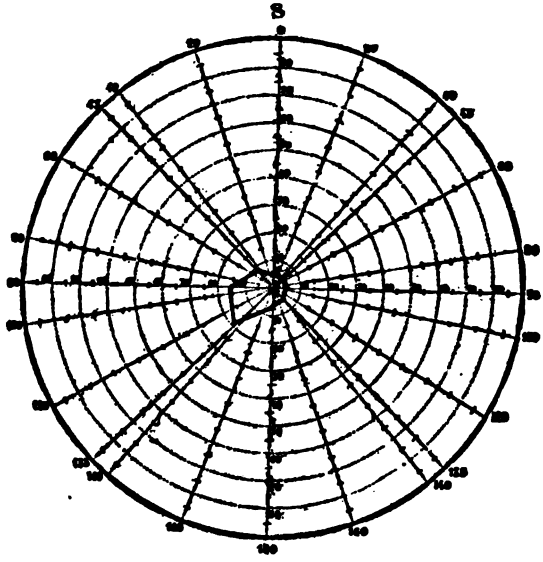

a short distance the darker and lighter currents ran along side by side, the darker gradually becoming narrower until, after a little, it could no longer be distinguished. Searching the fundus still farther I found a similar but less marked oscillation of a broken blood column in a branch of the superior temporal vein outward and upward from the macula.

Feb. 15th, the haze was less; the pulsation was still present in the two veins, but less pronounced.

Feb. 18th, the haze had cleared so much that all the larger veins and arteries could be seen on the disc and beyond, ap-

parently of full size; on the disc at least, all the larger vessels were now clearly defined. The dark-colored venous branches in which pulsation had been seen were now so nearly of the same color as the veins into which they emptied that no difference would have been remarked had they not been observed before; they showed no irregularity of current and had a well-marked light streak. Although the haze generally was much less, the "bands" were still well marked, but not quite so bright as before. The central vision was still $\frac{14}{12}$, and the field apparently unchanged.

From this time the patient was lost sight of, and the eventual result must therefore remain in doubt. Yet the fact that for two weeks central vision continued perfect makes it probable that it did not subsequently deteriorate. On the other hand, I am inclined to think that the retinal arteries (the retino-ciliary branch excepted) and veins did undergo more or less shrinkage.

That the only directly visible disturbance of circulation was observed in the veins might be held to point to a primarily venous, rather than arterial, affection. But the wide extent of the oedema of the retina, impartially distributed in all directions except towards the macula, can hardly be explained otherwise than by an interference with the blood-current in the main trunk, whether of vein or artery. And if the trunk of the vein were blocked there is no apparent reason why the district supplied by the retino-ciliary branch should have been in any way less affected than the parts supplied by the arteria centralis, and, moreover, distention of the veins, which did not exist, should have been expected. *Per contra*, the plugging of the trunk of the arteria centralis would rationally account for the peculiar distribution of the œdema.

It remains to account for the apparently undiminished size of the arteries. A certain amount of shrinkage from the original size there may have been, for the haze had not wholly disappeared when the patient was last seen, although on the disc the vessels were clearly defined. That may be explained, perhaps, on the supposition that the circulation was not entirely interrupted at the first, and that the plug was broken up or shrank afterward, but too late to admit a recovery of function in the parts of the retina from which nutrition had been largely cut off.

I have preferred to call the lesion here thrombosis rather than embolism because a very careful examination by Dr. W. W. Gannett failed to reveal any disease of the heart or large vessels, and because I believe the evidence indicates that thrombosis of the retinal vessels is the more common affection of the two.

PROGRESSIVE HYPEROPIC ASTIGMATISM.

EDWARD JACKSON, M.D.,

PHILADELPHIA, PENN.

There is little reason to doubt the correctness of the common belief, that in the great majority of cases astigmatism remains the same throughout life. But that the changes in the shape of the eye-ball in progressive myopia should sometimes involve the cornea was to be expected; and reported cases justify the expectation. At the meeting in 1867, Dr. O. D. Pomeroy narrated a case of presumedly acquired myopic astigmatism.

Increase of hyperopic astigmatism is, however, a different matter, for here we have not been led to expect the changes in the shape of the globe that occur in progressive myopia, although Risley and Norris have here reported cases showing that hyperopia diminishes by the same morbid processes as bring about an increase of myopia.

In 1885, Dr. S. Theobald reported here [see p. 29, Trans.] three cases of progressive astigmatism, one of which was hyperopic. In 1888 [see p. 60], Dr. J. B. Emerson reported another. At the meeting of the American Medical Association this year, Dr. O. B. Frothingham reported a third. All of these patients were young men, and the first measurement, and in the last two the later measurements, were made under atropia.

My attention was first drawn to the subject by the increase in my own astigmatism. Since then I have noted the following cases. They are all that I have met with in private practice, in which the change of the astigmatism in either eye amounted to 0.5 D., or over, the state of refraction having in each instance been carefully and repeatedly determined while the eye was fully under the influence of a mydriatic.

CASE I. My own. In 1880, aged 24, my refraction, measured under duboisin, took for its correction:

R. + 0.75 ⌒ + 0.50 cy. axis 90°. Vision = $\frac{4}{3}$.
L. + 0.75 ⌒ + 0.75 cy. axis 90°. Vision = $\frac{4}{3}$.

I put on my full correction and from that time wore it constantly. In 1882, in experimenting with various mydriatics, I measured my refraction when the eyes were fully under the influence sucessively of atropine, daturin, hyoscyamin, and homatropine, all the results agreeing exactly with that above given. Up to 1884, these lenses gave perfect vision and complete immunity from the headache and other evidences of eye strain that had been experienced before wearing them. At this time I was for some months engaged several hours a day in close eyework, in addition to that entailed by practice and ordinary reading. Headache, pain, and hyperemia of the eyes and blurring of distant vision were experienced. The discontinuance of the extra eye work brought considerable relief, but from time to time headache occurred, and it was noted that distant vision was not quite up to its former standard. This led me to again measure my refraction under homatropine, with the following result:

R. + 0 50 ⌣ + 1.25 cy. axis 90°. Vision = $\frac{4}{3}$.
L. + 0 50 ⌣ + 1.50 cy. axis 88°. Vision = $\frac{4}{3}$.

These lenses have since been worn with the same immunity from asthenopia as the others had given for the first four years of their use. Visual acuteness, and apparently the refraction, continue unchanged since that time.

CASE II. Miss S. D. H., aged 43, housekeeping, had suffered from pain in the eyes, injection of the conjunctiva, and excessive lachrymation. Under duboisin for several days, she accepted:

R. + 2 sph. Vision = $\frac{4}{4}$.
L. + 2 sph. Vision = $\frac{4}{4}$.

Three months later her refraction, again measured under duboisin, was the same.

Three years later, refraction without a mydriatic appeared unchanged, and distant vision with the glasses still $\frac{4}{4}$. She now required R. & L. + 3.50 for near work.

She was not under observation again until eight and one-half years after the first measurement of her refraction. She then came with distant vision with old glasses, reduced to $\frac{4}{8}$. Her refraction was now:

R. + 2.25 sph. ⌒ + 1. cyl. axis 15°. Vision = $\frac{4}{4}$.
L. + 2.25 sph. ⌒ + 1.50 cyl. axis 170°. Vision = $\frac{4}{4}$.

This correction was ordered for distance, and + 2.25 added for near work. One year later correction and vision the same. + 2.75 was added for near work. These she continues to use with satisfaction.

CASE III. Mr. E. S. P, aged 21, an architect, suffering from asthenopia, under duboisin was found to require:

R. + 1. sph. ⌒ + 1. cyl. axis 180°. Vision = $\frac{4}{4}$,
L. + 1. sph. ⌒ + 0.50 cyl. axis 180°. Vision = $\frac{4}{4}$.

The wearing of these glasses gave complete relief. Two years later he came back again, asthenopic. After keeping him under duboisin a few days:

R. + 1. sph. ⌒ + 1. cyl. axis 180°. Vision = $\frac{4}{4}$,
L. + 0.75 sph. ⌒ + 0.75 cyl. axis 180°. Vision = $\frac{4}{4}$,

were accepted.

Eight years from the date of the first correction he again returned suffering from asthenopia that had been increasing for several months. Under homatropine:

R. + 1.25 sph. ⌒ + 1.75 cyl. axis 175°. Vision = $\frac{4}{4}$.
L. + 1.25 sph. ⌒ + 1. cyl. axis 180°. Vision = $\frac{4}{4}$.

This was two years ago. His eyes continue comfortable.

CASE IV. Mrs. L. B. H., aged 33, keeping house, subject to headaches, and recently having difficulty with near work. Refraction measured under homatropine, and a few days later under duboisin, with the same result:

R. + 1.50 cyl. axis 95°. Vision = $\frac{4}{5}$.
L. + 0.75 cyl. axis 90°. Vision = $\frac{4}{5}$.

This correction was given and worn with relief of symptoms. Seven years later she returned, and her refraction under homatropine proved to be:

R. + 2. cyl. axis 95°. Vision = $\frac{4}{5}$.
L. + 1.50 cyl. axis 85°. Vision = $\frac{4}{5}$.

CASE V. C. S., a boy of 15, at school, had been wearing,

with comfort, until three weeks before, glasses ordered two years before by another surgeon, as follows:

R. + 0.50 ⌒ + 0.25 cy. axis 105°.
L. + 0.50 ⌒ + 0.50 cy. axis 80°.

Under duboisin his refraction now proved to be:

R. + 1. ⌒ + 0.50 cy. axis 95°. Vision = $\frac{4}{4}$.
L. + 1. ⌒ + 0.75 cy. axis 80°. Vision = $\frac{4}{4}$.

With these glasses and the somewhat prolonged use of the mydriatic he was relieved. Four months later he was put under the mydriatic, and showed no change of refraction.

Nearly four years later he again presented himself, on account of pain in the eyes preventing him from studying. Under homatropine his refraction now was:

R. + 1. ⌒ + 1. cyl. axis 90°. Vision = $\frac{4}{4}$.
L. + 0.75 ⌒ + 1.50 cyl. axis 78°. Vision = $\frac{4}{4}$.

CASE VI.—J. J., a boy aged 15, at school, complained of asthenopia. Under homatropine

R. + 0.75 sph. Vision = $\frac{4}{8}$.
L. + 1. sph. Vision = $\frac{4}{8}$.

He was kept out of school a few days, and then without glasses continued school and clerical work without headache or trouble from his eyes. Seven years later he came for asthenopia, and recent sudden failure of accommodation in the latter part of the day. Under homatropine he required:

R. + 0.50 sph. Vision = $\frac{4}{8}$.
L. + 0.25 sph. ⌒ + 0.62 cyl. axis 95°. Vision = $\frac{4}{8}$.

These were ordered for constant use and gave entire relief.

CASE VII.—P. H., a woman aged 47, had noticed impairment of vision, both near and distant, for a year or two, and increasing exertion required for eye work. Without a mydriatic she seemed to have 0.50 D. of myopic astigmatism, requiring the axis vertical, after repeated trials that gave the same result, I ordered for near work:

R. + 1. sph. ⌒ + 0.50 cyl. axis 180°.
L. + 1. sph. ⌒ + 0.50 cyl. axis 180°.

These gave some relief, but were not entirely satisfactory, and one year later, under homatropine, found she required the following correction:

R. + 1. sph. ⌒ + 0.50 cyl. axis 15°. Vision = $\frac{4}{5}$.
L. + 1.50 sph. ⌒ + 0.50 cyl. axis 165°. Vision = $\frac{4}{5}$.

Those were ordered for distance, and a + 1. sph. added for near work, and they for a time proved entirely satisfactory. But eighteen months after that she was again suffering. Her refraction now seemed without a mydriatic to require:

R. + 0.75 ⌒ + 1.50 cyl. axis 12°. Vision = $\frac{4}{5}$.
L. + 1.25 ⌒ + 1. cyl. axis 162°. Vision = $\frac{4}{5}$.

and after repeated trials this was ordered for distance with + 2. sph. added for near work; and again she was relieved. Subsequently + 2.50 was added for near work.

About five years from her first visit, she came with the history that vision had again been worse for some weeks; and under homatropine the correction was

R. + 0.75 ⌒ + 2 cyl axis 10°. Vision = $\frac{4}{5}$.
L. + 1.50 ⌒ + 1.25 cyl. axis 160°. Vision = $\frac{4}{5}$.

Again seven years and a half after the ordering of her first glasses, in February of the present year, her eyes again, under homatropine, she requires:

R. + 2. ⌒ + 1.75 cyl. axis 10°. Vision = $\frac{4}{5}$.
L. + 3. ⌒ + 1. cyl. axis 170°. Vision = $\frac{4}{5}$.

to which 3. D. sph. must be added for near work.

CASE VIII.—H. R., a man aged 21, stenographer, came for pain in the eyes and undue sensitiveness to light. Under homatropine, he required:

R. + 1. ⌒ + 0.62 cyl. axis 90°. Vision = $\frac{4}{3}$.
L. + 0 75 ⌒ + 0.75 cyl. axis 90°. Vision = $\frac{4}{3}$.

This correction suited him for nearly eighteen months. At the end of that time he returned; and his refraction tested under the same mydriatic needed:

R. + 1. ⌒ + 1. cyl. axis 90°. Vision = $\frac{4}{3}$.
L. + 1. ⌒ + 1.12 cyl. axis 90°. Vision = $\frac{4}{3}$.

Four months later he consulted another surgeon, underwent graduated tenotomy, and was given glasses that had a weaker spherical component. His eyes troubled him more after this than ever before; and six months afterward he came back to me. Under homatropine, his correction was:

R. + 1.25 ⌒ + 1. cyl. axis 97°. Vision = $\frac{4}{8}$.
L. + 0.87 ⌒ + 1.12 cyl. axis 85°. Vision = $\frac{4}{8}$.

Using these glasses, he says, "my eyes seem entirely well." It has been about ten months since the last correction was ordered.

CASE IX.—Mrs. J. H. S., wife of a physician, aged 36, came for occipital headache and weakness of the eyes, felt since the birth of her child, now six months old. Under homatropine she took:

R. + 0.75 sph. ⌒ + 0.25 cyl. axis 180°. Vision = $\frac{4}{4}$.
L. + 1. sph. ⌒ + 0.12 cyl. axis 180°. Vision = $\frac{4}{4}$.

The spherical alone was prescribed. She wore the glasses constantly for a time, then for reading and sewing only; and after that did not need them at all.

Three years and a half later, she came back suffering again from eye-strain, which her old glasses did not at all relieve. Under homatropine she now needed:

R. + 0.75 sph. ⌒ + 1.75 cyl. axis 155°. Vision = $\frac{4}{4}$ –.
L. + 1.25 sph. ⌒ + 0.50 cyl. axis 15°. Vision = $\frac{4}{4}$.

These were ordered eight months ago; she has not reported since.

CASE X.—Miss N. R. P., aged 20, at school. Headaches and sudden failure of accommodation, growing more troublesome for several months. With homatropine requires:

R. + 2.75 sph. ⌒ + 1.50 cyl. axis 108°. Vision = $\frac{4}{4}$.
L. + 2.75 sph. ⌒ + 1.50 cyl. axis 90°. Vision = $\frac{4}{4}$.

These she wore constantly for two years with great satisfaction, then began to have trouble again, and six months later consulted me again. With homatropine she now took:

R. + 3.25 sph. ⌒ + 2. cyl. axis 105°. Vision = $\frac{4}{4}$.
L. + 3.25 sph. ⌒ + 1.50 cyl. axis 90°. Vision = $\frac{4}{4}$.

Three months later she wrote that they were doing pretty well.

CASE XI.— Miss A. S., aged 15, at school, has had chronic marginal blepharitis, and for some weeks, failure of accommodation. Under homatropine, she takes:

R. + 0.75 sph. Vision = $\frac{4}{3}$.
L. + 0.50 sph. ⌣ + 0.50 cyl. axis 90°. Vision = $\frac{4}{3}$.

These she wore almost constantly for nearly four years. She then returned for asthenopia. And on using the mydriatic was found to need:

R. + 0.62 cyl. axis 90°. Vision = $\frac{4}{3}$.
L. + 1.12 cyl. axis 90°. Vision = $\frac{4}{3}$.

These have now been worn three years and a half.

CASE XII. Master F. M., aged 13, at school, came to me for headaches and imperfect vision, both near and distant. Under duboisin he required the following:

R. + 4. sph. ⌣ + 1 50 cyl. axis 95°. Vision = $\frac{4}{20}$.
L. + 4. sph. ⌣ + 2.50 cyl. axis 105°. Vision = $\frac{4}{12}$.

Eight years later he returned with a history of gradually increasing asthenopia for the last year or so, and under homatropine was found to need:

R. + 4. sph. ⌣ + 4. cyl. axis 97°. Vision = $\frac{4}{6}$.
L. + 4. sph. ⌣ + 3.50 cyl. axis 110°. Vision = $\frac{4}{6}$.

It should also be noted that before using homatropine for his last refraction test, his vision with his old glasses was R. $\frac{4}{8}$ partly, and L. $\frac{4}{6}$ partly, showing a great gain in visual acuteness, to offset the imperfect focusing.

CASE XIII. Master C. A. S., aged 13, at school, subject to "sore eyes" and frontal headache, under atropine needed:

R. + 0.75 sph. ⌣ + 0.50 cyl. axis 90°. Vision = $\frac{4}{4}$.
L. + 1. sph. Vision = $\frac{4}{4}$.

Ten months later, having had trouble with them for about six weeks, the glasses had been and were still worn constantly. In fact, he has never since that time been able to do without them. Under duboisin he now took:

R. + 1.25 sph. ⌒ + 1. cyl. axis 90°. Vision = $\frac{4}{4}$.
L. + 1.75 sph. Vision = $\frac{4}{4}$.

Four years after his first visit his refraction, again tested under homatropine, showed no material change. And at the end of six years and a half, under that mydriatic, he required:

R. + 1.75 sph. ⌒ + 1. cyl. axis 95°. Vision = $\frac{4}{4}$ +.
L. + 2.50 sph. ⌒ + 0.25 cyl. axis 30°. Vision = $\frac{4}{4}$ +.

Throughout the whole time his eyes have presented a high and troublesome positive aberration; that is, the center of the dilated pupil is more hyperopic than the periphery.

CASE XIV. Mrs. J. R., aged 31, housekeeping, came for headache and eyeache, worse after eye work. Under homatropine she took:

R. + 0.50 sph. Vision = $\frac{4}{4}$. (?)
L. + 0.50 sph. ⌒ + 0.25 cyl. axis 180°. Vision = $\frac{4}{4}$. (?)

These spherical lenses, without the cylinder, were worn with entire relief until nearly six years later, when the symptoms gradually returned. Tested now under homatropine she needed:

R. + 0.75 sph. ⌒ + 0.50 cyl. axis 180°. Vision = $\frac{4}{4}$. (?)
L. + 0.50 sph. ⌒ + 0.75 cyl. axis 10°. Vision = $\frac{4}{4}$. (?)

which was ordered for constant use. She was examined more than three years after her first visit, and her refraction at that time found unchanged.

CASE XV. S. J. W., aged 32, asthenopia worse after near work, and visual acuteness not so good as formerly. Under homatropine required:

R. + 0.75 cyl. axis 85°. Vision = $\frac{4}{5}$.
L. + 1. cyl. axis 95°. Vision = $\frac{4}{5}$.

These were worn constantly for four years. Then she began to suffer again after near work or during exposure to a bright light. The same mydriatic now showed a need for the following correction:

R. + 0.50 sph. ⌒ + 1.25 cyl. axis 80°. Vision = $\frac{4}{5}$.
L. + 0.50 sph. ⌒ + 1.25 cyl. axis 90°. Vision = $\frac{4}{5}$.

This patient shows in both eyes a notable degree of positive aberration.

CASE XVI. Mrs. E. R. B., aged 48, housekeeping, came for failure of near vision. Under homatropine she took:

R. + 0.25 sph. ⌒ + 0 25 cyl. axis 60°. Vision = $\frac{4}{6}$.
L. + 0.75 sph. ⌒ + 0.25 cyl. axis 120°. Vision = $\frac{4}{6}$.

Nearly five years later she returned again, and now required for distance:

R. + 0.50 sph. ⌒ + 1. cyl. axis 60°. Vision = $\frac{4}{5}$ partly.
L. + 1. sph. ⌒ + 0.50 cyl. axis 130°. Vision = $\frac{4}{5}$ partly.

She has quite noticeable irregular astigmatism, which accounts for her imperfect vision.

CASE XVII. Miss M. W. H., aged 17, came for headache and failure of accommodation after near work. Measured under homatropine she took:

R. + 1.25 sph. ⌒ + 0.50 cyl. axis 85°. Vision = $\frac{4}{4}$.
L. + 1. sph. ⌒ + 0.75 cyl. axis 90°. Vision = $\frac{4}{4}$.

Wearing these constantly, she had but little trouble with her eyes until three years later. Under homatropine she then required:

R. + 1.50 sph. ⌒ + 1. cyl. axis 95°. Vision = $\frac{4}{4}$.
L. + 1.50 sph. ⌒ + 1.25 cyl. axis 85°. Vision = $\frac{4}{4}$.

CASE XVIII. Miss N. R., aged 17, learning dress-making, came for headache and pain in the eyes aggravated, by near work. Under homatropine, and later under duboisin and daturin, she was found to need:

R. + 2.75 sph. Vision = $\frac{4}{4}$.
L. + 2.75 sph. Vision = $\frac{4}{4}$.

These glasses she wore constantly, but sometimes was troubled with headache. Two years later her eyes were on this account put under atropine. They then required:

R. + 3. ⌒ + 0.50 cyl. axis 65°. Vision = $\frac{4}{4}$.
L. + 3. ⌒ + 0.50 cyl. axis 110°. Vision = $\frac{4}{4}$.

Five years from her first visit her eyes under homatropine

show no farther increase of astigmatism. She wears the glasses, but they do not entirely prevent headaches.

In all of these cases the balance and strength of the ocular muscles were carefully tested and watched. In several of the cases apparent tendencies to deviation of the visual axes disappeared under the use of the correcting lenses; in several no such tendency was discovered at any time; in only one was there a marked persistent tendency of this kind, — this was case 7. When first seen he showed an esophoria of 2°, abduction 6°, adduction 20°. After this both abduction and adduction were at times considerably reduced. Two years after he first came to me I found him with abduction 1°, and adduction 21°, and with esophoria starting at 2°, and being followed up by correcting prisms running up to 16°, then diminishing again until it settled at 9°. At this time I suggested the need of a tenotomy, and at this time he deserted me for a colleague with larger experience and larger reputation for graduated tenotomy. Since his return to me he has had esophoria, abduction, and adduction about as when he first consulted me. My observations, therefore, do not indicate any special connection between muscular defects and progressive astigmatism.

It would be very interesting to know something of the frequency of such an increase in the degree of hyperopic astigmatism. But the seventeen cases here reported give no positive light on this subject. One cannot estimate what proportion of his patients would return to him should there be a recurrence of their asthenopia or other symptoms after a lapse of four years and a half, the average interval in the cases here reported. I have on my case books records of a larger number of patients who have come to me from careful, competent colleagues, with glasses that did not, when they came, correct the hyperopic astigmatism their eyes presented; and doubtless my colleagues have on their books cases that have gone to them from me, in a similar condition. Then there are probably many in whom a change of 0.5 D. in the astigmatism of one or both eyes has not led to any recurrence of the asthenopia or other annoyance, since many in the community suffer no inconvenience from that amount of astigmatism. Should I hazard a guess at the

frequency of these cases of progressive hyperopic astigmatism, it would be that they constitute about two per cent. of all cases seeking relief on account of anomalies of refraction. The cases in which, after the lapse of an equal length of time, the use of a mydriatic has shown no change in the amount of astigmatism, outnumber them very decidedly; and cases of mixed and myopic astigmatism are relatively, though not absolutely, more frequently progressive.

It is of interest to note that I have encountered no case of regressive astigmatism, — none in which the astigmatism had diminished so much as one-half dioptre; though it is not improbable that such cases occur.

It seems probable that the progression of astigmatism was determined, in some of these cases, by chronic, congestive, or inflammatory conditions allied to those of progressive myopia, but acting rather on the anterior segment of the eyeball, and determining a change in the shape of the cornea. But while the corneal change may be one of distension, the normal gradual increase of hyperopia, which Priestley Smith has shown to be due to the gradual increase in the size of the crystalline lens, would cause the change of refraction to be usually in the direction of increased hyperopia in all meridians, as was the case in most of these eyes.

In many of these cases there is a clear history of renewal of symptoms of congestion or chronic inflammation, coincident with the change in the amount of astigmatism, quite similar to what occurs in cases of progressive myopia. In six of the cases there was actual diminution of the hyperopia in one meridian, of one or both eyes. These facts point toward the congestive causation of the change. The condition might be set up as part of some general impairment of nutrition, though in none of the cases is there noted any clear history of general ill health; or it might arise from eye-strain, due to unusual exertion of the eyes, of which there was a clear history in several cases; or to the simple hyperopia, due to symmetrical increase of the lens, setting up the inflammatory changes that would lead to an alteration of the astigmatism. The other probable factor is a simple tendency to unsymmetrical increase of the lens' bulk,

causing a more rapid increase of hyperopia in certain meridians than in others.

The frequent binocular symmetry of the change would point to some developmental tendency possessed by the individual. Family tendency is indicated by the blood-relationship existing between several of these cases. Cases 1 and 6 are brothers, 2 and 7 are sisters, and 3 and 13 are first cousins. And in each pair of relatives the astigmatism was progressive at about the same period of life, and in about the same meridians.

From this series of cases we must conclude that the liability to change in the amount of astigmatism is not confined to any particular period of life, though such changes may be more frequent in early life.

A study of the cases here reported indicates that astigmatism is by no means constant in degree, though decided changes are exceptional. Changes in its amount and slight changes in the direction of its principal meridians must be looked for. These changes are not due to muscular faults, and are not confined to any one period of life. And when a patient comes with lenses prescribed some time previously by a colleague that do not now correct his ametropia, we must not jump at the conclusion that the lenses were inappropriate at the time they were ordered.

DISCUSSION.

DR. HENRY D. NOYES, of New York.— This matter would be better understood if observations were made more frequently by Javal's Ophthalmometer for astigmatism. It is not extraordinary that the cornea should undergo change. Conical cornea is only one of the exaggerated forms. It is not unusual for it to take on a *quasi*-regular astigmatism. Many cases of astigmatism make their appearance, which, when examined with the ophthalmometer, show that the axis of greatest and least refraction do not lie at right angles to each other; for example, one axis may point to 75°, while the other points to 180°. This difference of 12° to 25° may occur on either side of the vertical position, and vision will not be brought up to the normal by correcting glasses. In these cases, you may assume that the cornea is undergoing a slow change in curvature, and that at a future time a different reading for the astigmatism will be found.

The shape of the cornea may alter perceptibly under the pressure of the lid and the action of the ocular muscles in certain cases. This is the reason why examination for astigmatism by subjective methods is often so unhappy for both parties. The patient may have been squeezing his eyes trying to see. I have found that while at one trial under the ophthalmometer, I got a given amount of astigmatism, when the lid was lifted the astigmatism diminished. I have made this observation a number of times. I have even found that the attempt to steady the eye would give rise to slight variations. All these things point to the fact that the cornea is, to some degree, a variable structure, and that we must not be too certain that the astigmatism has changed.

I take this opportunity of stating that my experience with the ophthalmometer has strengthened my belief in its great value. Its help in the determination of astigmatism is such as no one could appreciate without its use.

DR. SAMUEL THEOBALD, of Baltimore, Md.—Several years ago I reported a number of cases of what I then regarded as progressive astigmatism. With more extended observation, I have become convinced that what may be termed manifest astigmatism and latent astigmatism exist in many eyes. I would not say that there is no such thing as true progressive astigmatism from alteration of the cornea, but I think that most of the cases in which the astigmatism apparently increases are not of this nature, but are simply cases of latent astigmatism made manifest by wearing glasses. The case is tested with every precaution, and a certain amount of astigmatism is made out. This is corrected by cylinders, and entire relief is given for some months, or perhaps for several years. The patient then returns with asthenopia again present, and, on repeating the tests, instead of finding, for example, 1.5 D. of astigmatism, as at the first examination, we find, perhaps, 2 D. or 2.5 D. The astigmatism was there, originally, but was rendered latent by the action of the ciliary muscle, and only became manifest as a result of wearing cylindrical glasses. I have spoken of it before, but I think it worth while again to call attention to the observation that it is especially in cases of astigmatism against the rule that latent astigmatism is apt to be encountered. In these cases, the ciliary muscle seems to have, to an unusual degree, the faculty of correcting the astigmatism by a symmetrical contraction.

DR. R. A. REEVE, Toronto, Can.—I have a maiden lady under my care whose accommodation was paralyzed by a specialist. She was told that she would not require stronger

glasses than ten inches for distance. She is now wearing six-inch glasses with a weak minus cylinder.

In regard to the effect of pressure of the lids on the cornea, why should we not exclude that by the instillation of a two or four per cent. solution of cocaine, which relieves the pressure of the orbicularis?

I can confirm what Dr. Noyes has said in regard to corneal astigmatism as shown by the ophthalmometer,—that the meridian of greatest and of least refraction are in many cases not at right angles to each other.

I can also confirm the statement that the degree of astigmatism may be modified by the pressure of the lids. We see it occur even while the images are being observed with the ophthalmometer. These two points are, I think, thoroughly established by every one who has made much use of the ophthalmometer, and they must be taken into account in any discussion of the results of reported cases where examinations have been made by any subjective method.

DR. O. F. WADSWORTH, of Boston, Mass.—I agree with Dr. Theobald as to the existence of latent astigmatism. Such cases do not, even with glasses, get quite normal vision; and while the action of the ciliary muscle may explain some of them, and perhaps, in part, all, I think that another explanation may be found in this, that the patient, being accustomed to imperfectly formed images, does not at first, from regularly formed images, recognize the object so well as he should. It is only after practice that he is able to estimate properly the correct form, and so the whole of the astigmatism becomes manifest only after wearing for a time partial correction.

DR. EDWARD JACKSON, of Philadelphia.—I think that there are other reasons why the idea of astigmatism remaining latent under full mydriasis is untenable, and here the history of several of these cases is against it. Cases in which the measurements were made, and glasses worn constantly for from two to four years, and then another measurement under full mydriasis made, without the slightest change in refraction. Then, perhaps in a few months, a clear history of eye-strain, and a decided change in the amount of astigmatism. This differs from latent hyperopia, which tends to become manifest, in part at least, soon after the manifest hyperopia had been corrected.

The change of the cornea by pressure I have seen with the ophthalmometer, and it is very marked in some cases; but it is an exceptional phenomenon. It is an exceptional cornea that shows any change under ordinary pressure.

AN ELEMENTARY DISCUSSION OF SOME CASES OF CENTRICAL REFRACTION THROUGH TIPPED SPECTACLE-LENSES.

BY JOHN GREEN, M.D.,
ST. LOUIS, MO.

The general case of a small pencil centrically refracted through a thin spherical lens is discussed in standard treatises on optics.* For the purposes of the present discussion it will be sufficient to consider in detail the particular case of a parallel pencil centrically refracted through a thin convexo-plane spherical lens.

The discussion of the case of a tipped spherical lens will be found to give direct solutions also of principal cases of tipped toric and cylindrical lenses.

I.

(1) LAW OF REFRACTION.—(*a*) When a ray of light is refracted in passing from a rarer into a denser, or from a denser into a rarer medium, the incident ray, the refracted ray, and the normal to the refracting surface at the point of incidence lie in the same plane; this plane we will call the *plane of refraction*.†

(*b*) The inclination of the ray to the normal is greater in the rarer than in the denser medium, and the sines of the angles of inclination in the two media are in a constant ratio the numerical value of which is determined by the particular media and the wave length of the light.

Let Q Q′ (Fig. 1) represent the direction of a ray incident on the surface of a denser medium at A at an angle, to the normal, Q A N = Q′ A N′; on entering the denser medium, the ray is refracted in the plane Q′ A N′ at an angle, to the normal, Q′ A N′ < Q′ A N′ = Q A N.

* A full discussion of the theory of spherical lenses is given in Parkinson's Optics (2d Ed., London and Cambridge, 1866).

† This very convenient designation of the plane of the incident and the refracted ray and the normal to the surface at the point of incidence is taken from Pickering and Williams (Proc. Am. Acad. of Arts and Sciences, Feb. 9, 1875). To Professors E. A. Engler and H. S. Pritchett, of Washington University, the writer is indebted for the kindly suggestions and criticism.

Conversely, if we take Q′ Q to represent the direction of a ray emerging at the surface of the denser medium at A at an angle, to the normal, Q′ A N′ = Q A N, we have the angle of refraction Q A N > Q A N = Q′ A N′.

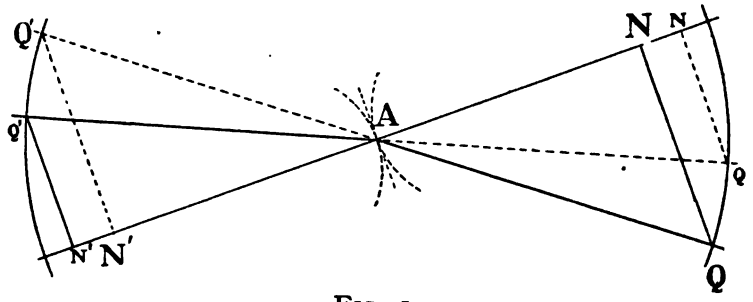

FIG. 1.

OBS.—Inasmuch as the direction of the normal N N′ is determined by the direction of the refracting surface at A, the point of incidence or of emergence of the ray, it is evident that so long as this direction remains unchanged, the refracting surface may be of any form whether plane or curved.

If about A as a centre we describe opposite arcs of a circle (whose radius we will, for convenience, consider unity) cutting Q Q′, Q Q′ and N N′, and draw Q N, Q′ N′, Q′ N′, and Q N perpendicular to N N′, we have —

$$\frac{QN}{Q'N'} = \frac{\sin QAN}{\sin Q'AN'}; \quad \frac{Q'N'}{QN} = \frac{\sin Q'AN'}{\sin QAN}.$$

Designating Q A N, the angle of inclination of the ray to the normal in the rarer medium, by ϕ, Q′ A N′, the angle of inclination of the ray to the normal in the denser medium, by ϕ', and the ratio $\frac{QN}{Q'N'} = \frac{\sin\phi}{\sin\phi'}$ by μ, we have—

$$\frac{\sin\phi}{\sin\phi'} = \mu; \quad \frac{\sin\phi'}{\sin\phi} = \frac{1}{\mu}; \quad \sin\phi = \mu\sin\phi'; \quad \sin\phi' = \frac{1}{\mu}\sin\phi.$$

The ratio $\frac{\sin\phi}{\sin\phi'} = \mu$ is called the *index of refraction.* In this communication, cases of refraction from air into glass and from glass into air will alone be considered, and the approximate value, $\mu = \frac{3}{2} = 1.5$ will be assumed for the refractive index.

When the incident or the emergent ray is normal to the refracting surface, we have —

$$\phi = 0 \therefore \sin\phi = 0;\ \sin\phi' = \frac{1}{\mu}\sin\phi = 0 \therefore \phi' = 0:$$

$$\phi' = 0 \therefore \sin\phi' = 0;\ \sin\phi = \mu\sin\phi' = 0 \therefore \phi = 0.$$

A ray normal to a refracting surface undergoes, therefore, no change of direction in passing from one medium into another medium of different density.

(2) REFRACTION AT A SPHERICAL SURFACE.— Every normal to a spherical surface is a diameter cutting every other normal at the centre; every plane of refraction, therefore, since it contains a normal, passes through the centre of the sphere.

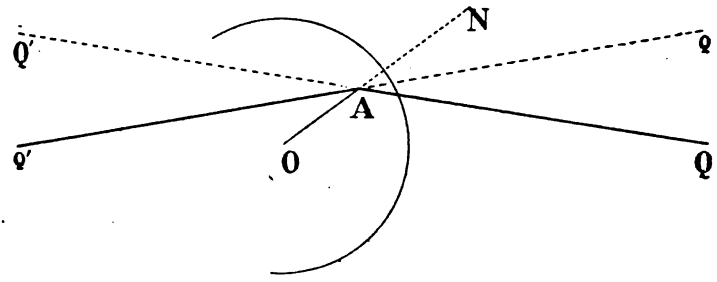

FIG. 2.

Let Q Q′ (Fig. 2) represent the direction of a ray incident on a convex spherical surface of a denser medium at A at an angle, to the normal, $Q\,A\,N = Q'\,A\,O = \phi$ and refracted in the plane Q′ A O at an angle, to the normal, $q'\,A\,O = \phi' < Q'\,A\,O = Q\,A\,N = \phi$. As N O is normal to the spherical surface it is a diameter of the sphere, and as Q A and A q′ lie in the same plane with N O, this plane of the incident and the refracted ray and the normal, passes through the centre of the sphere at O.

Conversely, we may take q′ q to represent the direction of a ray emerging at a convex spherical surface of a denser medium at A at an angle, to the normal, $q'\,A\,O = \phi'$, and refracted in the plane q A N at an angle, to the normal, $Q\,A\,N = \phi > q\,A\,N = \phi'$. As q′ A and A Q lie in the same plane with N O, the plane of refraction q′ A Q passes through O.

The proposition may similarly be shown to be true when the denser medium is bounded by a concave spherical surface.

A ray normal to a spherical refracting surface undergoes no change of direction on entering the second medium; it passes, therefore, through the centre of the sphere.

(3) Refraction of a Pencil of Rays at a Spherical Surface.—When a homocentric pencil of rays is refracted at a spherical surface, every plane of refraction passes through the centre of the sphere; every plane of refraction also passes through the vertex of the pencil; therefore every plane of refraction contains the line joining these two points, which line is a diameter of the sphere drawn through the vertex of the pencil, and every refracted ray cuts this axial line.

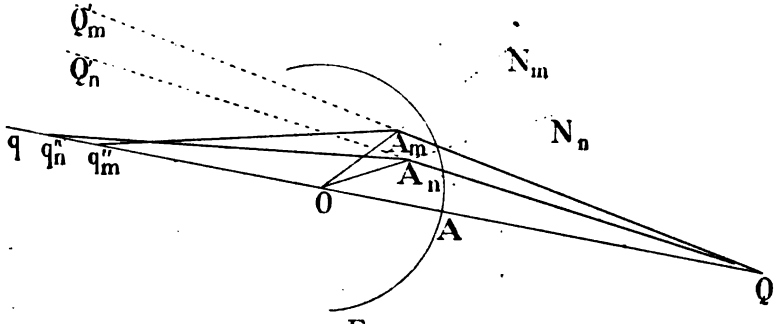

Fig. 3.

Let Q (Fig. 3) be the vertex of a (divergent) pencil, and let $Q\,A_m\,q''_m$ and $Q\,A_n\,q''_n$ represent two rays incident on a convex spherical surface of a denser medium at A_m and A_n and refracted toward the respective normals $A_m\,O$ and $A_n\,O$ in the planes $Q'_m\,A_m\,O$ and $Q'_n\,A_n\,O$. These planes pass through common points at the vertex of the pencil at Q, and at the centre of the sphere at O; their intersection is, therefore, a line drawn through Q and O, *i. e.*, a diameter of the sphere drawn through Q. The incident rays all cut this line at Q, and the refracted rays all cut the same line.

The proposition may similarly be shown to be true for the case of a convergent pencil emerging at a convex spherical surface of a denser medium, and, generally, for both divergent and convergent pencils refracted at a spherical surface.

If Q A be taken as a ray incident normally on the spherical refracting surface at A, consequently entering the second medium without change of direction to pass through O and q, this ray may be regarded as the axial ray of the pencil with reference to the spherical refracting surface $A\,A_m\,A_n$.

To extend the demonstration to the case of a (divergent or convergent) pencil refracted at a plane surface, we have only to make the radius of the sphere infinite, that is, to take O, the centre of the spherical surface, at an infinite distance in the direction A O; the line of intersection of the several planes of refraction is then a line drawn normal to the plane surface through the vertex of the pencil.

Special Case.— When the vertex of the pencil is taken at an infinite distance, the rays of the pencil become parallel, and the line of intersection of the several planes of refraction, which axial line is cut by every refracted ray, is a diameter of the sphere drawn toward of the vertex of the pencil, at infinity, which diameter is therefore parallel to the incident rays.

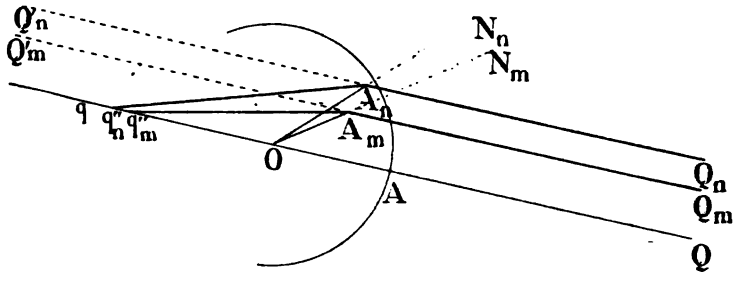

Fig. 4.

Let $Q_m\,A_m\,q''_m$ and $Q_n\,A_n\,q''_n$ (Fig. 4) represent two parallel rays incident on a convex spherical surface of a denser medium at A_m and A_n and refracted toward the respective normals $A_m\,O$ and $A_n\,O$ in the planes $Q'_m\,A_m\,O$ and $Q'_n\,A_n\,O$. These planes pass through a common point at the centre of the sphere at O; their line of intersection is, therefore, a line drawn through O toward of the vertex of Q_m and Q_n which is at infinity; this diameter is therefore parallel to the incident rays $Q_m\,A_m$ and $Q_n\,A_n$.

If Q A, parallel to $Q_m\,A_m$ and $Q_n\,A_n$, be taken as a ray

incident normally on the spherical refracting surface at A, consequently entering the second medium without change of direction to pass through O and q, this ray may be regarded as the axis of the parallel pencil with reference to the spherical surface $A\,A_m\,A_n$.

In the case of a convergent or divergent pencil whose vertex falls at the centre of a spherical refracting surface, or of a parallel pencil incident normally on a plane refracting surface, the incident rays are all normal to the surface and undergo no change of direction on entering the second medium.

(4) Focus of a Small Parallel Pencil Centrically Refracted at a Spherical Surface.—The refraction will be assumed to be from a rarer into a denser medium.

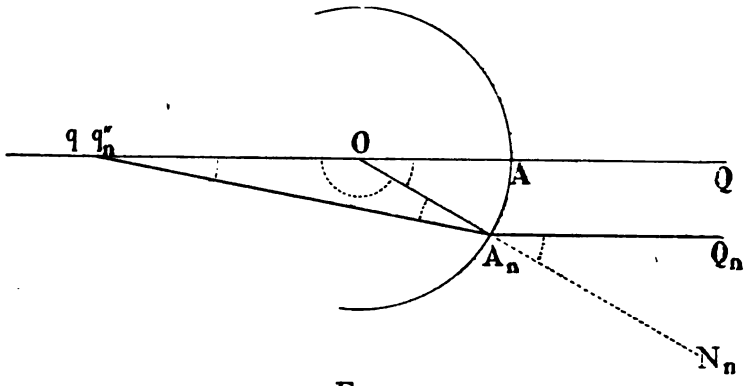

Fig. 5.

Let $A\,A_n$ (Fig. 5) represent an arc of a great circle of a sphere of glass, whose centre is at O. Let Q A represent a ray incident normally to the refracting surface, consequently entering the second medium without change of direction, and passing through O and q.

Let $Q_n\,A_n$ represent a second ray of the same parallel pencil, incident on the spherical refracting surface at an angle, to the normal, $Q_n\,A_n\,N_n = A\,O\,A_n = \phi$ and refracted at an angle, to the normal, $O\,A_n\,q''_n = \phi' < Q_n\,A_n\,N_n = A\,O\,A_n = \phi$; let q''_n be the point at which this excentrically refracted ray cuts the axial ray Q q to complete the triangle $O\,A_n\,q''_n$.

In this triangle we have

$A_n O q''_n = 180° - A O A_n = 180° - Q_n A_n N_n = 180° - \phi$,

$O A_n q''_n = \phi'$, and $A_n q''_n O = \phi - \phi'$.

Let $O A_n = O A = r$, $O q''_n = y$, and $A_n q''_n = v_2$.

Now $v_2 : y : r :: \sin\phi : \sin\phi' : \sin(\phi - \phi')$.

If we take A_n very near to A, so that Q A and $Q_n A_n$ shall represent the axial ray and another ray of a very small parallel pencil incident centrically on the spherical refracting surface, the angle ϕ being very small, we may, without sensible error, assume —

$\sin\phi = \phi = \mu\phi'$; $\sin\phi' = \phi'$; and $\sin(\phi - \phi') = \phi - \phi' = (\mu - 1)\phi'$.

Designating the limiting value of v_2 by v, we have

$$v : y : r :: \mu\phi' : \phi' : (\mu - 1)\phi' :: \mu : 1 : \mu - 1,$$

$$v = \frac{\mu r}{\mu - 1} = \mu \frac{1}{\mu - 1} r. \quad . \quad . \quad . \quad . \quad . \quad . \quad . \quad . \quad [1]$$

Taking q as the limiting position of q''_n we have, then, $A q = v = \mu \frac{1}{\mu - 1} r$ as the principal focal length of the spherical refracting surface $A A_n$; and q, a point $\mu \frac{1}{\mu - 1}$ radii from the centre of the face of the spherical surface, or $\frac{1}{\mu - 1}$ radii from the centre of the sphere, is the principal geometrical focus.

In the case of a small parallel pencil centrically refracted on a concave spherical surface of a denser medium, the principal geometrical focus lies in the rarer medium, and the principal focal length, being negative, is represented by $-\mu \frac{1}{\mu - 1} r$.

(5) FOCI OF A SMALL PARALLEL PENCIL EXCENTRICALLY REFRACTED AT A SPHERICAL SURFACE (of a denser medium).

(*a*) *Caustic of the Sphere.* — In the triangle $O A_n q''_n$ (Fig. 5) we have —

$$v_2 : y : r :: \sin\phi : \sin\phi' : \sin(\phi - \phi');$$

$$v_2 = \frac{\sin\phi}{\sin(\phi - \phi')} r; \; y = \frac{\sin\phi'}{\sin(\phi - \phi')} r.$$

If we take A_n at increasing distances from A on the arc $A A_n$ we have $A O A_n = Q_n A_n N_n = \phi$ increasing, and (since $\sin\phi' = \frac{1}{\mu}\sin\phi$, and $\sin\phi - \sin\phi' = [1 - \frac{1}{\mu}]\sin\phi$), we have $\sin\phi$,

$\sin\phi'$, and $\sin\phi - \sin\phi'$ all increasing at the same rate; but $\sin(\phi - \phi')$ increases at a greater rate than $\sin\phi - \sin\phi'$, consequently at a greater rate than $\sin\phi$ or $\sin\phi'$. We have, therefore, for every increase in the excentricity of the incident ray,

$$v_2 = \frac{\sin\phi}{\sin(\phi - \phi')} r \text{ and } y = \frac{\sin\phi'}{\sin(\phi - \phi')} r \text{ decreasing, and } q''_n$$

falling nearer to A and to O. If, now, we consider only such rays of the parallel incident pencil as are refracted in a meridional plane of the sphere, we have every refracted ray cutting every other refracted ray. The locus of all the points of intersection of consecutive refracted rays is a curve, having a cusp at q (the limiting position of q''_n), to which curve the refracted rays lying in its plane are all tangent. This curve, which is the envelope of all the refracted rays, is the principal diacaustic curve of the great circle $A A_n$.

If we consider only those rays of the parallel pencil which are incident on the spherical refracting surface under equal angles of incidence, the locus of all the points of incidence fulfilling this condition is a circle described on the surface of the sphere about A as a pole. All parallel rays incident on the spherical surface in such a circle are refracted symmetrically to the axis and form a conical shell, whose vertex is at q''_n; the greater the diameter of the base of the cone, the nearer does its vertex at q''_n lie to A and to O. The entire pencil may then be regarded as made up, after refraction at the spherical surface, of an infinite number of conical shells intersecting in an infinite number of consecutive circles, whose planes are perpendicular to the axis. The locus of all the circles of intersection of consecutive conical shells is the principal diacaustic surface of the sphere, which surface is the envelope of all the conical shells, and may be regarded as generated by revolving the diacaustic curve of the great circle about its axis; to this caustic surface all the refracted rays are tangent.

To construct the caustic curve as the envelope of the rays refracted in a meridional plane of the sphere, we have only to draw a sufficient number of parallel rays incident on the great circle $A A_n$, and refracted to cut the axial ray each at its own

point q''_n, whose distance from O and from A_n is computed from the values already found for y and for v_2, namely:

$$y=\frac{\sin\phi'}{\sin(\phi-\phi')}r=\frac{\sin\phi'}{\sin\phi\,.\,\cos\phi'-\cos\phi\,.\,\sin\phi'}r=\frac{1}{\mu\cos\phi'-\cos\phi}r;$$

$$v_2=\frac{\sin\phi}{\sin(\phi-\phi')}r=\frac{\sin\phi}{\sin\phi\,.\,\cos\phi'-\cos\phi\,.\,\sin\phi'}r=\mu\frac{1}{\mu\cos\phi'-\cos\phi}r\,.\,.\,[2]$$

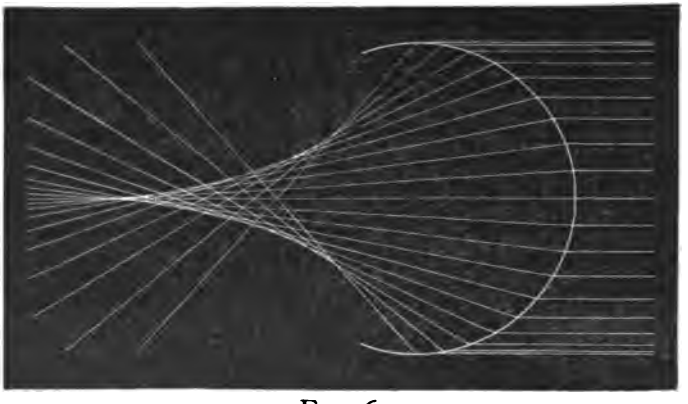

FIG. 6.

Fig. 6 shows the construction for the case of parallel incident rays, taking ϕ at increasing values with a common difference of 10° between the limits zero and 90°.

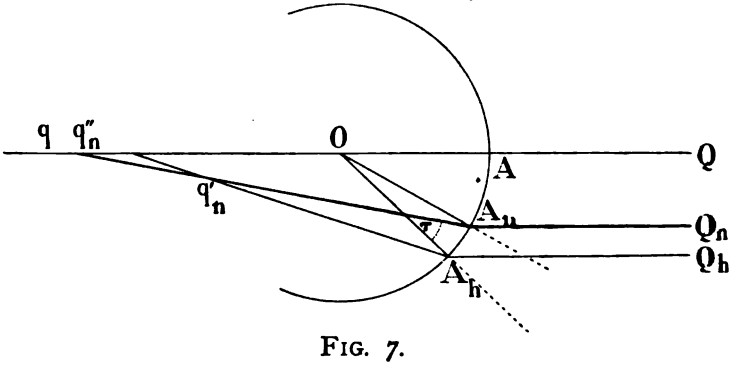

FIG. 7.

To construct the caustic curve by points, we have to find the point of intersection of each refracted ray with a consecutive refracted ray.*

* This demonstration is adapted from § 68, Chap. IV, of Parkinson's Optics (2d Ed., London and Cambridge, 1866).

Let $A\,O\,A_n$ (Fig. 7)$=\phi$, $A\,O\,A_h=\phi+\Delta\phi$,

$O\,A_n\,q''_n=\phi'$, $O\,A_h\,q'_n=\phi'+\Delta\phi'$,

$O\,A=O\,A_n=O\,A_h=r$, $A_n\,q''_n=v_2$, $A_n\,q_n'=v_1$, $A\,q=v$.

If, now, we take $A_n\,O\,A_h=A\,O\,A_h-A\,O\,A_n=\Delta\phi$ at decreasing values, we have—

$$A_n\,A_h\,q'_n \text{ approaching } A\,A_n\,q''_n=90^\circ+O\,A_n\,q''_n$$
$$=90^\circ+\phi'.$$

consequently,

$$\sin A_n\,A_h\,q'_n \text{ approaching } \cos O\,A_n\,q''_n=\cos\phi'.$$

In the limit,

$$\sin A_n\,A_h\,q'_n=\cos O\,A_n\,q''_n=\cos\phi'.$$

Now,

$$\sin A_n\,q'_n\,A_h : \text{chord } A_n\,A_h :: \sin A_n\,A_h\,q'_n : A_n\,q'_n$$
$$:: \sin A_n\,A_h\,q'_n : v_1.$$

In the limit,

$$A_n\,q'_n\,A_h : A_n\,A_h :: \sin A_n\,A_h\,q'_n : A_n\,q'_n :: \cos\phi' : v_1,$$
$$A_n\,q'_n\,A_h=\frac{A_n\,A_h\,.\cos\phi'}{v_1}.$$

Again,

$$\delta\phi=A\,O\,A_h-A\,O\,A_n=A_n\,O\,A_h=\frac{A_n\,A_h}{r};$$
$$\delta\,\phi'=O\,A_h\,q'_n-O\,A_n\,q''_n=\angle\tau-A_n\,q'_n\,A_h-(\angle\tau-$$
$$A_n\,O\,A_h)=A_n\,O\,A_h-A_n\,q'_n\,A_h=\frac{A_n\,A_h}{r}-\frac{A_n\,A_h\,.\cos\phi'}{v_1}.$$

Again,

$$\sin\phi=\mu\sin\phi',$$
$$\sin(\phi+\delta\phi)=\mu\sin(\phi'+\delta\phi'),$$
$$\sin\phi\,.\cos\delta\phi+\cos\phi\,.\sin\delta\phi=\mu\sin\phi'\,.\cos\delta\phi'$$
$$+\mu\cos\phi'\,.\sin\delta\phi'.$$

Dropping $\cos\delta\phi$ and $\cos\delta\phi'$ as factors (the cosine of the differential of an angle being equal to unity),

$$\sin\phi+\cos\phi\,.\sin\delta\phi=\mu\sin\phi'+\mu\cos\phi'\,.\sin\delta\phi'.$$

Subtracting $\sin\phi=\mu\sin\phi'$,

$$\cos\phi\,.\sin\delta\phi=\mu\cos\phi'\,.\sin\delta\phi'.$$

Substituting for $\sin\delta\phi$ and $\sin\delta\phi'$ the values found for $\delta\phi$ and $\delta\phi'$,

$$\cos\phi\frac{A_n\,A_h}{r}=\mu\cos\phi'\left(\frac{A_n\,A_h}{r}-\frac{A_n\,A_h\,.\cos\phi'}{v_1}\right);$$

Dividing both members of the equation by $A_n A_h$,

$$\cos\phi\frac{1}{r}=\mu\cos\phi'\left(\frac{1}{r}-\frac{\cos\phi'}{v_1}\right),$$

$$\frac{\cos\phi}{r}=\frac{\mu\cos\phi'}{r}-\frac{\mu\cos^2\phi'}{v_1},$$

$$\frac{\mu\cos^2\phi'}{v_1}=\frac{\mu\cos\phi'}{r}-\frac{\cos\phi}{r}=\frac{\mu\cos\phi'-\cos\phi}{r},$$

$$v_1=\mu\cos^2\phi'\frac{1}{\mu\cos\phi'-\cos\phi}r. \quad . \quad . \quad . \quad . \quad . \quad . \quad . \quad [3]$$

When A_n is taken very near to A, so that ϕ becomes a very small angle, we have, in the limit, $\phi=0$, and $\cos\phi$, $\cos\phi'$, and $\cos^2\phi'$ each equal to unity, and $v_1=\mu\frac{1}{\mu-1}r$; as this limiting value of v_1 is also limiting the value of v_2, we have, in the limit,

$$v_1=v_2=v=\mu\frac{1}{\mu-1}r;$$

which common value determines the position of the cusp of the caustic at the principal geometrical focus at q.

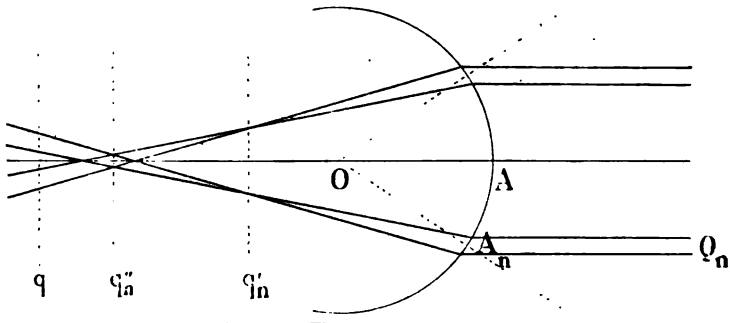

FIG. 8.

(*b*) *Secondary and Primary Focal Lines.* — Let A_n (Fig. 8) represent a meridional section of a narrow zone or annulus described on a spherical surface about A as a pole, and let $A_n q'_n q''_n$ similarly represent two conical shells of rays refracted on this annulus. Now the consecutive conical shells of rays refracted on the annulus intersect on the caustic in a series of consecutive circles near q'_n, and cut the common axis in a series of points near q''_n. The greatest condensation of rays is, therefore, in a thin ring near q'_n and in a small circular

spot near q''_n. If we consider only such rays as are refracted at A_n on a small section of the annulus, we shall have all the rays of this small excentrically refracted pencil passing through a small arc of the ring near q'_n and cutting the axis near q''_n. If, now, we intercept the pencil by a screen at q'_n, the image of a distant luminous point will appear as a small arc, which may be regarded as approximately a short straight line perpendicular to the plane of the paper; if we place the intercepting screen at q''_n, the image will be in the form of two opposite small sectors of the small luminous spot, but so much compressed that it may be regarded as approximately a short straight line in the plane of the paper. In the case of a small pencil excentrically refracted at a spherical surface, we have, then, no single focal point (toward which all the refracted rays converge or from which they diverge), but two focal lines, of which one, the secondary focal line, lies on the axis of the caustic, and the other, the primary focal line, lies on the caustic surface.

The smaller the angle ϕ the shorter are the two focal lines, and the nearer do they approach the limiting position q, at the cusp of the caustic; in the limit, the two focal lines, each reduced to a point, fall together at the geometrical focus at q.

In the case of a small parallel pencil excentrically refracted on a concave spherical surface of a denser medium, the caustic lies in the rarer medium, and the secondary and primary focal lengths are negative.

(6) Focus of a Small Parallel Pencil Directly and Centrically Refracted through a Thin Convexo-Plane Spherical Lens.

The focus of a small parallel pencil centrically refracted, from air into glass, at the first, convex spherical, surface of the lens is determined by the value,

$$[1] \quad \ldots\ldots\ldots \quad v=\mu\frac{1}{\mu-1}r.$$

It remains to determine the focus of the same (now convergent) small pencil after a second, direct, refraction, from glass into air, at the second, plane, surface of the lens.

Let Q q and $A_n q''_n$ (Fig. 9) represent the direction of the axial ray and another ray of a convergent pencil, and let a n represent a plane surface at which the pencil is directly refracted from a denser into a rarer medium. Let F''_n be the

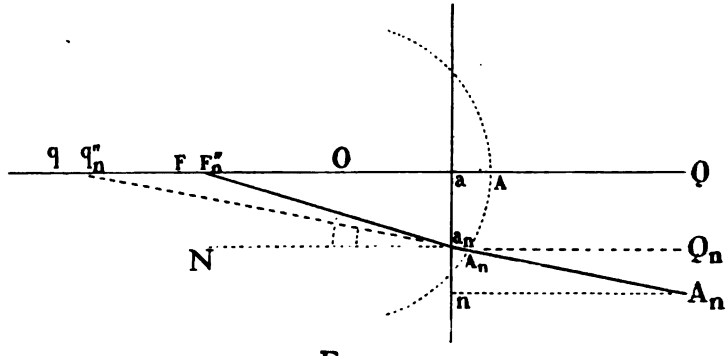

FIG. 9.

point at which the ray $A_n q''_n$, meeting the plane surface at an angle, to the normal, $q''_n a_n N = \phi'$, and refracted at an angle, to the normal, $F''_n a_n N = \phi > \phi'$, cuts the axial ray Q q. Take $a_n A_n = a_n F''_n$, and complete the right triangle $a_n n A_n$ by drawing $A_n n$ perpendicular to a n.

Now $a_n n A_n$ and $a_n a q''_n$ are similar triangles, therefore,

$$\frac{a_n A_n}{a_n q''_n} = \frac{a_n F''_n}{a_n q''_n} = \frac{a_n n}{a_n a} = \frac{\sin \phi'}{\sin \phi} = \frac{1}{\mu},$$

$$a_n F''_n = \frac{1}{\mu} a_n q''_n.$$

If we take ϕ' as a very small angle, consequently $\phi = \mu \phi'$, we have, taking a q and a F as the limiting values of $a_n q''_n$ and $a_n F''_n$, respectively,

$$a F = \frac{1}{\mu} a q.$$

If we take A q and $A_n q''_n$ to represent the axial ray and another ray of a very small parallel pencil after one, centrical, refraction at the first, convex spherical, surface of a convexo-plane lens, we may take a F and $a_n F''_n$ to represent the same two rays after a second, direct, refraction at the second, plane, surface of the lens. If we assume the lens to be very thin, we may, without sensible error, take a and a_n to represent not only the

points of emergence of the two rays at the second, plane, surface, but also their points of incidence on the first, convex spherical, surface; we have, then,

$$a\,q = A\,q = v = \mu \frac{1}{\mu - 1} r,$$

and, designating $a\,F = A\,F$ by f,

$$\therefore \quad f = \frac{1}{\mu} v = \frac{1}{\mu - 1} r. \quad . \quad . \quad . \quad . \quad . \quad . \quad . \quad . \quad [i]$$

As F is the limiting position of F''_n, we have, then, $a\,F = A\,F = f = \frac{1}{\mu - 1} r$ as the principal focal length of a thin convexo-plane lens for a small direct pencil; and F, a point $\frac{1}{\mu - 1}$ radii from the centre of the face (or of the back) of the thin lens, is the principal geometrical focus of the lens.

(7) Foci of a Small Parallel Pencil Obliquely and Centrically Refracted through a Thin Convexo-Plane Spherical Lens.

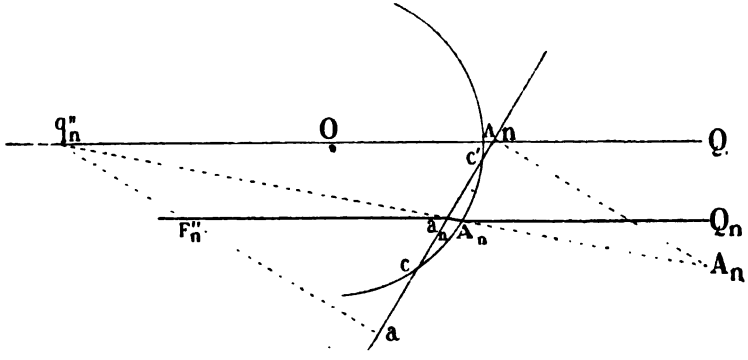

Fig. 10.

Let $Q_n A_n q''_n$ (Fig. 10) represent the path of a ray excentrically refracted on the great circle $A\,A_n$ to cut the axial ray $Q\,q''_n$, parallel to $Q_n\,A_n$, at q''_n. Let the chord c c′ represent a plane surface parallel to the direction of the spherical surface at A_n. Then $a_n\,F''_n$, parallel to $Q_n\,A_n$ and to Q q, will represent the direction of the ray after a second, oblique, refraction, from glass into air, at the plane surface c c′.

Draw $q''_n\,a$, perpendicular to $c\,c'$ produced, cutting $a_n\,F''_n$ at F''_n. Take $a_n\,A_n = a_n\,F''_n$, and draw $A_n\,n$ perpendicular to $c\,c'$. We have, then, $a_n\,A_n\,n = \phi'$, and $a_n\,F''_n\,a = \phi$. As $a_n\,n\,A_n$ and $a_n\,a\,q''_n$ are similar triangles, we have—

$$\frac{a_n\,A_n}{a_n\,q''_n} = \frac{a_n\,F''_n}{a_n\,q''_n} = \frac{a_n\,n}{a_n\,a} = \frac{\sin\phi'}{\sin\phi} = \frac{1}{\mu},$$

$$a_n\,F''_n = \frac{1}{\mu}\,a_n\,q''_n.$$

Assuming the lens to be very thin, we may, without sensible error, take $a_n\,q''_n = A_n\,q''_n = v_2$; similarly, taking $a_n\,F''_n = A_n\,F''_n = f_2$, we have,

$$[2] \quad . \quad . \quad . \quad v_2 = a_n\,q''_n = A_n\,q''_n = \mu\frac{1}{\mu\cos\phi' - \cos\phi}\,r;$$

$$f_2 = a_n F''_n = \frac{1}{\mu}A_n\,q''_n = \frac{1}{\mu\cos\phi' - \cos\phi}\,r; \quad . \quad . \quad . \quad [ii]$$

which value determines the place of the secondary focal line at F''_n.

To find the place of the primary focal line, we have to find the point of intersection of a consecutive ray of the twice-refracted pencil with the obliquely and centrically refracted ray $Q_n\,A_n\,a_n\,F''_n$.

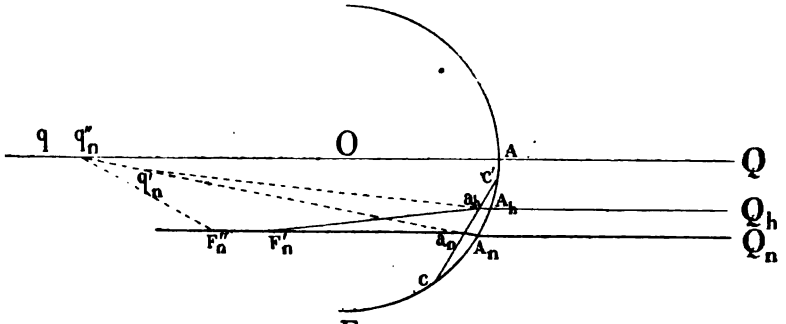

FIG. 11.

Let $Q_n\,A_n\,q''_n$ (Fig. 11) represent the path of a ray excentrically refracted on the great circle $A\,A_n$ to cut the axial ray $Q\,q$, parallel to $Q_n\,A_n$, at q''_n; and let $Q_n\,A_n\,a_n\,F''_n$ represent the path of the same ray refracted excentrically on the spherical surface at A_n, and obliquely at a_n at the plane surface $c\,c'$ parallel to the direction of the spherical surface at A_n. Similarly, let $Q_h\,A_h\,q'_n$

represent the path of a less excentric ray of the same parallel pencil cutting $A_n q''_n$ at q'_n, and let $Q_h A_h a_h F'_n$ represent the same ray twice refracted, at A_n and a_n, to cut $a_n F''_n$ at F'_n.

Neglecting the thickness of the thin lens, we have

$$a_n q''_n = A_n q''_n = v_2, \text{ and } a_n q'_n = A_n q'_n = v_1.$$

Similarly,

$$a_n F''_n = A_n F''_n = f_2; \text{ let } a_n F'_n = A_n F'_n = f_1.$$

Now $q''_n a_n c = 90° - \phi'$, and $F''_n a_n c = 90° - \phi$.

Let $a_n q'_n a_h = \Delta \phi'$, and let $a_n F'_n a_h = \Delta \phi$.

Taking $a_n q'_n a_h = \Delta \phi'$ at decreasing values, we have —

$q'_n a_h c$ approaching $q''_n a_n c = 90° - \phi'$, consequently

$\sin q'_n a_h c$ approaching $\cos q''_n a_n c = \cos \phi'$.

Similarly, we have —

$F'_n a_h c$ approaching $F''_n a_n c = 90° - \phi$, consequently

$\sin F'_n a_h c$ approaching $\sin F''_n a_n c = \cos \phi$.

Now,

$$\sin a_n q'_n a_h : a_n a_h :: \sin a_n a_h q'_n : a_n q'_n :: \sin a_n a_h q'_n : v_1,$$

$$\sin a_n F'_n a_h : a_n a_h :: \sin a_n a_h F'_n : a_n F'_n :: \sin a_n a_h F'_n : f_1.$$

In the limit,

$$\delta \phi' : a_n a_h :: \cos \phi' : v_1, \text{ and } \delta \phi : a_n a_h :: \cos \phi : f_1;$$

$$\delta \phi' = \frac{a_n a_h . \cos \phi'}{v_1}, \text{ and } \delta \phi = \frac{a_n a_h . \cos \phi}{f_1}.$$

Again,

$$\sin \phi = \mu \sin \phi',$$

$$\sin (\phi + \delta \phi) = \mu \sin (\phi' + \delta \phi'),$$

$$\sin \phi . \cos \delta \phi + \cos \phi . \sin \delta \phi = \mu \sin \phi' . \cos \delta \phi' + \mu \cos \phi' . \sin \delta \phi'.$$

Dropping cosines of differentials as factors,

$$\sin \phi + \cos \phi . \sin \delta \phi = \mu \sin \phi' + \mu \cos \phi' . \sin \delta \phi'.$$

Subtracting $\sin \phi = \mu \sin \phi'$,

$$\cos \phi . \sin \delta \phi = \mu \cos \phi' . \sin \delta \phi'.$$

Substituting for $\sin \delta \phi$ and $\sin \delta \phi'$ the values found for $\delta \phi$ and $\delta \phi'$,

$$\cos \phi \frac{a_n a_h . \cos \phi}{f_1} = \mu \cos \phi' \frac{a_n a_h . \cos \phi'}{v_1}.$$

Dividing both members of the equation by $a_n a_h$, and reducing,

$$\frac{\cos^2 \phi}{f_1} = \frac{\mu \cos^2 \phi'}{v_1},$$

$$f_1 : v_1 :: \cos^2 \phi : \mu \cos^2 \phi'.$$

Now we have found

$$[3] \quad . \quad . \quad . \quad . \quad v_1 = \mu \cos^2 \phi' \frac{1}{\mu \cos \phi' - \cos \phi} r,$$

$$\therefore f_1 = \cos^2 \phi \frac{1}{\mu \cos \phi' - \cos \phi} r; \quad . \quad . \quad . \quad . \quad [iii]$$

which value determines the place of the primary focal line at F'_n.

The values of f_2 and f_1 in terms of f are found from

$$[i] \ldots f = \frac{1}{\mu - 1} r, \therefore r = (\mu - 1) f;$$

$$[ii] \ldots f_2 = \frac{1}{\mu \cos \phi' - \cos \phi} r = (\mu - 1) \frac{1}{\mu \cos \phi' - \cos \phi} f; \ldots\ldots [II]$$

$$[iii] \ldots f_1 = \cos^2 \phi \frac{1}{\mu \cos \phi' - \cos \phi} r = (\mu - 1) \cos^2 \phi \frac{1}{\mu \cos \phi' - \cos \phi} f. \ldots [III]$$

The power of any lens is expressed by the reciprocal of its focal length; in the case of a thin convexo-plane spherical lens, we have, then,

$$[i] \ldots f = \frac{1}{\mu - 1} r, \therefore \frac{1}{f} = (\mu - 1) \frac{1}{r};$$

$$[ii] \ldots f_2 = \frac{1}{\mu \cos \phi' - \cos \phi} r = [II] \ldots (\mu - 1) \frac{1}{\mu \cos \phi' - \cos \phi} f,$$

$$\frac{1}{f_2} = \frac{1}{\mu - 1} (\mu \cos \phi' - \cos \phi) \frac{1}{f}; \quad . \quad . \quad . \quad . \quad . \quad . \quad . \quad . \quad . \quad [II]$$

$$[iii] \ldots f_1 = \cos^2 \phi \frac{1}{\mu \cos \phi' - \cos \phi} r = [III] \ldots . (\mu - 1) \cos_2 \phi$$

$$\frac{1}{\mu \cos \phi' - \cos \phi} f,$$

$$\frac{1}{f_1} = \frac{1}{\mu - 1} \cdot \frac{1}{\cos^2 \phi} (\mu \cos \phi' - \cos \phi) \frac{1}{f}. \quad . \quad . \quad . \quad . \quad . \quad . \quad . \quad [III]$$

If, now, we take ϕ at decreasing values, we have, in the limit, $\phi = 0$, and $\cos \phi$, $\cos \phi'$ and $\cos^2 \phi$ each equal to unity, consequently,

$$[II] \ldots . \frac{1}{f_2} = \frac{1}{\mu - 1} (\mu \cos \phi' - \cos \phi) \frac{1}{f} = \frac{1}{f};$$

$$[III] \ldots \frac{1}{f_1} = \frac{1}{\mu - 1} \cdot \frac{1}{\cos^2 \phi} (\mu \cos \phi' - \cos \phi) \frac{1}{f} = \frac{1}{f}.$$

If we take ϕ at increasing values, we have, as ϕ approaches 90°, $\cos\phi$ and $\cos^2\phi$ approaching zero, while, in the same limit, $\sin\phi = 1$, $\sin\phi' = \frac{1}{\mu}\sin\phi = \frac{1}{\mu}$, and $\cos\phi' = \sqrt{1 - \sin^2\phi'} = \sqrt{1 - \left(\frac{1}{\mu}\right)^2} = .745$; consequently,

$$[\text{II}] \ldots \frac{1}{f_2} = \frac{1}{\mu - 1}(\mu\cos\phi' - \cos\phi)\frac{1}{f} = \mu\frac{1}{\mu - 1}\cos\phi'\frac{1}{f} = 2.236\frac{1}{f}.$$

$$[\text{III}] \ldots \frac{1}{f_1} = \frac{1}{\mu - 1} \cdot \frac{1}{\cos^2\phi}(\mu\cos\phi' - \cos\phi)\frac{1}{f} = \infty.$$

If we take $\phi = 45°$, we have $\cos^2\phi = .5$, $\therefore \frac{1}{\cos^2\phi} = 2$; and, comparing [II] and [III], $\frac{1}{f_1} = 2\frac{1}{f_2}$.

Applying these solutions to the case of a tipped convexo-plane spherical lens, ϕ representing the angle of inclination, it appears (*a*) that the effect of the tipping is to increase the power of the lens in both the vertical and the horizontal meridian, (*b*) that the rate of increase is greater for the vertical than for the horizontal meridian, (*c*) that when the lens is tipped through an angle of 45° the power of the lens in the vertical meridian becomes equal to twice its power in the horizontal meridian, and (*d*) that when the lens is tipped through an entire quadrant its power is raised to infinity in the vertical meridian, and in the ratio $\mu\frac{1}{\mu - 1}\cos\phi' : 1 = 2.236 : 1$ in the horizontal meridian.

In the foregoing discussion the case of a convexo-plane spherical lens has alone been considered in detail, but the solutions are equally applicable, with change of sign, to the case of a concavo-plane lens, and, since the focal length of a thin lens remains practically the same whichever side of the lens is turned in the direction of the incident rays, they are true also, for plano-convex and plano-concave lenses. Furthermore, the power of any combination of thin lenses in contact is practically equal to the algebraic sum of the powers of the several lenses which enter into the combination; hence, it is permissible to regard every lens bounded by two spherical surfaces as

equivalent to a spherico-plane and a plano-spherical lens with their plane surfaces in contact. It follows, therefore, that solutions [II] and [III] are valid for all cases of centrical refraction of a parallel pencil through a thin spherical lens.

Similarly, we may regard every cylindric-spherical (or spherico-cylindrical) lens as made up a cylindric-plane and a plano-spherical lens with their plane surfaces in contact; inasmuch, however, as the discussion of the case of a cylindric-spherical lens is included in that of a toric-plane lens, it will be most convenient to study the two cases together.

II.

(8) FOCI OF A SMALL PARALLEL PENCIL CENTRICALLY REFRACTED THROUGH A THIN TORIC-PLANE* OR CYLINDRIC-PLANE LENS.—The case of direct centrical refraction, and the two principal cases of oblique centrical refraction in which the

* Toric refracting surfaces, made by a grinding tool of the form of a wheel with a rounded rim, have been produced, in decorative glass cutting, from the early days of the art; such toric surfaces are concave, and, when sunk in a plate of glass, afford typical examples of concavo-plane toric lenses. Toric surfaces have also been used, in individual cases, in the manufacture of spectacle glasses for the correction of astigmatism, as in the case of M. Cassas, historical painter, reported by Javal in the *Annales d' Oculistique* for March–April, 1866, for whom Suscipi, an optician of Rome, had, in 1840 or 1844, ground a pair of lenses in which a concave toric was combined with a convex spherical surface. Letters-patent, bearing date Sept. 15, 1885, were issued by the U. S. Patent Office to Anton Wagner, assignor to John L. Borsch, both of Philadelphia, for "a lens the surface of which has a greater degree of curvature in the direction of one axis than in the direction of the other axis." The specifications and accompanying drawings show that the surfaces claimed as the invention of Wagner are equatorial segments of tori, and they are described and figured as either convex in all meridians or concave in all meridians; the case of a surface cut from the lesser equator of the torus, which gives a curved surface convex in the meridional and concave in the equatorial plane, is not mentioned, and it seems altogether probable that the toric configuration of the two surfaces described was not recognized by the patentee. The production of these lenses, ground to any desired radius in each of the two principal meridians, by Mr. Borsch, and later by the optical firm of Borsch & Rommel, of Philadelphia, and the obvious utility of certain combinations of toric with spherical surfaces, making it practicable to correct cases of simple, of compound, and of mixed astigmatism by means of lenses of the meniscus form, have had the effect of removing toric lenses from the category of cases of curiosity to that of practical optical work. The figures obtained by the development of the lens-surfaces executed by Mr. Borsch were shown in an article, by the writer, in the AMERICAN JOURNAL OF OPHTHALMOLOGY for March, 1886, and have since been noticed in a work entitled "*Lunettes et Pince-nez*," by Dr. G. J. BULL, of Paris.

plane of refraction passes through the axis of the torus, or cylinder, and in which it cuts the axis at right-angles, will alone be considered.

DEF.— When a circle is revolved about a line in its own plane as an axis, a toric surface is generated. When the axis of revolution is a chord, other than a diameter, of the generating circle, two toric surfaces are generated, by the greater and lesser arcs, respectively (Fig. 12, *a*). When the axis is taken outside the generating circle, the toric surface has the form of a ring (Fig. 12, *b*). The plane of the circumference described by

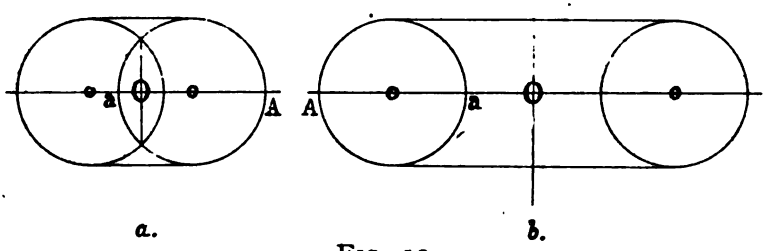

FIG. 12.

the centre of the generating circle cuts the toric surface *equatorially*. When the axis of revolution is taken outside the generating circle, this plane cuts the toric surface in two equatorial circles, a lesser and a greater, which have a common centre at the point in which the equatorial plane cuts the axis of revolution, which point is the centre of the torus. Every plane passing through the axis of revolution cuts the toric surface *meridionally*.

OBS.— The sphere, conceived as generated by the revolution of a circle about a diameter, and the right cylinder, generated by the revolution of a right line about another line parallel to itself, may be regarded as special cases of the torus. In the case of the sphere, any two planes passing perpendicularly to each other through the centre may be taken as an equatorial and a meridional plane, respectively ; in the case of the right cylinder, the position of the center on the axis is indeterminate, and any plane perpendicular to the axis may be taken as an equatorial plane.

If we designate O o, the radius of the circumference

described by the centre of the generating circle, by R, and o A, the radius of the generating circle, by r, we have R + r for the radius of the greater equatorial circle, and R — r for the radius of the lesser equatorial circle of the torus. When R = o, the torus becomes a sphere, and when R = ∞ or r = ∞, it becomes a cylinder. For convenience,

$$\text{let } r = r_m,\ R + r = r_E, \text{ and } R - r = r_e,$$

r_m, r_E and r_e representing radii of the toric surface for a meridional and for the greater and the lesser equatorial circles, respectively; similarly, let v_m, v_E, and v_e, and f_m, f_E, and f_e represent the several principal focal lengths of the torus and of the corresponding toric-plane lens for the same three cases. We have, then, for the case of—

(*a*) *Direct Centrical Refraction at a Toric Surface, and through a Thin Toric-Plane Lens,*

$$[1] \ldots\ldots v_E = \mu \frac{1}{\mu - 1} r_E, \text{ and } v_m = \mu \frac{1}{\mu - 1} r_m;$$

$$[i] \ldots\ldots f_E = \frac{1}{\mu - 1} r_E, \text{ and } f_m = \frac{1}{\mu - 1} r_m.$$

Taking $r = r_m = \infty$ *, the torus becoming a cylinder, we have

$$[1] \ldots\ldots v_E = \mu \frac{1}{\mu - 1} r_E, \text{ and } v_m = \infty;$$

$$[i] \ldots\ldots f_E = \frac{1}{\mu - 1} r_E, \text{ and } f_m = \infty.$$

When the point of incidence of the small direct parallel pencil is taken centrically on the lesser equatorial circle of the torus, r_e, consequently v_e and f_e, being negative, we have

$$[1] \ldots\ldots -v_e = -\mu \frac{1}{\mu - 1} r_e, \text{ and } v_m = \mu \frac{1}{\mu - 1} r_m;$$

$$[i] \ldots\ldots -f_e = -\frac{1}{\mu - 1} r_e, \text{ and } f_m = \frac{1}{\mu - 1} r_m;$$

the toric surface being, in this case, concave in the lesser equatorial and convex in the meridional plane.

* We may also take $R = \infty$, $R + r = \infty$ then becoming r_m, and r becoming r_E.

(*b*) *Oblique Centrical Refraction through a Thin Toric Lens, the Plane of Refraction passing through the Axis of the Torus.*

If we suppose a thin convexo-plane toric lens rotated about a line perpendicular to the axis of the torus and to the axis of the incident pencil, the case becoming that of oblique centrical refraction through the lens in a meridional plane of the torus, we have

$$[\text{II}] \ldots\ldots f\,\text{E}_2 = (\mu - 1)\frac{1}{\mu\cos\phi' - \cos\phi} f\,\text{E}, \text{ and}$$

$$[\text{II}] \ldots\ldots \frac{1}{f\,\text{E}_2} = \frac{1}{\mu - 1}(\mu\cos\phi' - \cos\phi)\frac{1}{f\,\text{E}};$$

$$[\text{III}] \ldots f\,\text{m}_1 = (\mu - 1)\cos^2\phi\,\frac{1}{\mu\cos\phi' - \cos\phi} f\,\text{m}, \text{ and}$$

$$[\text{III}] \ldots\ldots \frac{1}{f\,\text{m}_1} = \frac{1}{\mu - 1}\cdot\frac{1}{\cos^2\phi}(\mu\cos\phi' - \cos\phi)\frac{1}{f\,\text{m}}.$$

Taking $\text{r} = r\,\text{m} = \infty$ *, the case becoming that of oblique centrical refraction through a thin convexo-plane cylindrical lens in a meridional plane of the cylinder, we have

$$[\text{II}] \ldots\ldots f\,\text{E}_2 = (\mu - 1)\frac{1}{\mu\cos\phi' - \cos\phi} f\,\text{E}, \text{ and}$$

$$[\text{II}] \ldots\ldots \frac{1}{f\,\text{E}_2} = \frac{1}{\mu - 1}(\mu\cos\phi' - \cos\phi)\frac{1}{f\,\text{E}};$$

$$[\text{III}] \ldots f\,\text{m}_1 = \infty, \text{ and } [\text{III}] \ldots\ldots \frac{1}{f\,\text{m}_1} = 0.$$

When the point of incidence of the small oblique parallel pencil is taken centrically on the lesser equator of the toric surface, $r\,\text{e}$, consequently $f\,\text{e}$, being negative, we have

$$[\text{II}] \ldots\ldots -f\,\text{e}_2 = -(\mu - 1)\frac{1}{\mu\cos\phi' - \cos\phi} f\,\text{e}, \text{ and}$$

$$[\text{II}] \ldots\ldots -\frac{1}{f\,\text{e}_2} = -\frac{1}{\mu - 1}(\mu\cos\phi' - \cos\phi)\frac{1}{f\,\text{e}};$$

$$[\text{III}] \ldots\ldots f\,\text{m}_1 = (\mu - 1)\cos^2\phi\,\frac{1}{\mu\cos\phi' - \cos\phi} f\,\text{m}, \text{ and}$$

$$[\text{III}] \ldots \frac{1}{f\,\text{m}_1} = \frac{1}{\mu - 1}\cdot\frac{1}{\cos^2\phi}(\mu\cos\phi' - \cos\phi)\frac{1}{f\,\text{m}};$$

* Taking $\text{R} = \infty$, $\text{R} + \text{r} = \infty$ then becoming $r\,\text{m}$ and r becoming $r\,\text{E}$, the case is transformed into that of excentrical refraction at a cylindrical surface, or of oblique centrical refraction through a thin cylindrical lens, in an equatorial plane of the cylinder.

The toric lens being, in this case, concave in the lesser equatorial and convex in the meridional plane of the torus.

(*c*) *Oblique Centrical Refraction through a Thin Toric Lens, the Plane of Refraction cutting the Axis of the Torus at right-angles.*

If we suppose the thin convexo-plane toric lens rotated about a line parallel to the axis of the torus, the case becoming that of oblique centrical refraction through the lens in the equatorial plane of the torus, we have

$$[\text{II}] \ldots . f\mathrm{m}_2 = (\mu - 1)\frac{1}{\mu\cos\phi' - \cos\phi} f\mathrm{m}, \text{ and}$$

$$[\text{II}] \ldots . \frac{1}{f\mathrm{m}_2} = \frac{1}{\mu - 1}(\mu\cos\phi' - \cos\phi)\frac{1}{f\mathrm{m}};$$

$$[\text{III}] \ldots . f\mathrm{E}_1 = (\mu - 1)\cos^2\phi\,\frac{1}{\mu\cos\phi' - \cos\phi} f\mathrm{E}, \text{ and}$$

$$[\text{III}] \ldots \frac{1}{f\mathrm{E}_1} = \frac{1}{\mu - 1} \cdot \frac{1}{\cos^2\phi}(\mu\cos\phi' - \cos\phi)\frac{1}{f\mathrm{E}}.$$

Taking $\mathrm{r} = r\mathrm{m} = \infty$,* consequently $f\mathrm{m} = \infty$, the case becoming that of oblique centrical refraction through a thin convexo-plane cylindrical lens in an equatorial plane of the cylinder, we have

$$[\text{II}] \ldots . f\mathrm{m}_2 = \infty, \text{ and } [\text{II}] \ldots . \frac{1}{f\mathrm{m}_2} = 0;$$

$$[\text{III}] \ldots . f\mathrm{E}_1 = (\mu - 1)(\cos^2\phi)\frac{1}{\mu\cos\phi' - \cos\phi} f\mathrm{E}, \text{ and}$$

$$[\text{III}] \ldots \frac{1}{f\mathrm{E}_1} = \frac{1}{\mu - 1} \cdot \frac{1}{\cos^2\phi}(\mu\cos\phi' - \cos\phi)\frac{1}{f\mathrm{E}}.$$

When the point of incidence of the small parallel pencil is taken excentrically on the lesser equator of the toric surface, $r\mathrm{e}$, consequently $f\mathrm{e}$, being negative, we have

$$[\text{II}] \ldots . f\mathrm{m}_2 = (\mu - 1)\frac{1}{\mu\cos\phi' - \cos\phi} f\mathrm{m}, \text{ and}$$

$$[\text{II}] \ldots . \frac{1}{f\mathrm{m}_2} = \frac{1}{\mu - 1}(\mu\cos\phi' - \cos\phi)\frac{1}{f\mathrm{m}};$$

* Taking $\mathrm{R} = \infty$, $\mathrm{R} + \mathrm{r} = \infty$ then becoming $r\mathrm{m}$, and r becoming $r\mathrm{E}$, the case is transformed into that of oblique refraction at a cylindrical surface, or of oblique centrical refraction through a thin cylindrical lens, in a meridional plane of the cylinder.

[III]. . . . $-fe_1 = -(\mu - 1)\cos^2\phi \dfrac{1}{\mu\cos\phi' - \cos\phi} fe$, and

[III]. . . $-\dfrac{1}{fe_1} = -\dfrac{1}{\mu - 1} \cdot \dfrac{1}{\cos^2\phi}(\mu\cos\phi' - \cos\phi)\dfrac{1}{fe}$;

the toric lens being, in this case, convex in the meridional and concave in the lesser equatorial plane of the torus.

The geometrical construction for the case of a small parallel pencil obliquely and centrically refracted on a convex toric surface (or obliquely refracted on a convex cylindrical surface) of a denser medium, the plane of refraction passing through the axis of the torus (or cylinder) is shown in Fig. 13.

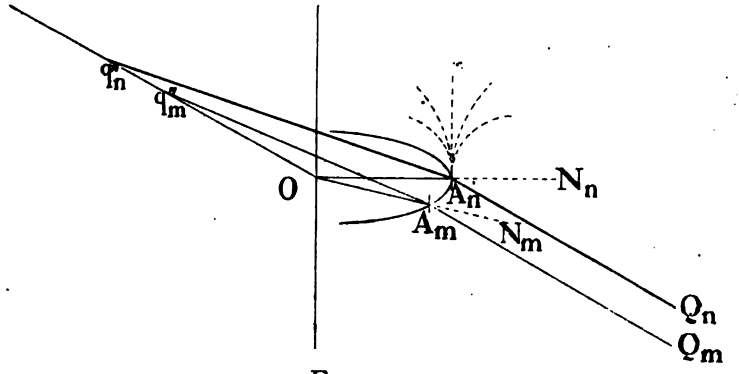

FIG. 13.

Let $Q_n A_n q''_n$ (Fig. 13) represent the axial ray of a parallel pencil incident at A_n on the equator of a torus at an angle, to the normal, $Q_n A_n N_n = \phi$ and refracted at an angle, to the normal, $O A_n q''_n = \phi'$, $\sin\phi'$ equaling $\frac{1}{\mu}\sin\phi$. Let $Q_m A_m q''_m$ represent another ray of the same parallel pencil incident on the equator of the torus at A_m and refracted to cut Oq, the line of intersection of the planes of refraction $Q_n A_n O$ and $Q_m A_m O$, parallel to $Q_n A_n$ and $Q_m A_m$ (*cf.* Fig 4). Taking A_m very near to A_n, we have $Q_m A_m N_m$ approaching $Q_n A_n N_n$, and q''_m approaching q''_n as a limiting position. Designating $O A_n$ by r_E and $A_n q''_n$ by v_{E_2} (*cf.* Fig. 5), we have

$A_n O q''_n = 180° - \phi$, $O A_n q''_n = \phi'$, $O q''_n A_n = \phi - \phi'$, and

[2] . . . . . $v_{E_2} = \dfrac{\sin\phi}{\sin(\phi - \phi')} r_E = \mu \dfrac{1}{\mu\cos\phi' - \cos\phi} r_E$,

which is the expression for the principal secondary focal length of the torus when the plane of refraction passes through the axis. It will be observed that the value of ϕ, which determines the values of v'_{E_2}, is determined by the direction of the toric surface at its equator; the construction holds good, therefore, also for a spherical surface, as has been already shown (*cf.* Fig. 4), and for a cylindrical surface; and, with a slight change in the drawing, for the case of oblique refraction in a meridional plane on the lesser equator of the torus.

The construction for the case of a small parallel pencil excentrically refracted on a convex toric surface (or on a convex cylindrical surface) of a denser medium, the plane of refraction cutting the axis of the torus at right-angles, is the same as that already shown in Fig. 7, in which we may take $A A_n$ as an arc of the greater equatorial circle of a torus (or of an equatorial circle of a cylinder), conseqently $O A_n = r_E$, and $A_n q'_n = v_{E_1}$; we have, then,

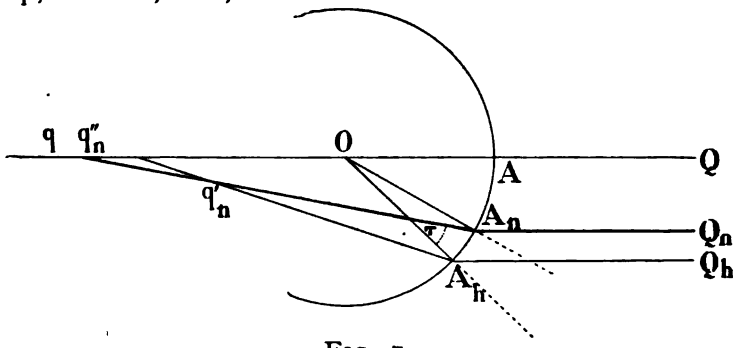

FIG. 7.

$$[3] \ldots\ldots v_{E_1} = \mu \cos^2 \phi' \frac{1}{\mu \cos \phi' - \cos \phi} r_E,$$

which is the expression for the principal primary focal length of the torus (or cylinder) when the plane of refraction cuts the axis at right angles.

To adapt this construction to the case of a small parallel pencil excentrically refracted on the lesser equatorial circle of the torus (or on a concave cylindrical surface of a denser medium), the plane of refraction cutting the axis at right-angles, we have only to take O, consequently q, q''_n and q'_n to the right of A;

the caustic curve will then lie in the rarer medium, and, designating O A_n by $-re$ and $A_n q'_n$ by $-v e_1$, we have—

$$[3] \quad -v e_1 = -\mu \cos^2 \phi' \frac{1}{\mu \cos \phi' - \cos \phi} re.$$

Applying the solutions which have been obtained to principal cases of tipped toric lenses, ϕ representing the angle through which the lens is tipped, it follows that, in all cases in which the axis of the toric surface lies in either the vertical or the horizontal plane, solutions [II] and [III] hold good as well for toric as for spherical lenses, observing always that the symbol for the principal focal length of the lens in the horizontal meridian (f E, $-f$e or fm, as the case may be) enters, as the controlling factor, into the formula for the secondary focal length of the tipped lens, and that the symbol for the principal focal length of the lens in the vertical meridian enters, as the controlling factor, into the formula for the primary focal length of the tipped lens.

Inasmuch as the power of any spherico-cylindrical lens in its two principal meridians is the algebraic sum of the powers of the combined spherico-plane and plano-cylindrical lenses of which we may regard the spherico-cylindrical lens as made up, in these two meridians respectfully, it follows that solutions [II] and [III] hold good also for all cases of tipped spherico-cylindrical lenses in which the principal meridians of the untipped lens are vertical and horizontal.

In the special case of a plano-cylindrical lens (or of any equivalent lens, whether with two cylindrical surfaces or with a concave or convex toric combined with a convex or concave spherical surface), the power of the lens ($\frac{1}{f\text{m}} = 0$) in its meridian of no refraction remains unchanged when the lens is tipped; the power of the lens in its principal meridian of greatest refraction varies with the degree of inclination, and is determined by formula [II] or formula [III], according as this meridian happens to be horizontal or vertical in the untipped lens.

The change effected in the power of any lens by tipping may be summed up as follows:

Every spherical lens is increased in power in all its meridians; the rate of increase and the actual increase being greatest in the vertical [III], and least in the horizontal meridian [II]. A spherical lens is, therefore, also rendered astigmatic, and the excess of increase in power in the vertical meridian over that in the horizontal meridian, for any given inclination, is the measure of the astigmation.

Every convex or concave toric or spherico-cylindrical lens is increased in power in all its meridians. When the two principal meridians of the lens lie in the vertical and in the horizontal plane, respectively, the rate of increase in power is greatest in the vertical [III] and least in the horizontal meridian [II]; and when the power of the untipped lens is greatest in the vertical meridian, the actual increase is also greatest in the vertical meridian, and the astigmatism of the lens is increased. When, on the other hand, the power of the untipped lens is greatest in the horizontal meridian, the astigmatism of the lens is at first diminished, and since the possible increase in power in the horizontal meridian [II] is limited, while the possible increase in power in the vertical meridian [III] is unlimited, there is always some value of ϕ (the angle of inclination) at which the astigmatism of the lens is reduced to zero, and beyond which the direction of the meridians of greatest and least refraction is reversed.

In the case of a tipped plano-cylindrical (or other equivalent) lens, the greatest increase in power is in the meridian at right-angles to the axis of the lens, the power of the lens in the meridian of the axis remaining at zero. The rate of increase, and also the actual increase in power, is greatest [III] when the axis of the untipped lens is horizontal, and is least [II] when the axis of the untipped lens is vertical.

If we adopt the metric notation, taking the case of any lens whose principal meridians (of greatest and least refraction) are assumed to be vertical and horizontal, we may represent the power of the untipped lens in the horizontal meridian by Dh and in the vertical meridian by Dv, and, similarly, the power of the tipped lens in the same meridians by Dh_2 and Dv_1, respectively; assuming the approximate value $\mu=\frac{3}{2}=1.5$, we have, then,

[II] . . . . $Dh_2 = (3 \cos \phi' - 2 \cos \phi)\ Dh$;

[III] . . . $Dv_1 = \frac{1}{\cos^2 \phi} (3 \cos \phi' - 2 \cos \phi)\ Dv$.

If we take $Dh = Dv = D$, we have, for the special case of a tipped spherical lens,

[II] . . . . $D_2 = (3 \cos \phi' - 2 \cos \phi)\ D$;

[III] . . . $D_1 = \frac{1}{\cos^2 \phi} (3 \cos \phi' - 2 \cos \phi)\ D$;

$$D_1 = \frac{1}{\cos^2 \phi} D_2.$$

If we take $Dh = 0$, we have, for the special case of a tipped plano-cylindrical (or other equivalent) lens with its axis horizontal,

[II] . . . . $Dh_2 = 0$;

[III] . . . $Dv_1 = \frac{1}{\cos^2 \phi} (3 \cos \phi' - 2 \cos \phi)\ Dv$.

If we take $Dv = 0$, we have, for the special case of a tipped plano-cylindrical (or other equivalent) lens with its axis vertical,

[II] . . . . $Dh_2 = (3 \cos \phi' - 2 \cos \phi)\ Dh$; [III] . . . . $Dv_1 = 0$.

The following table gives the computed values of D_1, D_2, and $D_1 - D_2$, in terms of D, for differences of 5° in the value of ϕ between the limits zero and 45°.

$\phi =$	$\frac{D_1}{D} = \frac{Dv_1}{Dv} = \frac{1}{\cos^2 \phi}(3 \cos \phi' - 2 \cos \phi)$.	$\frac{D_2}{D} = \frac{Dh_2}{Dh} = 3 \cos \phi' - 2 \cos \phi$.	$\frac{D_1}{D} - \frac{D_2}{D} = \left(\frac{1}{\cos^2 \phi} - 1\right) 3 \cos \phi' - 2 \cos \phi$.
zero.	1.	1.	0.
5°	1.010	1.002	0.008
10°	1 042	1.010	0 032
15°	1.097	1.023	0.074
20°	1.179	1.041	0.138
25°	1.297	1.066	0.231
30°	1.462	1.096	0.366
35°	1.689	1.134	0 555
40°	2.008	1.178	0.830
45°	2.464	1.232	1.232
.....	.....	.....	.....
90°	infinity.	2.236	infinity.

CYST OF THE IRIS, FOLLOWING A PENETRATING WOUND, WHICH HAD CAUSED SYMPATHETIC NEURO-RETINITIS.

BY S. D. RISLEY, M.D., AND B. A. RANDALL, M.D.,
PHILADELPHIA, PA.

The following clinical history of a single case of this always interesting disease presents so many and varied points of interest, that it is deemed of sufficient importance to be placed upon record in the annals of the society.

John D., aet. 12 years, on December 26, 1882, received an injury to the left eye-ball, inflicted by the steel point of an arrow, projected from a toy gun, the propelling force being a strong rubber band. The projectile punctured or ruptured the ball at the corneo-scleral junction in its lower and inner quadrant. The boy was seen within an hour after the injury. The anterior chamber was filled with blood, and a nearly vertical wound 4 mm. in length was found, the upper part lying in the transparent corneal tissue, the lower extending into the ciliary region. A large mass of iris was entangled in the wound, and possibly also a part of the ciliary body. Ether was administered, and an effort made to replace the protruding mass. Failing in this, the hernia was excised, the wound freed from the stump and pigment by a horn spatula, the eye thoroughly cleansed, and the pressure bandage applied after instillation of a solution of atropia. Marked reaction followed, but was controlled by the usual methods, and the wound finally closed with a cystoid scar. The blood clot rapidly disappeared from the anterior chamber, and the posterior capsule of the lens was then found to be gray and strongly reflecting, and no reflex from the fundus could be obtained. The bandage was continued until January 22d, when the cystoid scar had given place to a white and flat cicatrix, and a gray-red reflex was visible from the fundus. The eye was red and irritable, and exhibited some dread of light. There was no increase of the capsular opacity. On January 27th, one month after the accident, the uninjured

right eye showed slight photophobia, with conjunctival and ciliary injection. T. *n.*, p. p. 13 ctm. and V. = $\frac{6}{vi}$. The media were transparent, but the optic nerve was flushed. The symptoms increased until February 3d, when vision had sunk to = $\frac{6}{ix}$. The media remained transparent, but the nerve was veiled, and its surface quite as red as the surrounding eye-ground. One week later it was noted that "nerve margins are obscured by the swollen and hazy retina, veins are full, dark, and tortuous, — no hemorrhages. The media are transparent, and iris dilates *ad maximum.* The injured eye is soft, otherwise no notable change. Marked photophobia." February 19th, "O. D: V. = $\frac{6}{xii}$. Changes in eye ground have steadily progressed, showing small yellowish-white splotches throughout, but a careful study reveals no spots on the cornea or vitreous opacity." On March 2d, "O. D., only a foggy view of the eye-ground can be obtained, and careful study now shows numerous small spots on the membrane of Descemet, and a web-like opacity in the vitreous, V. = $\frac{6}{xxx}$." Potass. iodide had been steadily administered from the first manifestation of the neuro-retinitis, but this was now replaced by mercurial inunctions; atropia was used locally, and smoked glasses worn in the light. The acuity of vision became steadily less until only the large letters of the test card could be indistinctly seen at a few feet. In ten days the symptoms began slowly to subside. The photophobia grew less, the ciliary injection subsided, and the media gradually cleared up, until, on May 4th, it was noted "O. D. + .50 *c* ax. 90° V. = $\frac{6}{vi}$ — p. p. 13 ctm., media transparent, nerve margins ragged, splotches and retinal infiltration have disappeared, and circulation normal. O. S. counts fingers, ball soft, white." On June 1st, his mother related, that "on May 29th the boy suddenly became blind, and fell from his chair in an epileptoid convulsion, remaining unconscious for about ten minutes. This was followed by nausea, vomiting, and violent headache, which still persists, but is much less severe." He had been "*dull*" for several days before the attack. He was seen by the family physician, who directed a return to the mercurial inunctions in addition to temporary

means for immediate relief. He remained "out of sorts" for several days, but the convulsion was not repeated.

In September, the boy returned to school, and was not seen again until July, 1884, — one and one-half years after the injury,— when he came suffering from asthenopia, which was relieved by a correcting glass, V. = $\frac{6}{6}$. No notable change was found in either eye. The following November, 1884, he had a second convulsion, similar, in all respects, to that of May, 1883, which was followed by the violent headache which persisted for many days, but subsided under iodide and bromide of potassium, O. D. V. $\frac{6}{6}$ O. S. q. p. l. The lad was seen at intervals through the ensuing years, for occasional attacks of ciliary injection and photophobia, which soon subsided under rest from school and a mydriatic, until March, 1888, when he passed from observation until March, 1890. Then he once more appeared with marked sympathetic irritation, O. D. V. $\frac{6}{6}$? n. flushed, ciliary injection. O. S., increased lachrymation, ciliary injection, and a large semi-transparent cyst in the lower part of the anterior chamber near the site of the coloboma in the iris, but extending over the pupil at its lower margin, and lying in contact with the cornea. Its appearance is well delineated by the accompanying sketch made by Dr. Randall. In the early history of the case, at the first appearance of trouble with the uninjured eye, enucleation had been urged, but strenuously refused by the parents of the child. This advice was again given, as the cyst was seen to be growing rapidly, and there was room for suspicion of sarcoma, but refused until further responsibility in the case was declined, unless the advice was accepted. The offending eye was then removed, and the operation was followed by a rapid subsidence of the symptoms.

The eye was hardened in Müller's fluid followed by alcohol, stained entire in carmine, imbedded by the chloroform-paraffine method, and the complete sections mounted in balsam. No sarcoma was found. The cyst proved exceedingly delicate, and practically void of all contents, its walls constituted by the altered anterior and posterior layers of the iris, the former showing traces of iris stroma as well as the usual structureless wall, lined with pavement endothelium. The angle of the anterior

chamber was decidedly widened and rounded, the cyst walls being closely in contact with the tissues in the lower third. There were strong adhesions to the lens capsule; but anteriorly such connection was doubtful, although seemingly present at one or two points. The cornea, ciliary body above and below, and the upper part of the iris, revealed little abnormality. The nerve entrance showed a deep porus, with rather prominent margins, but little abnormality; the retina was poorly preserved. The lens, although successfully cut, proved so brittle as to make satisfactory study of its cataractous condition impossible. The cyst, in this instance, following a penetrating wound as in almost all of the reported cases, was of the serous form, and had developed within the tissues of the iris, distending the anterior chamber at its site, as shown by the sketch of one of the sections.

In the above history, it is to be noted, that following the injury there was developed in the uninjured eye during the course of three months a pronounced attack of neuro-retinitis, followed by choroiditis, which spread forward, culminating in serous iritis with deposits on the membrane of Descemet. This progressed in severity until vision sank to little more than the ability to count fingers at two feet. Under mercurial inunctions this rapidly subsided, the eye once more recovering a normal acuity of vision. The attacks of convulsions followed by persistent headache seem to suggest basilar meningeal involvement. The intervening long series of years, during which the eyes manifested repeated evidences of the so-called sympathetic irritation, attended by headache, and finally the urgent necessity for enucleation of the injured eye; the occurrence of the large, non-malignant cyst of the iris; and, lastly, the complete relief afforded by the removal of the injured eye—furnish an unusual history, and one, withal, replete with varied interest in the study of the pathogeny of sympathetic disease.

DISCUSSION.

DR. HENRY D. NOYES, of New York. — Was the first attack one of neuro-retinitis which disappeared? Did enucleation stop the appearance of the second relapse?

DR. RANDALL. — Yes, sir.

DR. LUCIEN HOWE, of Buffalo, N. Y. — I would mention in this connection a case of apparent cyst which was difficult of diagnosis. It was covered with pigment. Otherwise, it had every appearance of a cyst. The condition lasted about two and one-half years; and, to my surprise, it gradually disappeared.

EIGHT CASES OF RUDIMENTARY ZONULAR DOUBLE CATARACT AMONG TEN MEMBERS OF THE SAME FAMILY.

BY DR. HASKET DERBY,

BOSTON, MASS.

The theory that hereditary lenticular opacity is more apt to be marked in the case of females than in that of males is well illustrated in the remarkable group of cases to which I desire to call your notice.

Mr. F. W., Mr. C. W., and Mrs. A. are children of the same parents. They have all arrived at middle-age, the eldest being now 49. The parents are both dead, but were always supposed to have natural vision. Neither of these parties have ever had their attention called to their sight, except F. W., who wears convex cylindrical glasses for the near.

Each one has, in either eye, a rudimentary zonular cataract, circular in shape, with a large clear centre, the appearances in the case of the sister being the most marked. The opacity, with her, seems back of the centre of the lens, is linear and oval in shape, the larger end of the oval being directed upwards. The fundus is clearly visible and normal. With a convex cylinder, 1 D. in the right eye, 1.5 D. in the left eye, she has normal vision.

Either brother has a smaller, linear ring of opacity in the center of each lens. The older, aged 49, is emmetropic; the younger, aged 48, has, like his sister, hypermetropic astigmatism, wearing right 1.5 D. cyl., left 2 D. cyl. Each has normal vision.

We come now to the succeeding generation. The sister has

four children, the elder brother one, and the younger, three. Of the eight children, six are similarly affected.

Of the sister's children, all have the opacity.

(1.) E., female, aged 20. The zonular ring is circular, with the usual clear centre. Right eye Ah. 1.75, V. nearly 0.9. Left eye Ah. 1.5, V. nearly 0.9.

(2.) S., male, aged 19. Each eye emmetropic, V. 1. The opacity in the right lens is triangular, much resembling in shape the Irish harp on a British gold coin. In the left it is circular, and a single bar of opacity juts out on one side, towards the periphery of the lens.

(3.) M., female, aged 12. This child and her sister, the succeeding case, are twins. Opacity in each eye triangular in shape, as in the brother's right eye. Slight irregular Ah. Vision, right 0.9; left less than 0.7.

(4.) D., female, aged 12. The zonular cataract is here diamond shaped, with the usual central aperture; the edges being denser and the aperture notably smaller in the left eye, where the affection is much more marked in its development than in any other one of these cases. No astigmatism can be made out. Vision in right eye not quite 0.8, in left 0.3.

The younger brother has three children.

(1.) G., male, aged 18. The shape of the opacity is circular in one eye, like a diamond in the other. It is relatively faint, in fact, can only be made out by using a weak mirror. Emmetropia and normal vision in each eye.

(2.) E., male, aged 15. Eyes normal in every respect.

(3) E., female, aged 12. Marked opacity, circular in each eye. Vision and refraction normal.

The elder brother has one child.

Mrs. G., aged 18. Each lens perfectly clear. Slight My. in one eye. Slight Am. in the other. Vision substantially normal.

We see from this series of cases, first: that such faults of development are more apt to be transmitted through the female than the male; and second, are transmitted more perfectly to females than to males; the only exception being the daughter of the elder brother. It is also interesting to note that two of the three principals have hypermetropic astigmatism.

DISCUSSION.

DR. HENRY D. NOYES, of New York. — Can Dr. Derby state whether convulsions occurred in any of these individuals at any period. It was the theory of Arlt that this form of cataract occurred as a result of intra-uterine convulsions, of which corroborative evidence could be found after birth. He collected a number of cases of that character in which the convulsions were either intra-uterine, or occurred during the first year of extra-uterine life. A recent paper in Graefe's Archives has combatted that theory as not sustained by any reasonable mechanical explanation.

THE PRESIDENT. — The presumption is that there was nothing of that kind. I inquired carefully into the histories, and no account of convulsions is noted.

NOTES ON TWENTY-ONE CASES OF CATARACT, OCCURRING IN A SINGLE FAMILY.

BY DR. JOHN GREEN,

ST. LOUIS, MO.

In October, 1888, I was consulted by Mrs. Anna R., 83 years of age, who had noticed beginning failure of vision in the left eye about seven years before, and in the right eye about two years before. I found senile cataract, mature in the left eye, immature in the right eye. She told me that a grandmother (mother's mother), an aunt (mother's sister), three cousins (daughters of the latter), and a brother had been blind from cataract, and that she had children, grandchildren, and great-grandchildren, also with cataract. By carefully questioning Mrs. R. and two of her daughters, who were under my care at the same time, I learned that of 53 descendants of Mrs. R., 14 (26.4 per cent.), of 65 known descendants of Mrs. R.'s mother 16 (24.6 per cent.), and of 70 known descendants of Mrs. R.'s grandmother, 20 (28.6 per cent.) had been the subjects of cataract; or, counting the grandmother, that of 71 persons, belonging to six successive generations, 21 (29.6 per cent.) were known to have had cataract.

The following table shows the several lines of descent of 70 known descendants of No. 1* (grandmother of No. 12*—Mrs. Anna R.). Males are designated by **heavy-faced** type, cases of cataract by an asterisk (*).

- 1*
  - 2*
    - 4*
    - 5*
    - 6*
  - 3
    - 7*
    - 8
    - 9
    - 10
    - 11
    - 12*
      - **19** [28–34. sex unknown.]
      - 20*
        - 35*
          - **65***, 66.
        - **36***
          - 67, 68, **69**.
        - 37*
          - **70***
      - **21**
        - 38, 39, **40**, **41**.
      - **22**
        - 42*, 43, 44, 45.
      - **23***
        - 46–49, **50–53**.
      - **24***
        - 54*, **55**.
      - 25*
      - **26***
        - 56*–59, **60–63**.
      - 27
        - **64**.
    - 13
    - 14
    - 15
    - 16
    - 17
    - 18
      - 71*.

NOTE.—The parentage of No. 71* is (through an omission in the record) at present unknown to me. She is, however, the daughter of one of the granddaughters of No. 12*; her mother is said to have perfect sight.

By inspection of the table, it will be seen that, of 71 persons (excluding the seven children of No. **19**, whose sex is not stated), the males number 27 (42.2 per cent.), the females 37 (57.8 per cent.).

Of 21 cases of cataract, the males number 6 (28.6 per cent.), the females 15 (71.4 per cent.).

Of 20 cases of cataract, descendants of No. 1,* the inheritance has been through the father in 4 (20 per cent.), and through the mother in 16 (80 per cent.).

Of 54 persons (Mrs. Anna R.—No. 12*—and her descendants), excluding the seven children of No. **19**, the males number 22 (46.8 per cent.), the females 25 (53.2 per cent.).

Of 15 cases of cataract (No. 12* and her descendants), the males number 6 (40 per cent.), the females 9 (60 per cent.).

Of 15 cases of cataract (No. 12* and her descendants), the inheritance has been through the father in 4 (26.6 per cent.), and through the mother in 11 (73.3 per cent.).

Nine mothers (1st to 5th generations) have had 35 children, of whom 17 (48.6 per cent.) have had cataract.

Six mothers, with cataract, have had 21 children, of whom 14 (66.6 per cent.) have had cataract.

Three mothers, not subjects of cataract, have had 14 children, of whom 3 (21.4 per cent.) have had cataract.

Seven fathers (4th and 5th generations) have had 36 children, of whom 3 (8.3 per cent.) have had cataract.

Four fathers, with cataract, have had 21 children, of whom 2 (9.5 per cent.) have had cataract.

Three fathers, not subjects of cataract, have had 15 children, of whom 1 (6.6 per cent.) has had cataract.

It is of interest to note the ages at which cataract made its appearance in the fifteen cases in which the facts are known with approximate accuracy.

First and second generations.—In Nos. 1, 2*, 4*, 5*, 6* and 7* the development of cataract is said to have been late in life.

Third generation.—In No. 12* the first symptoms of cataract were detected after the 76th year.

Fourth generation.—In 5 cases (Nos. 20*, **23***, **24***, 25*, and **26***,) the development of cataract was between the 40th and 55th year.

Fifth generation.—Of 6 cases (Nos. **35***, **36***, 37*, 42*, 54*, and 56*), cataract is said to have appeared in all between the 20th and 30th year.

Sixth generation.—In 3 cases (Nos. **65***, **70***, and 71*) cataract was developed between the 6th and the 9th year.

Nos. 12*, 20*, and 25* submitted to operation by extraction; they were cases of typical senile cataract, with a large and hard nucleus in each case.

Nos. 35*, 37*, **65***, **70***, and 71* were treated by dicission of the capsule. In No. 37* the dicission was supplemented, after nine hours, by linear extraction, a well-defined nucleus

having escaped into the anterior chamber, with glaucomatous increase of tension. In the other four cases solution of the lens progressed without noteworthy complication. In all eight cases excellent visual results were obtained.

SPECIMENS OF FILARIA OCULI HUMANI.

DR. F. M. WILSON,

BRIDGEPORT.

Mrs. M. Louisa Reutlinger, aged 42, missionary at Benita, 100 miles north of Gaboon, west coast of Africa, tells me of a worm, called by natives — and also by the missionaries of that locality — the "eye worm;" that it is comparatively common among the natives, and that all the missionaries of that station have had it; but, so far as she knows, the missionaries of other stations do not have it, though some who have visited Benita have had it.

They have two theories: one that they get it from drinking water; another, that the ovum is deposited in their tissues by some of the many insects which bite them. This worm, as she has seen and heard of it, is always about 2 inches long and $\frac{1}{16}$ in. thick, and white in color. They were common enough not to be considered unusual among the natives.

In the mission school native children would come to her and say, "My worm hurts my eye, I must go home." The natives feel them in different parts of the body, but she never knew one to be extracted save from beneath the ocular conjunctiva. They can there see the worm, and they thrust a pointed piece of palm leaf, having a barb on the end, through the conjunctiva, hook the barb around the worm, and pull it out.

She has never known a worm to come to the surface itself. She has never known any serious harm to come to the natives from the presence of the worm. Of the missionaries only she and one other have had worms removed. The others have felt the worm, and, in some cases, seen it beneath the ocular con-

junctiva, but in all cases except these two the worm has disappeared of itself and not reappeared.

Her own personal experience with it began about six years ago, and during all that time she has, at intervals varying from one month to six, felt the worms. She has, on quite a number of occasions, seen the worm beneath the ocular conjunctiva of her own eye.

The sensations caused by the worm are, first, consciousness of its presence from its motion described as "tickling," and, when it gets near the surface, pain, which, around the eyes, was sometimes very severe.

In February, 1889, while in Basle, Switzerland, Dr. Hagler removed a worm from beneath the skin of her left upper lid. In November, 1889, Dr. F. J. Young of Bridgeport, Conn., removed another from beneath the skin of right upper lid, and kindly furnished the specimen which I have mounted and now show you. When caught, the worm was rapidly moving from outer toward inner canthus, and its motions beneath the skin were plainly visible. It was very lively when pulled out, and for some minutes after.

In February, 1890, Dr. Loveland of Clifton Springs removed a similar worm from beneath the skin of her back. I expected to have shown this specimen also, but a servant carelessly destroyed it. On July 1, 1890, my associate, Dr. Byron, removed from her right upper lid a piece of a similar worm, about one inch in length, not being able to get the whole worm. The third specimen was kindly furnished by Dr. D. B. St. John Roosa.

I have letters from three other missionaries, which confirm Mrs. Reutlinger's story of the size and habits of the worm, in all particulars.

DISCUSSION.

DR. HENRY D. NOYES, of New York. — I have removed a filaria from the anterior chamber of the eye of a horse. It had been recognized for some months. A large paracentesis was performed, and the worm came out with the gush of aqueous humor.

DR. B. ALEXANDER RANDALL, of Philadelphia. — I have

looked for the filaria in the eye where it was found in the blood. Dr. DeSaussure of Charleston brought a case to the last meeting of the American Medical Association. The filariæ were quite numerous in the blood, but there was no suggestion of their presence in the eye, so far as the rather unsatisfactory study showed. As they were of microscopic size in the blood, they might have been readily overlooked.

DR. F. M. WILSON, of Bridgeport, Conn. — So far as I have been able to obtain the evidence from missionaries themselves, the filariæ are more common in the cellular tissue than in the eyeball. From the literature we should infer the opposite.

A NEW OPHTHALMOSCOPE.

DR. GEO. M. HARLAN,
PHILADELPHIA, PENN.

In this instrument I have endeavored to combine, so far as possible, the advantages of the Loring, Knapp, and Noyes ophthalmoscopes, and have made several additions and some changes in the mechanism.

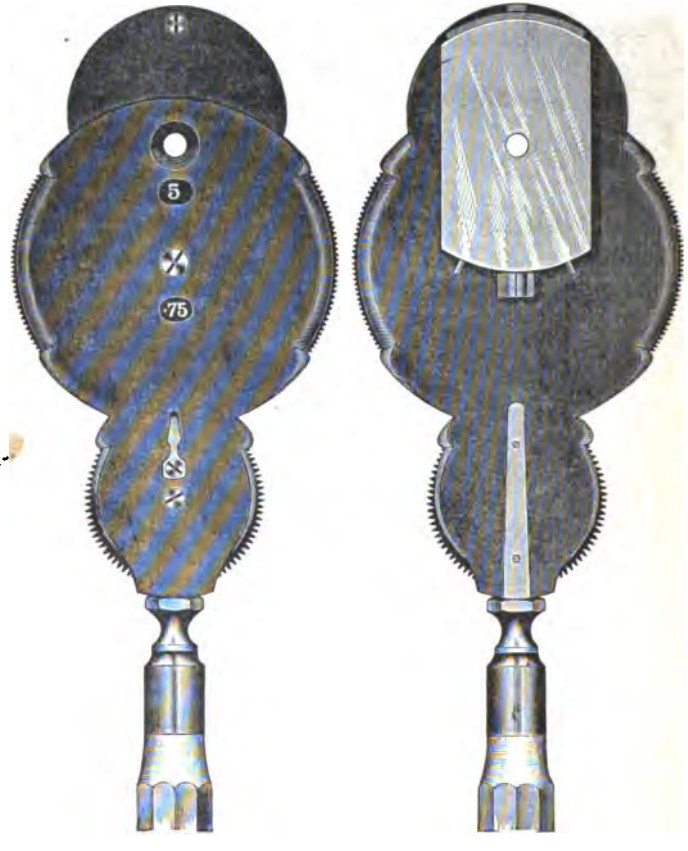

There are two discs placed one directly over the other. The principal one has seven plus and seven minus lenses, with intervals of one dioptre, and is rotated by means of a small cog-

wheel at the top of the handle. The supplementary superimposed disc contains plus and minus lenses of .50, .75, 15, and 30 D., and is rotated by means of its serrated edge. This gives lens combinations with an interval of $\frac{1}{4}$ D. from .50 to 7; and with an interval of 1 D. from 7 to 37. The lenses are protected by a metallic cover. There are also stenopaic slits $\frac{3}{8}$ of a milli-



meter in width at angles of 90°, 180°, 45°, and 135°, which can be placed in front of any of the lenses in the principal disc. The Wadsworth tilting mirror is used.

The instrument is small and compact, and carefully balanced, and, to secure greater lightness and elegance, is made of aluminium. It weighs less than two ounces

DISCUSSION.

DR. B. ALEXANDER RANDALL, of Philadelphia.—I have used a similar modification of the Loring ophthalmoscope for several years, and can repeat the statements I made here in 1886 as to the extreme satisfaction that I have had from the use of the instrument in that form.

178/30

41
22

175/30

41
22